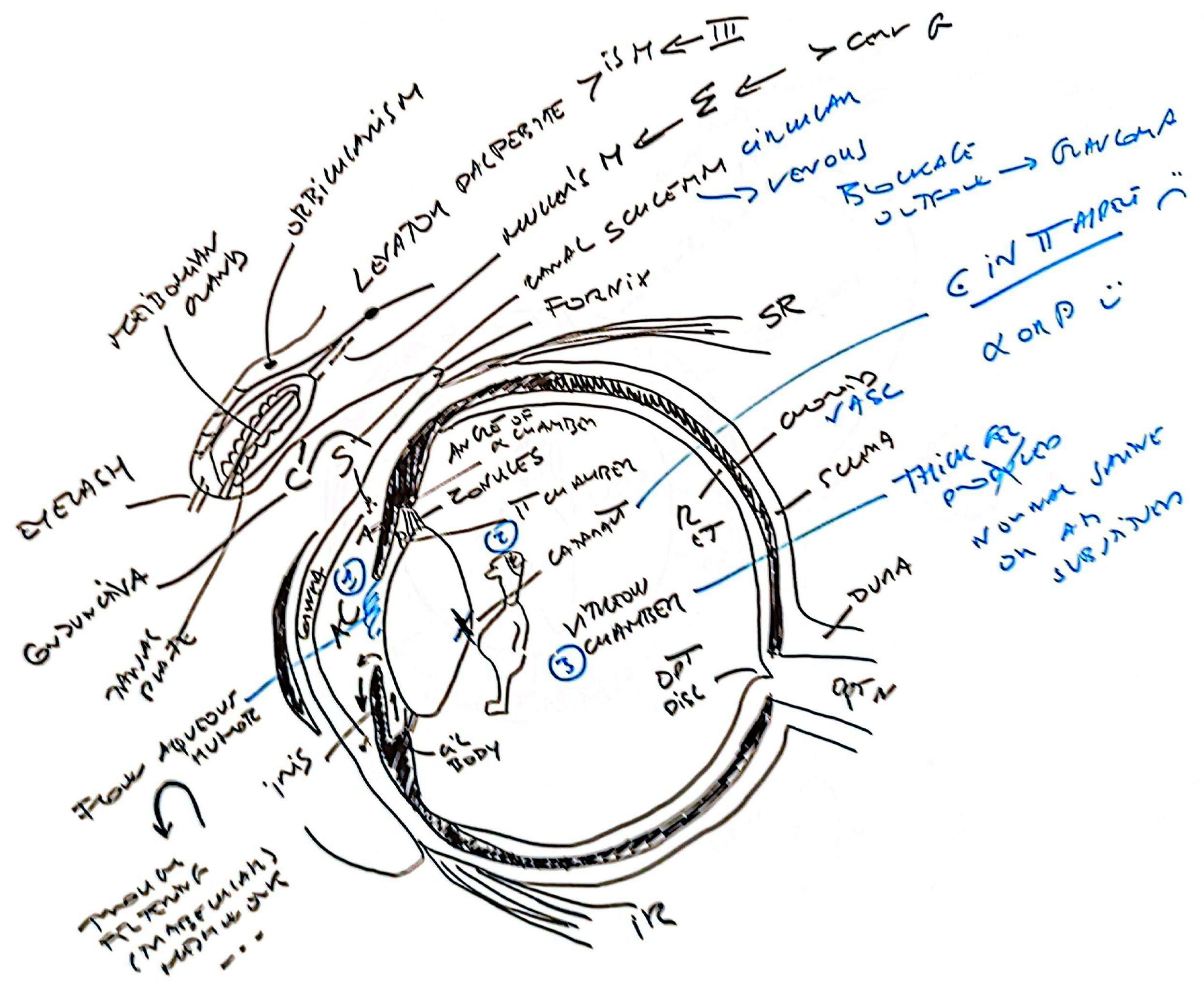
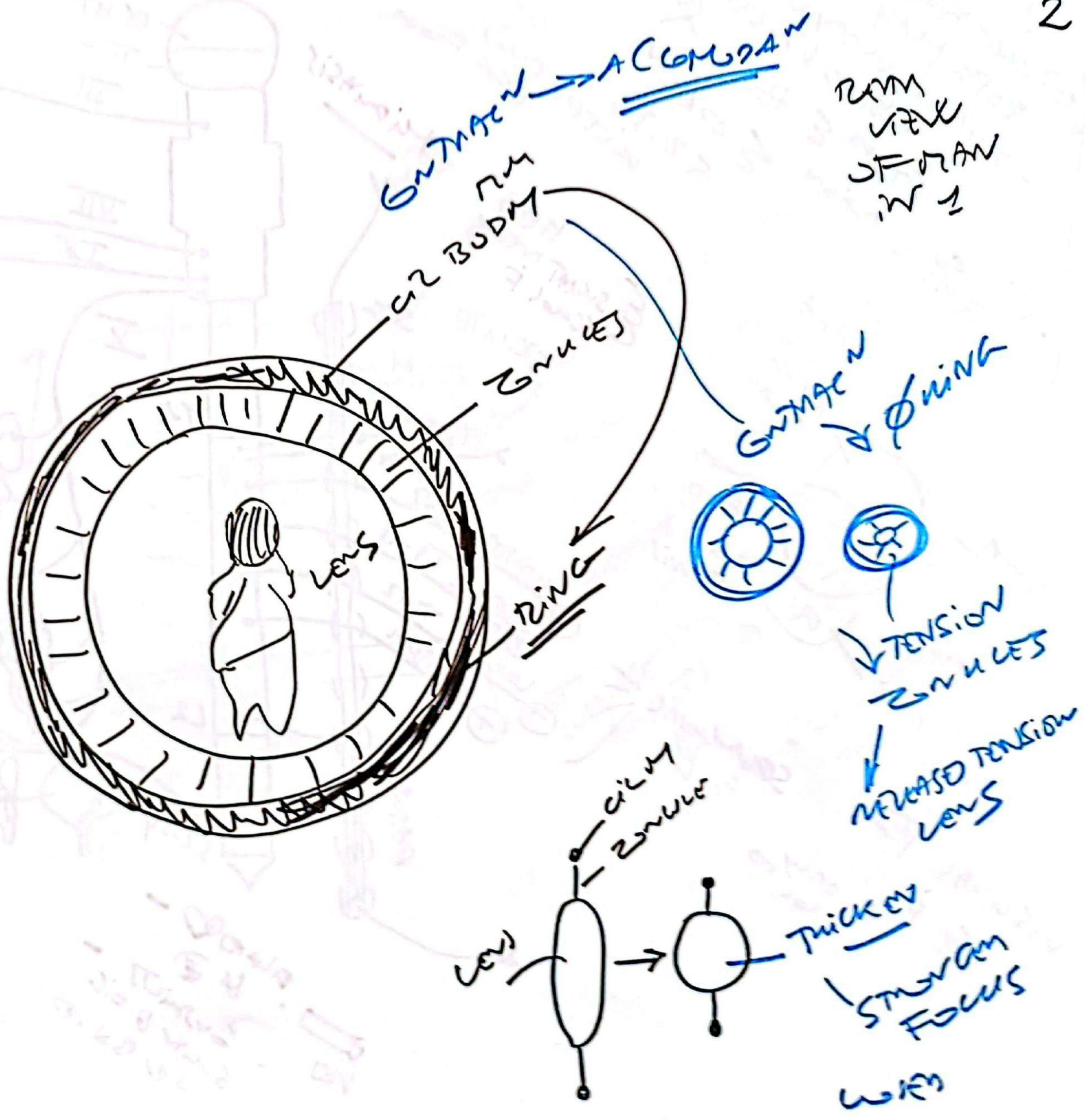

3 LAYERS CORNEA



OUTER

EPIT

BOWMAN'S MB

TRASPARENCY FROM

STROMA

DESCMET'S MB

ENDOT
DAMAGE
AFFECTS

H₂O
CORNEAL CLOUDING

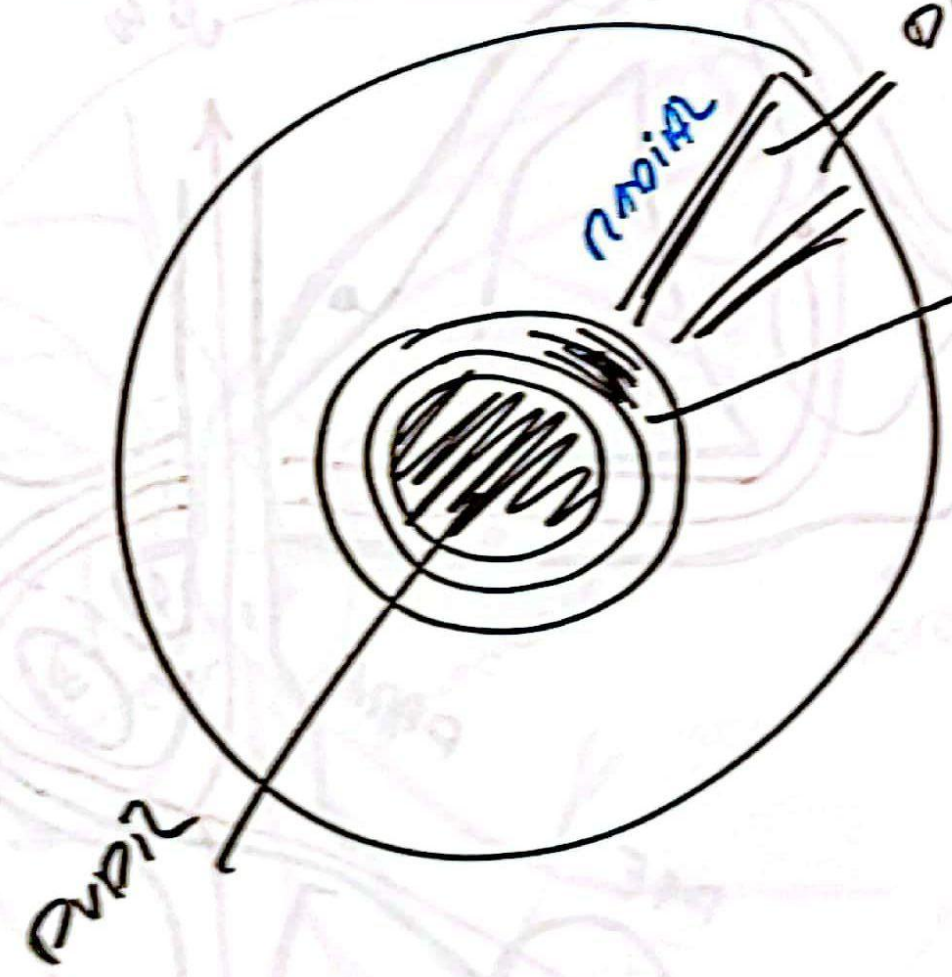
1mm

CORNEA

ii

GL

FI



Σ SCR
DIATOR MM PUPIL PUPIL

MM iris

GROSSION M
GROSSION
XIII

PUPIL

RADIAL

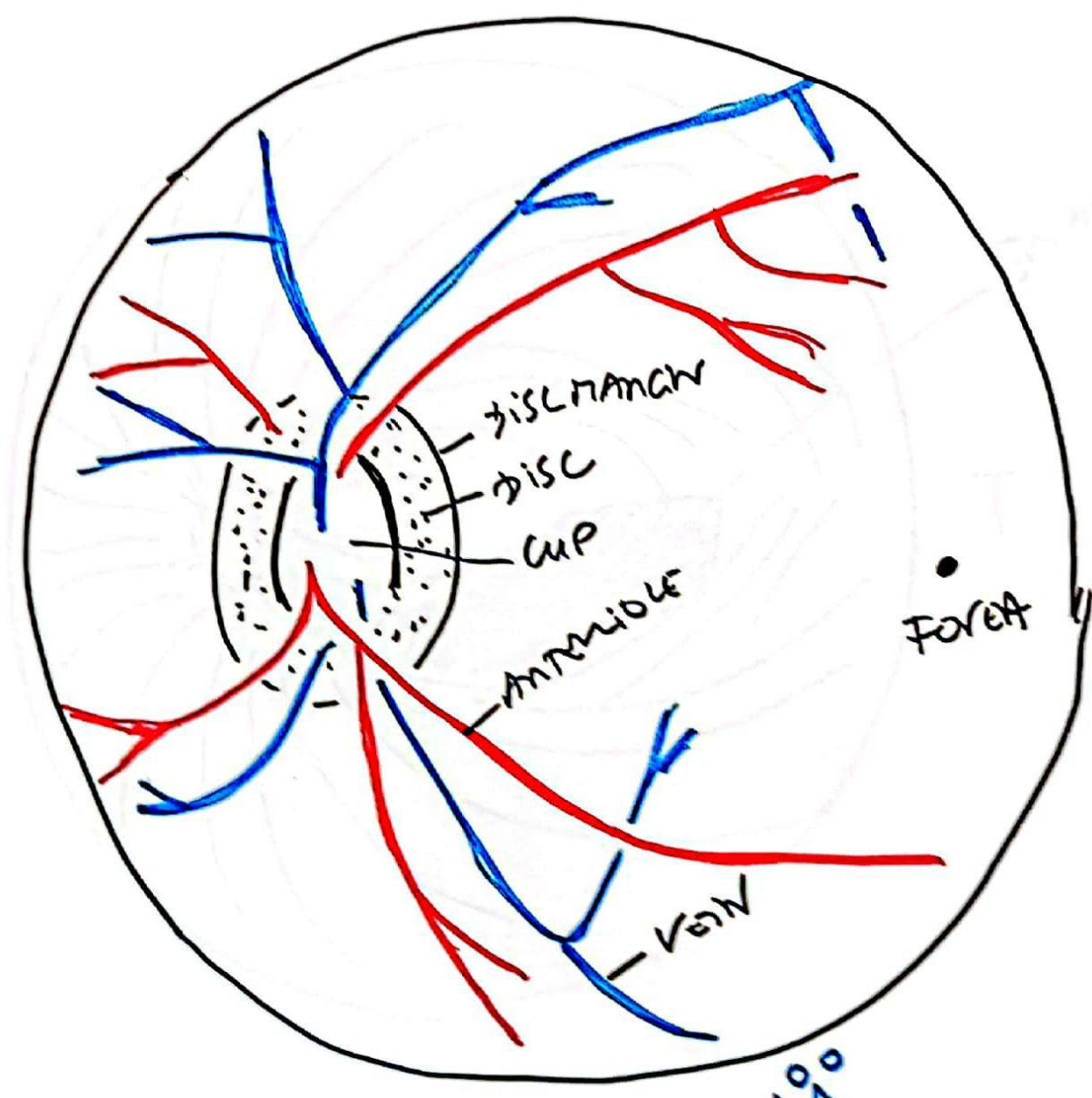
DIATOR

VIEW 6
RETINA
→ PUPIL

4 QUADRANTS

NASAL

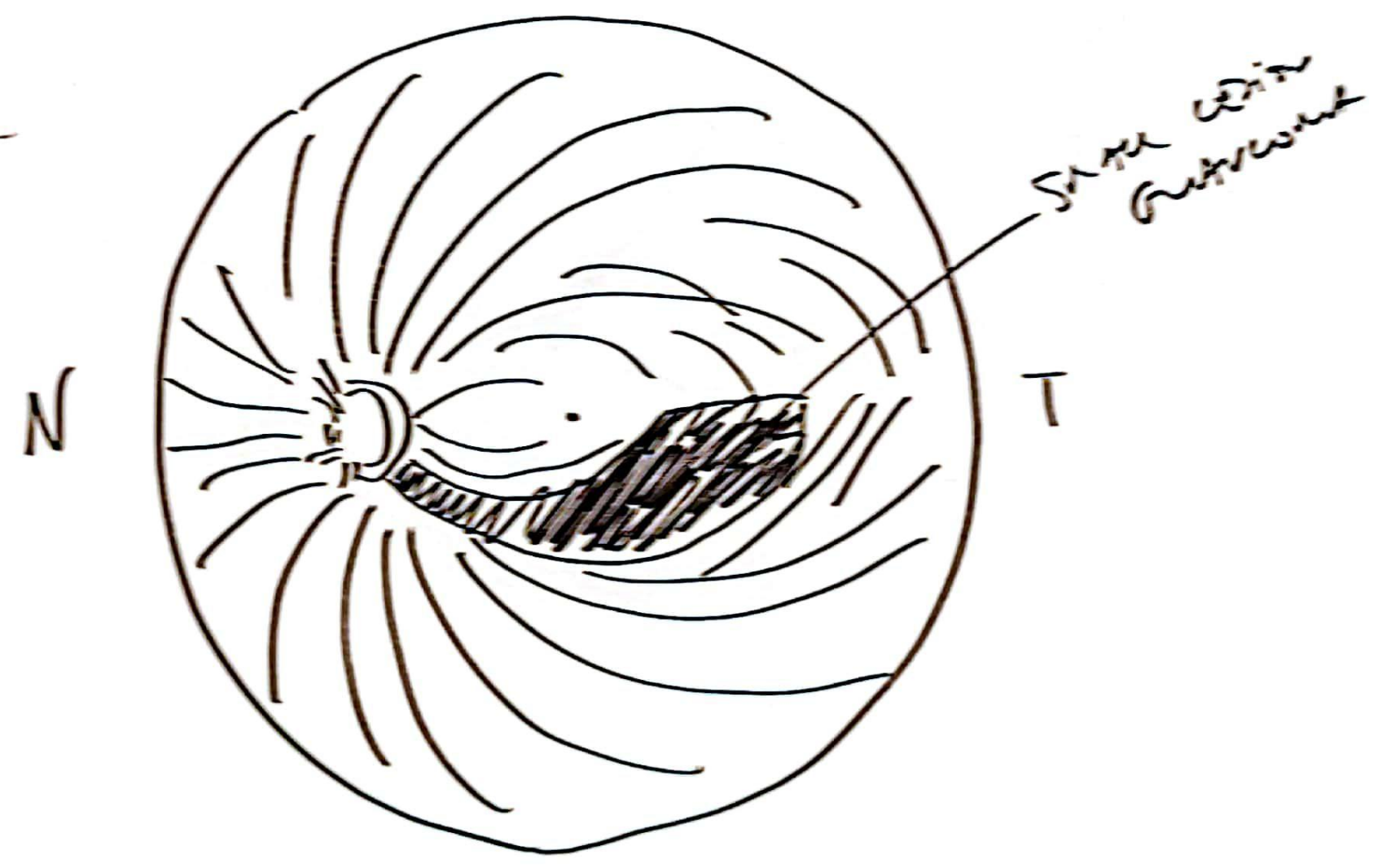
TEMPORAL



VV AA
SMCM

PATTERNS
OF OPTIC
FIBRE
GROWTH
UPON
OPT DISC

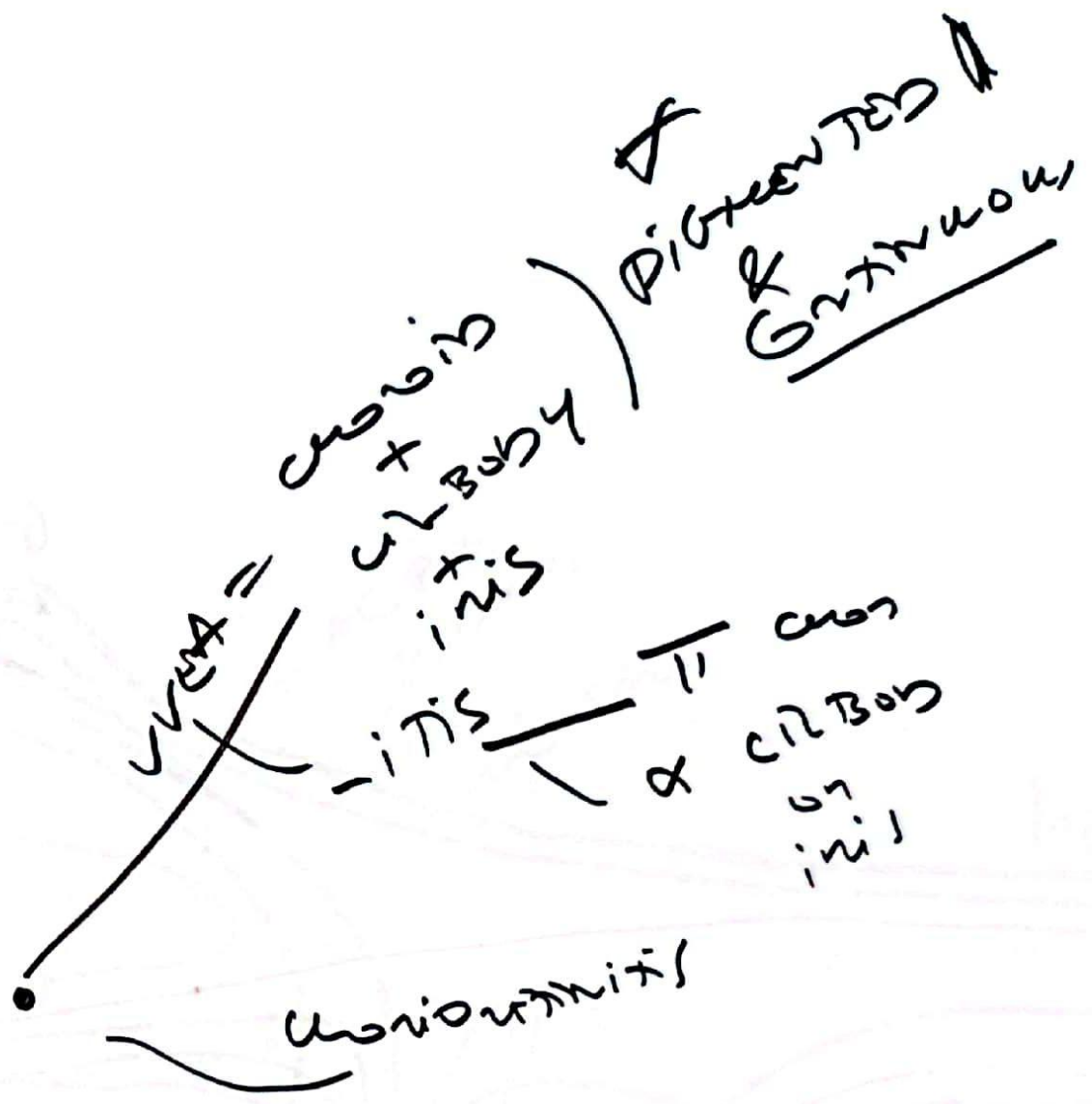
Optic Nerve



Spike lesion

N

T



LAC
APPARATU

