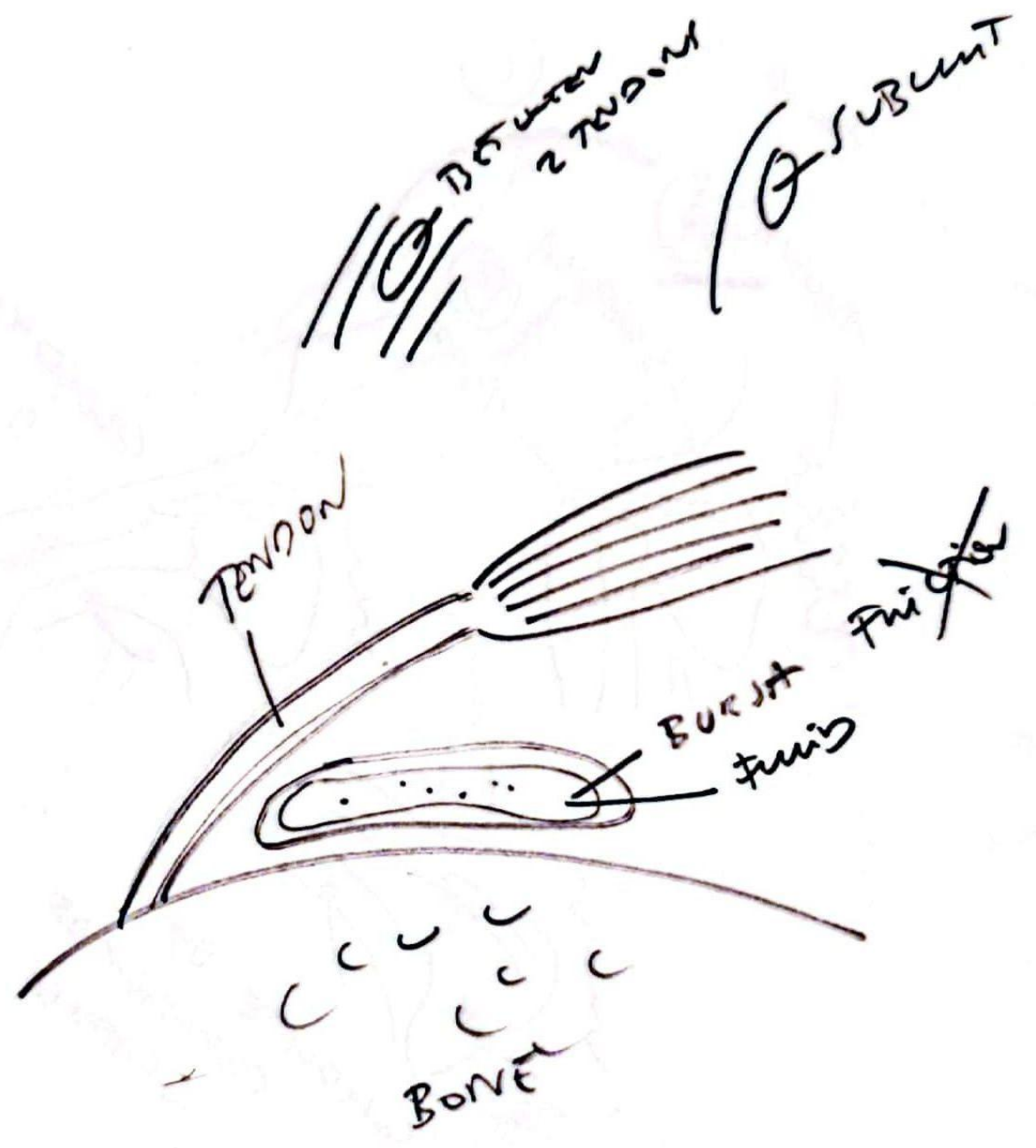


- BURSITIS
- 1 TENNIS ELBOW & GY CRT TENDON
 - 2 SWELLING OF ELBOW
 - 3 THROMBOTIC BURSITIS
- OLECRANON BURSITIS
- SUBCUT

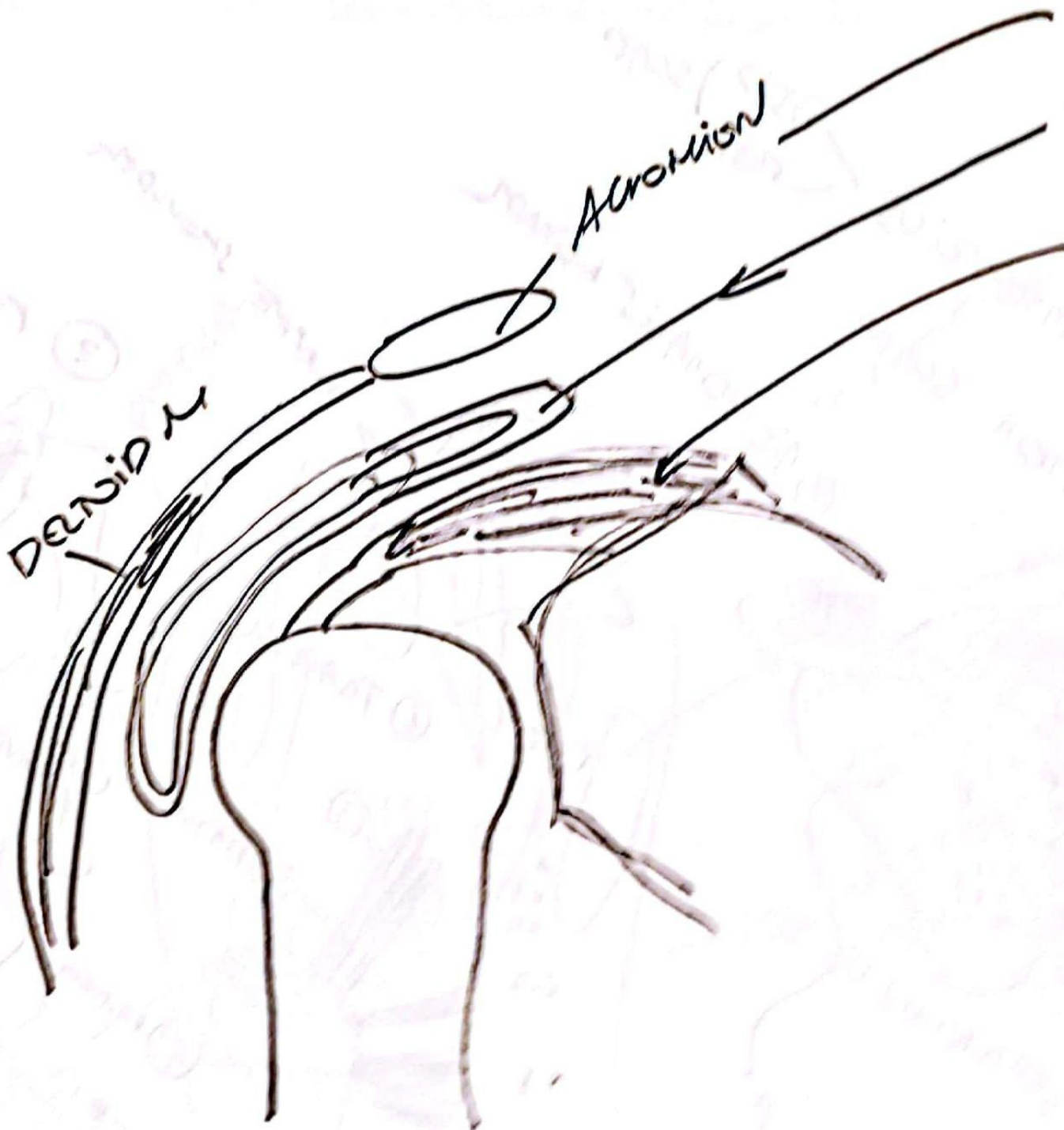


BURSA
BETWEEN
TENDON
& BONE

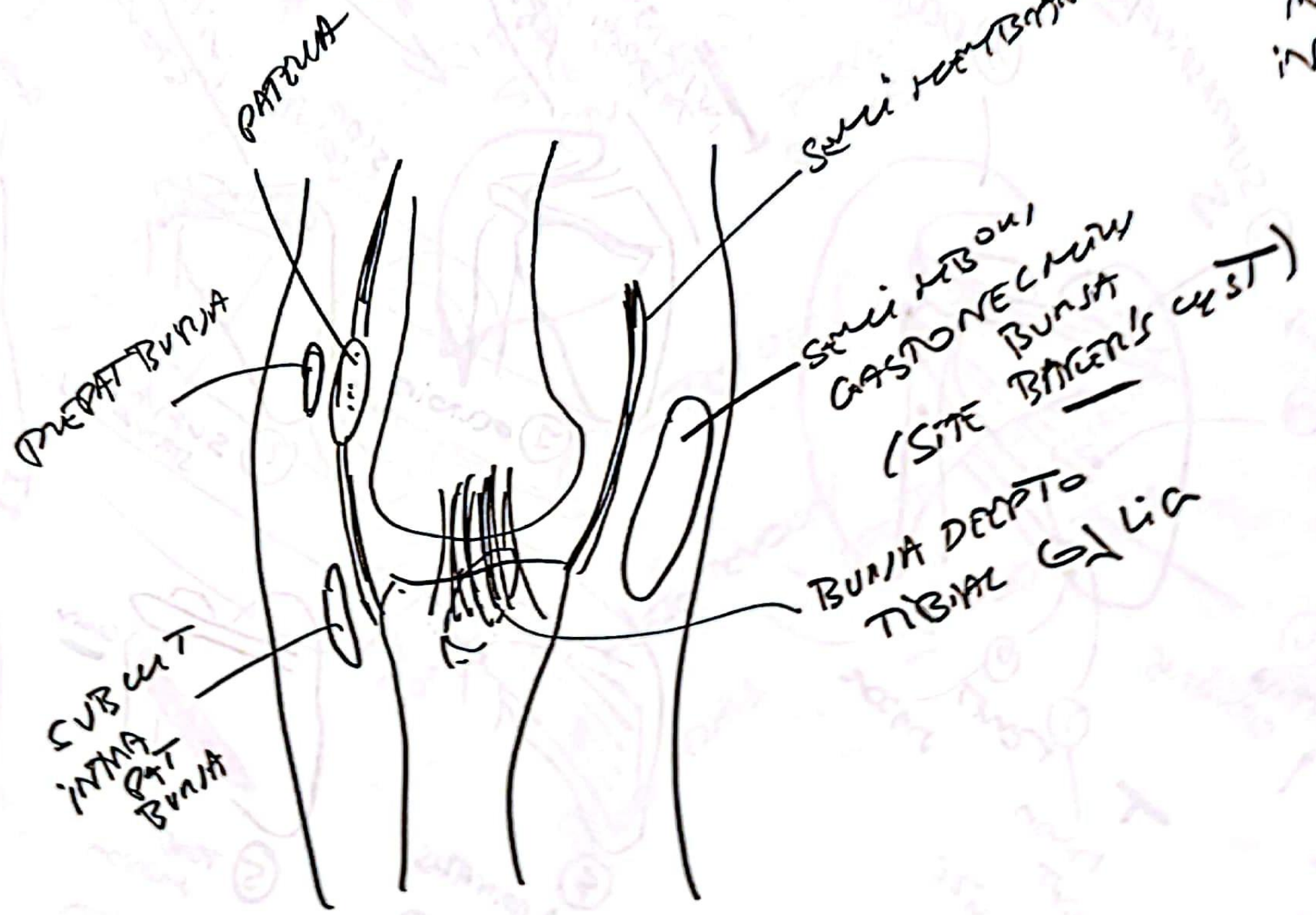
Deltoid M

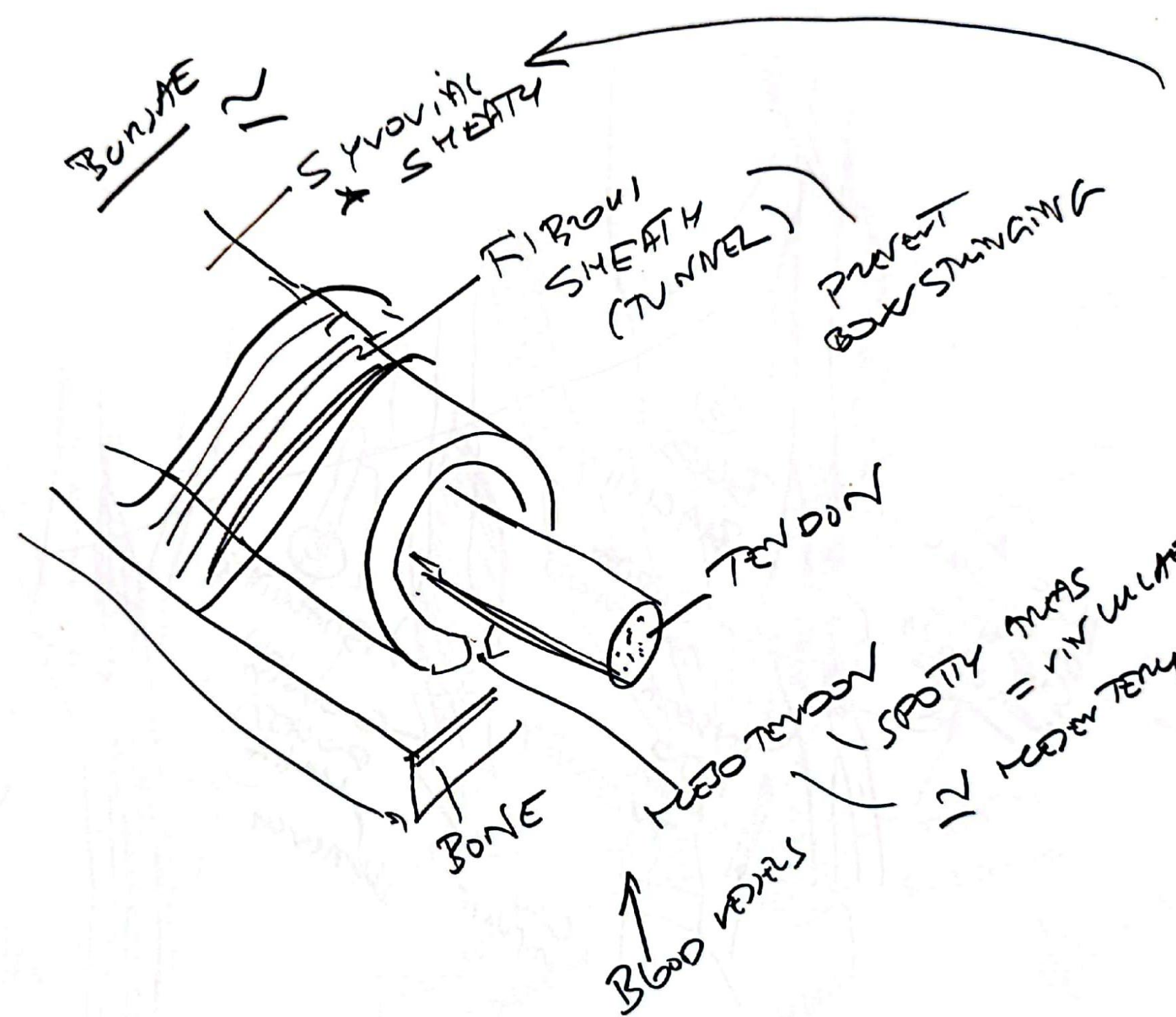
ACROMION

- ACROMION
- SUBACROMIAL BURSA
- SUPRASPINATUS M



BURSAE
KNEE
COMMONLY
INVOLVED
IN BURSTITIS





TYPICAL SYNOVIAL SHEATH

BUNDLE

SYNOVIAL SHEATH

FIBROUS SHEATH (TUNNEL)

PREVENT BOWSTRAINING

TENDON

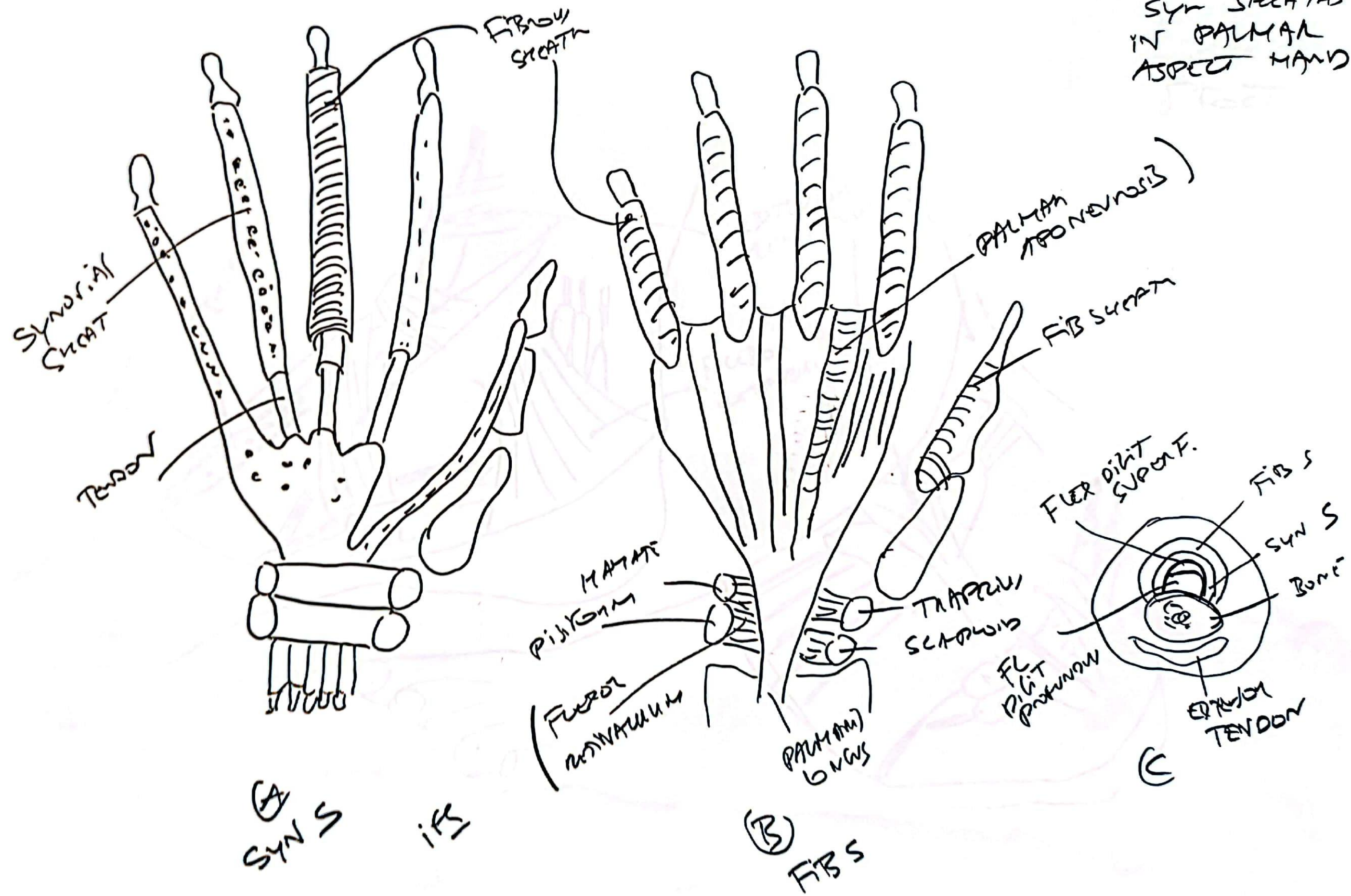
BONE

BLOOD VESSELS

MEDIAN TENDON

SPOTTY AREAS = VASCULATURE
12 MEDIAN TENDON

DISPOSITION
 SYN SHEATHS
 IN PALMAR
 ASPECT HAND



SYNOV
SHEATHS
OF FOOT

