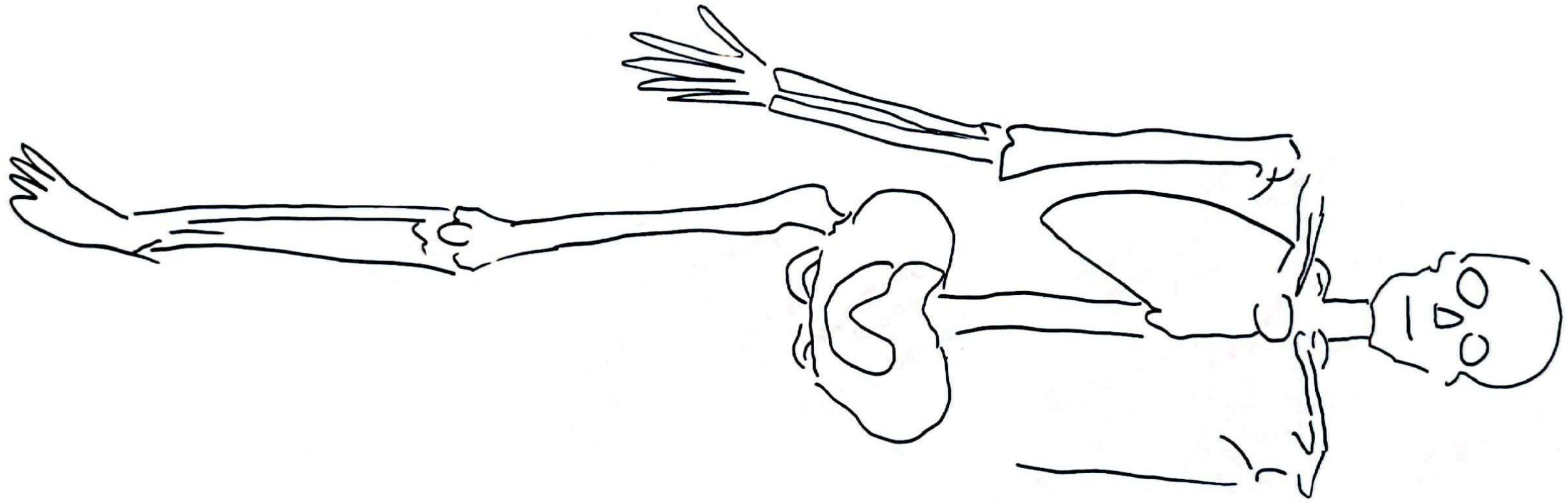
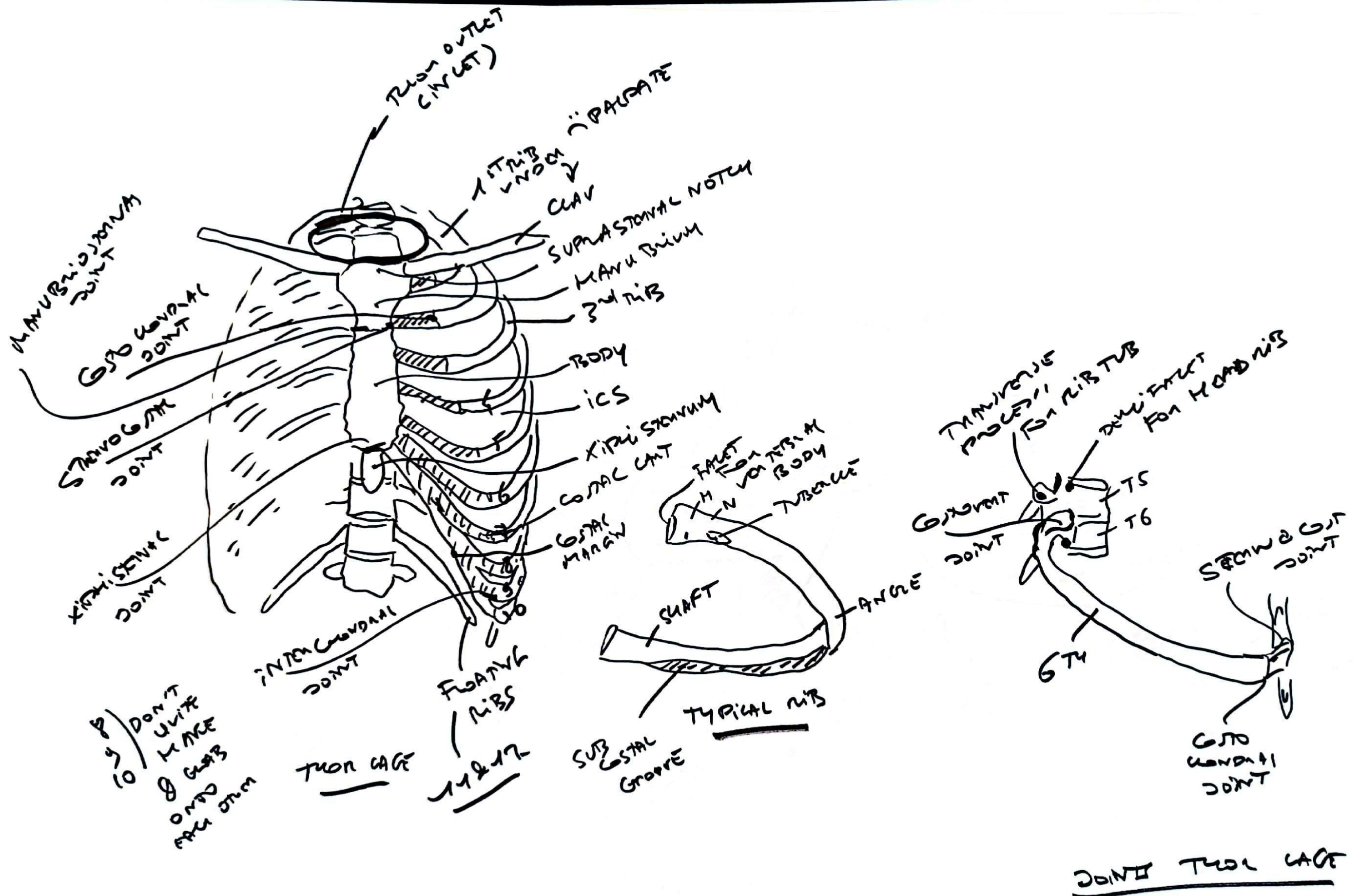


# SKELTAL

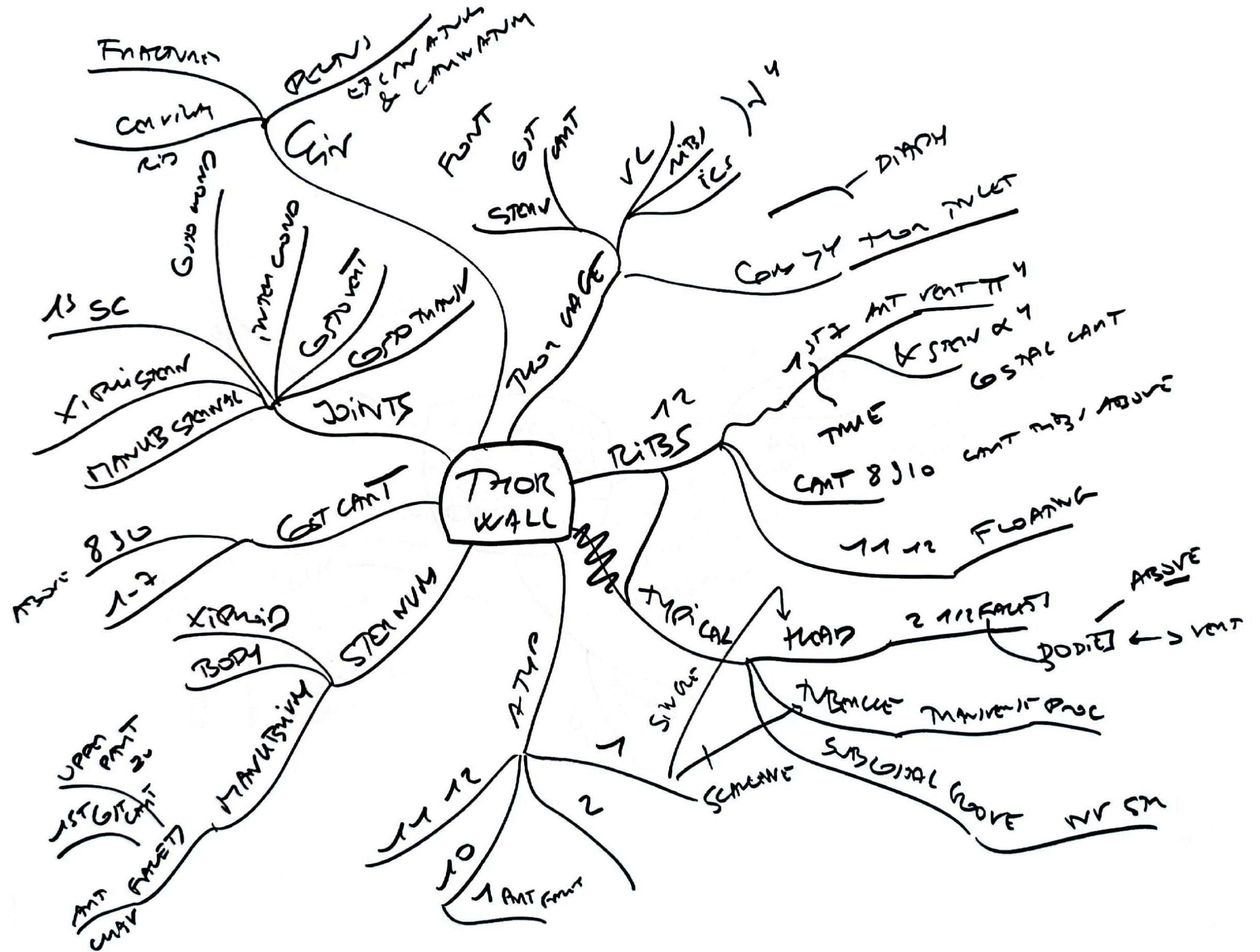
47 rays

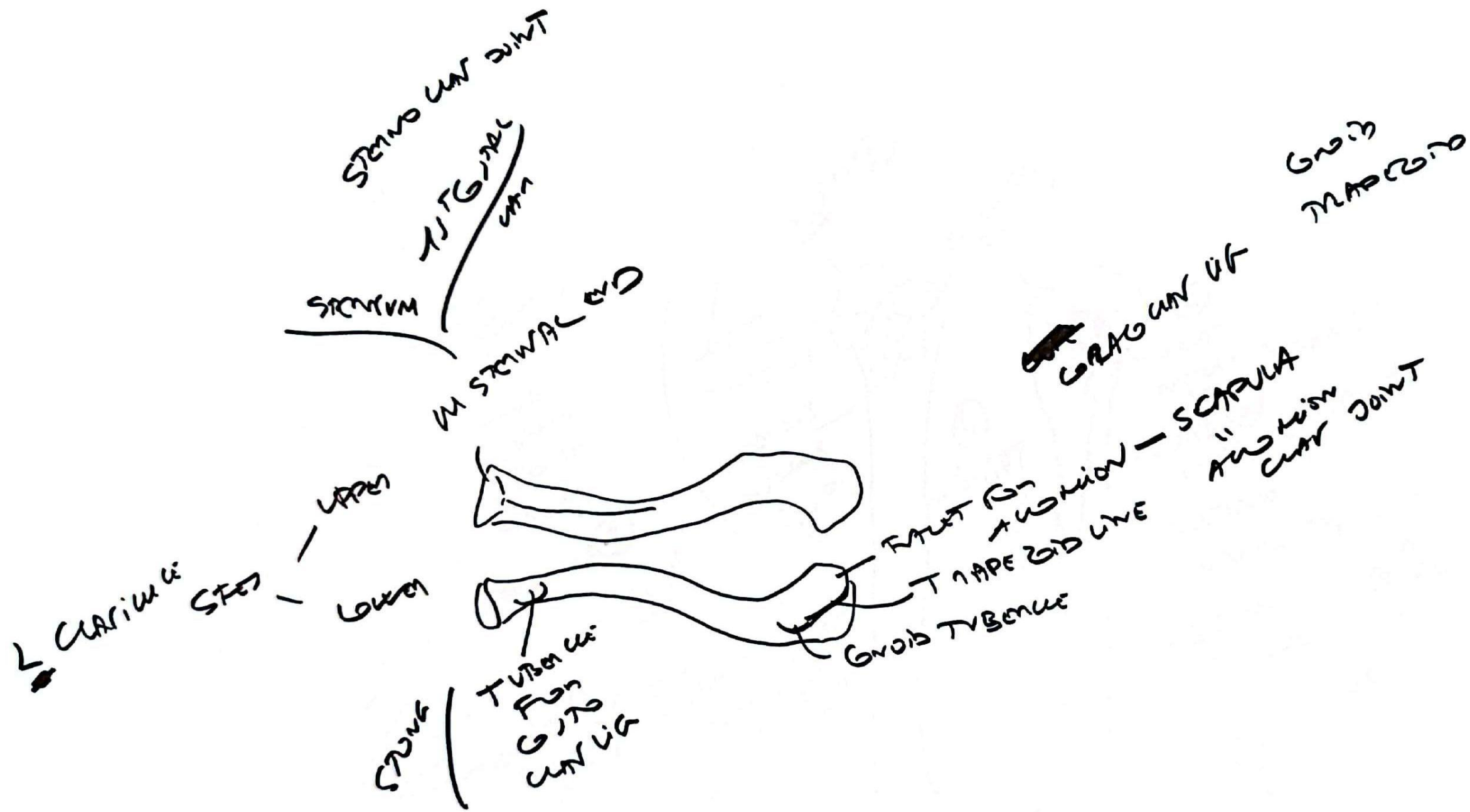


1 RIB CASE



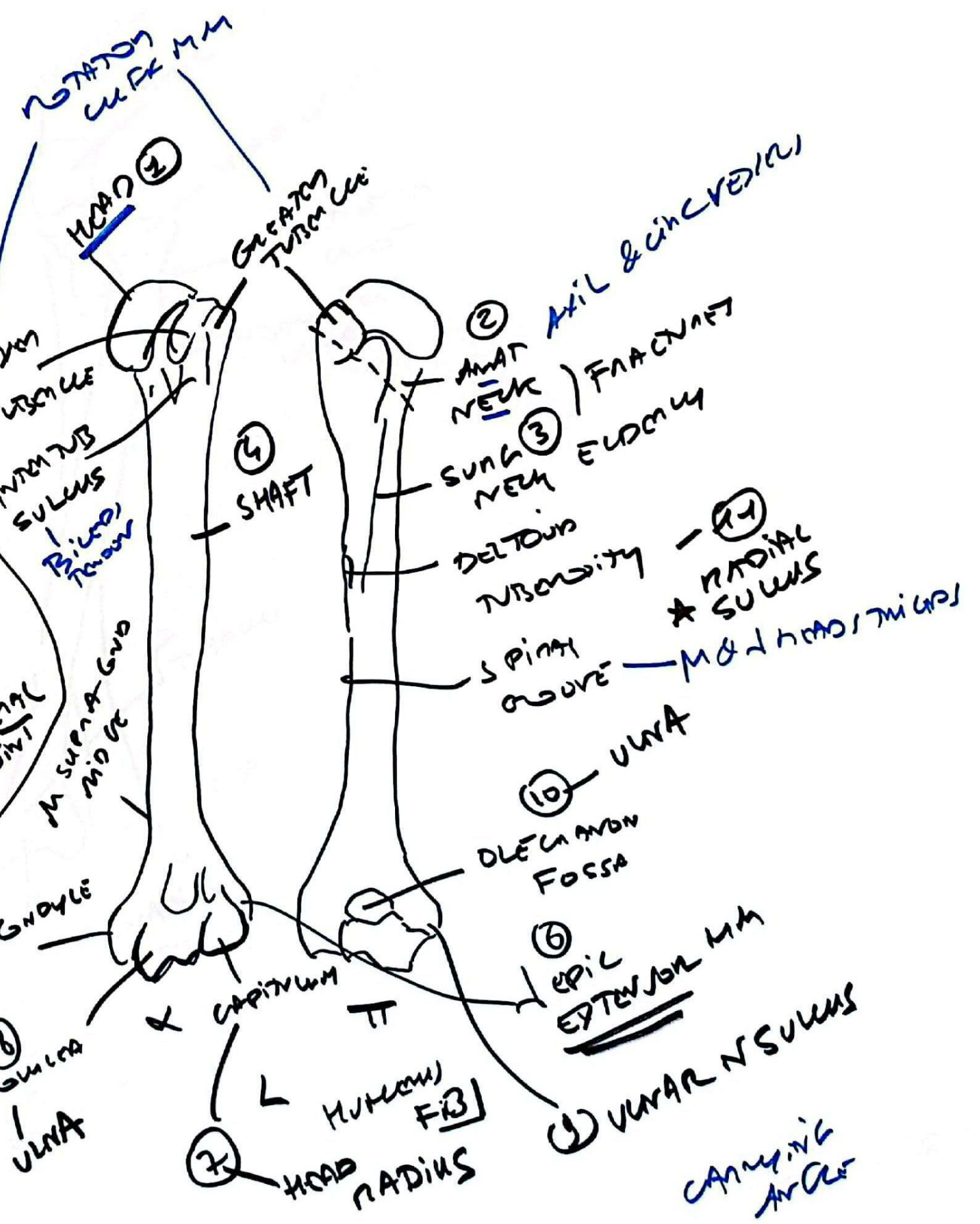
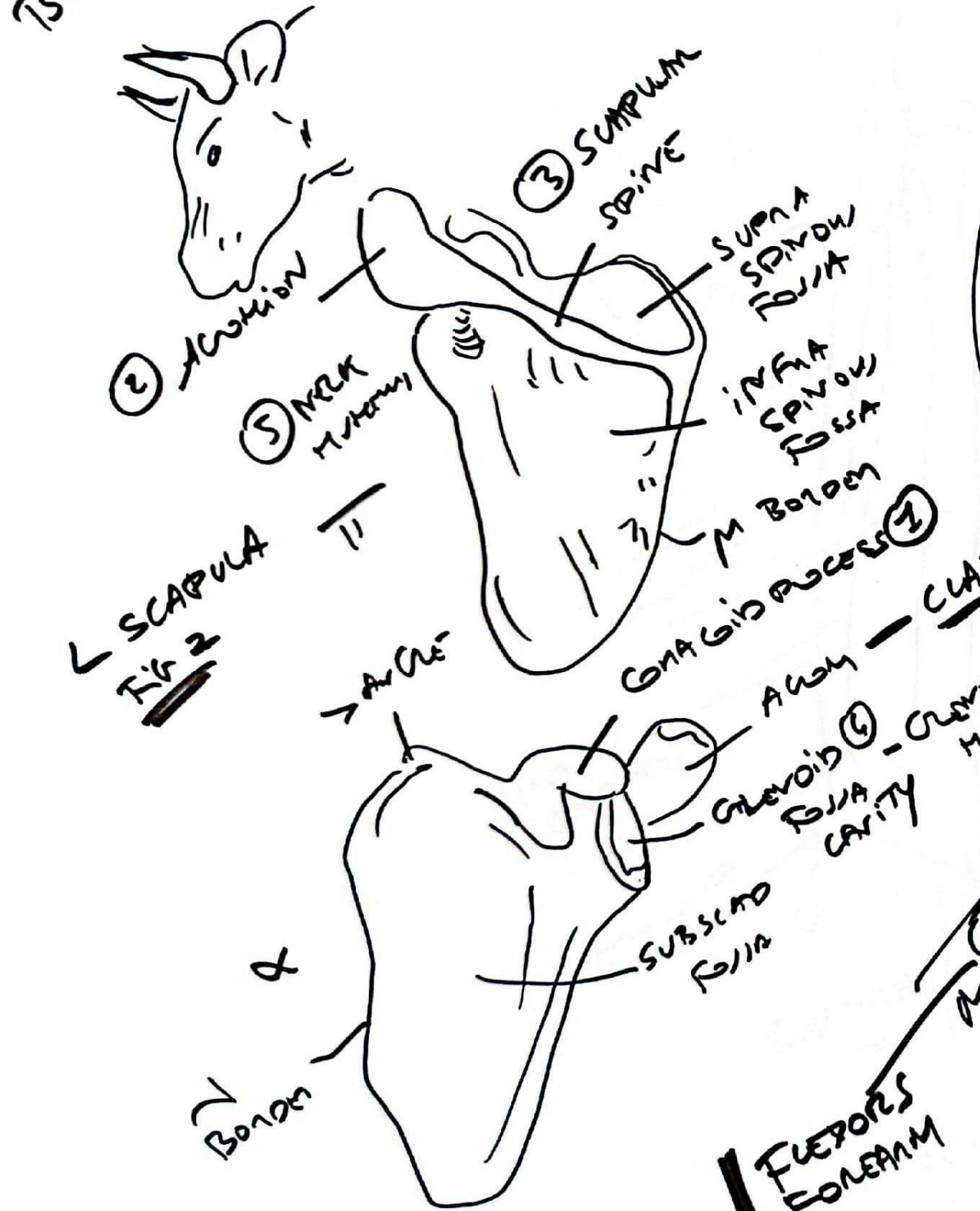


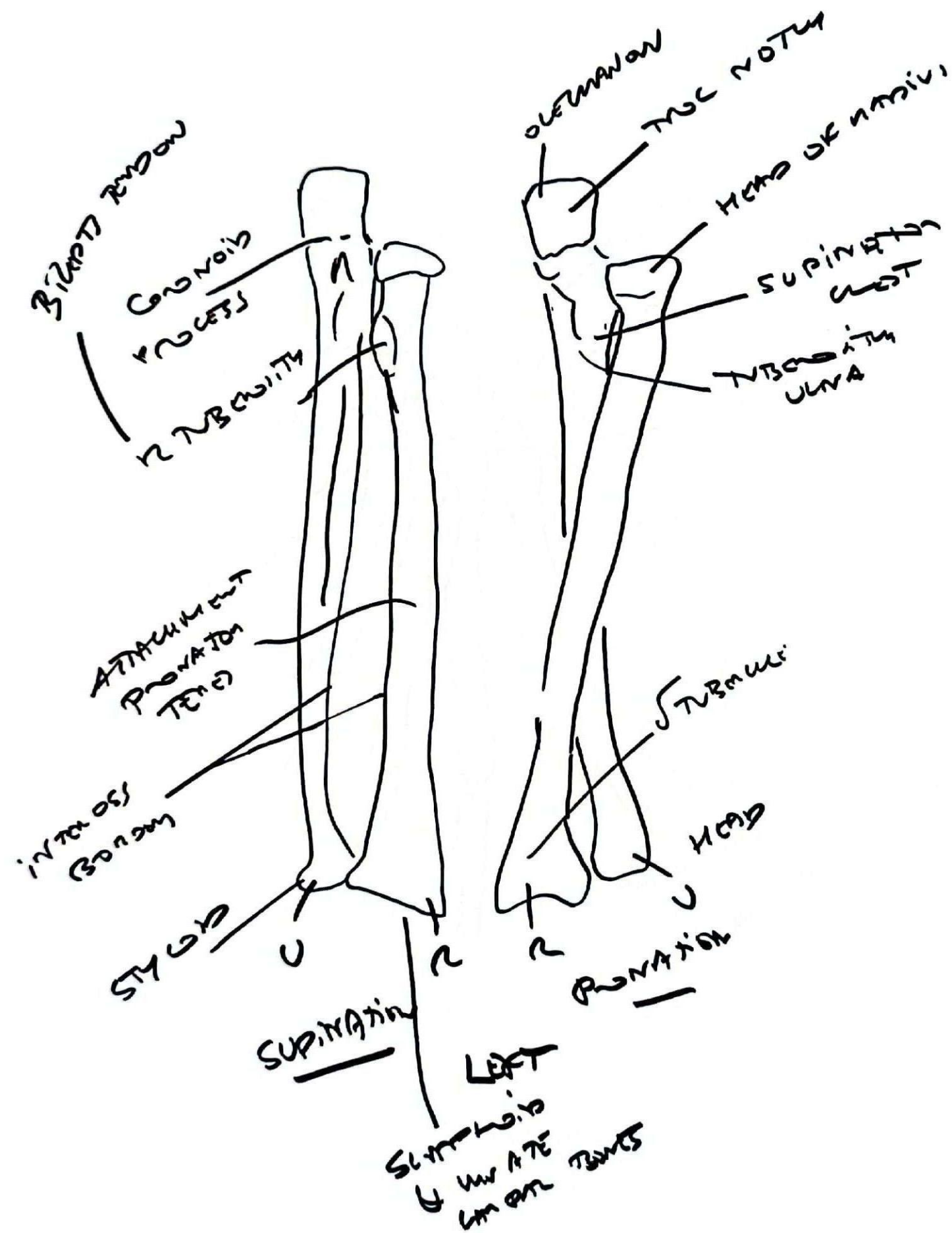






**BULL HEAD**







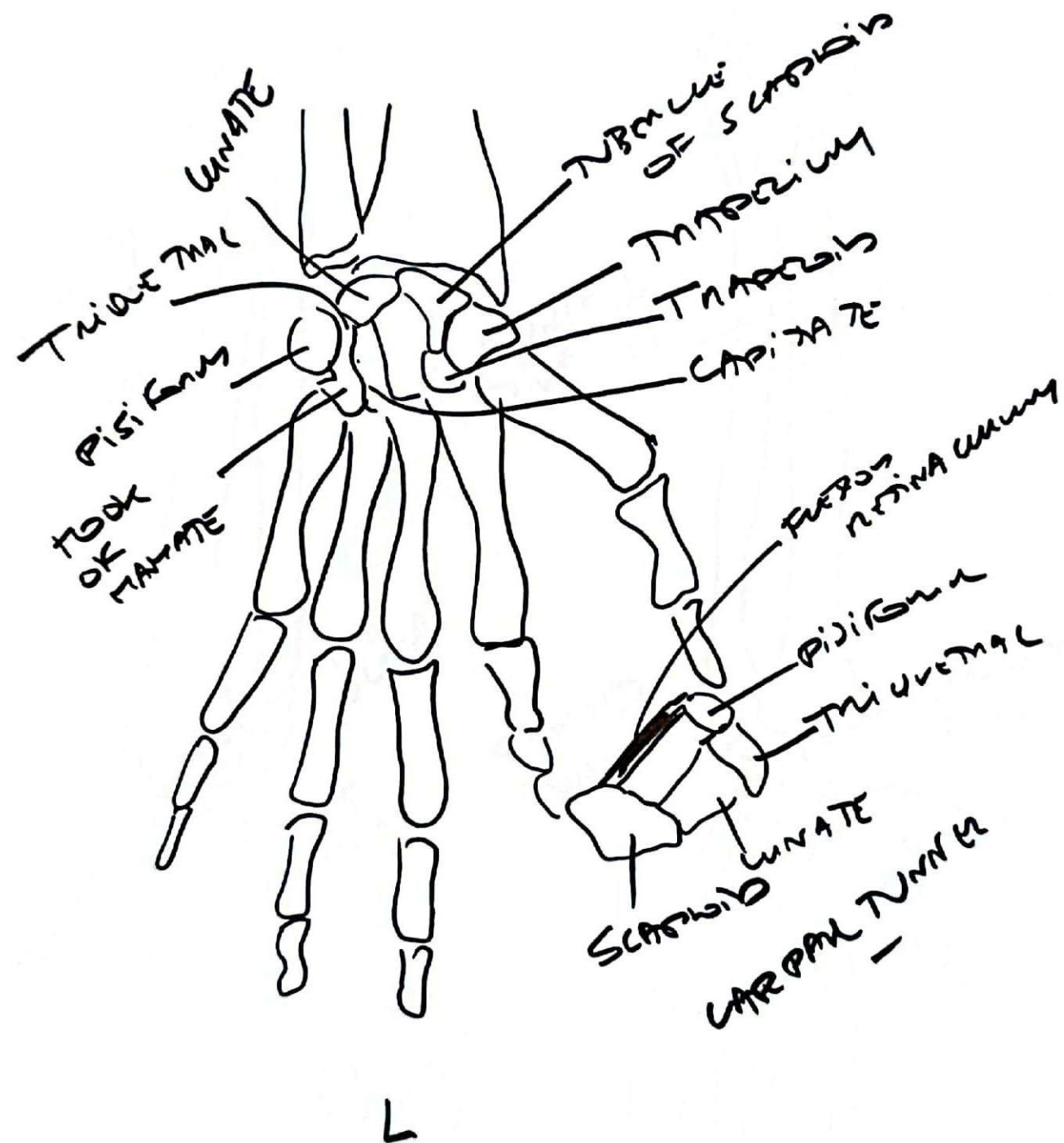
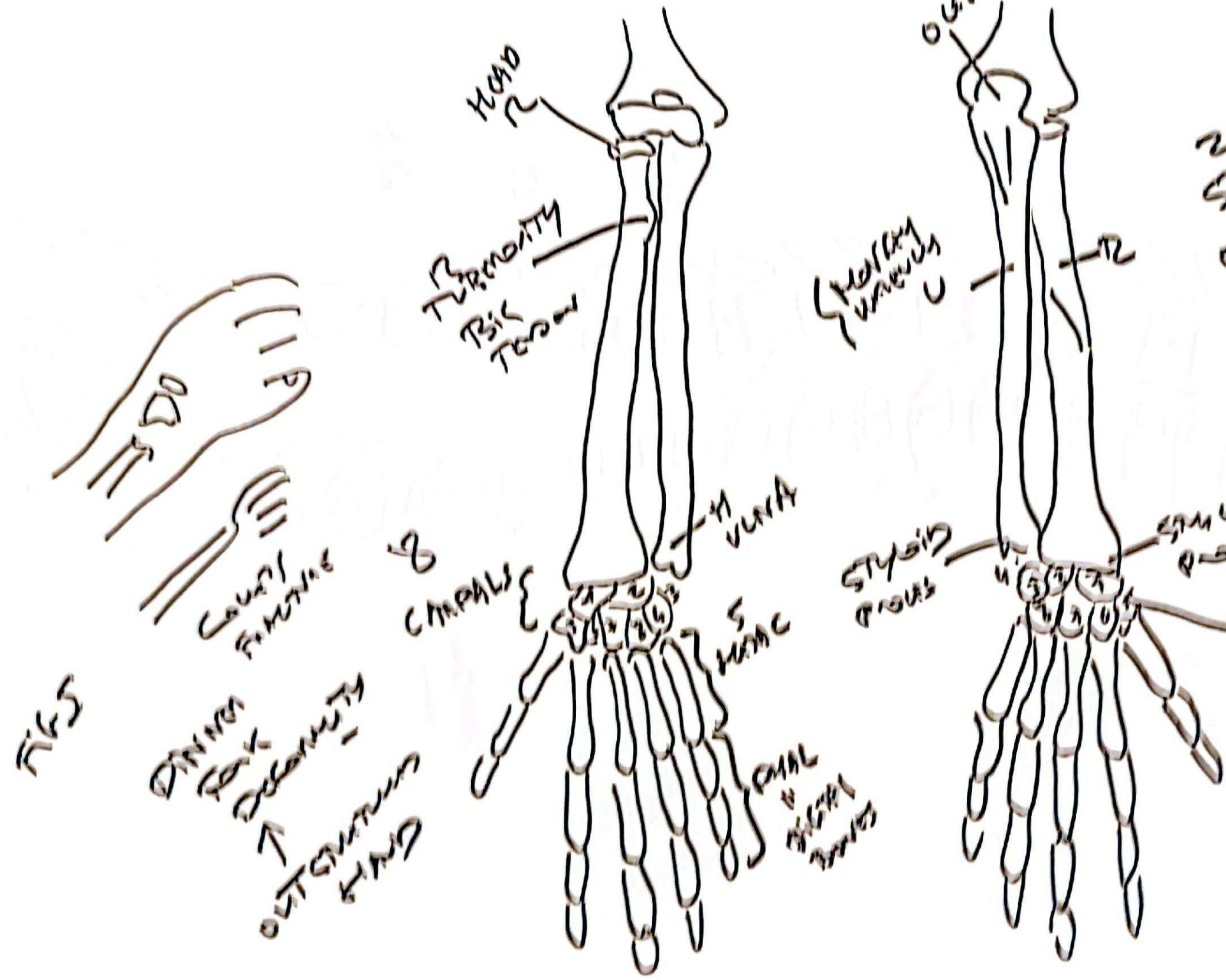


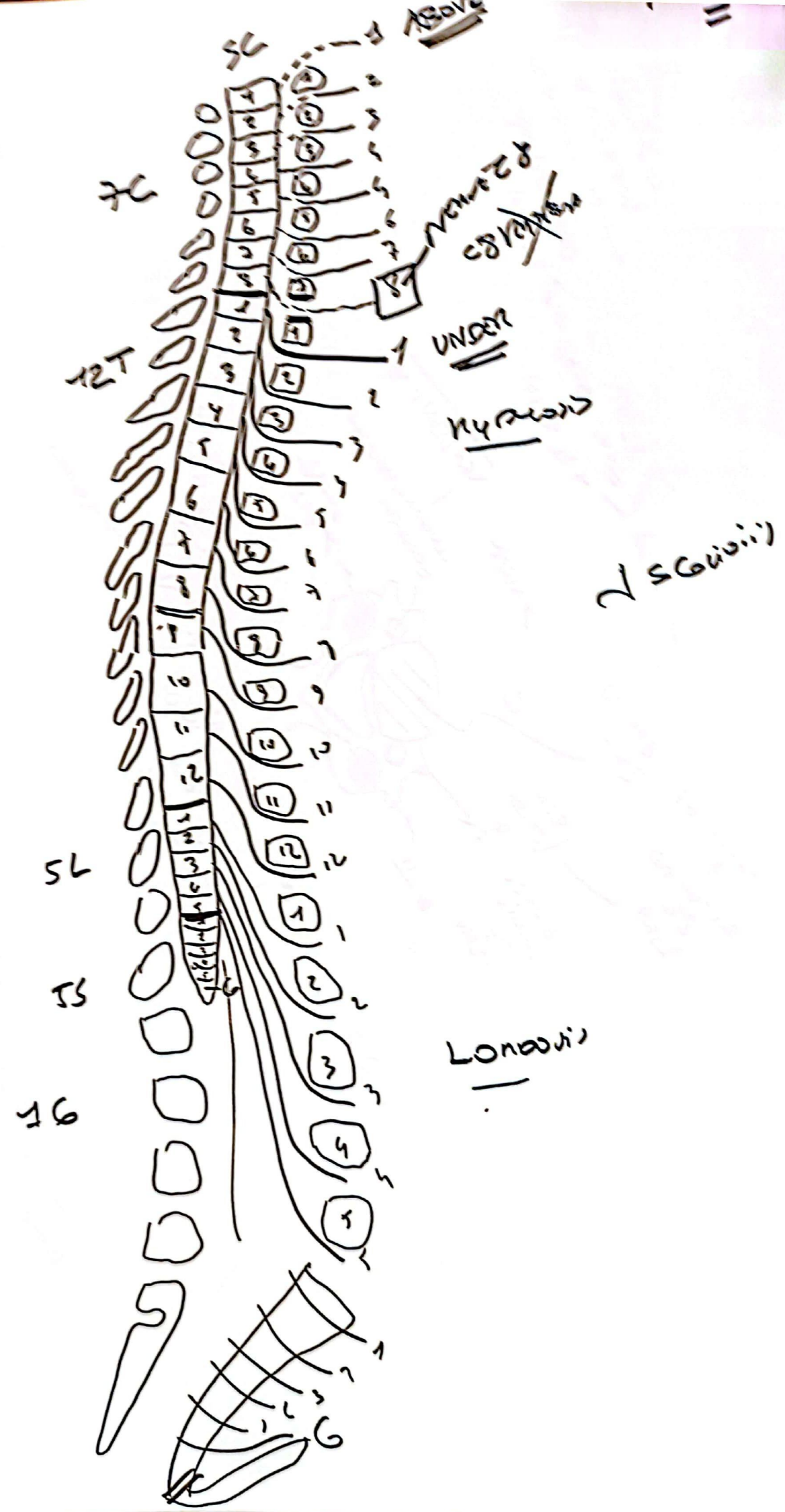
FIG-4  
FOREARM & HAND



2 FOLDS STARTING AT RADIUS OF ULNA  
 1) SUPRATORAL CARPUS  
 2) ULNAR CARPUS  
 3) TRAPAZIUM  
 4) POSITIVE ALBUMIN  
 5) THAT TRAPAZIUM  
 6) THAT TRAPAZOID  
 7) CANNOT HANDLE  
 8) HANDLE HANDLE

SKULL  
 CORONOID PROCESS  
 DINNER FORK  
 POINTS  
 OUTSTANDING HAND





- Lig. Interspin. Disc
- Synovial joints Ant. Proc
- Body DBM
- Basivertebral LV
- Transverse process
- Spinous process
- Lamina
- Interspinous Lig
- Intervertebral Disc

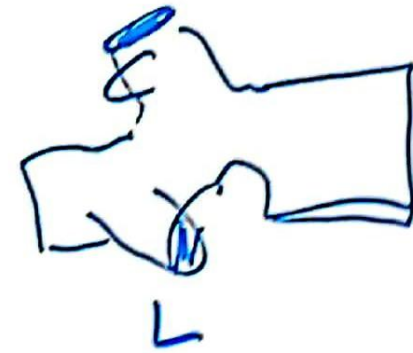
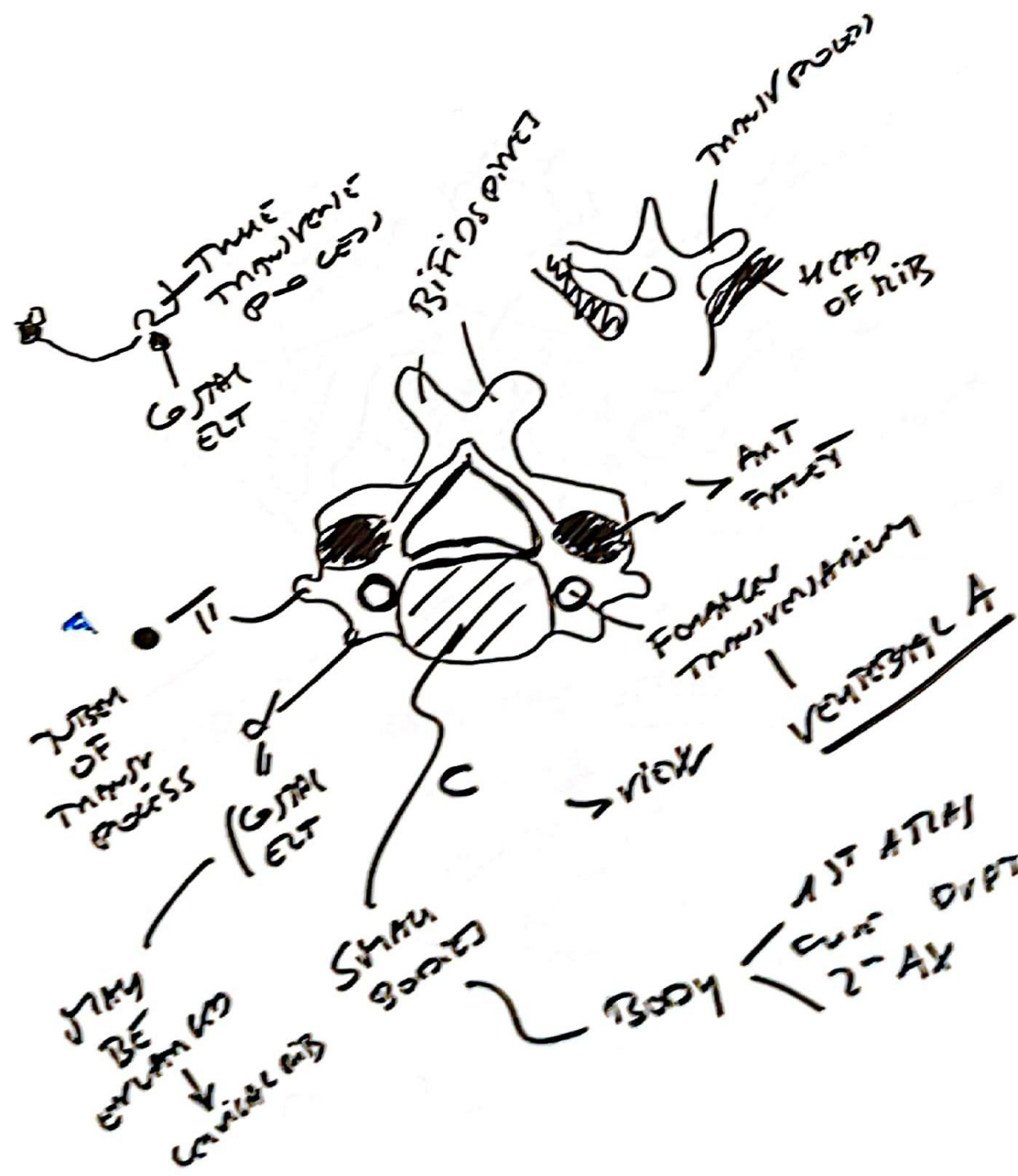
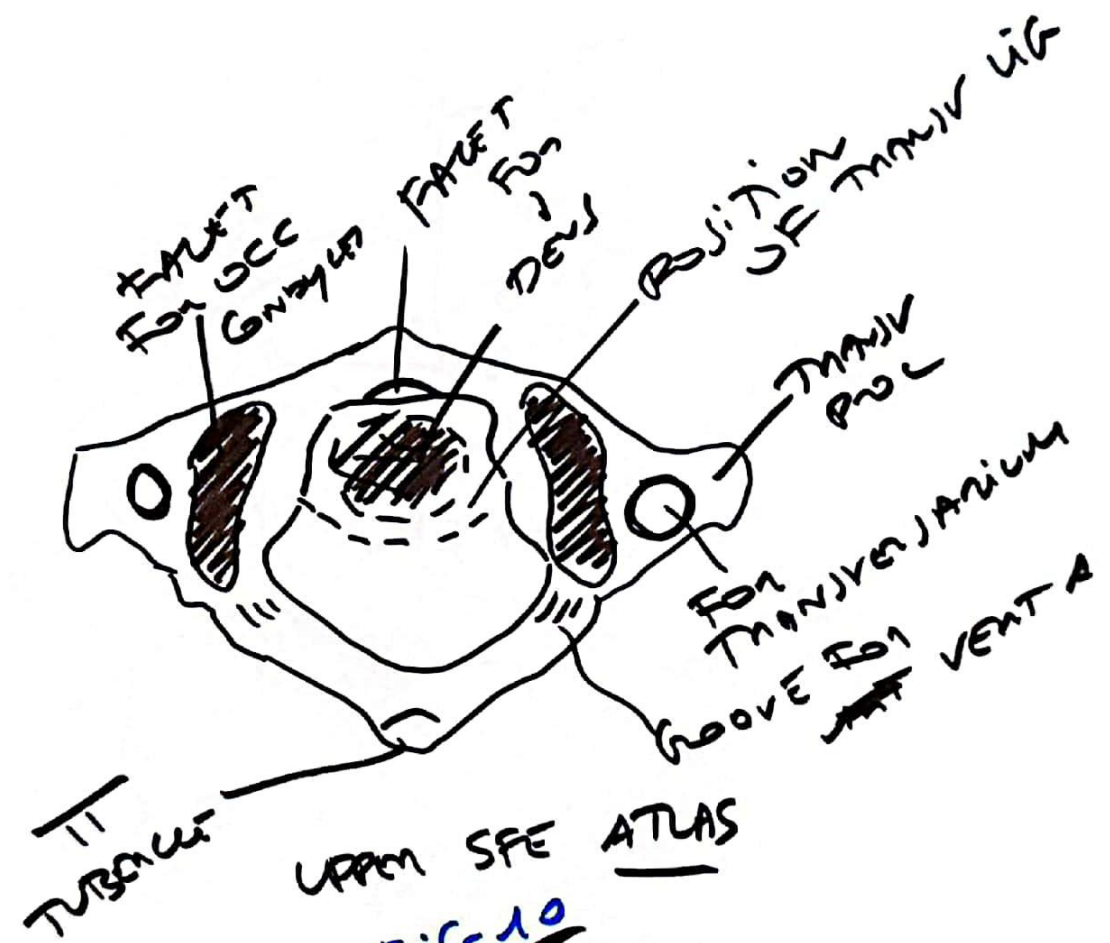


FIG 1

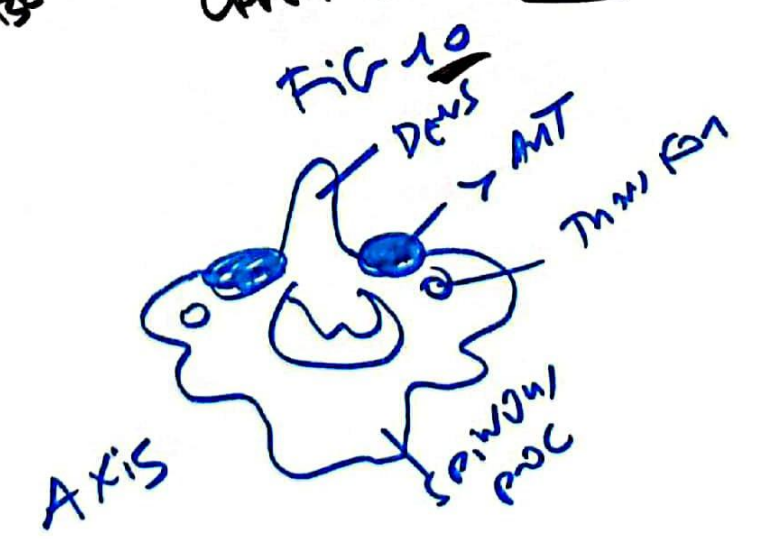

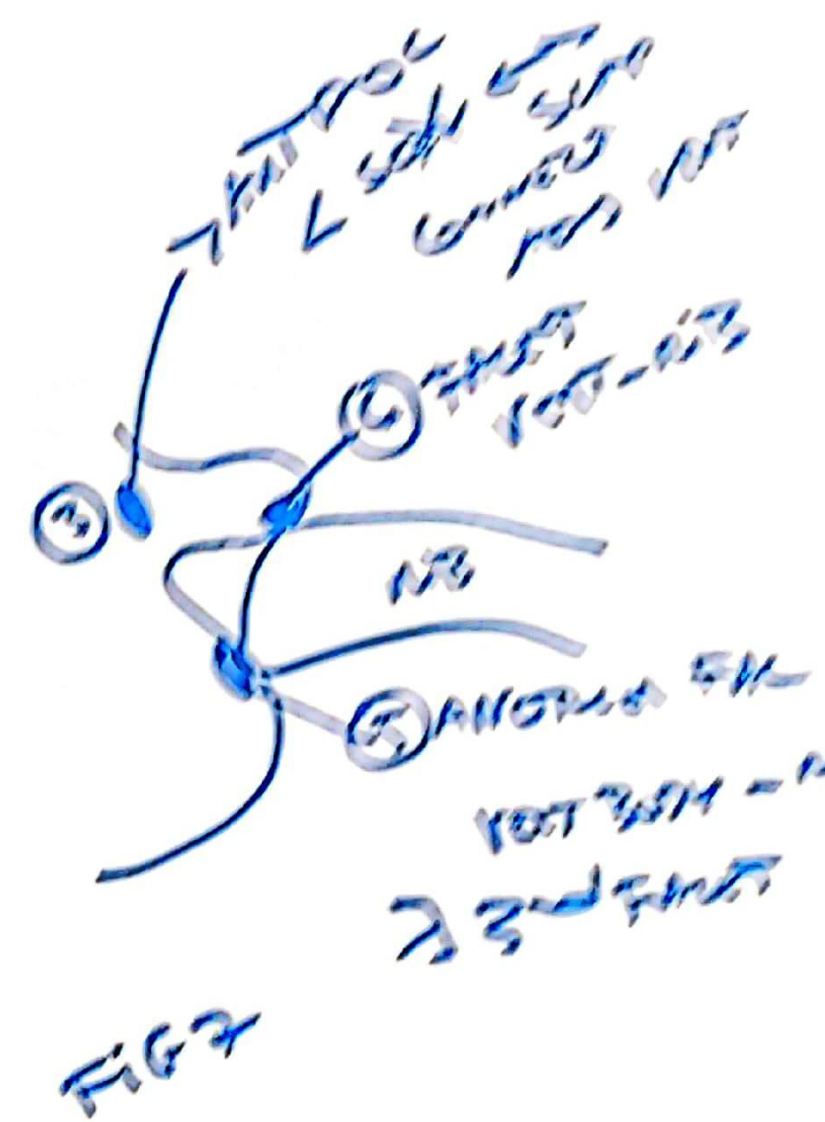
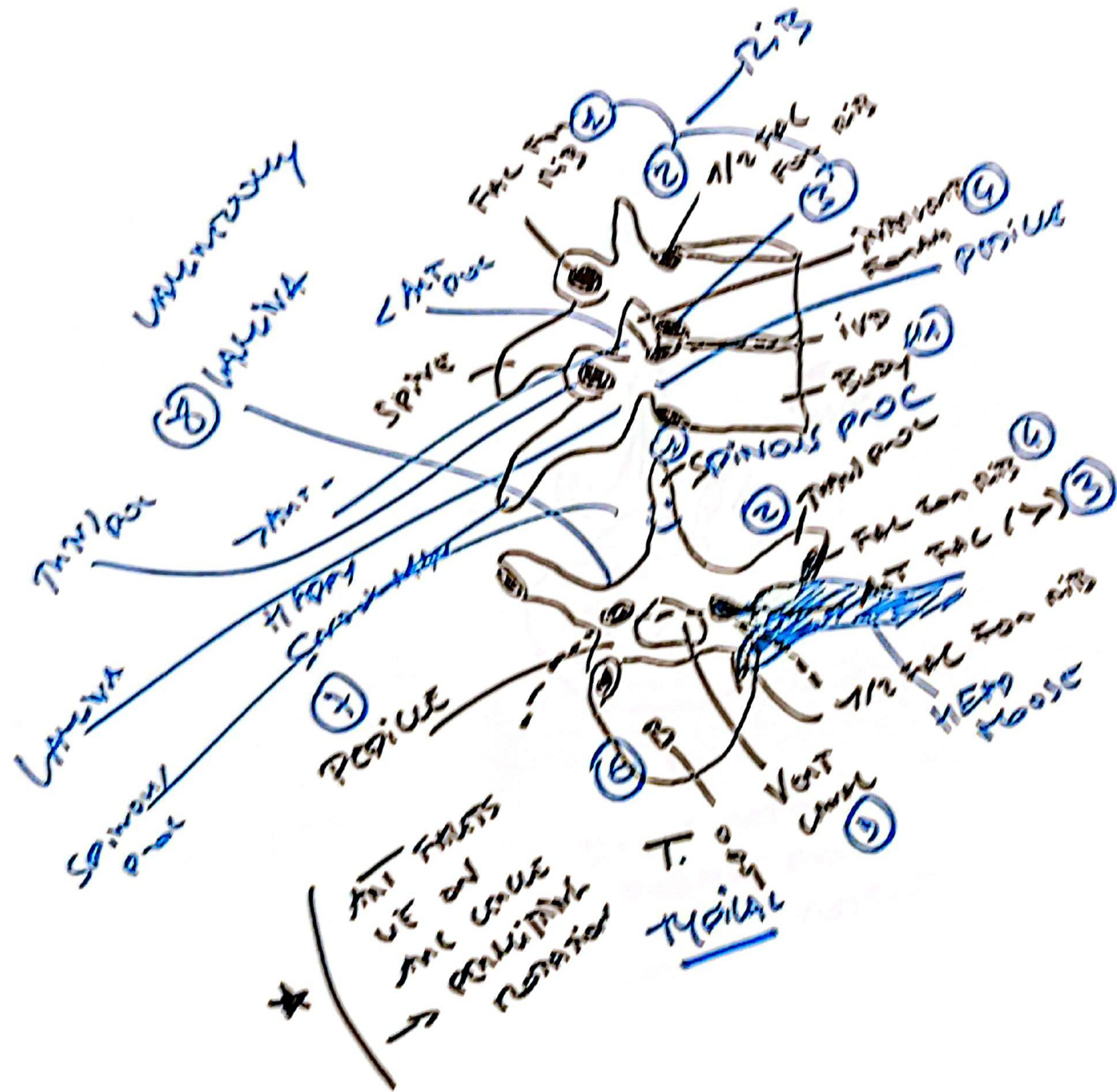
It is considered if  
 this is the  
 primary  
 transverse of






UPPER SFE ATLAS













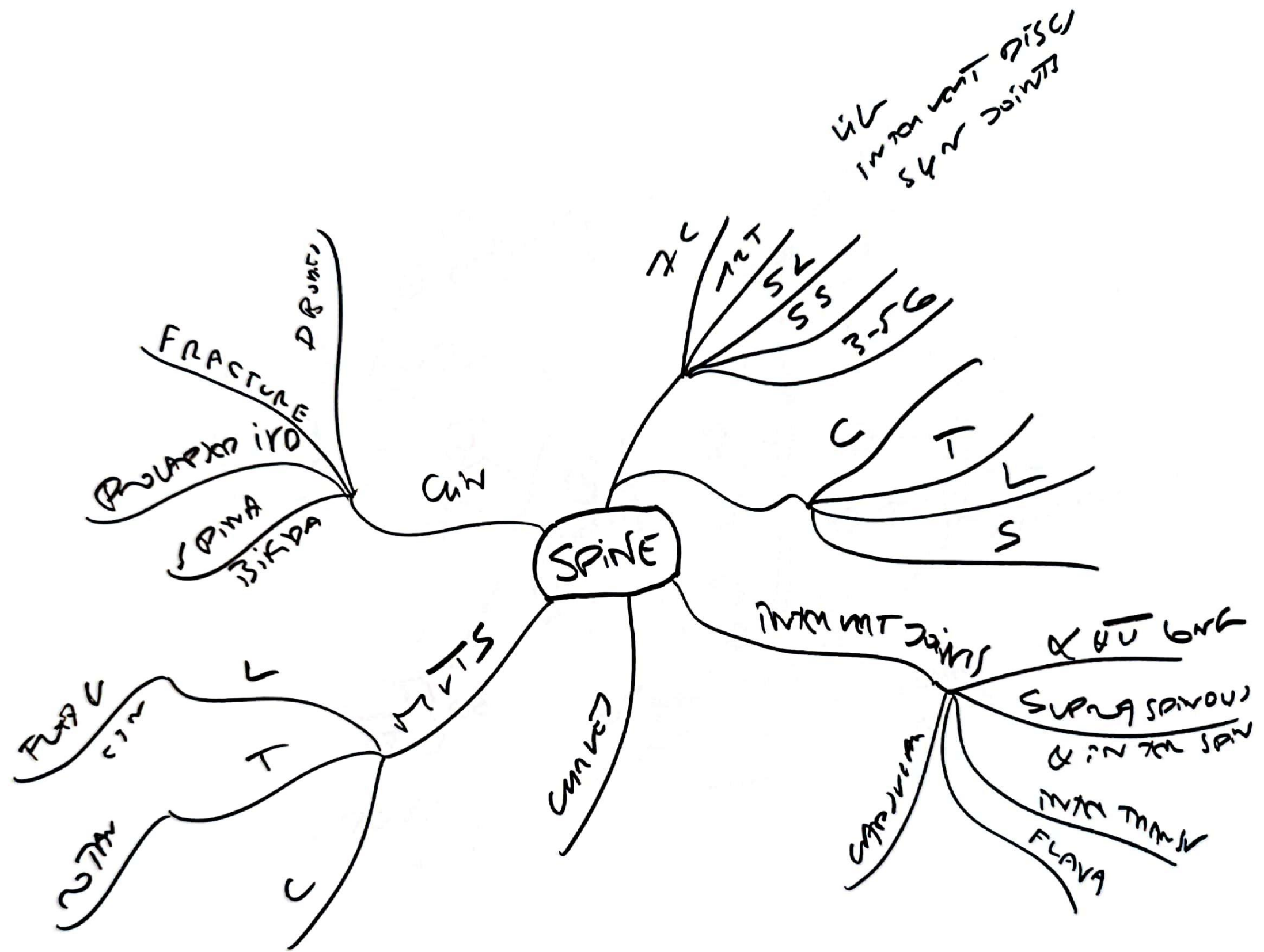


FIG 14  
SACRUM

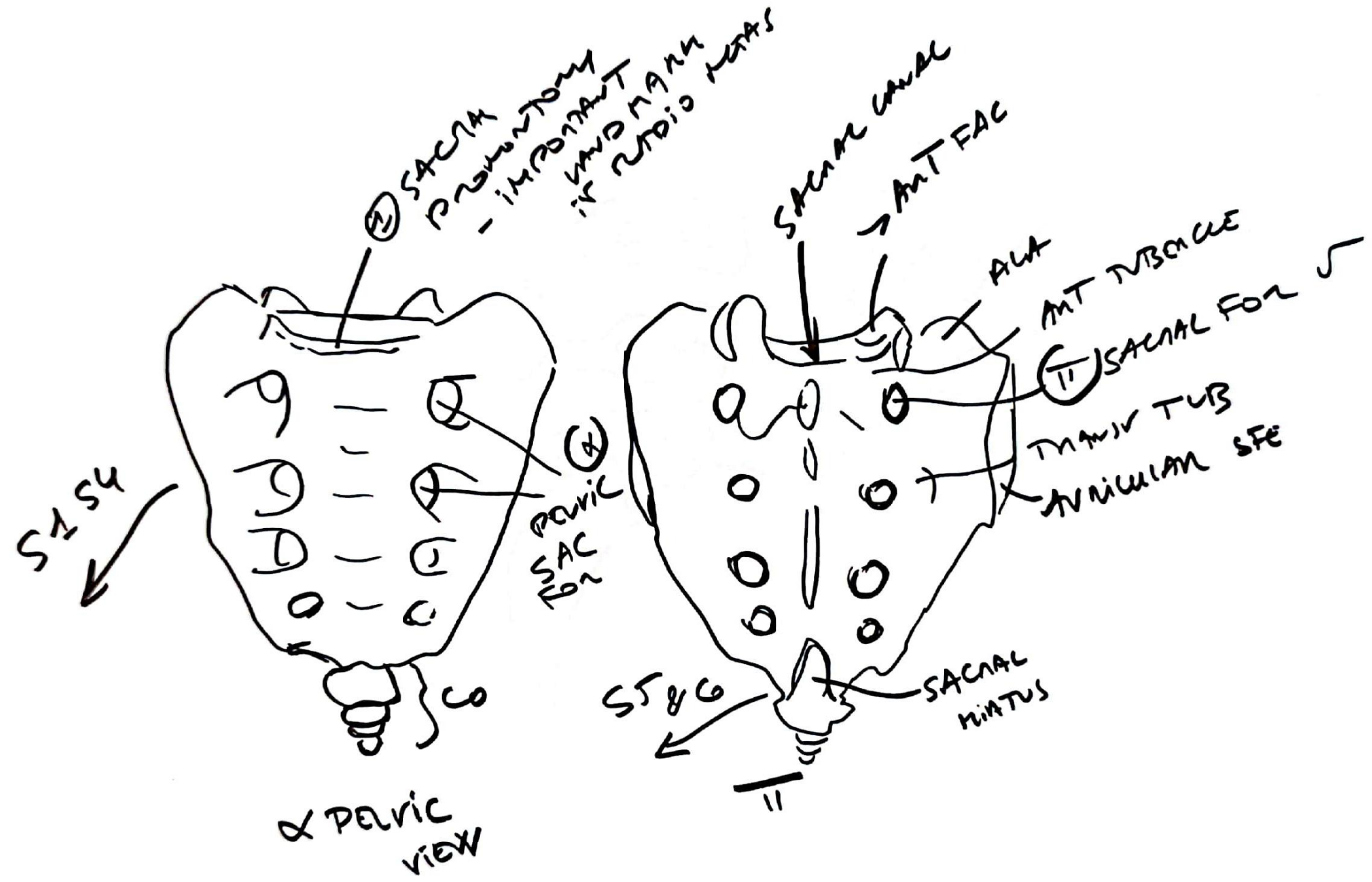
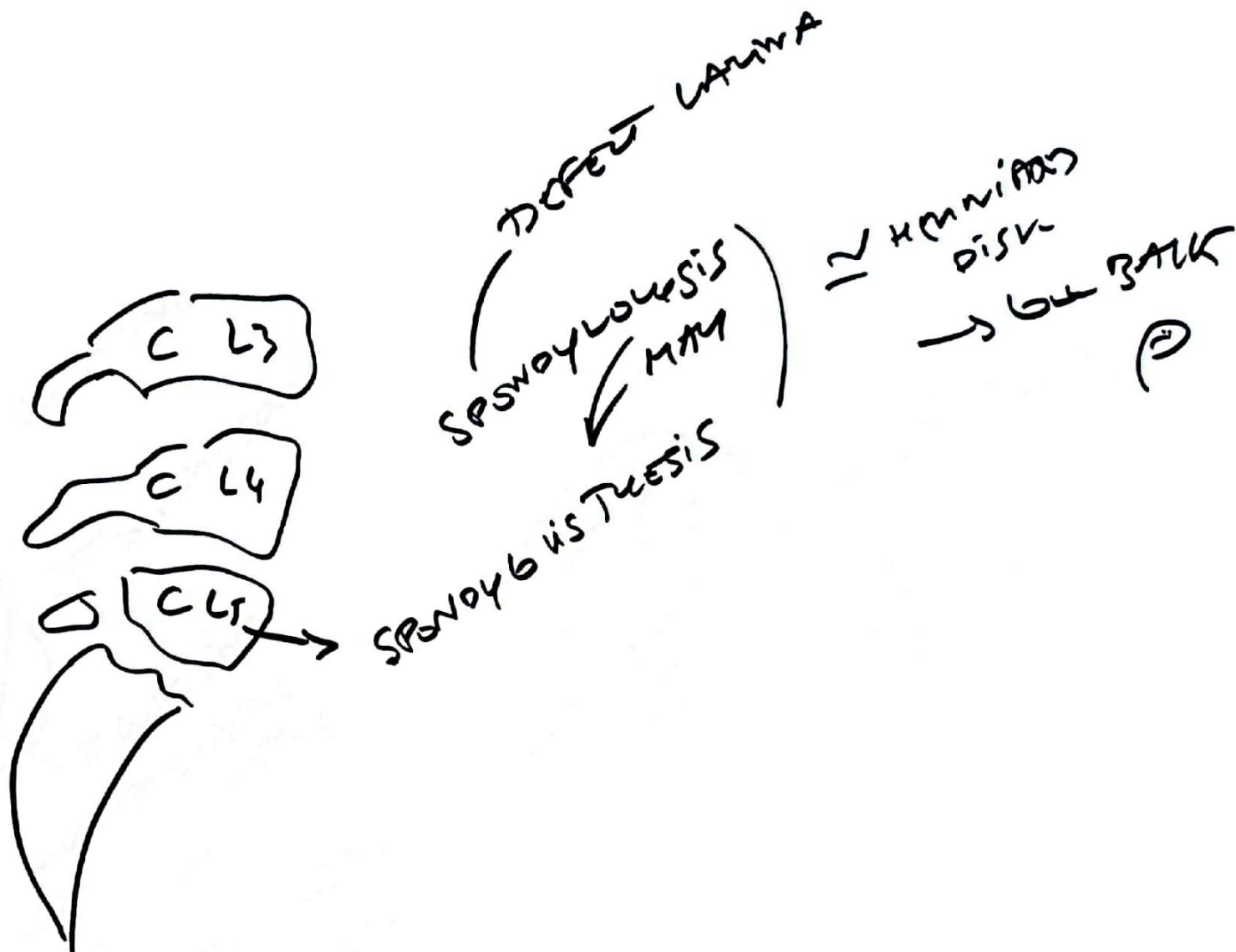




FIG 12



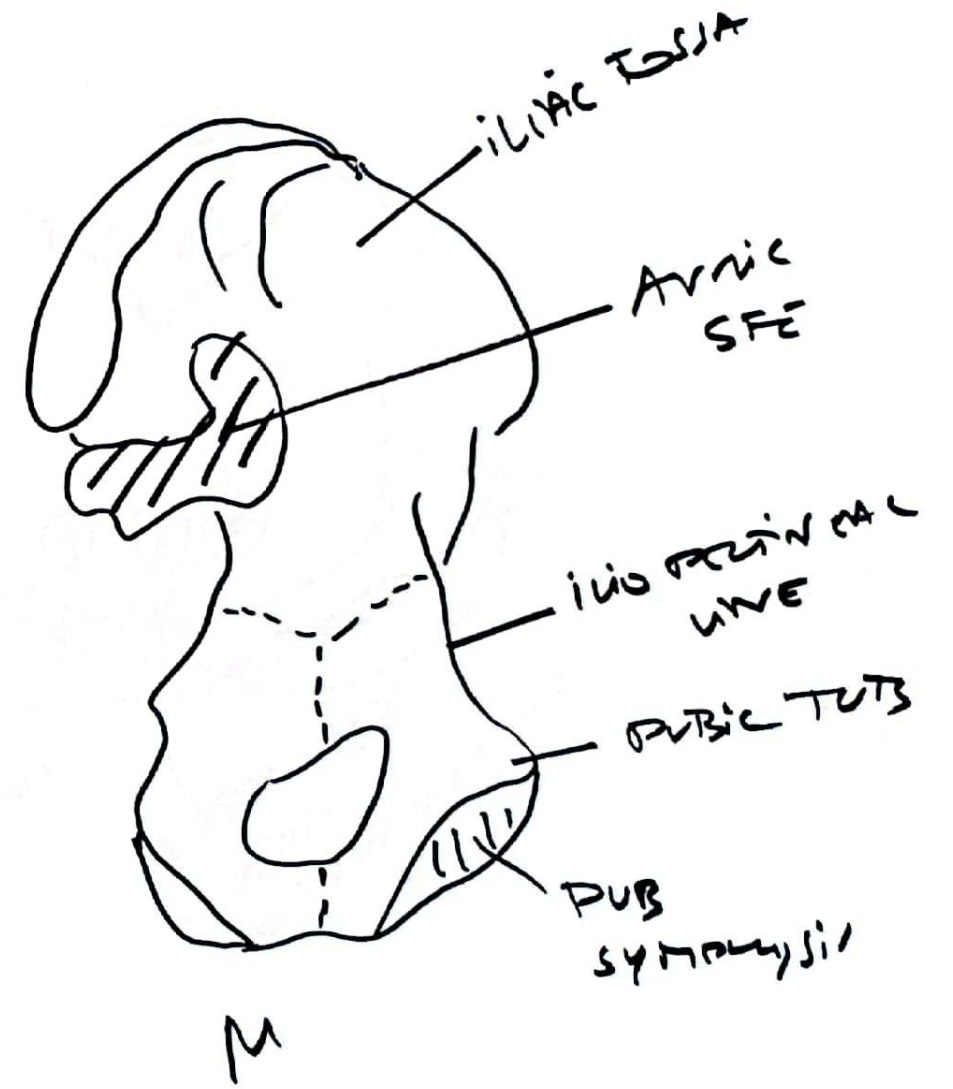
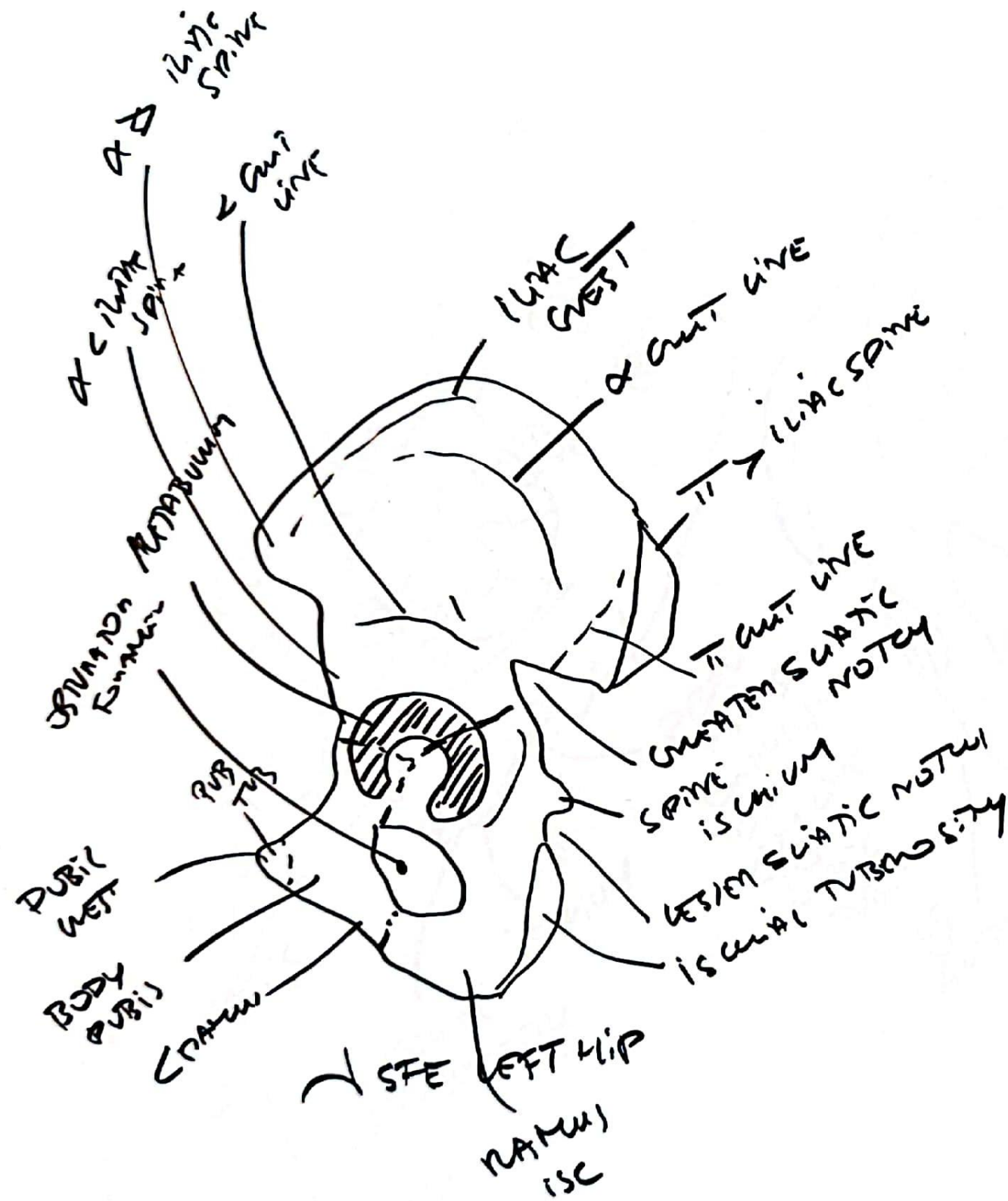
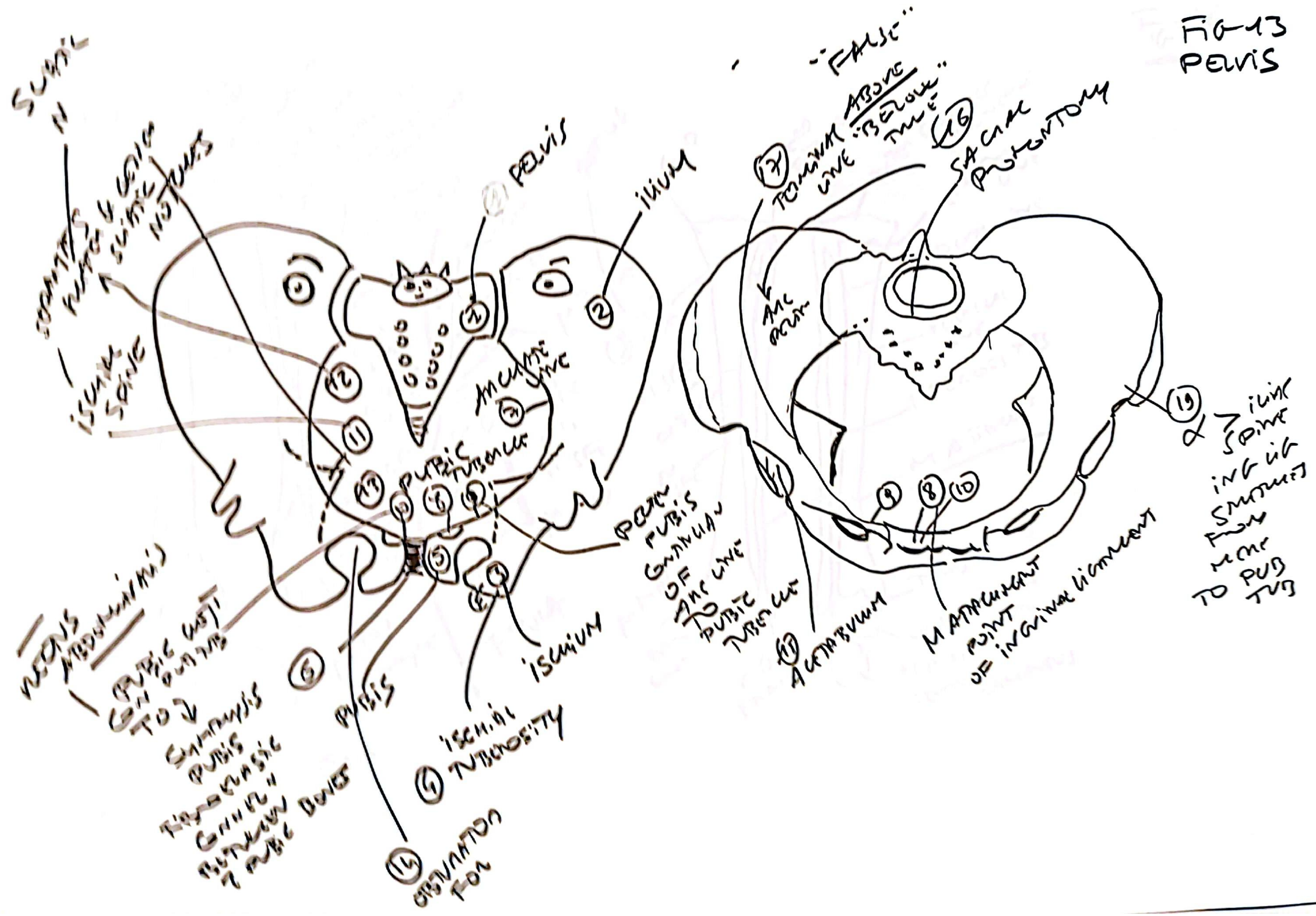




FIG-13  
PELVIS





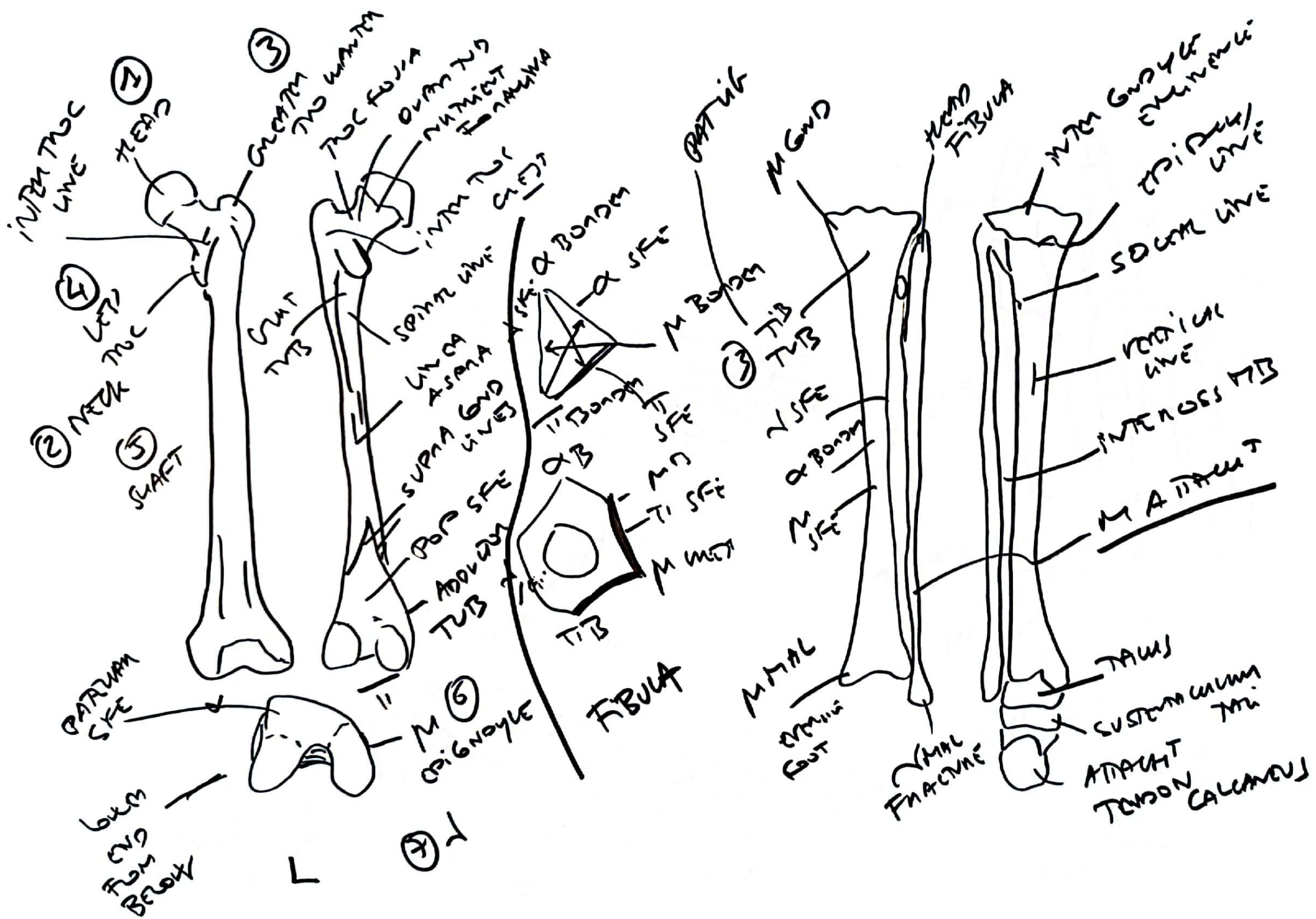


FIG 15  
FOOT

TOE  
HAWK  
VALGUS

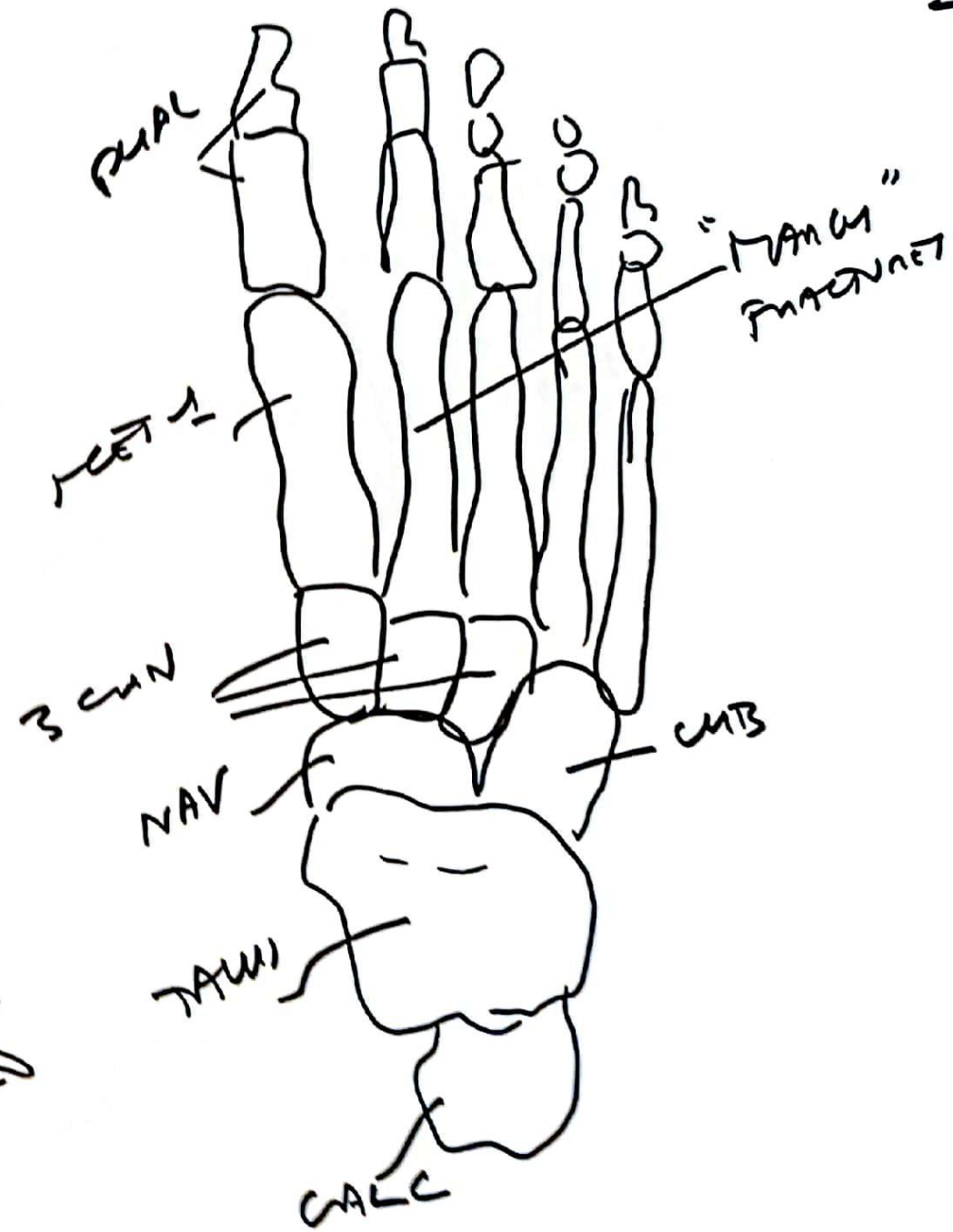
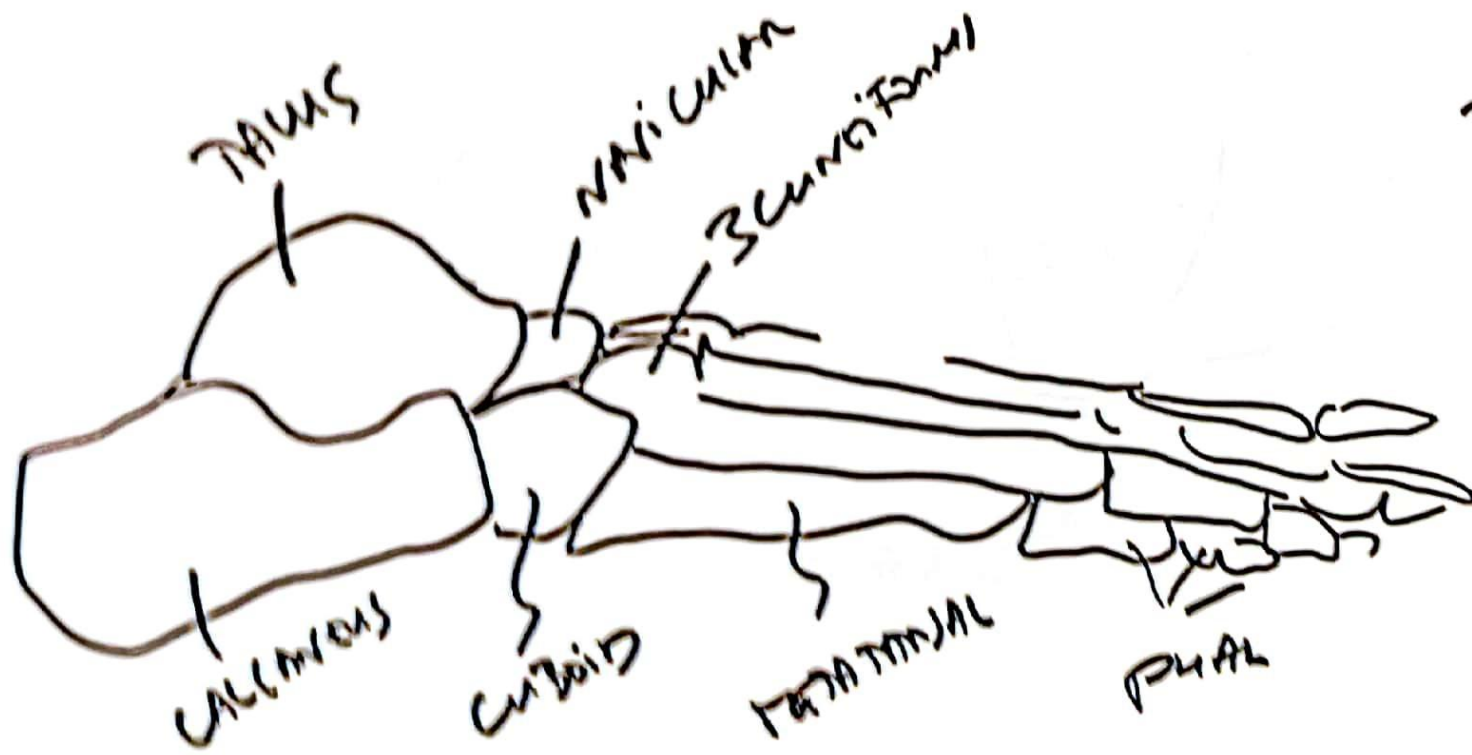
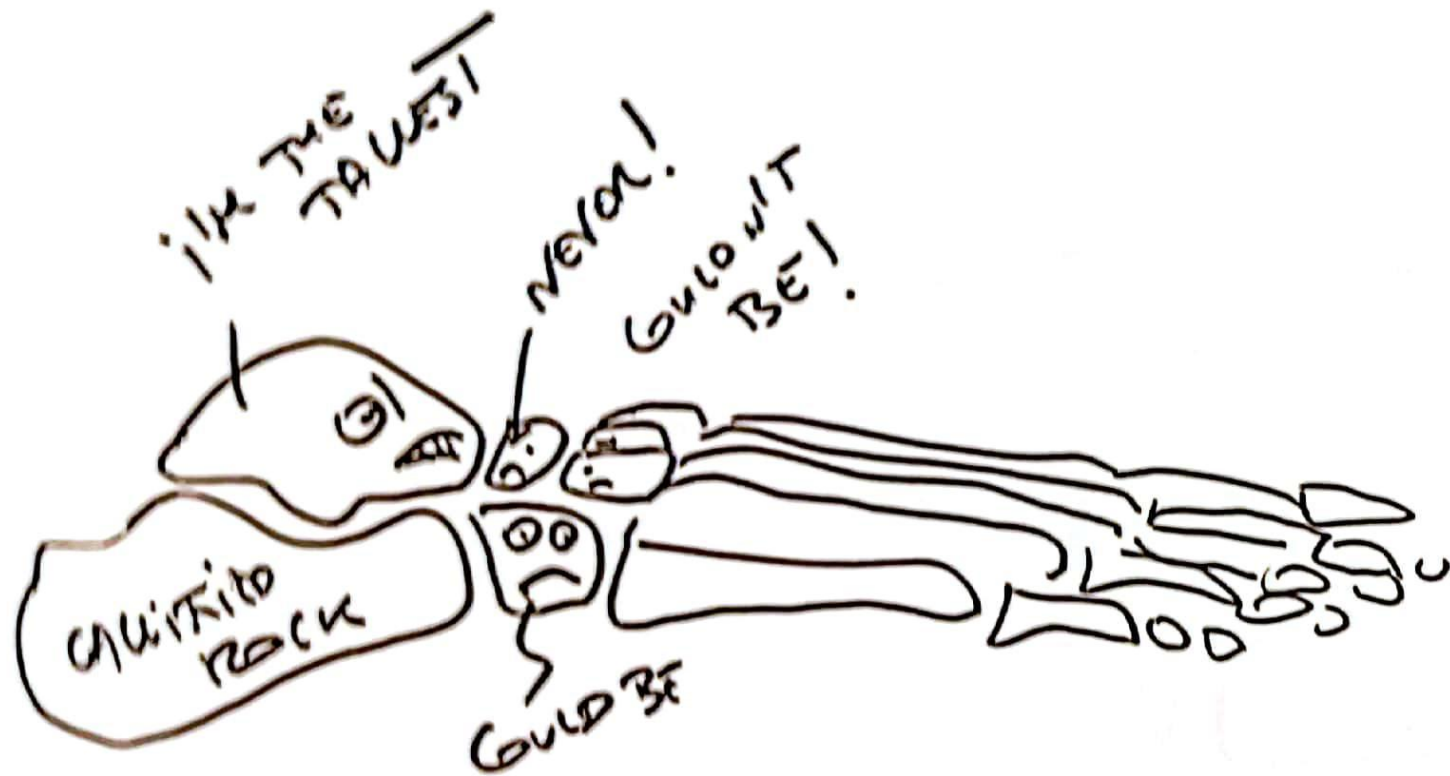
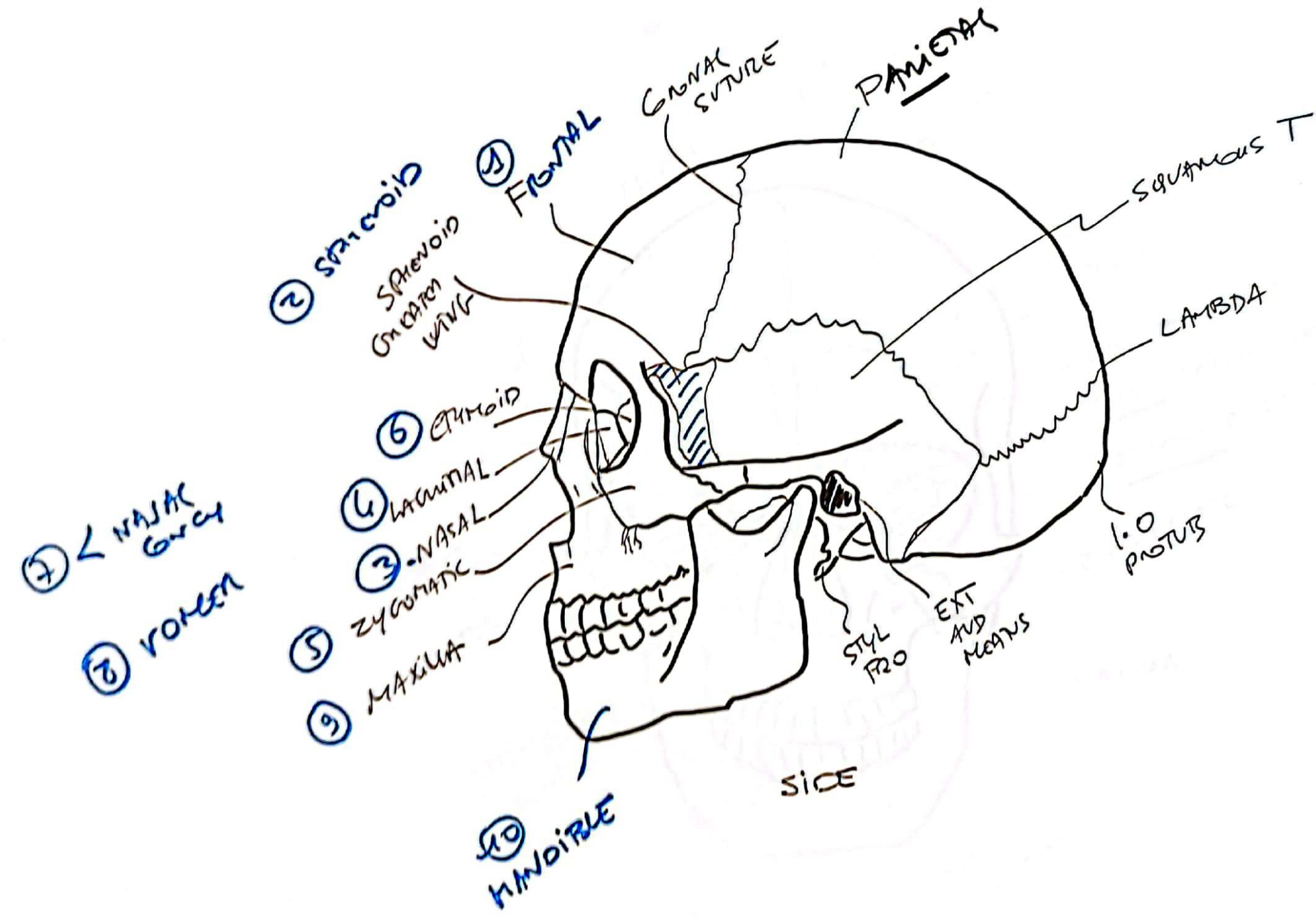
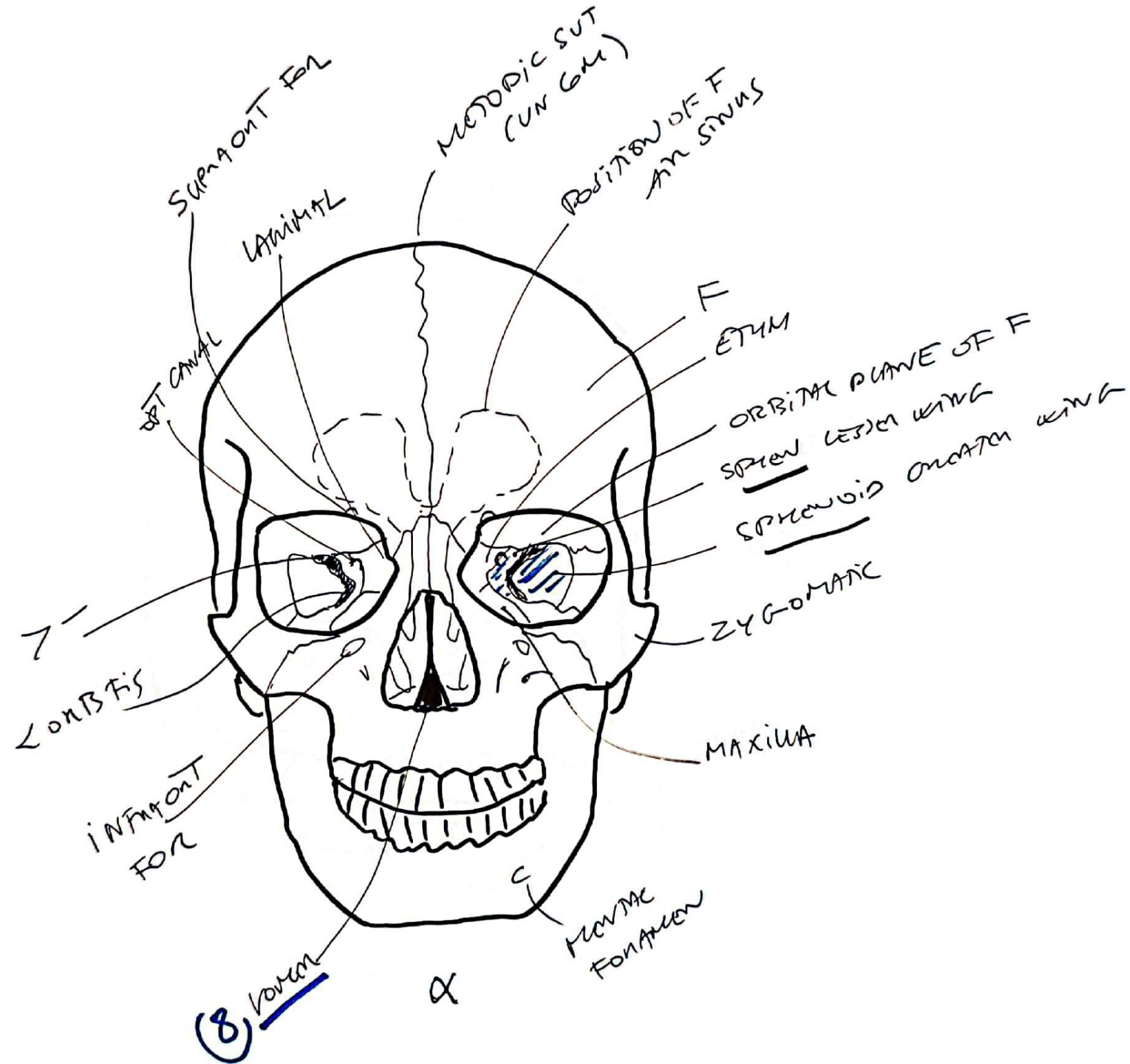
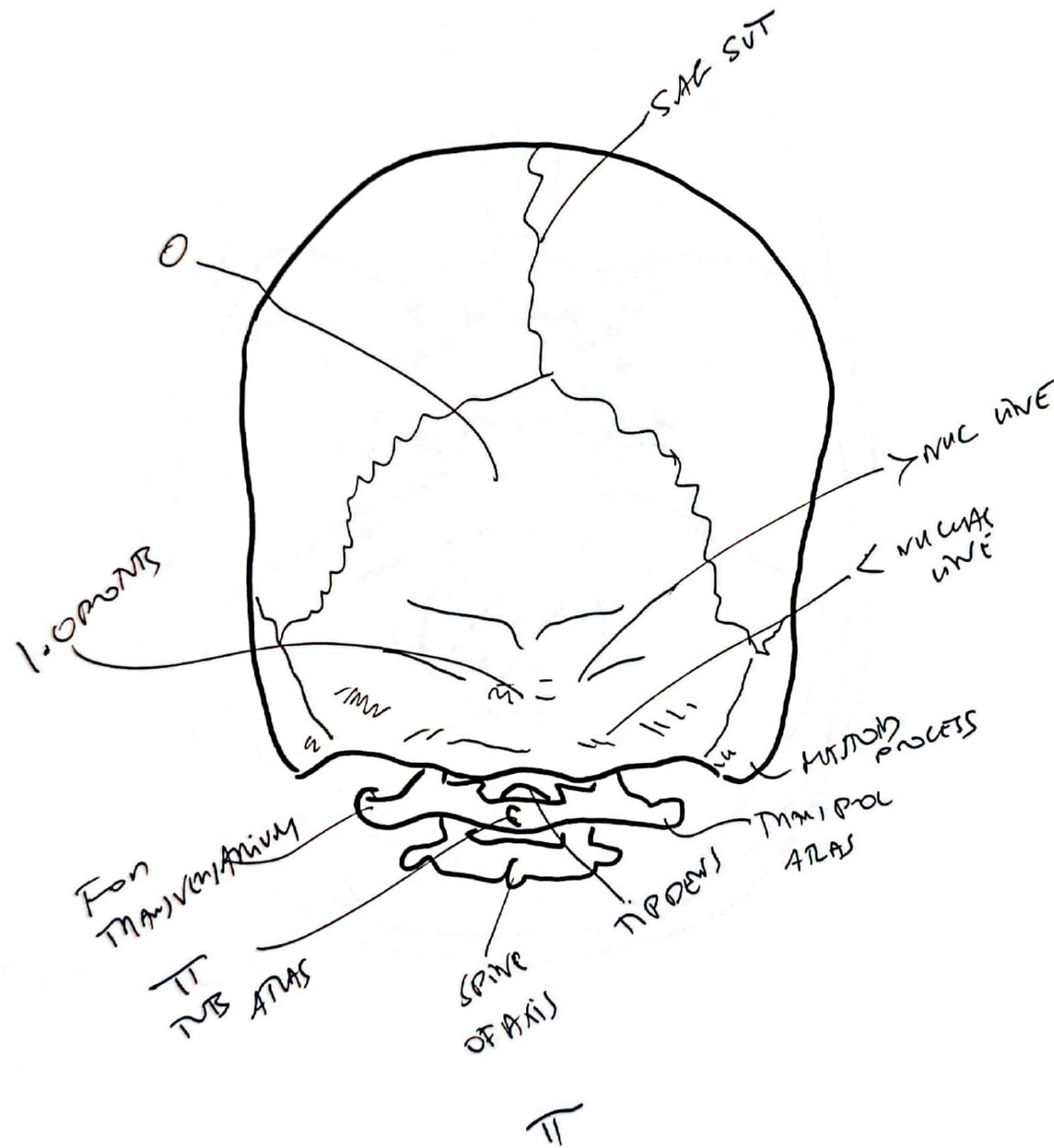




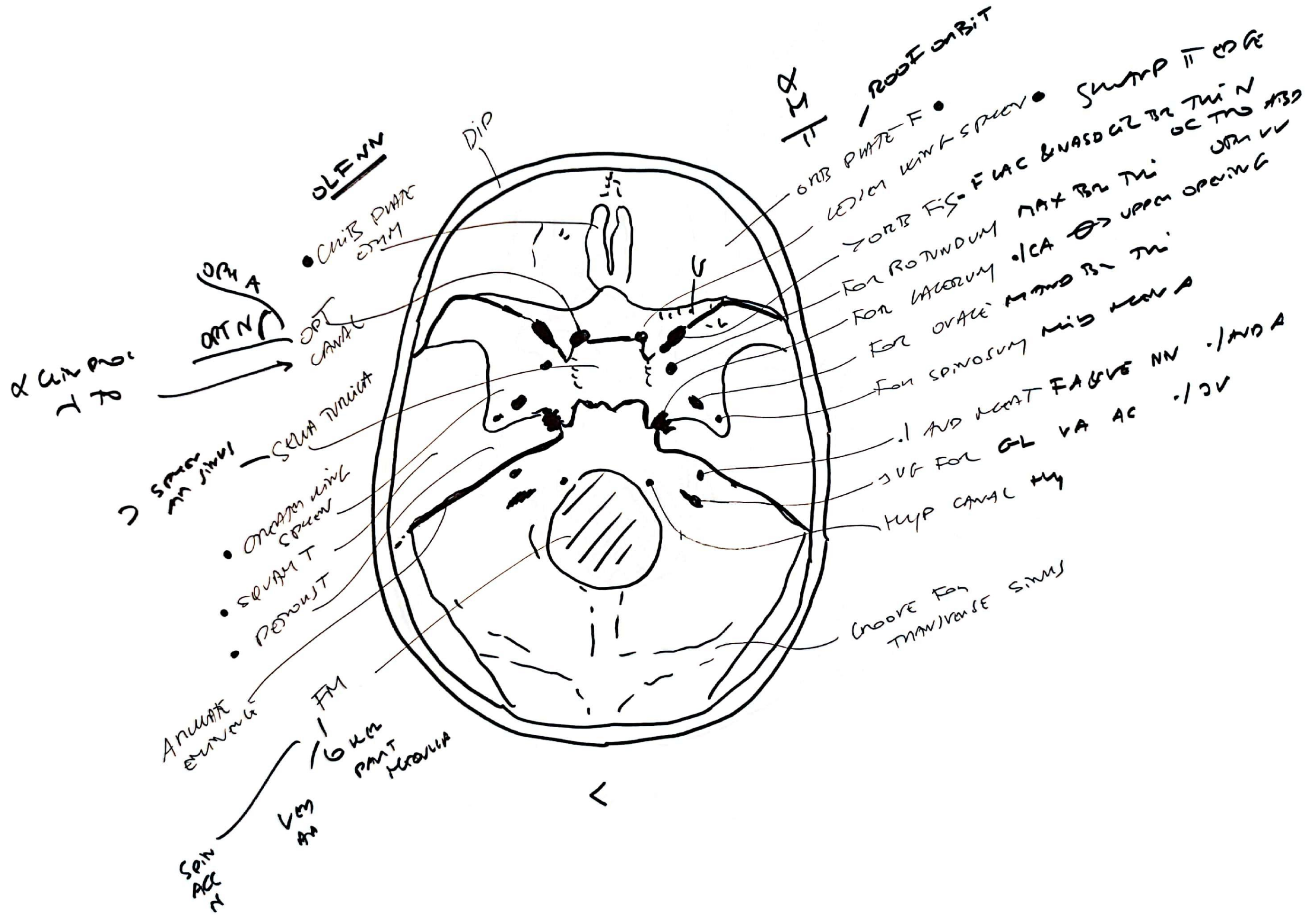
FIG 17  
CRANIAL  
BONES

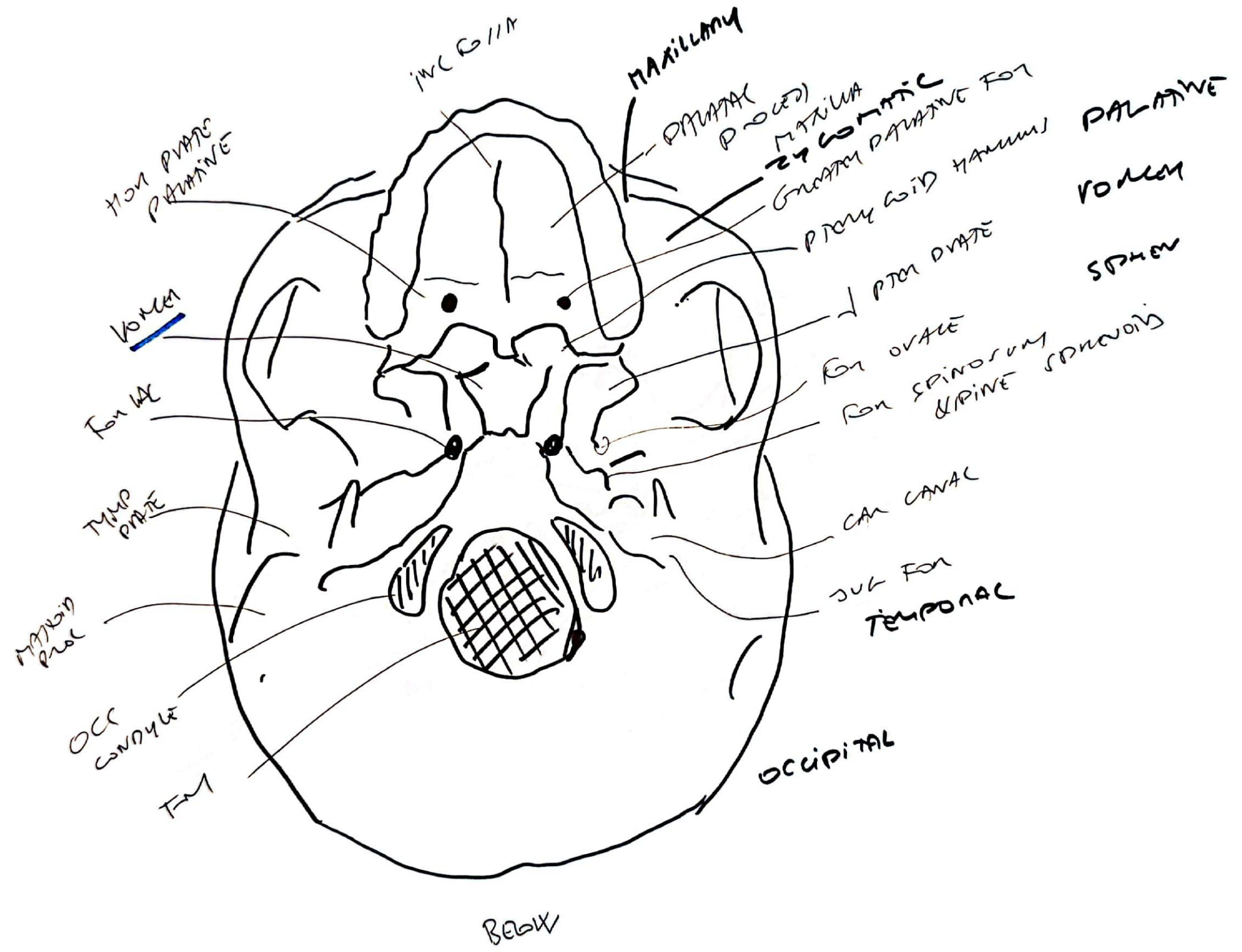


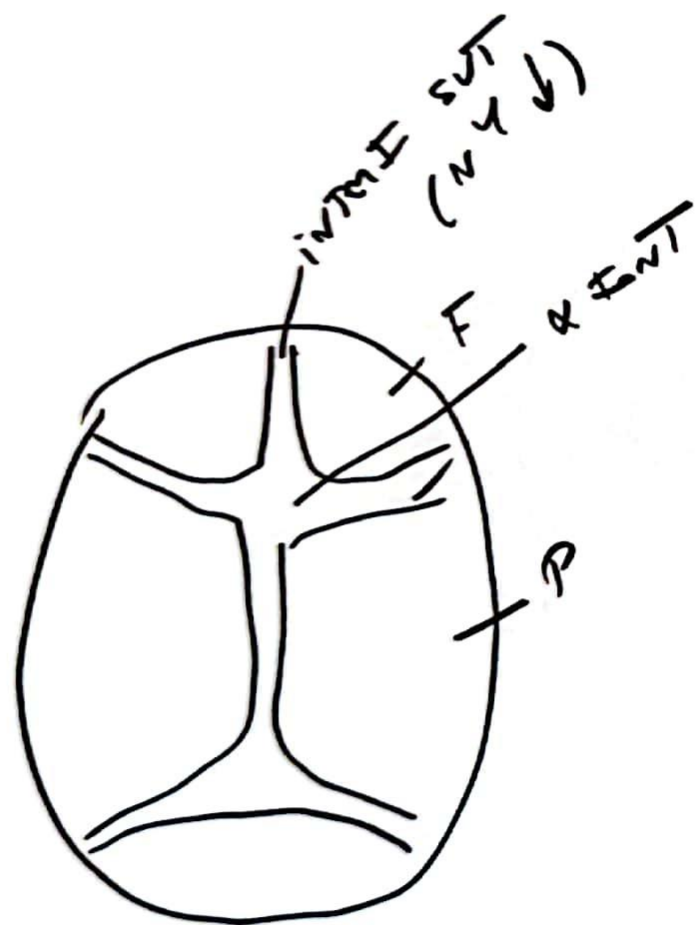




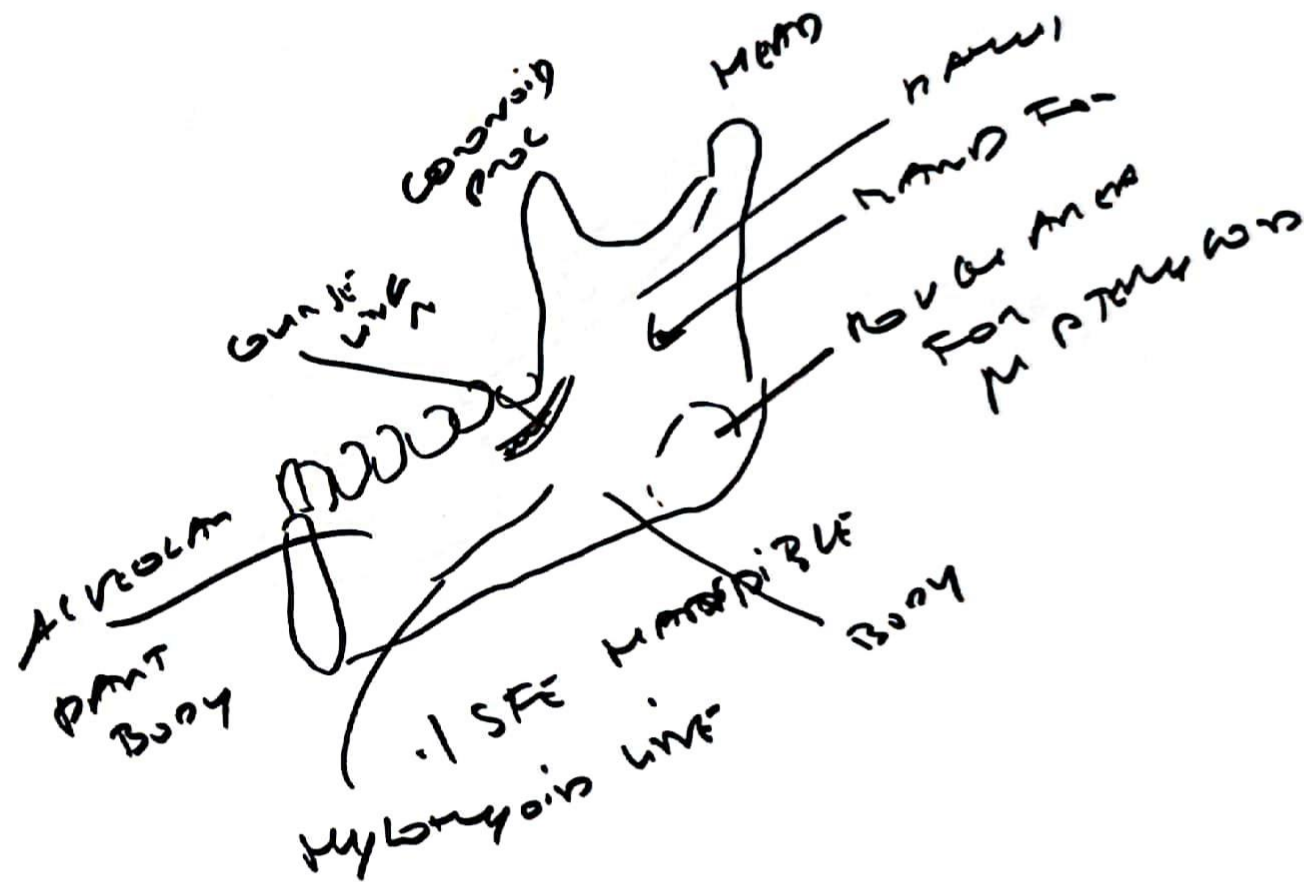




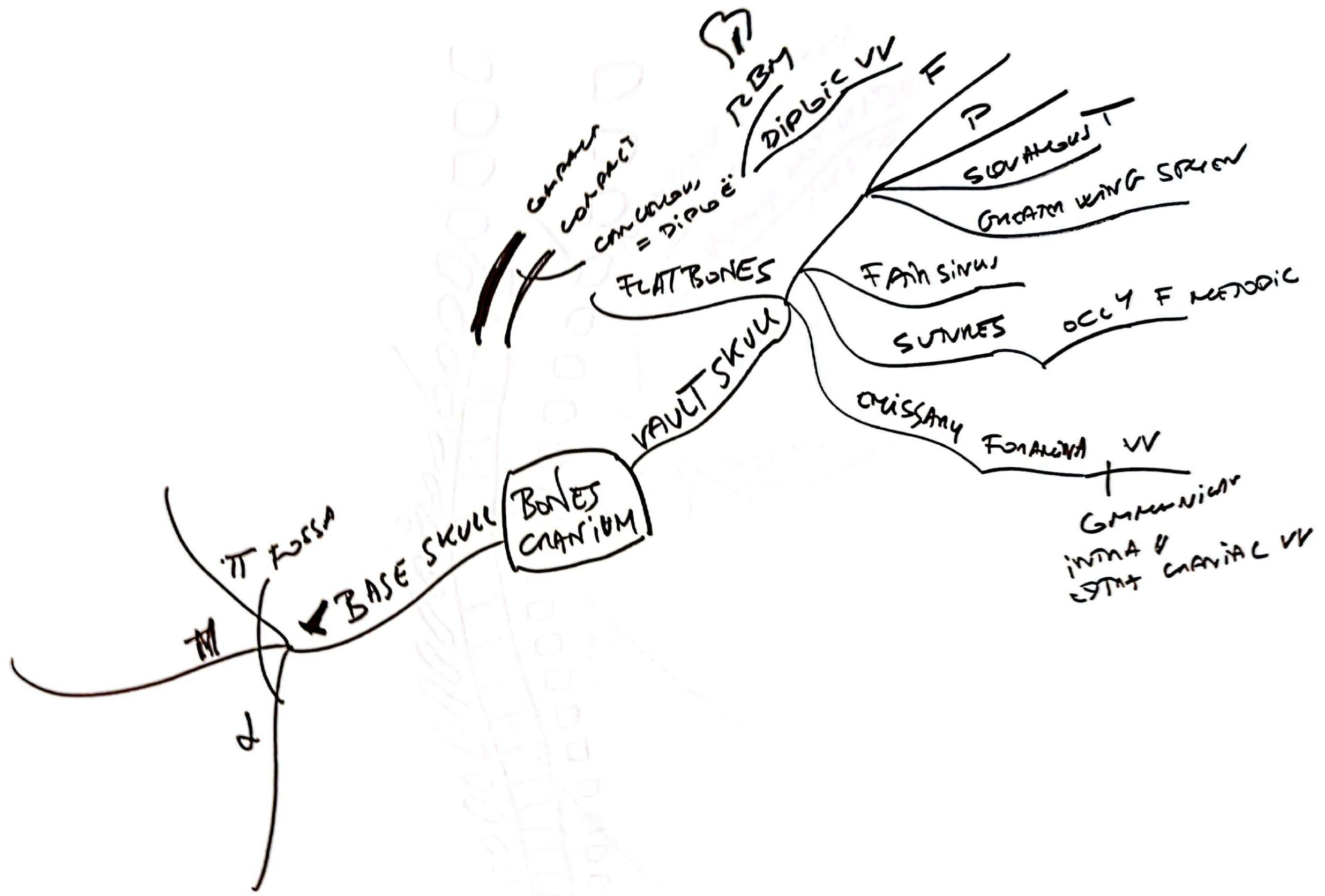


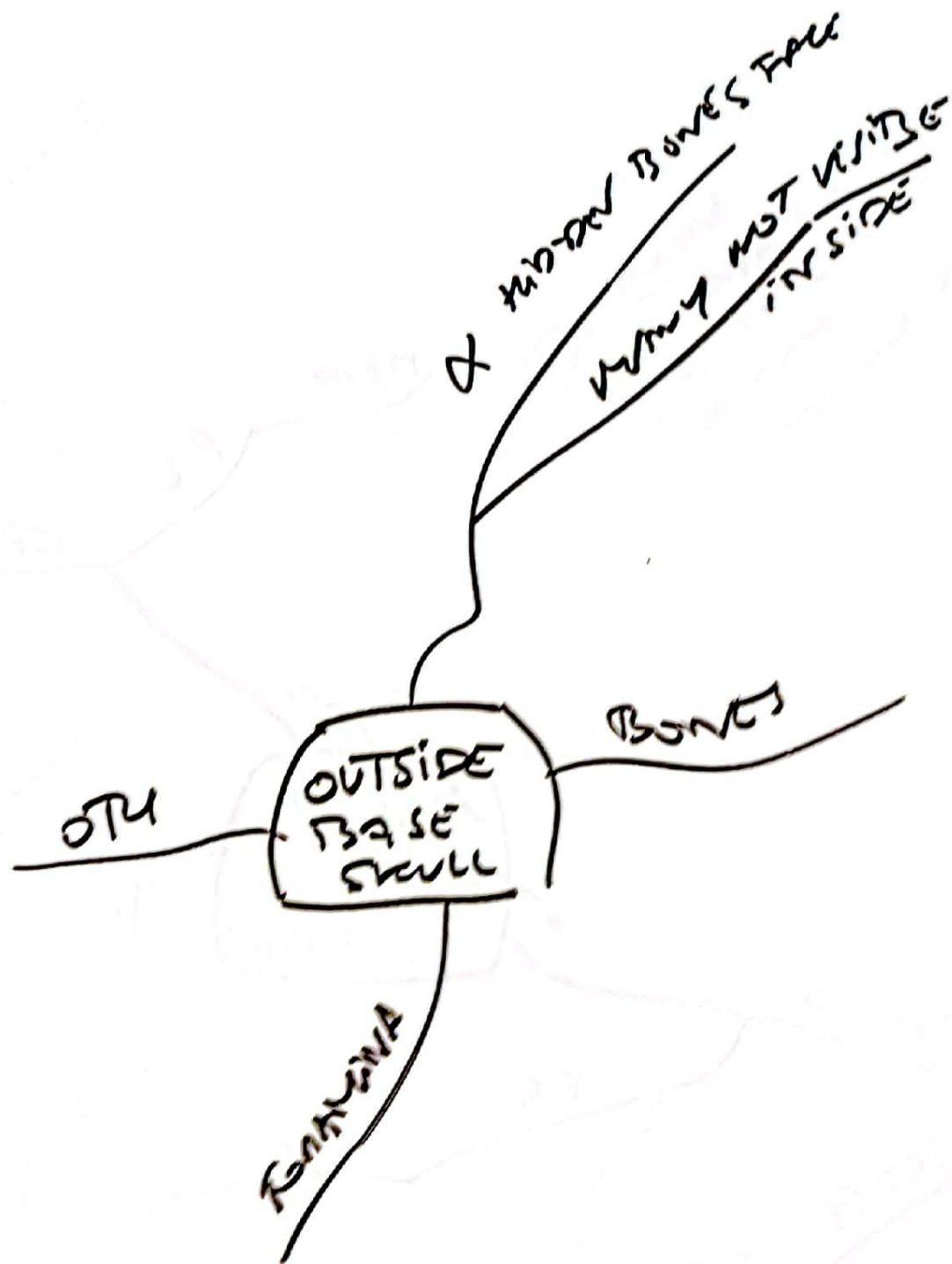


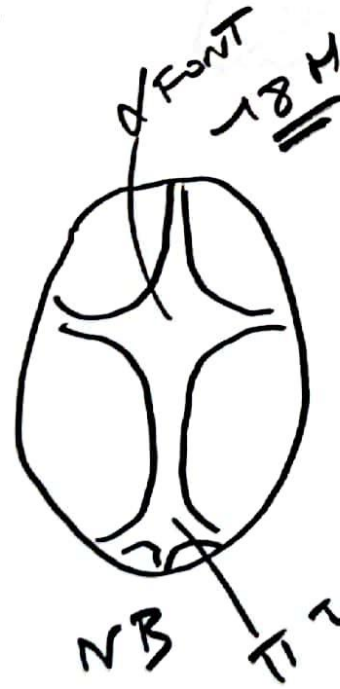

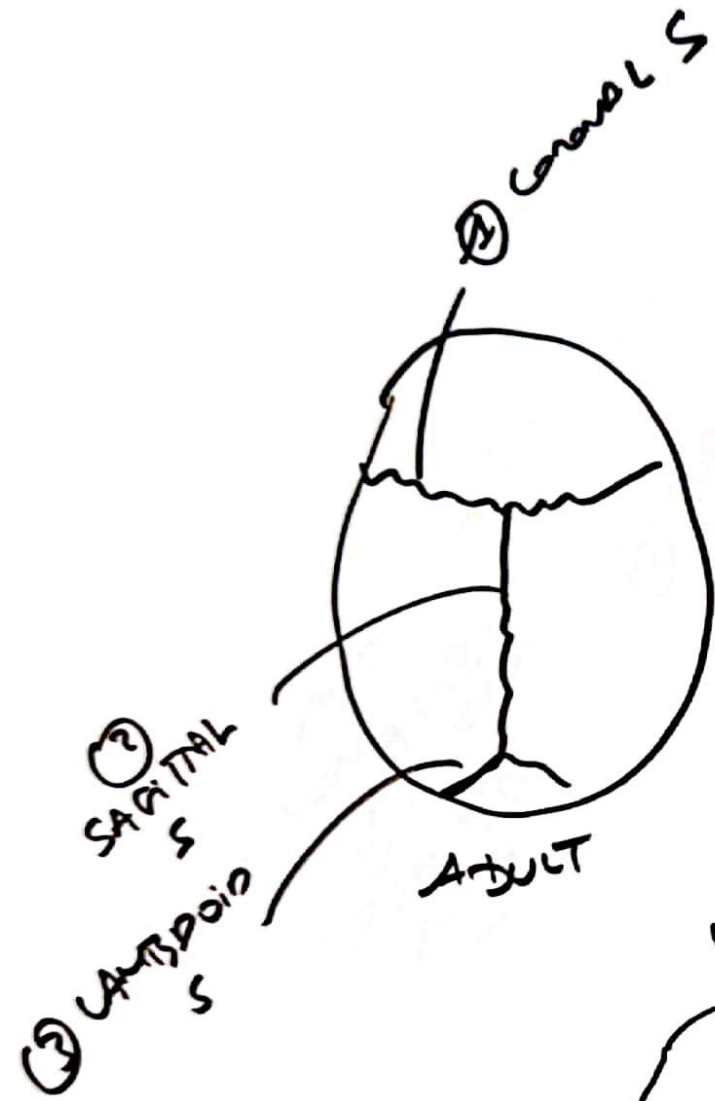
FLY  
ABDOMEN











20/ES  
 BY 24 AD

FIG 18  
 SUNNET  
 SKULL



FIG 18  
FRONTAL  
BONE

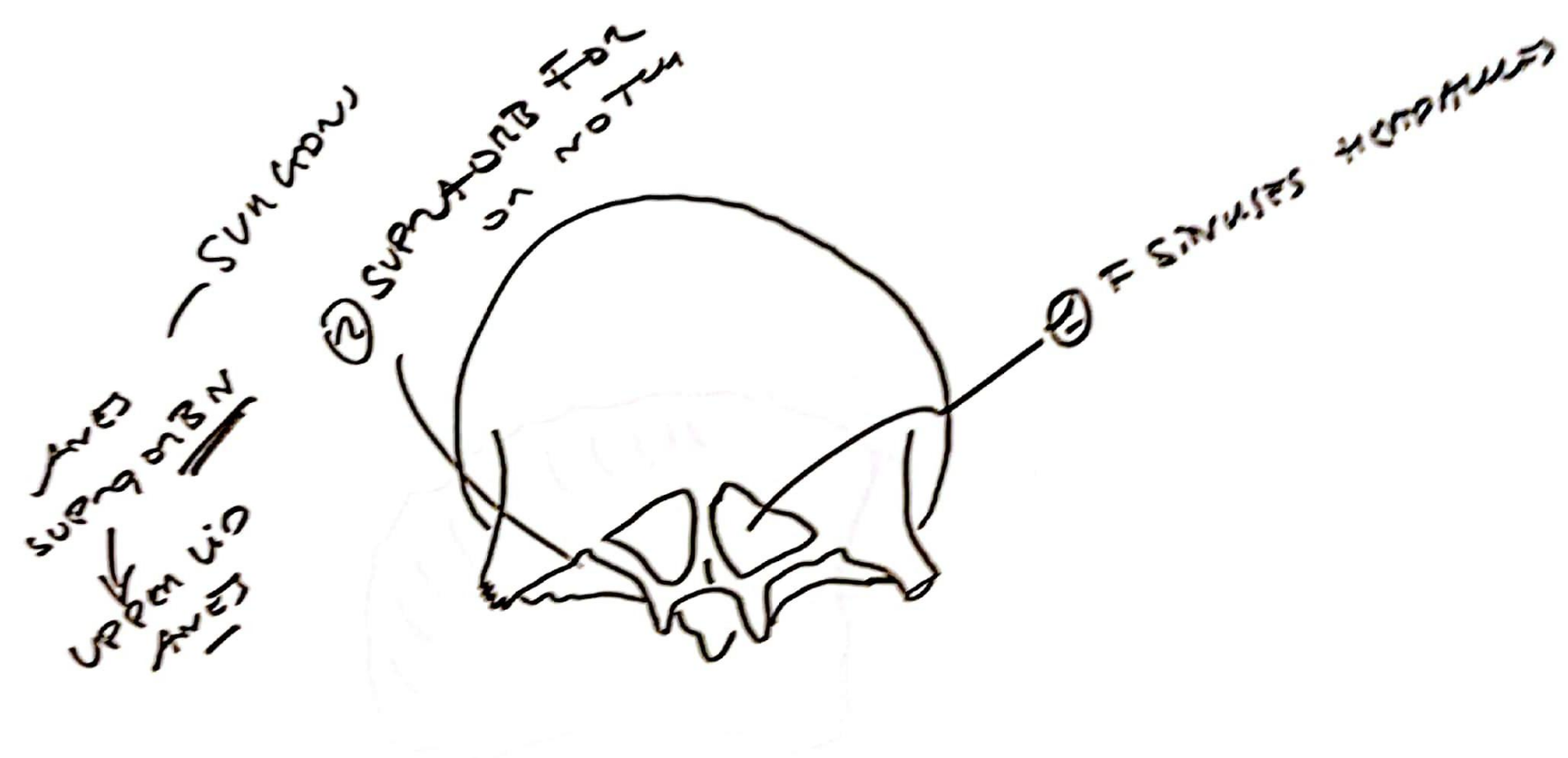


FIG-20  
PANORAMIC  
R  
VIEW




Fig-24  
Craniofacial  
skeleton

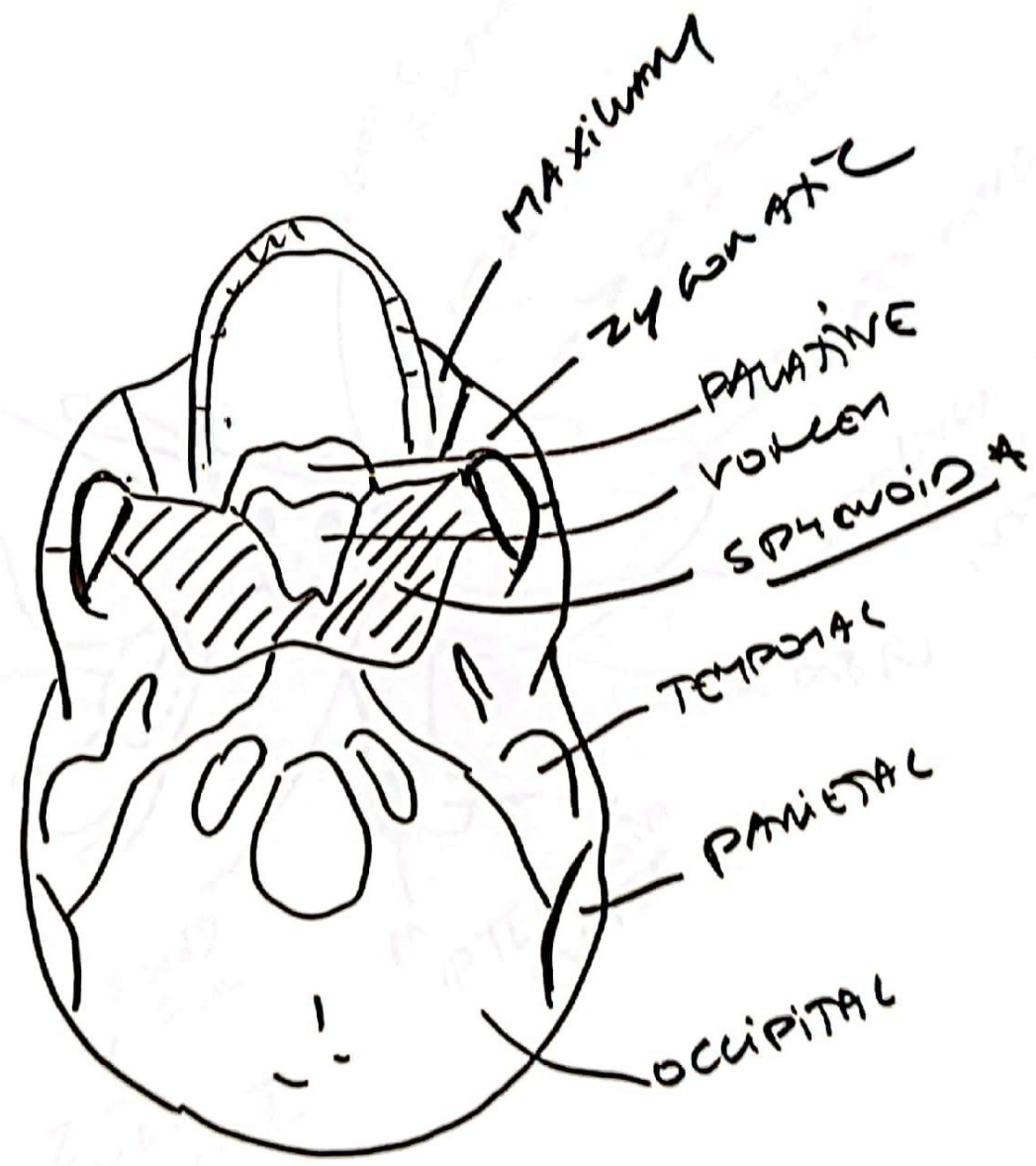
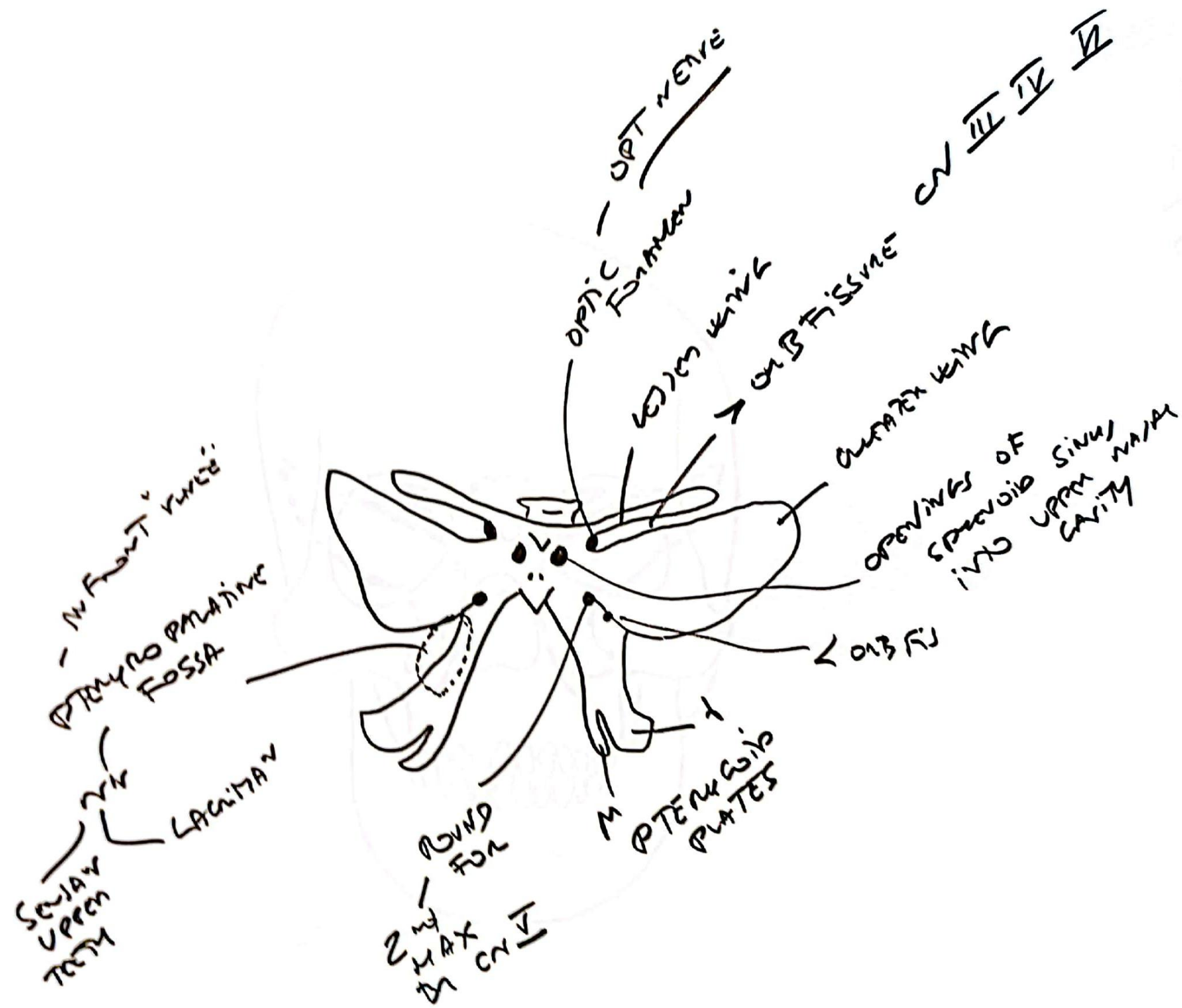




FIG 21  
Sphenoid  
& view



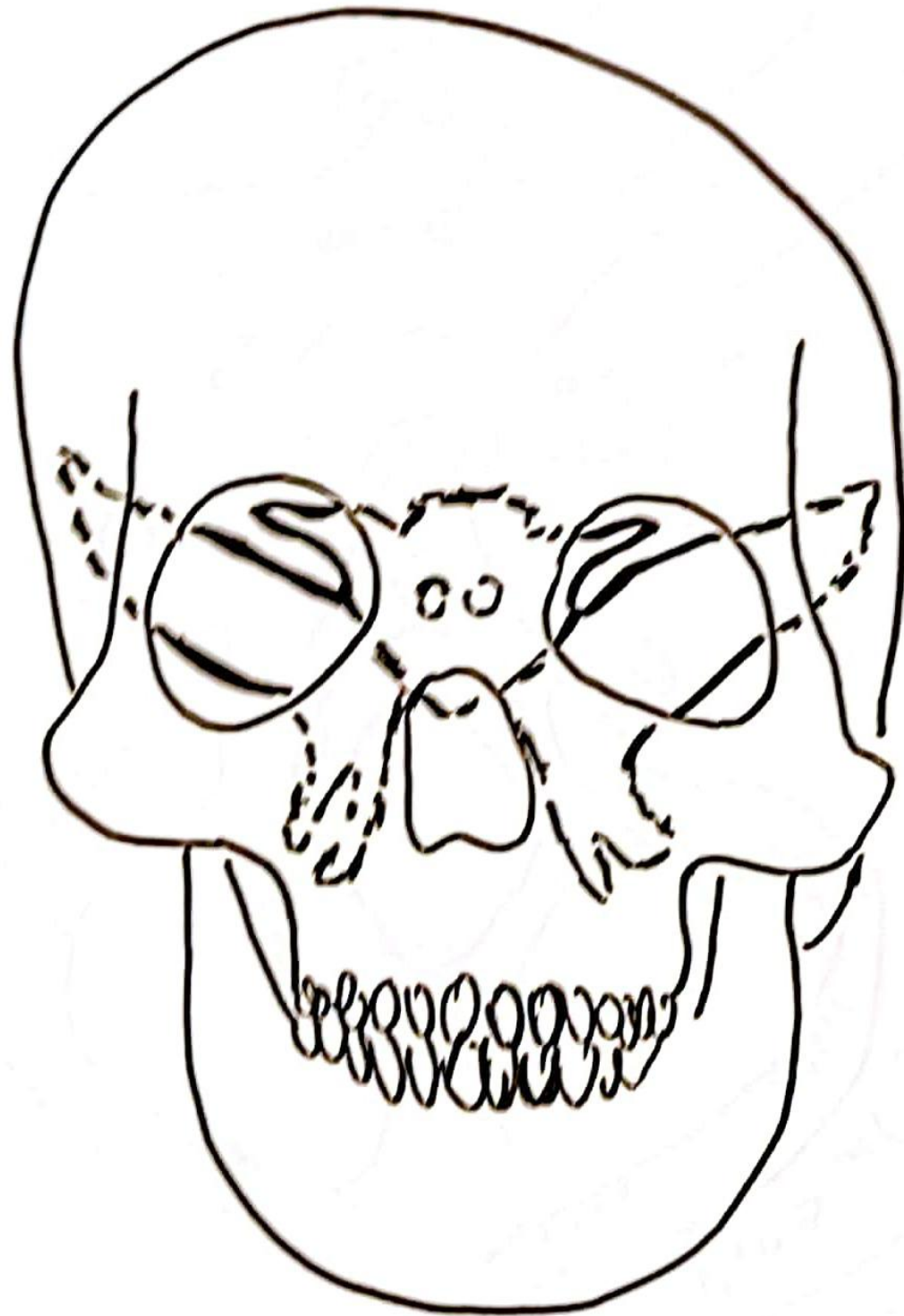


FIG-22  
SPHENOID  
IN RELATION  
AGAINST  
OTHER  
SKULL BONES  
& VIEW

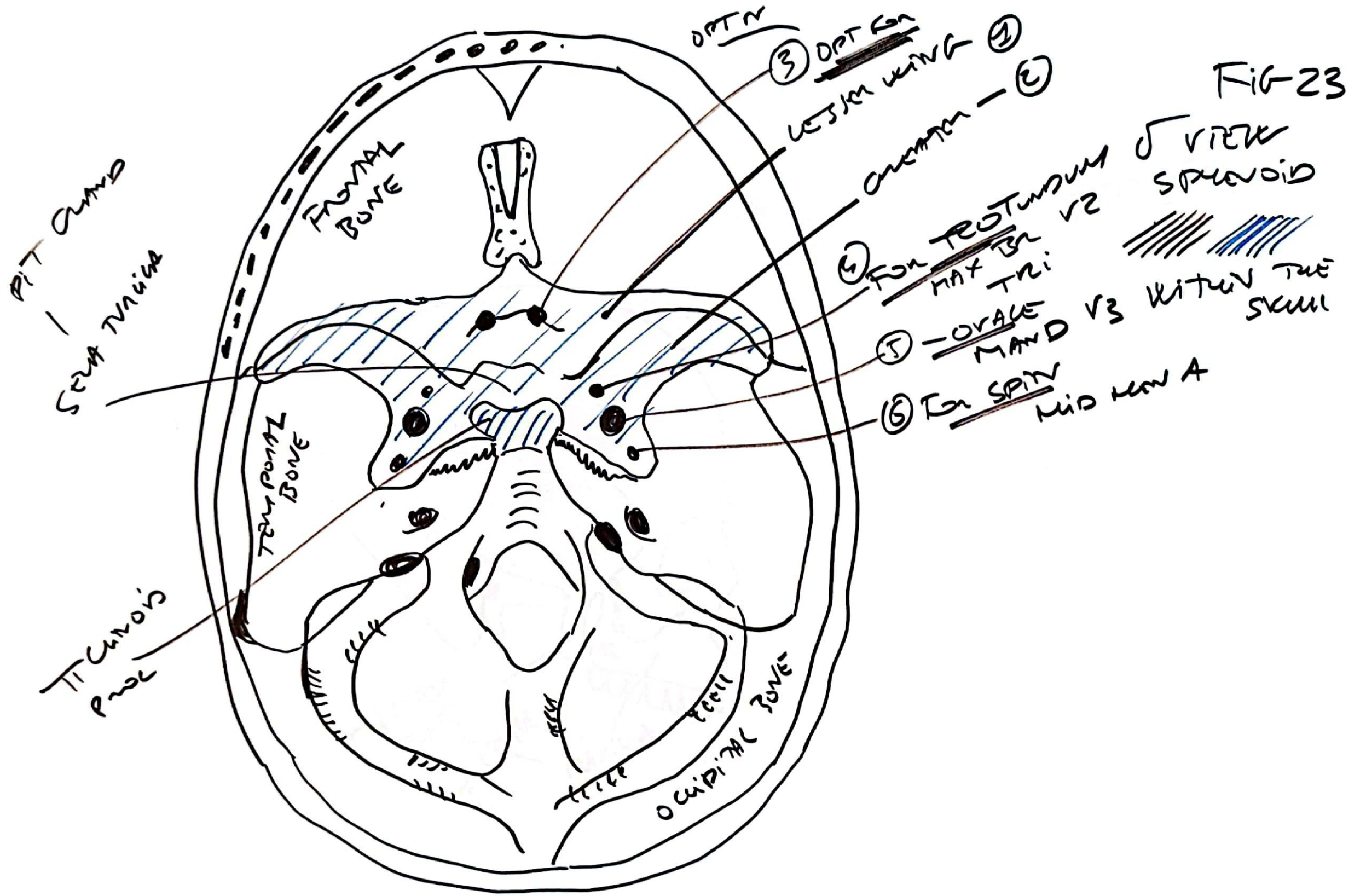




FIG-26

PTERYGOMAXILLARY  
FUSION

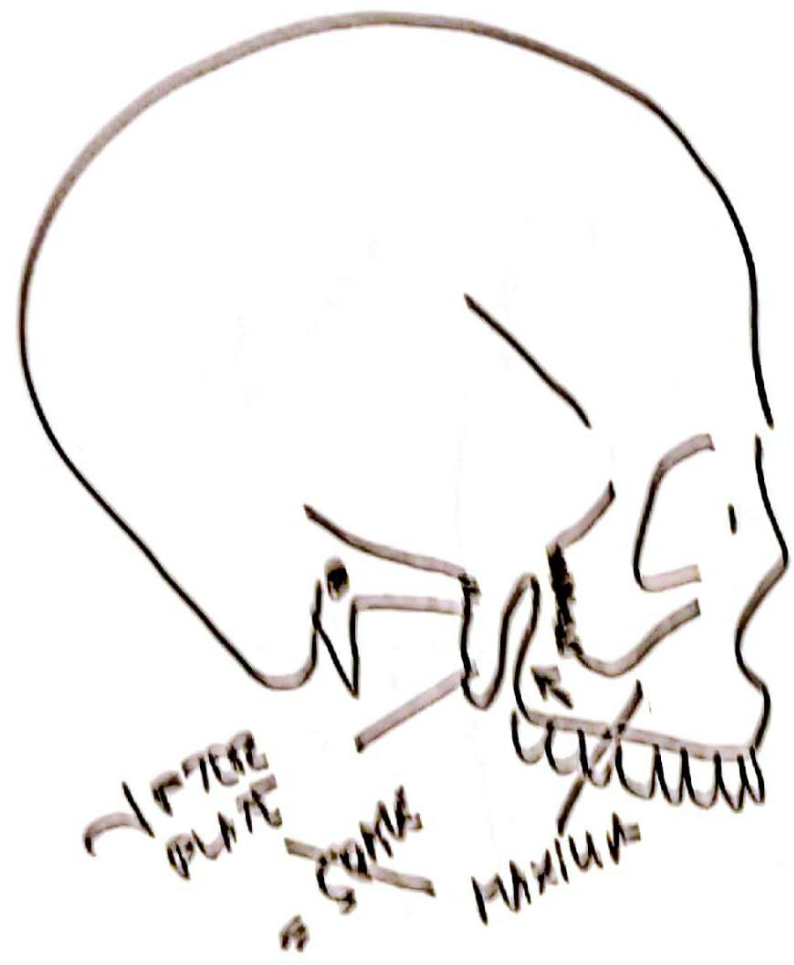
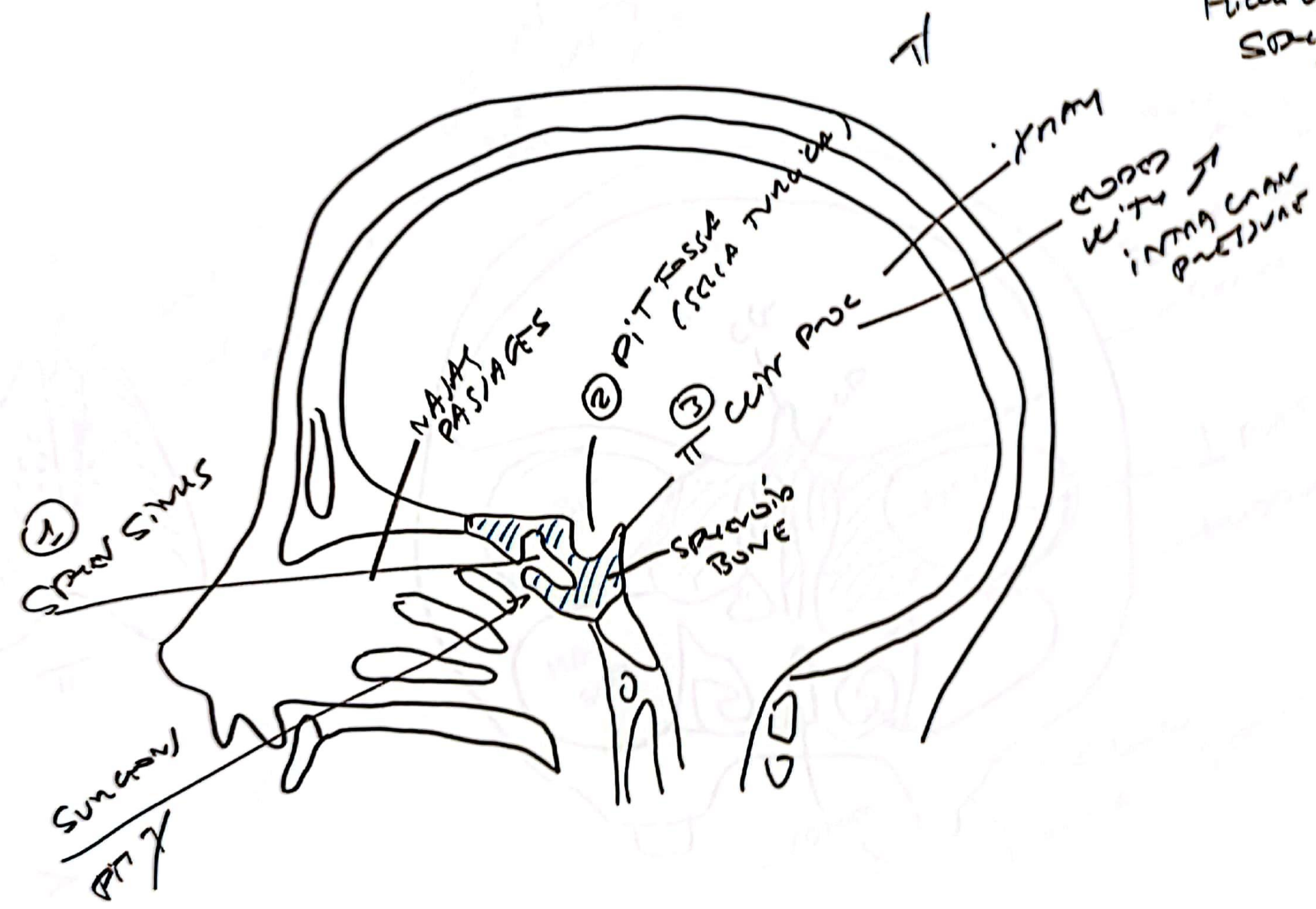
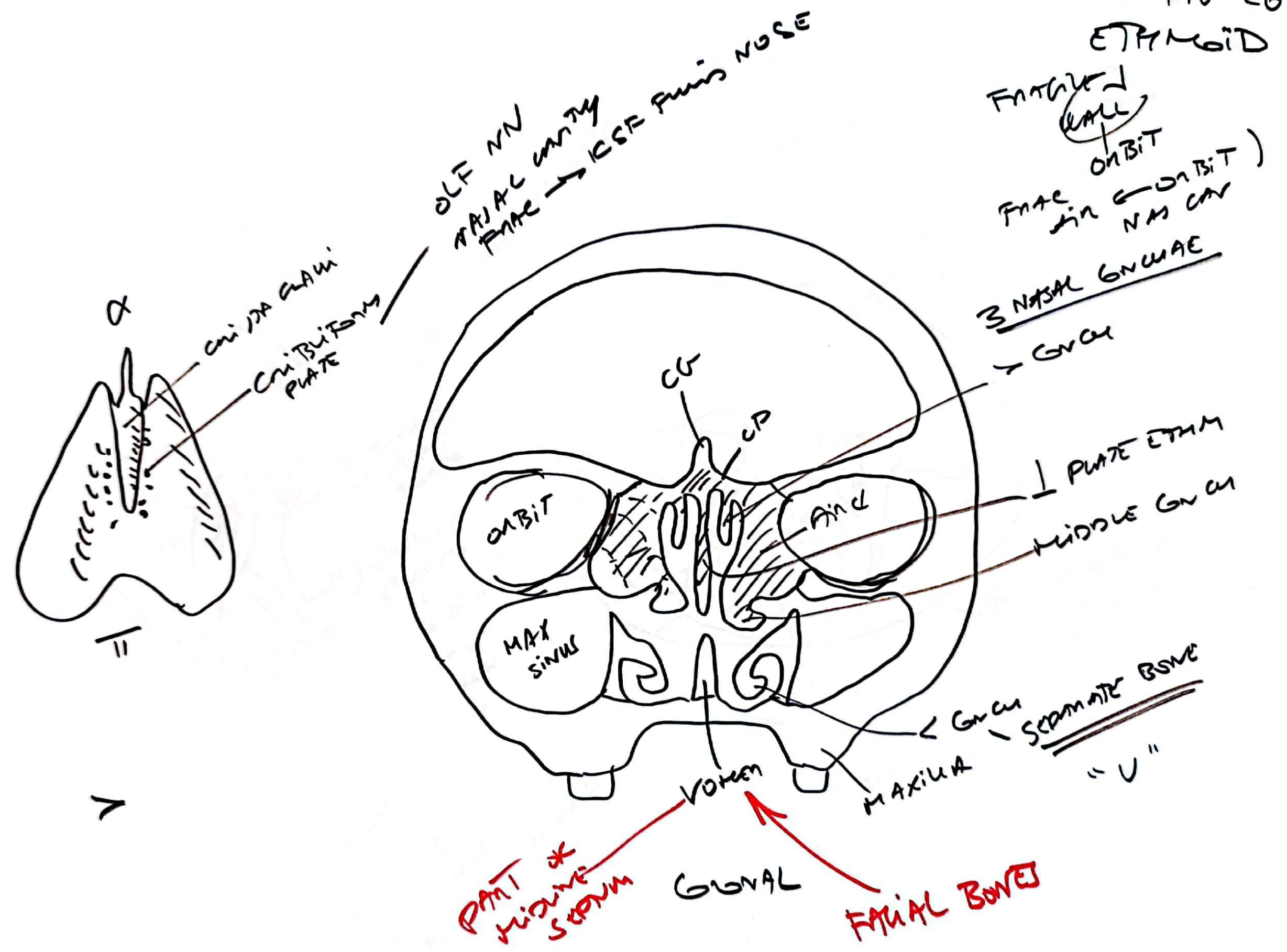


FIG 25  
SAGITTAL  
VIEW SKULL  
HUMAN LACUNA  
SPINOUS  
BONE



ETHMOID





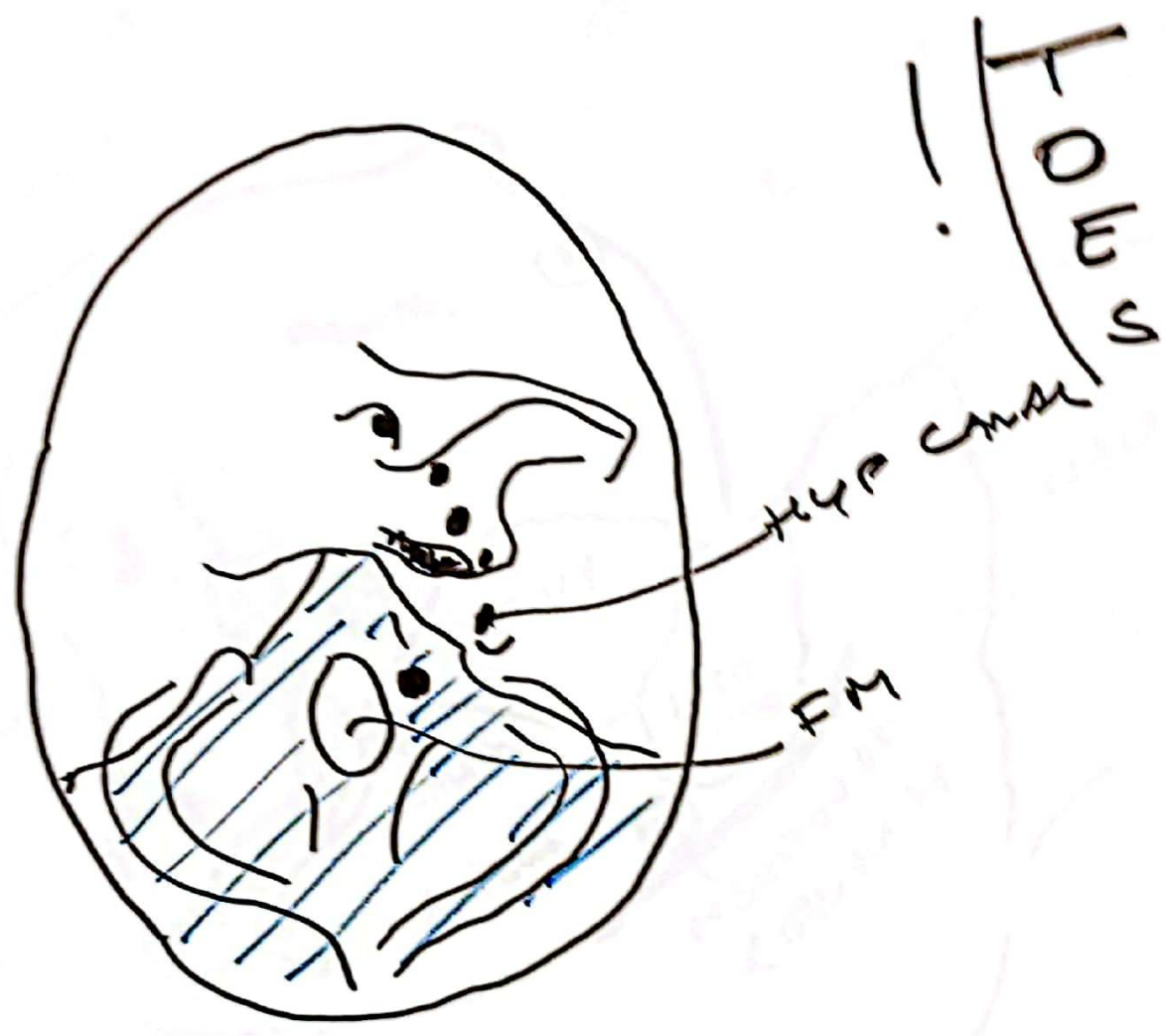


occipital

REMEMBER

CRANIAL  
CERVICAL  
THORACIC  
LUMBAR  
TOES  
SACRAL

For 5 CN	7 8 9 10 11
12	
1	
2 3 4 5 6	



Right eye



FIG 29  
ORBITAL  
BONES

ON GONION  
 FISTULA  
 BETWEEN  
 MANDIB & MMA CANAL

MAY BE A SIGN  
 OF ENLARGED  
 OPTIC CANAL

ENLARGEMENT  
 ON X RAY

OPH VEIN

EMR

CN 3, 4, 5, 6

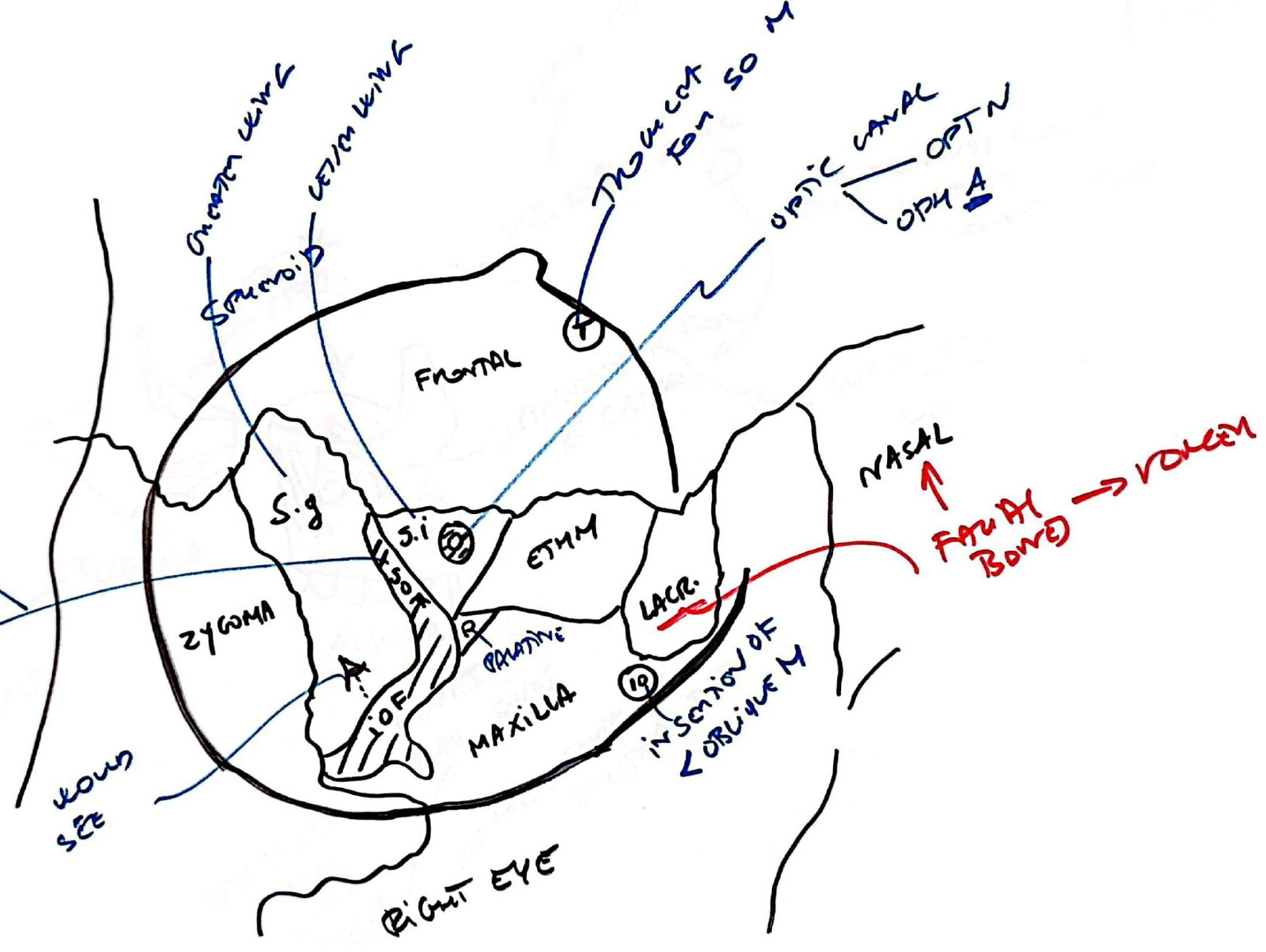




FIG 30  
ZYGOMATIC  
&  
MAXILLARY

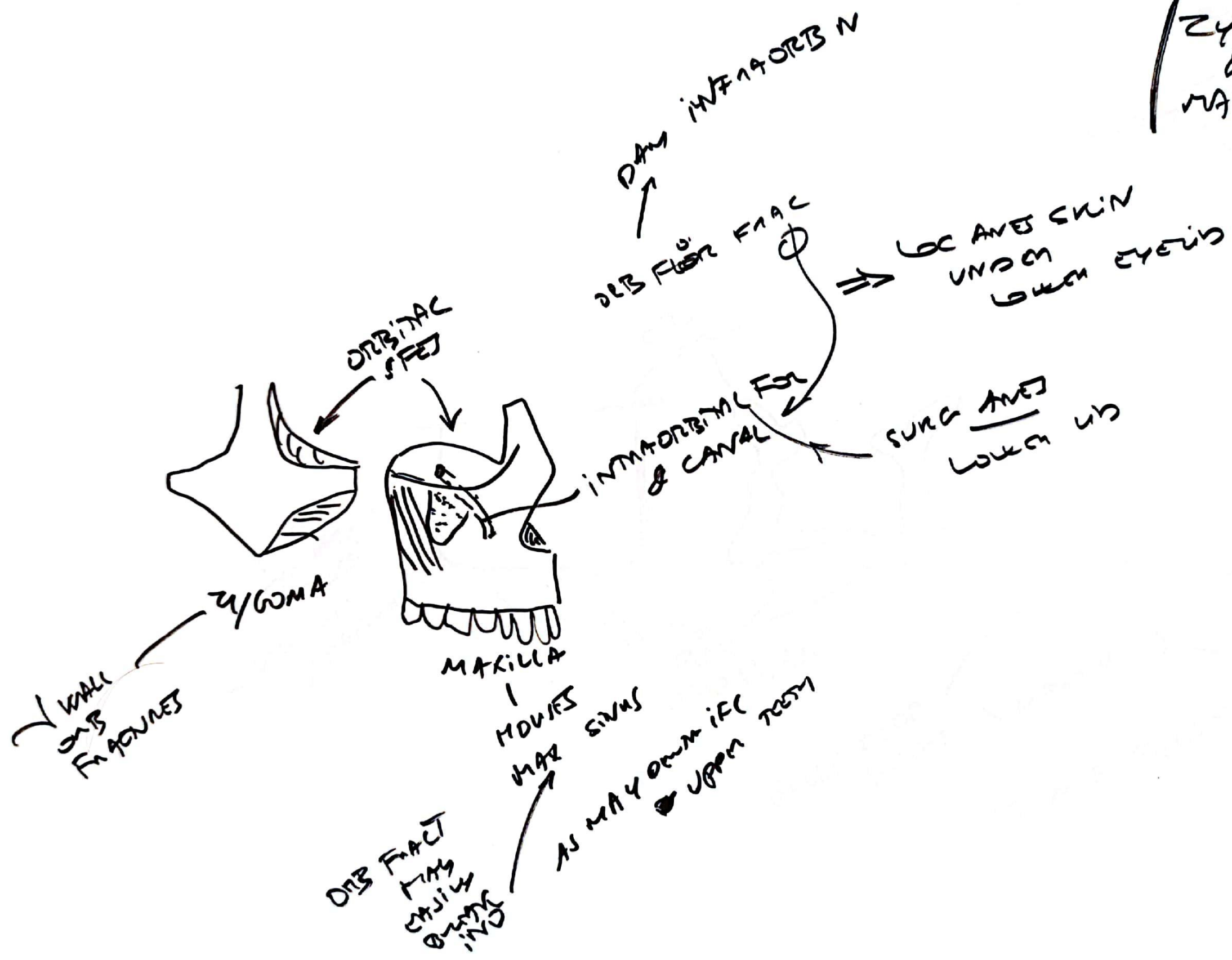


FIG 31  
PALATINE  
BONE

ORBIT  
BACK  
MOUTH

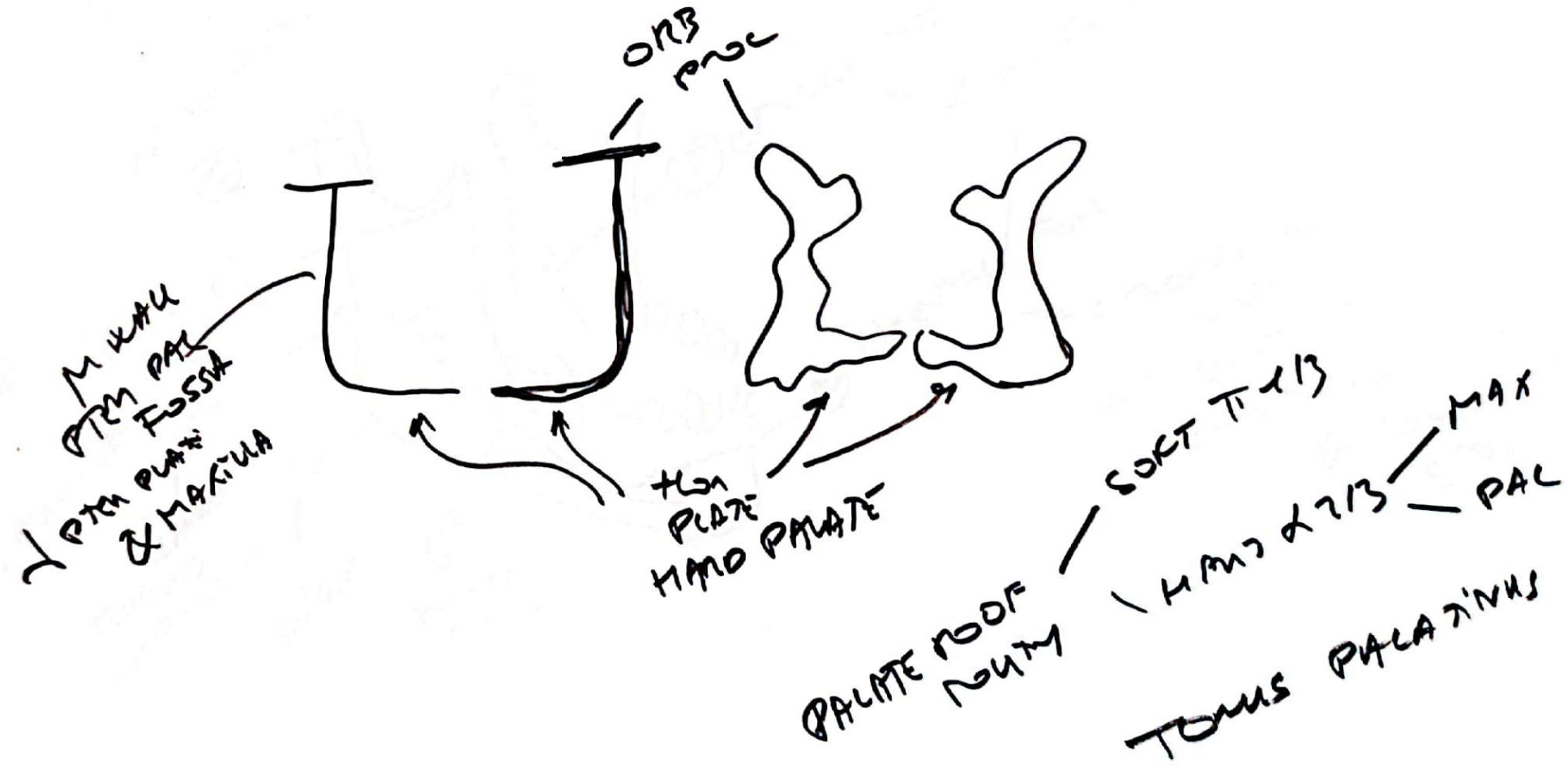
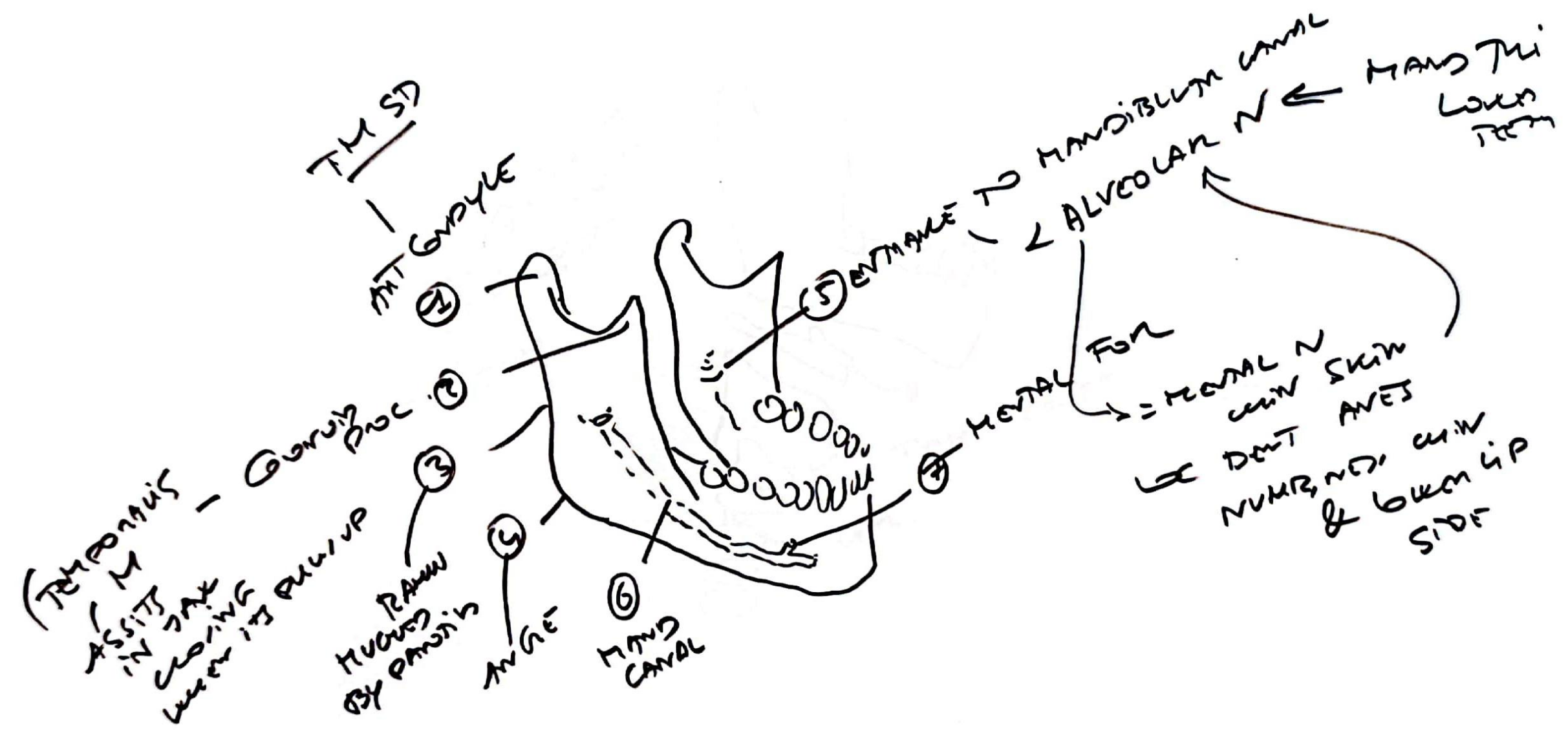


FIG 32  
MANDIBLE





Handwritten marks or scribbles in the top right corner.



