
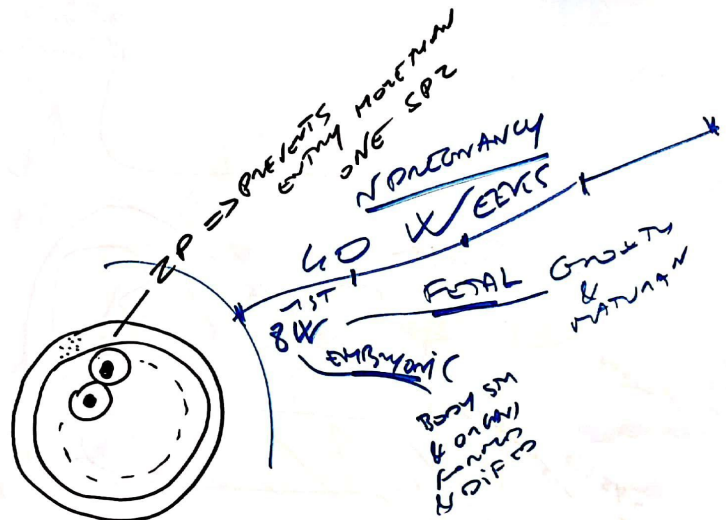
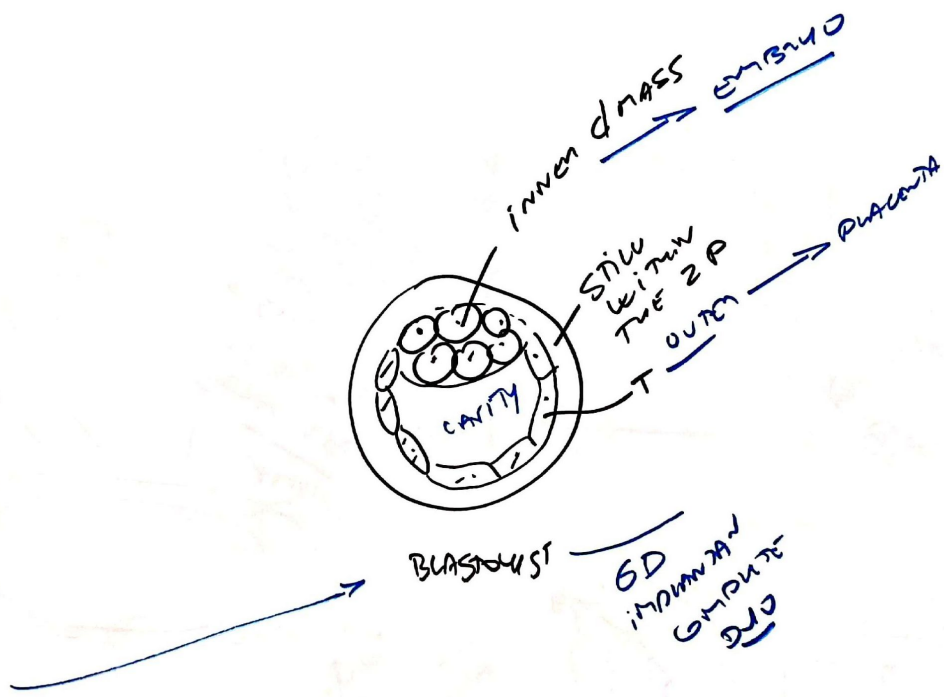
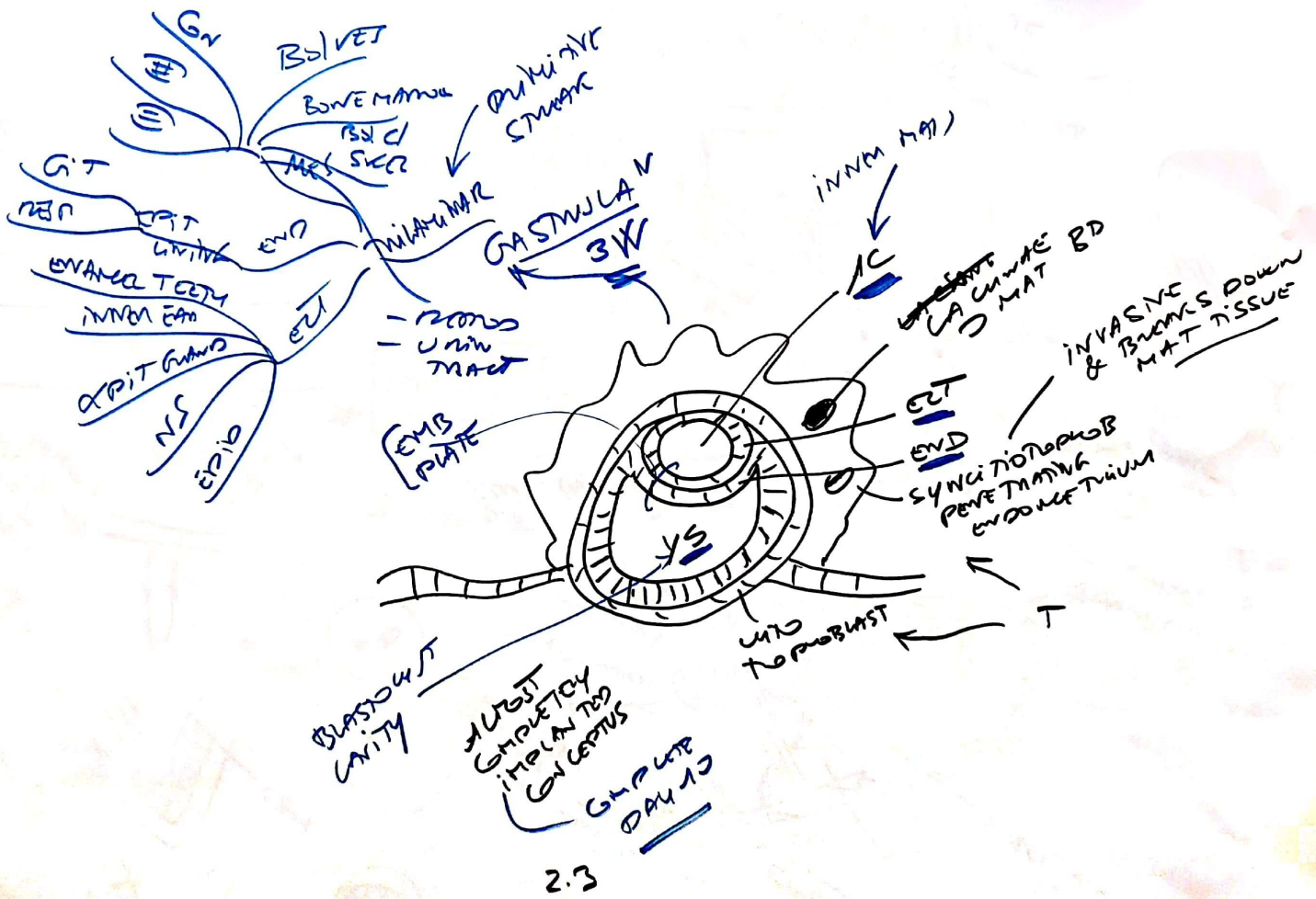


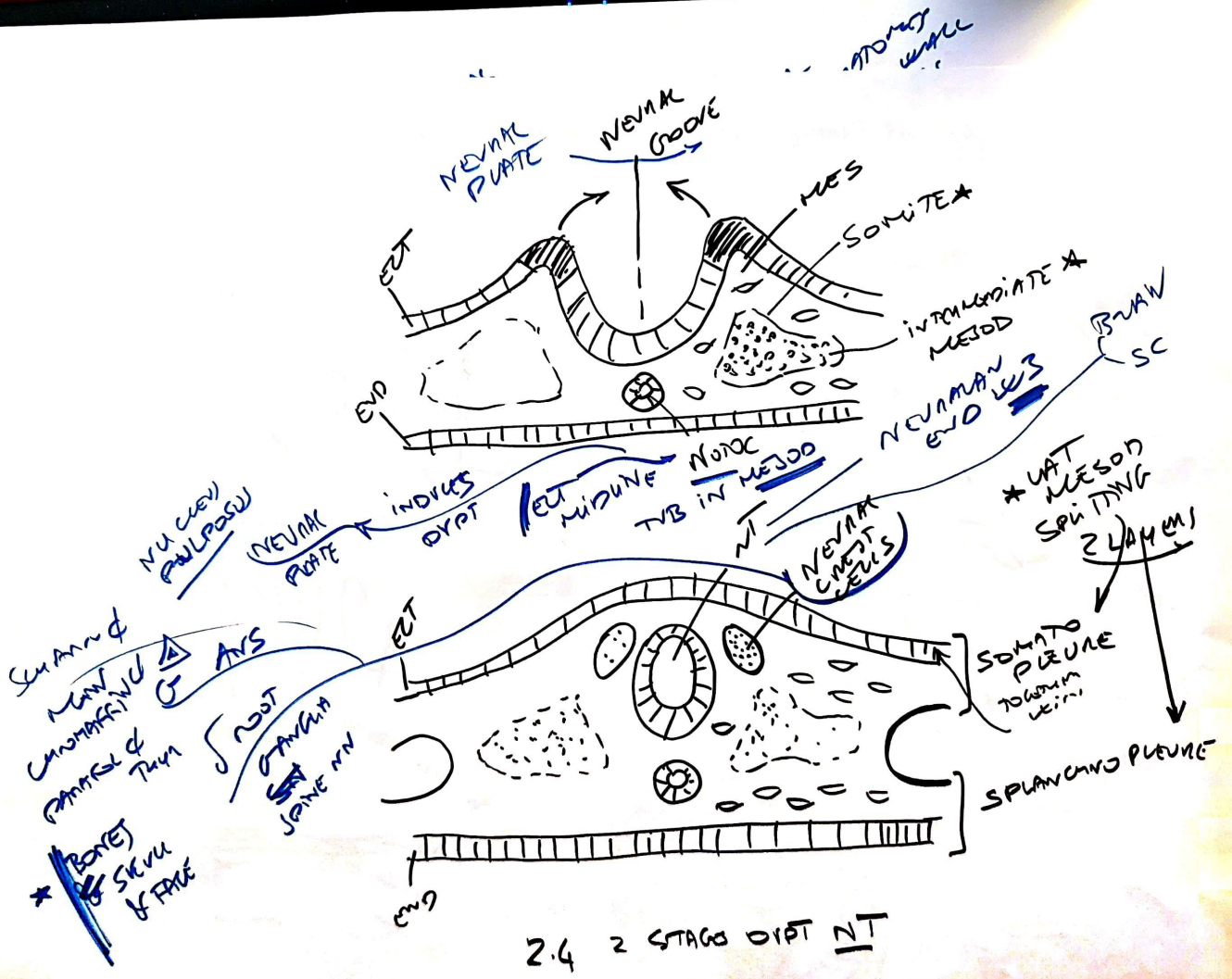
2
EMBRYOLOGY

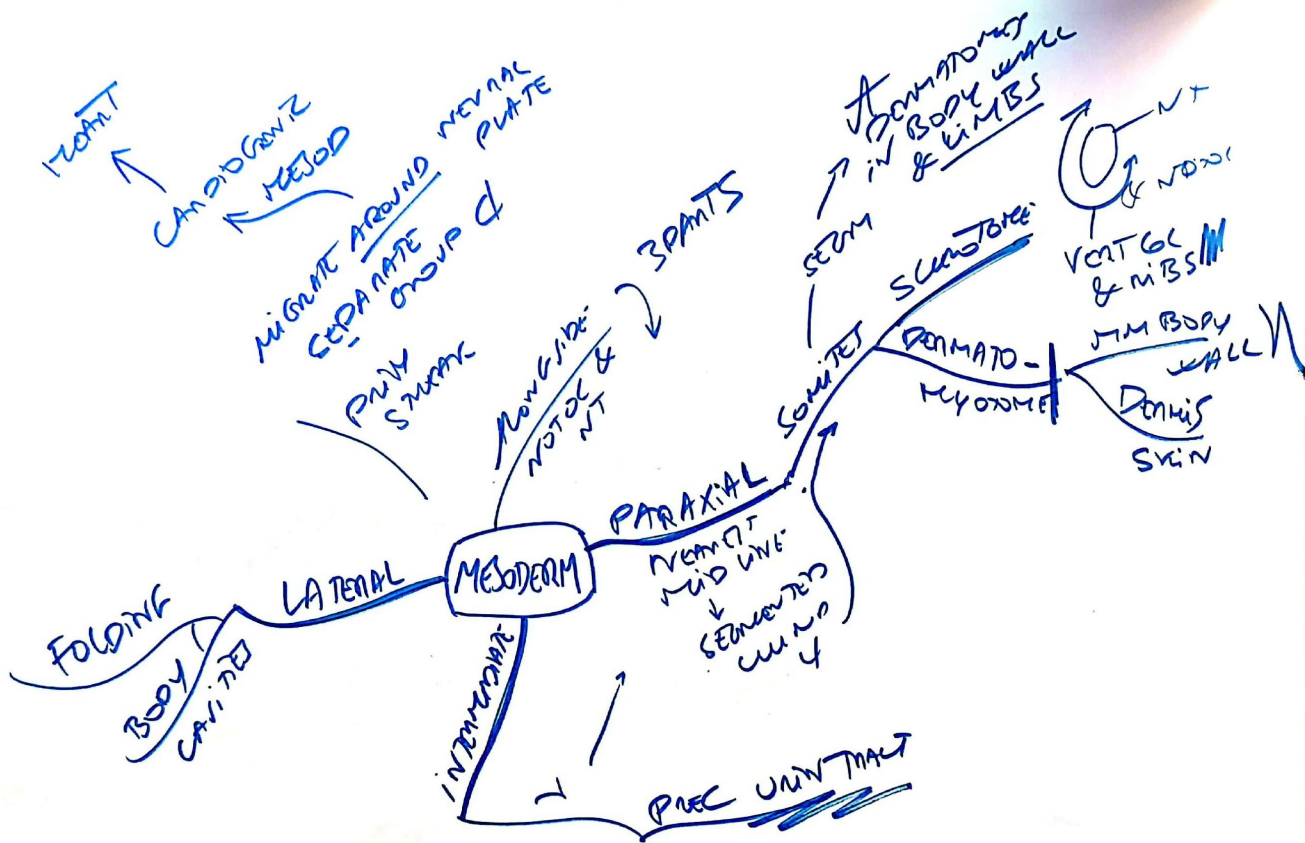


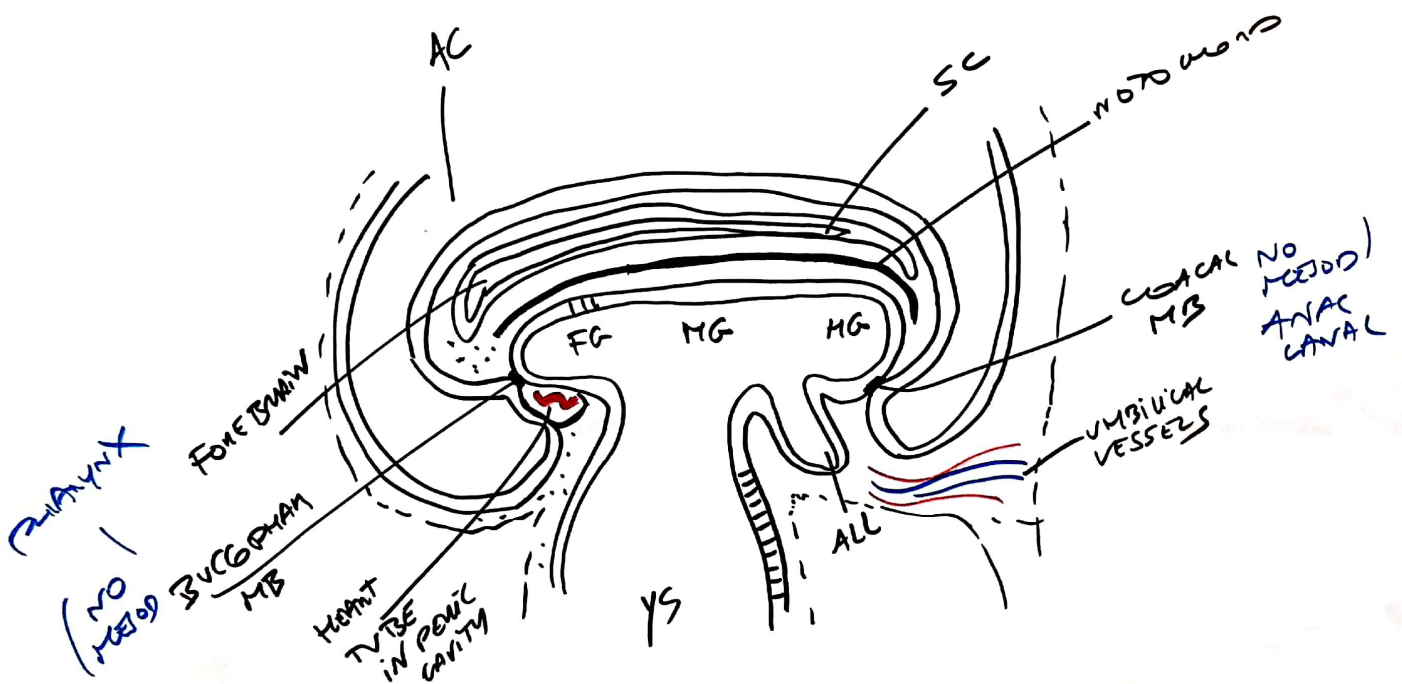


2.2









2.6 Lateral view show head & tail folds
 neck YS → close off → leaving midgut intact
 Allantois functionless → separate → median umbilical
 CS → sub vessels (intra-emb course not shown) ligament