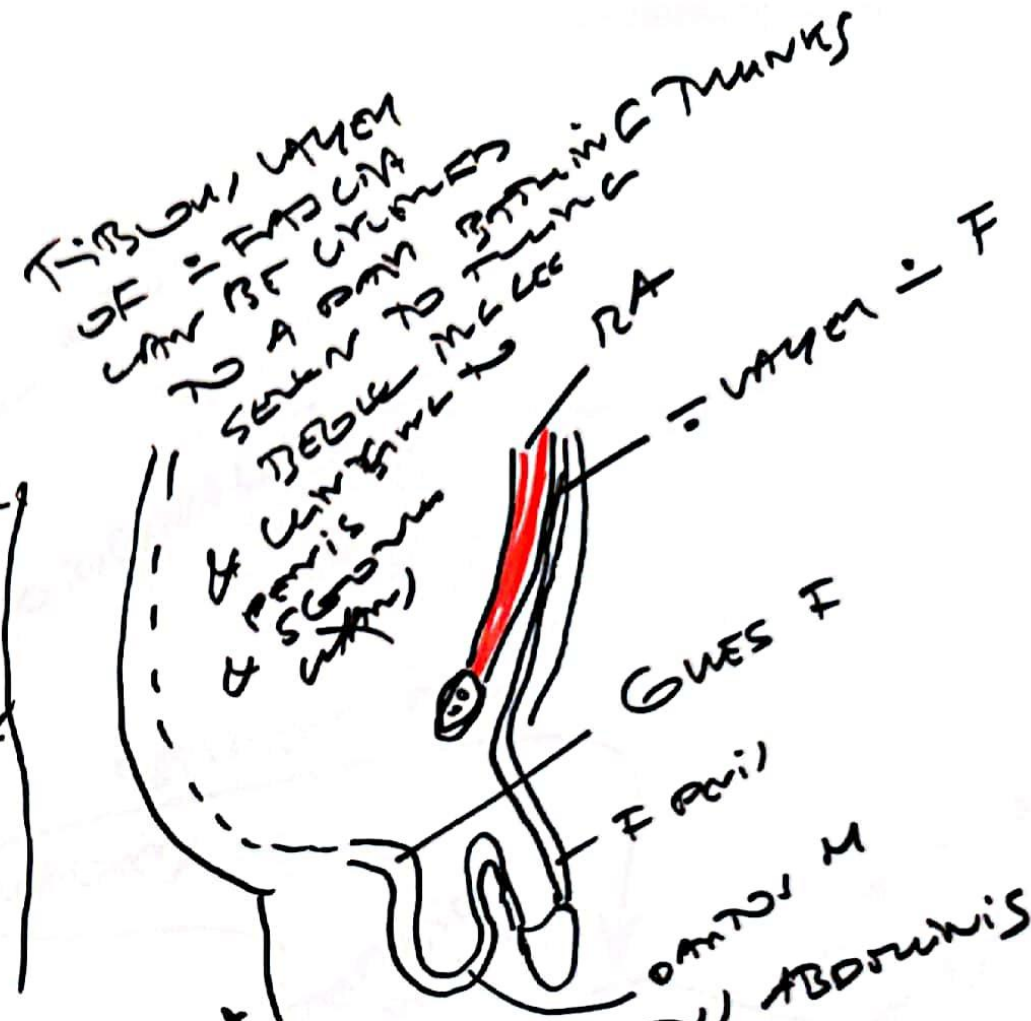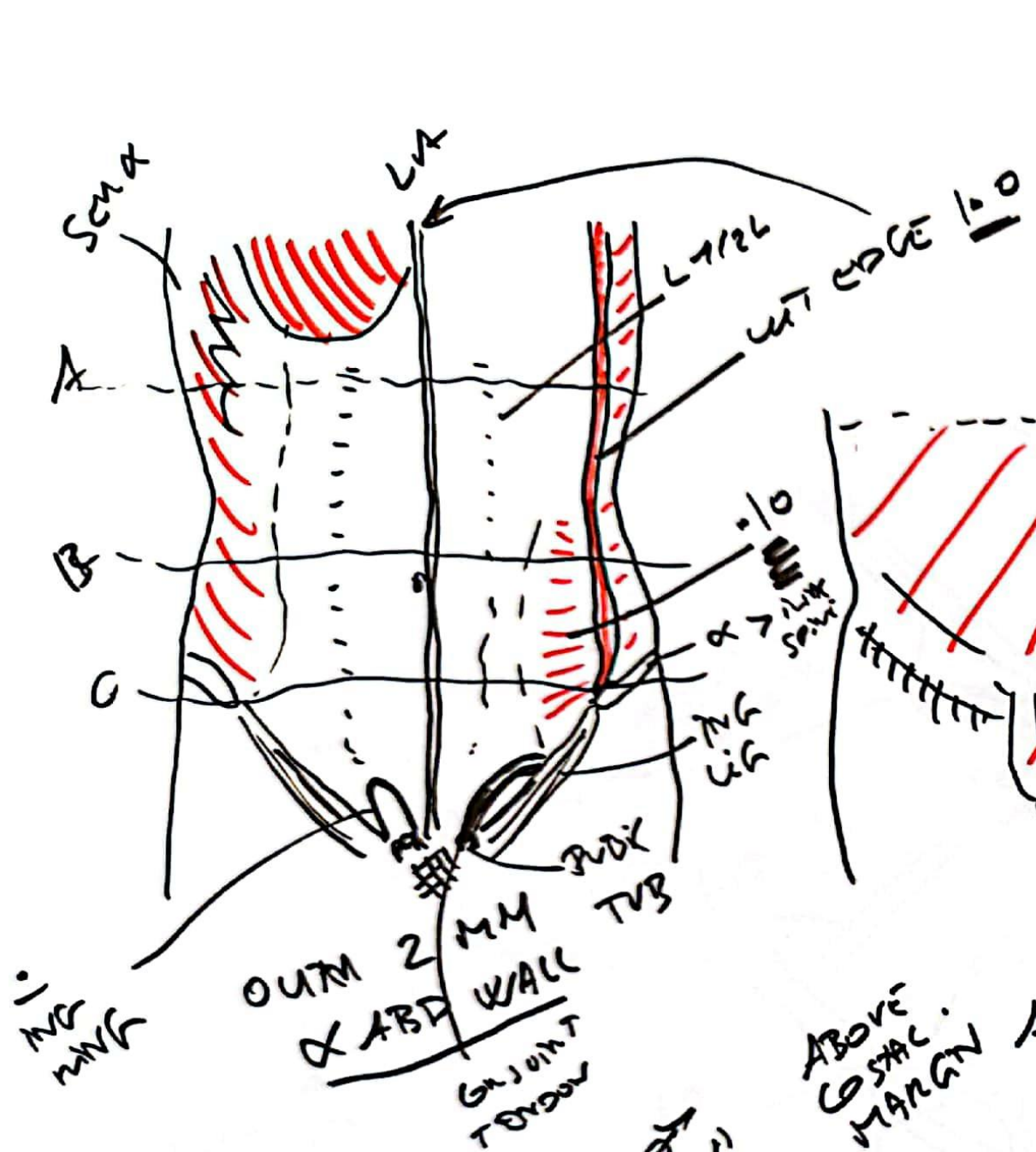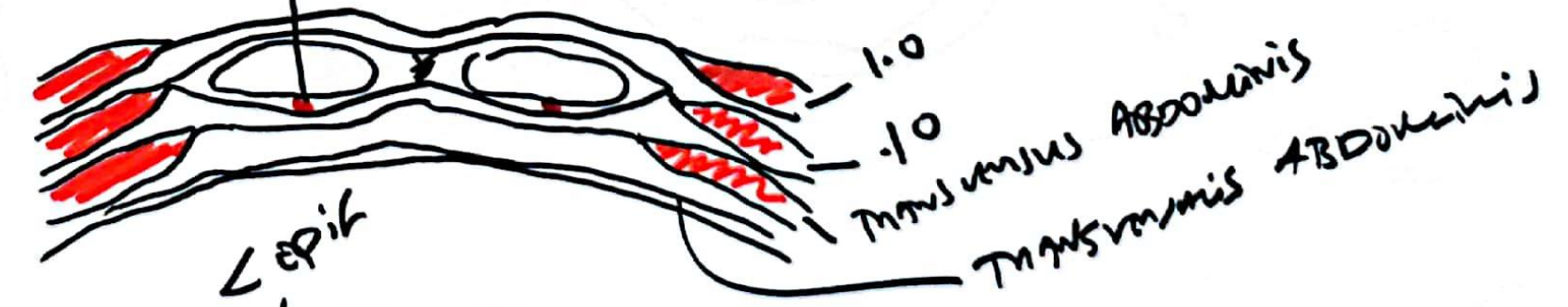



ABOVE G STAC MARGN A



ABOVE UMB B

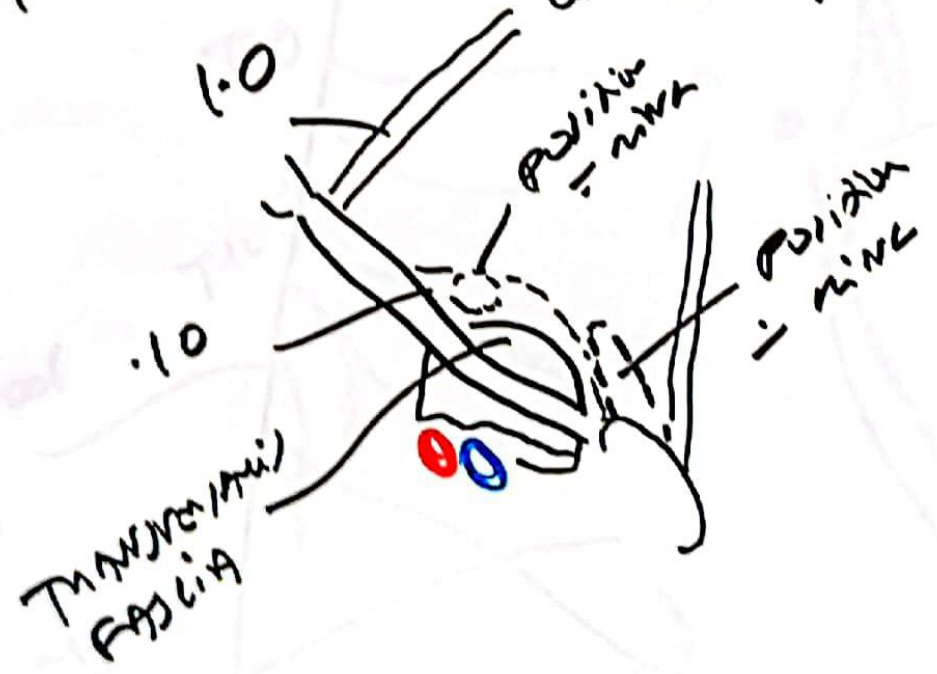
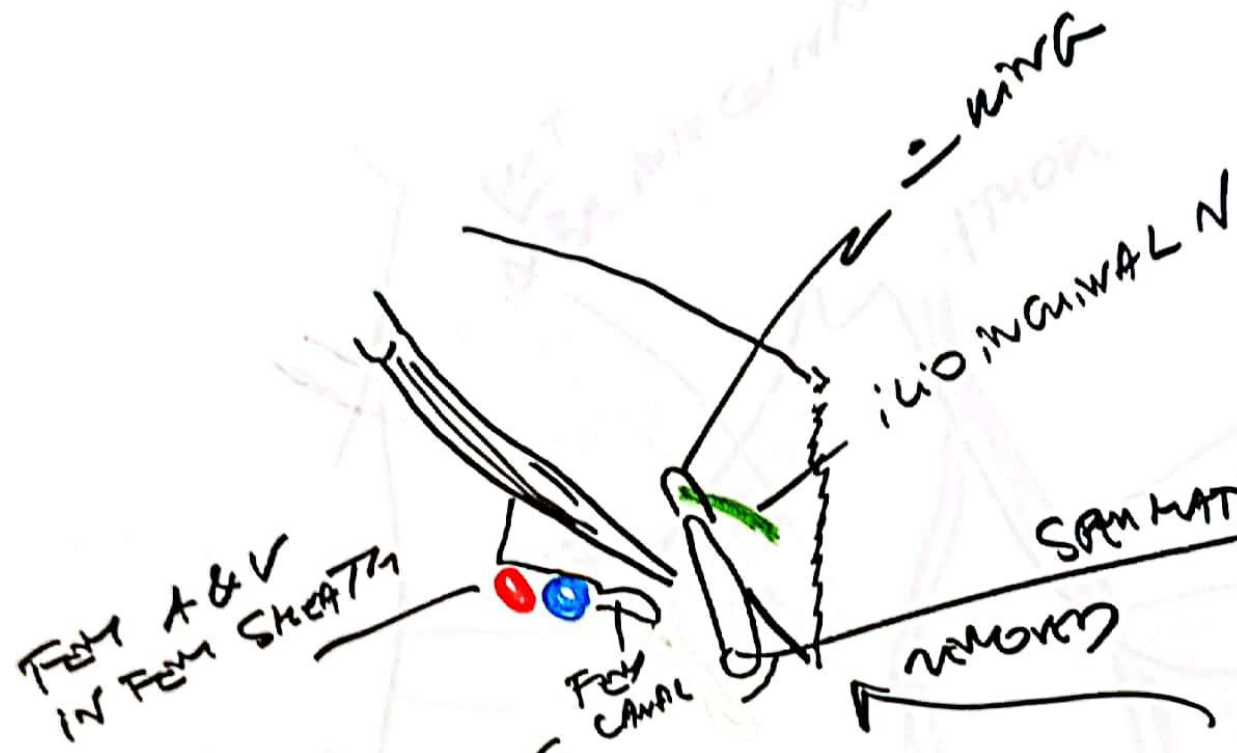


ABOVE SYNO PUB C



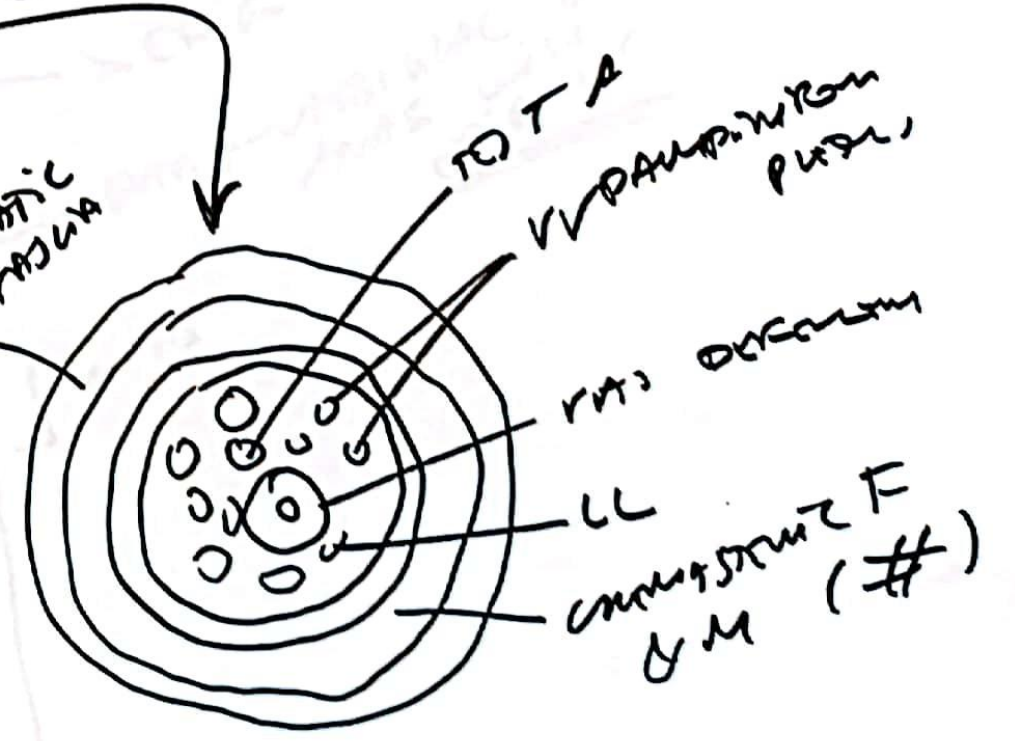
30 Nov 20

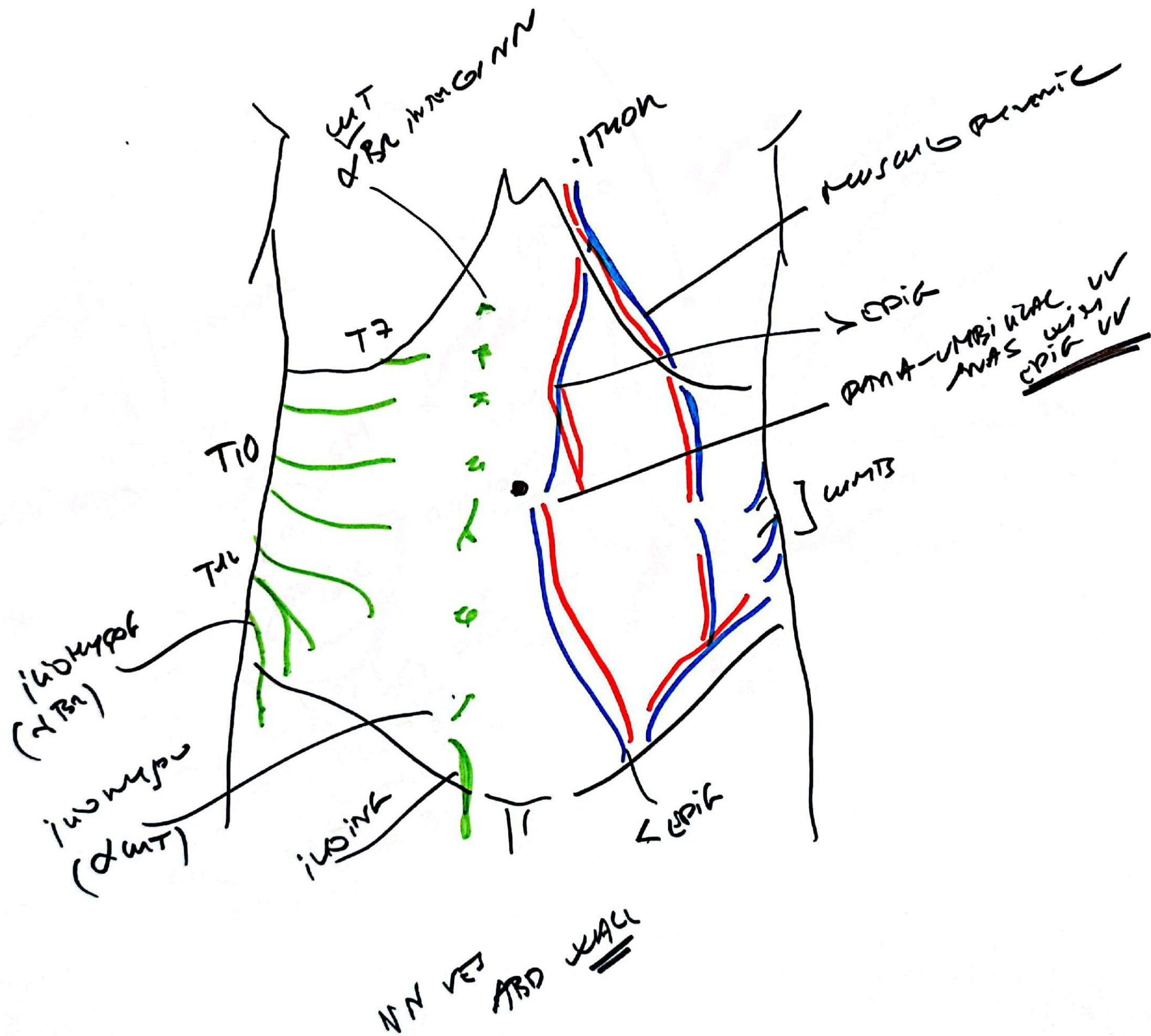
NOUINAL CANAL

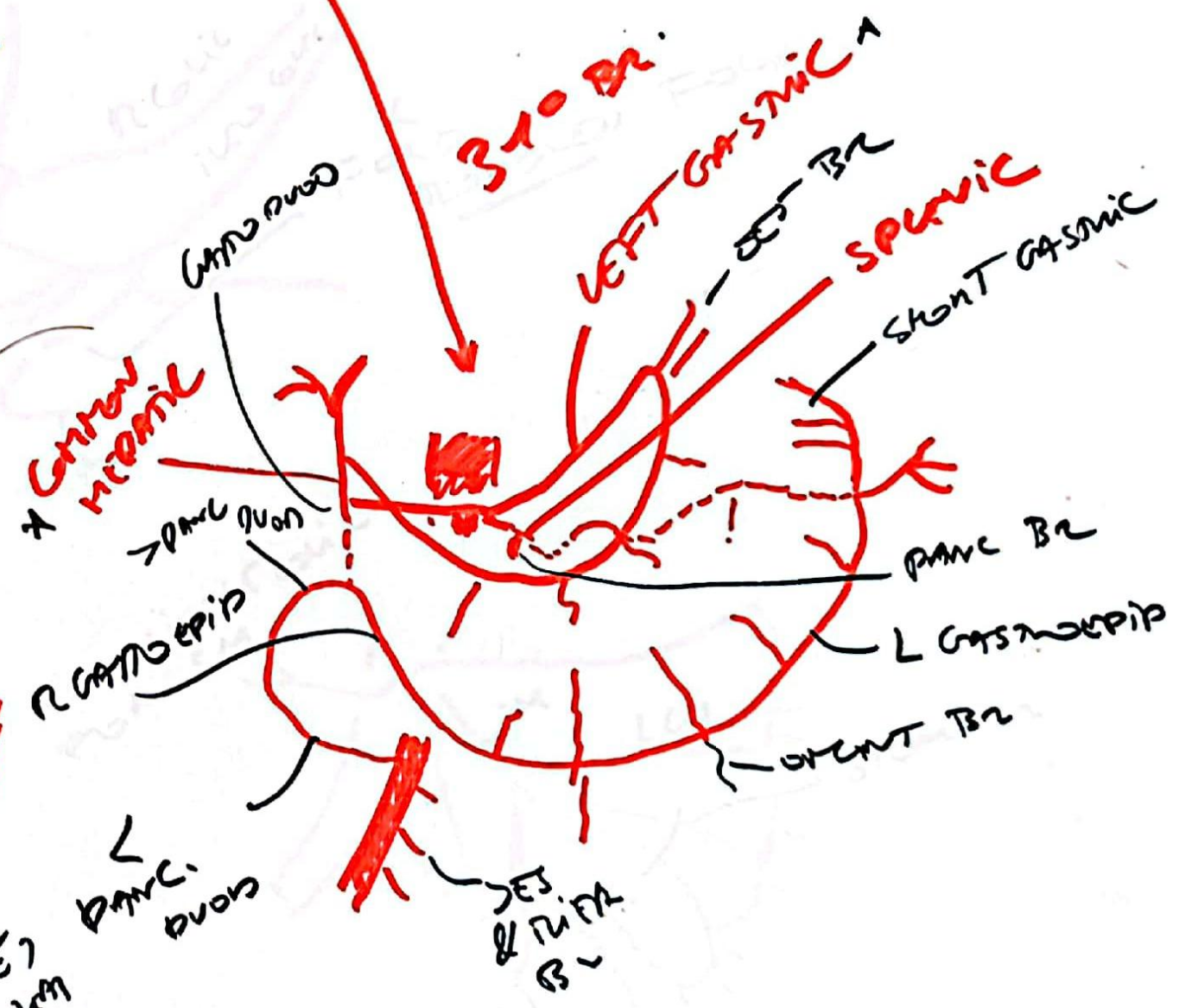
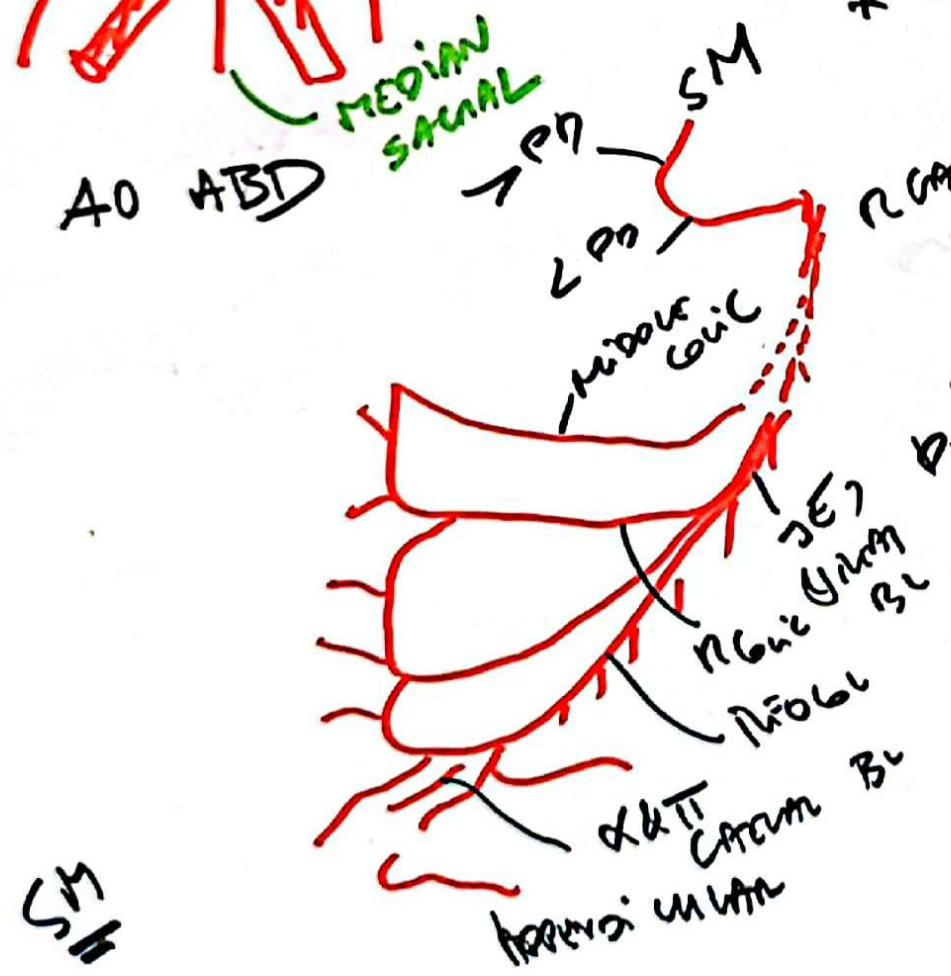
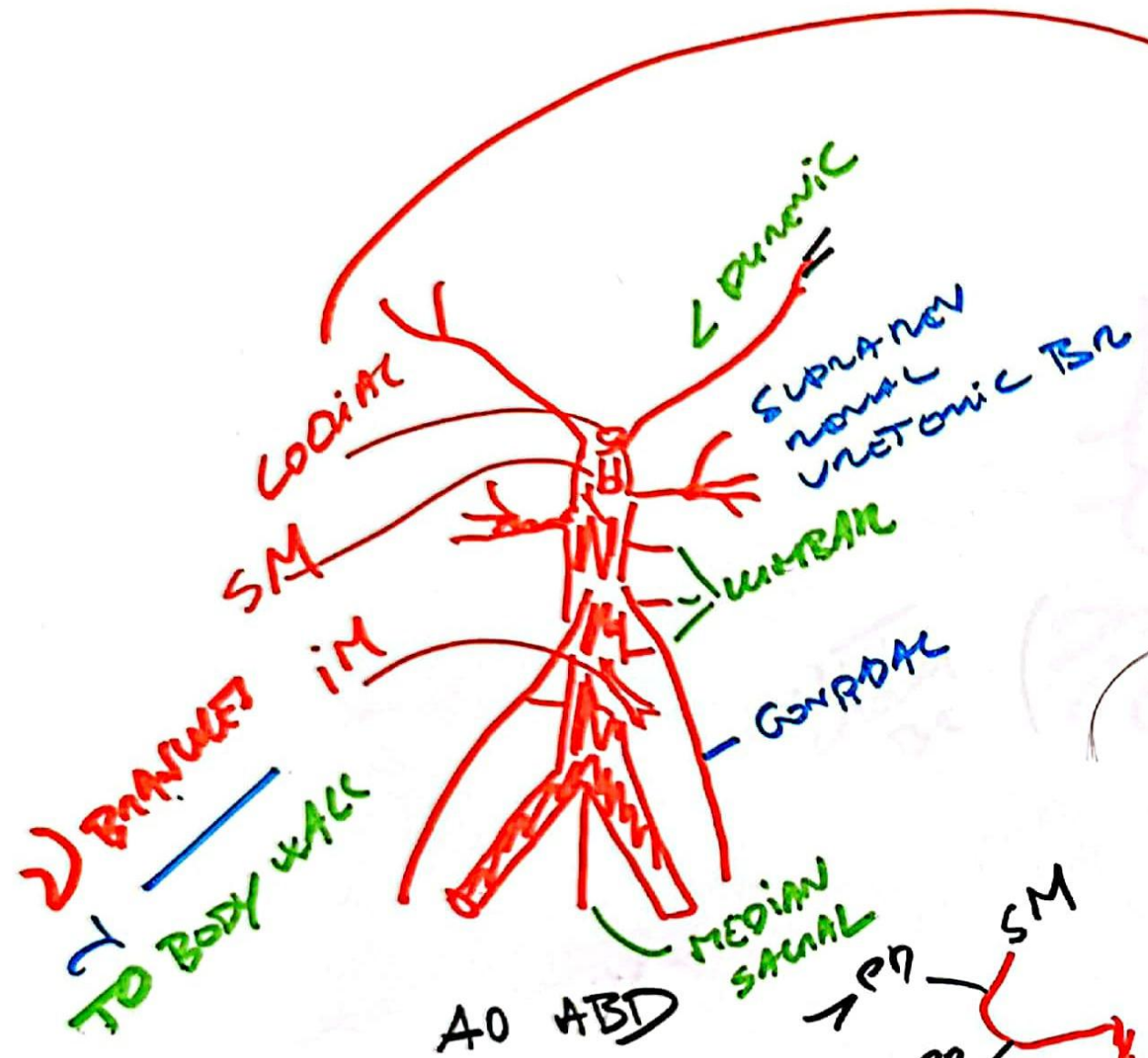


SPERMATIC CORD

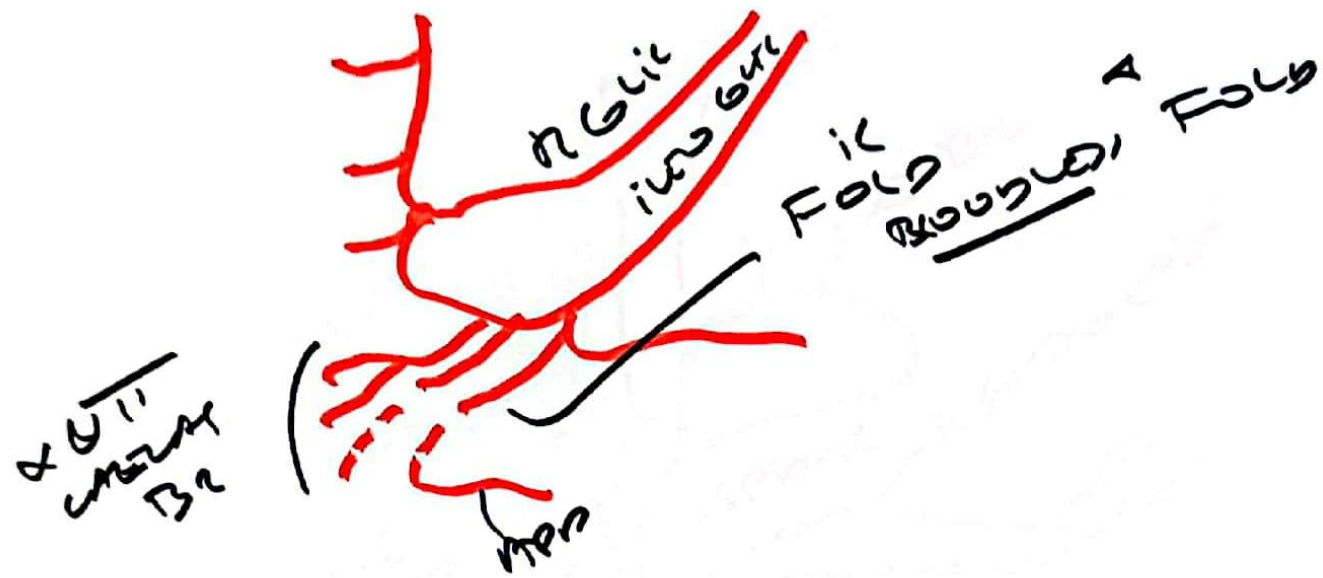
SPERMATIC FASCIA



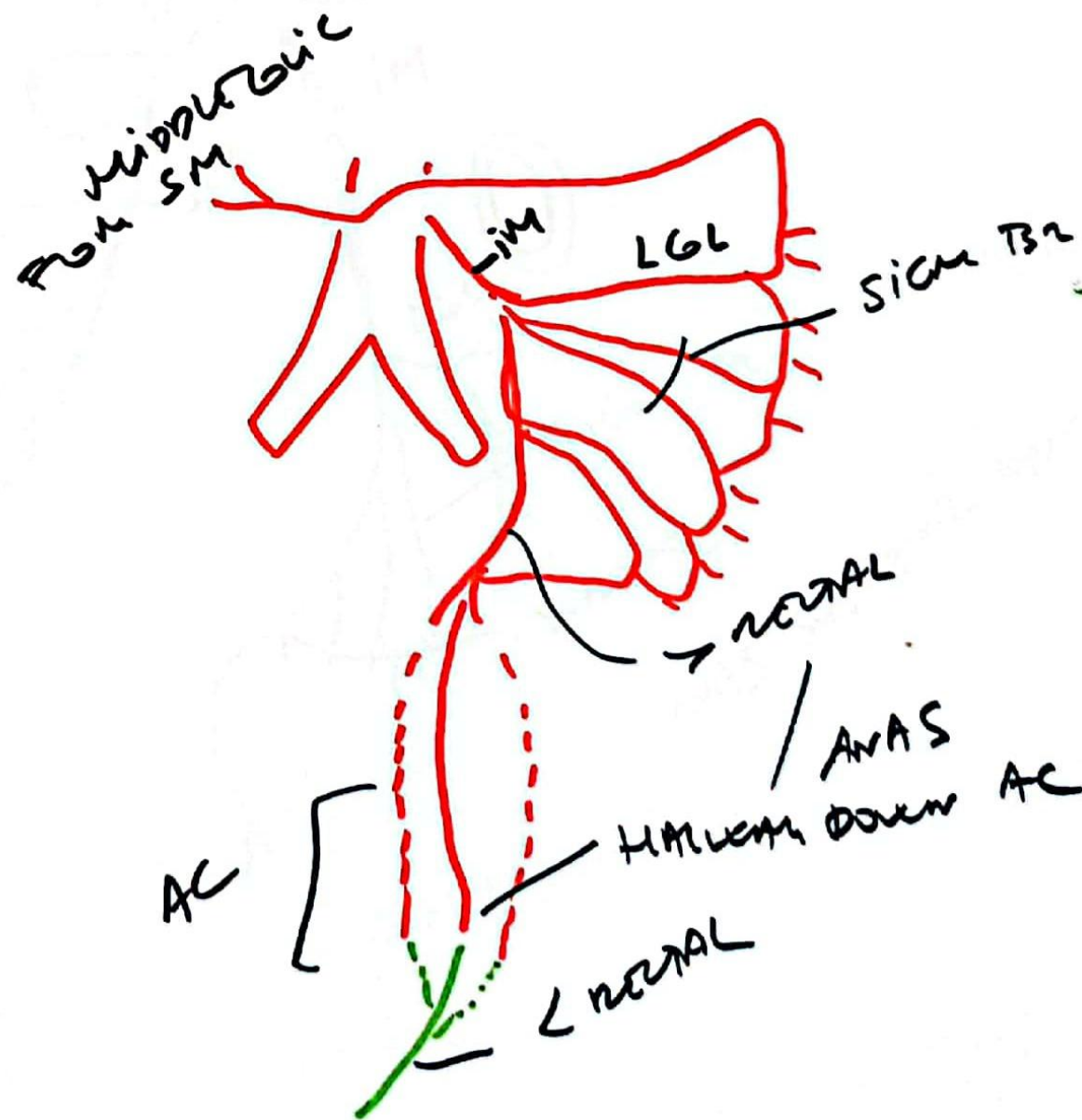


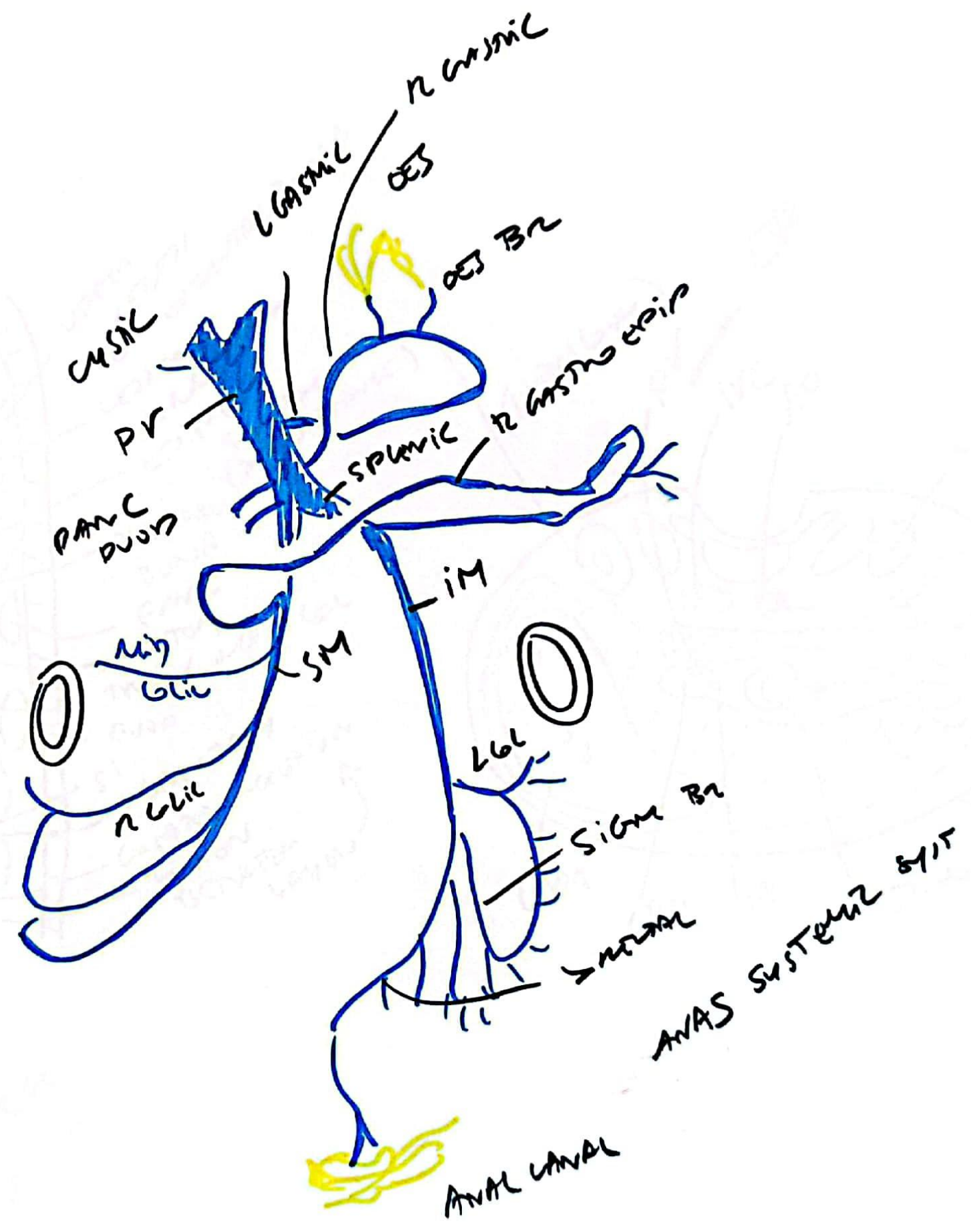
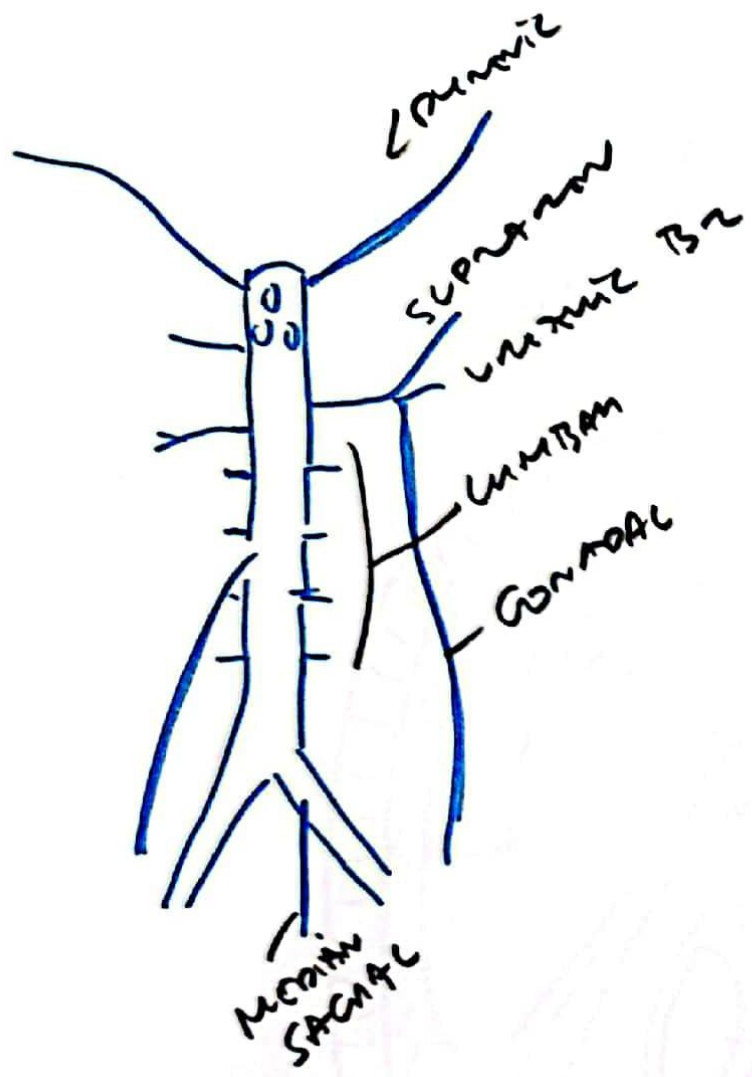


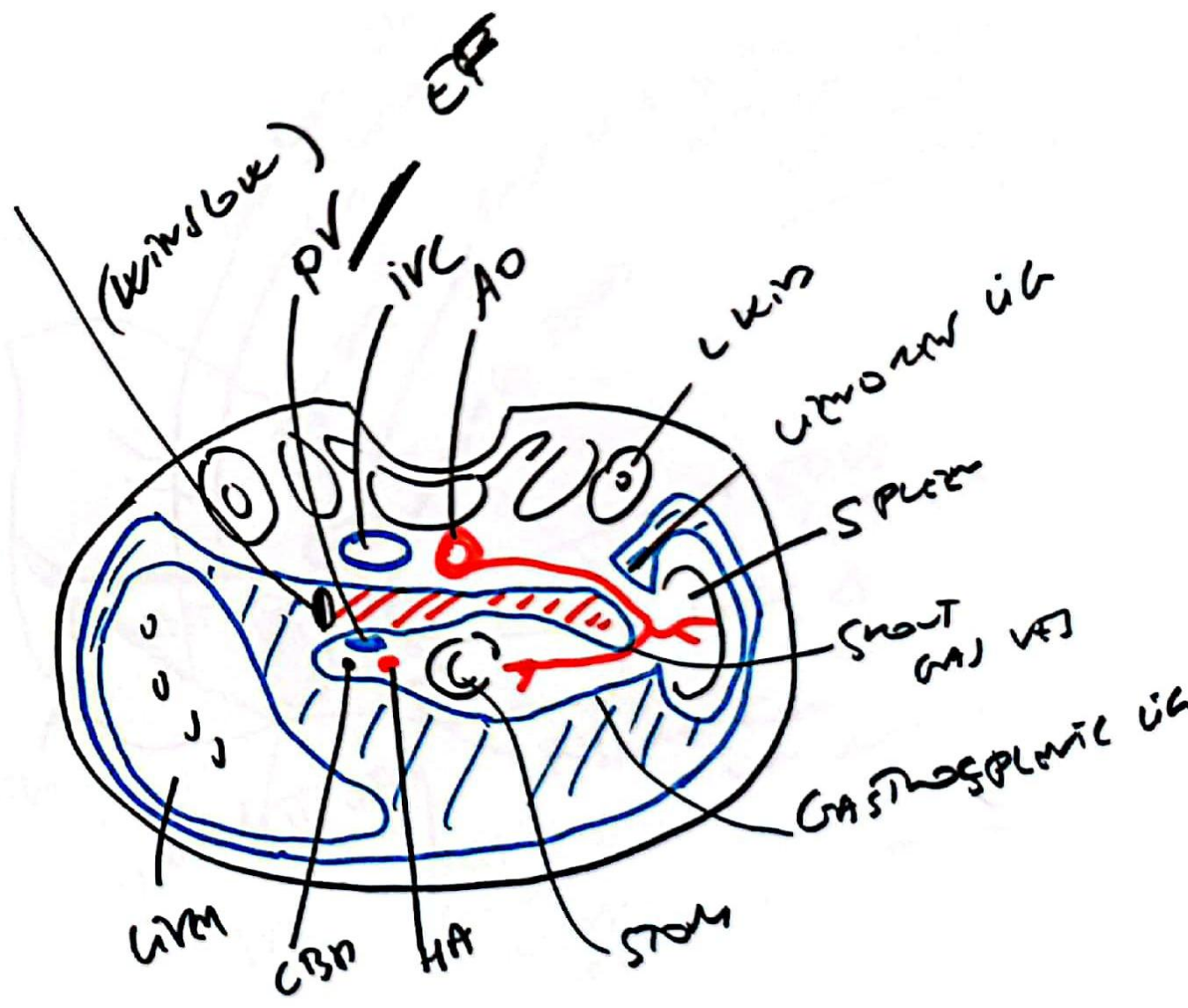
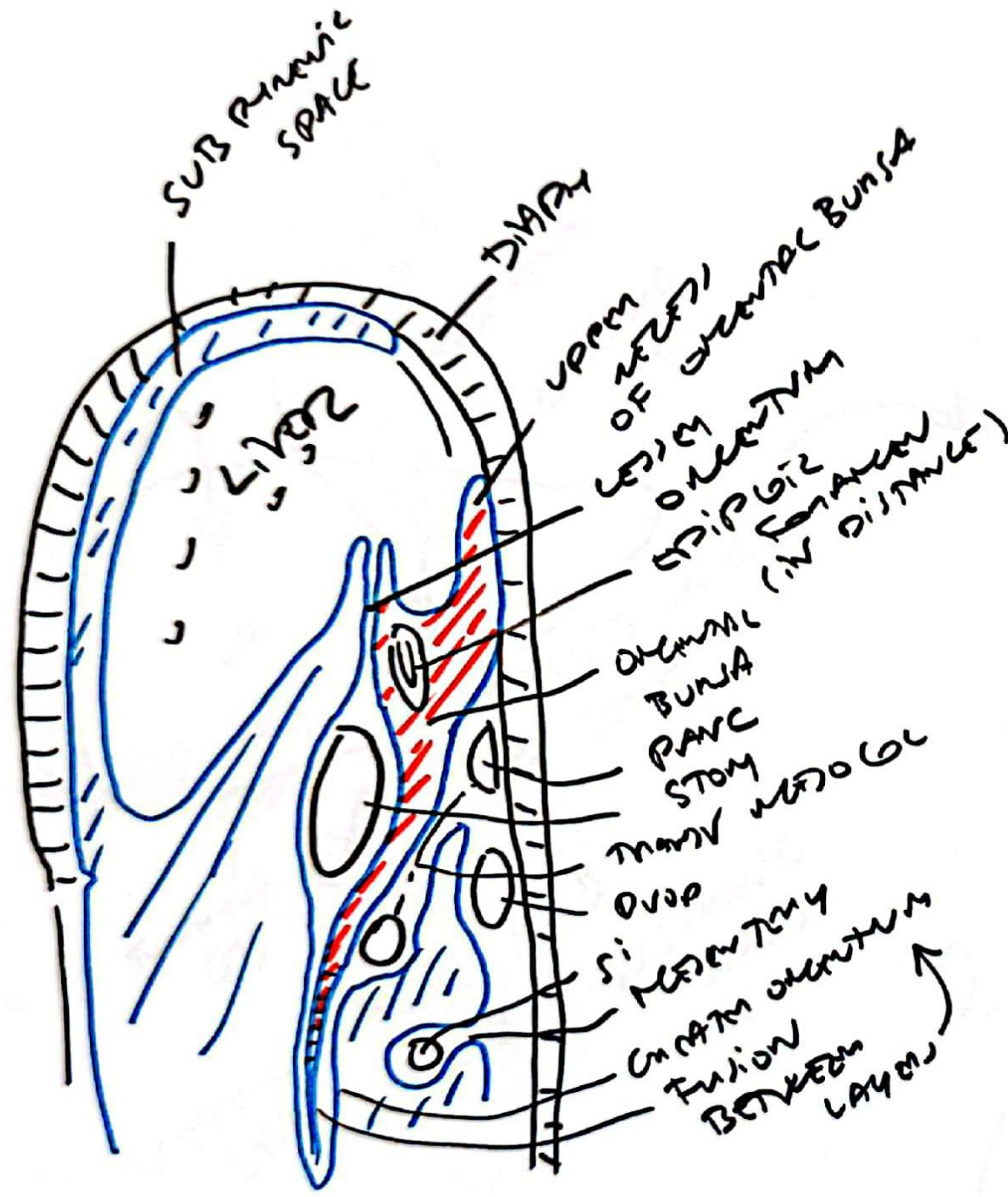
115



AC
MPA
BR

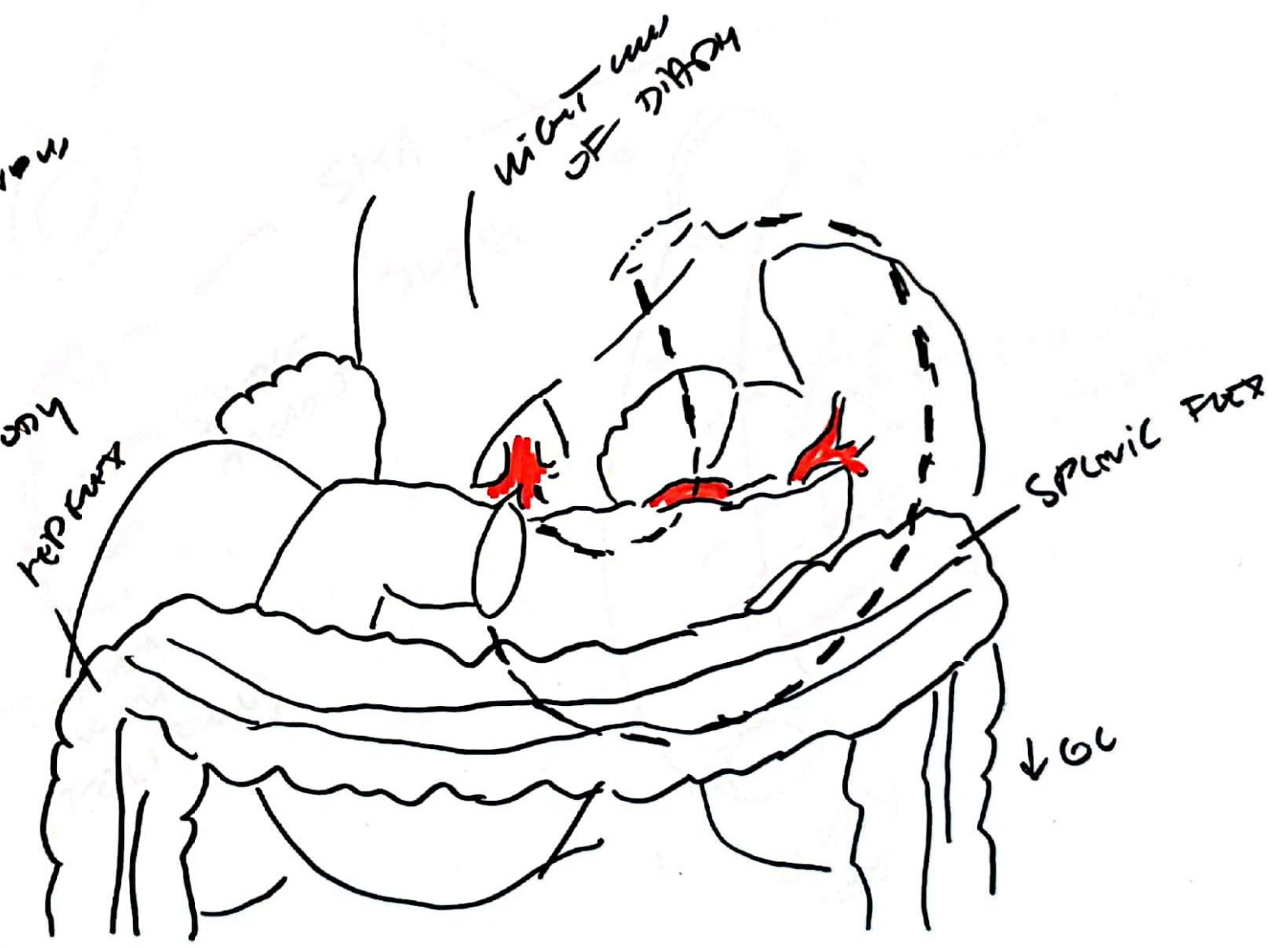
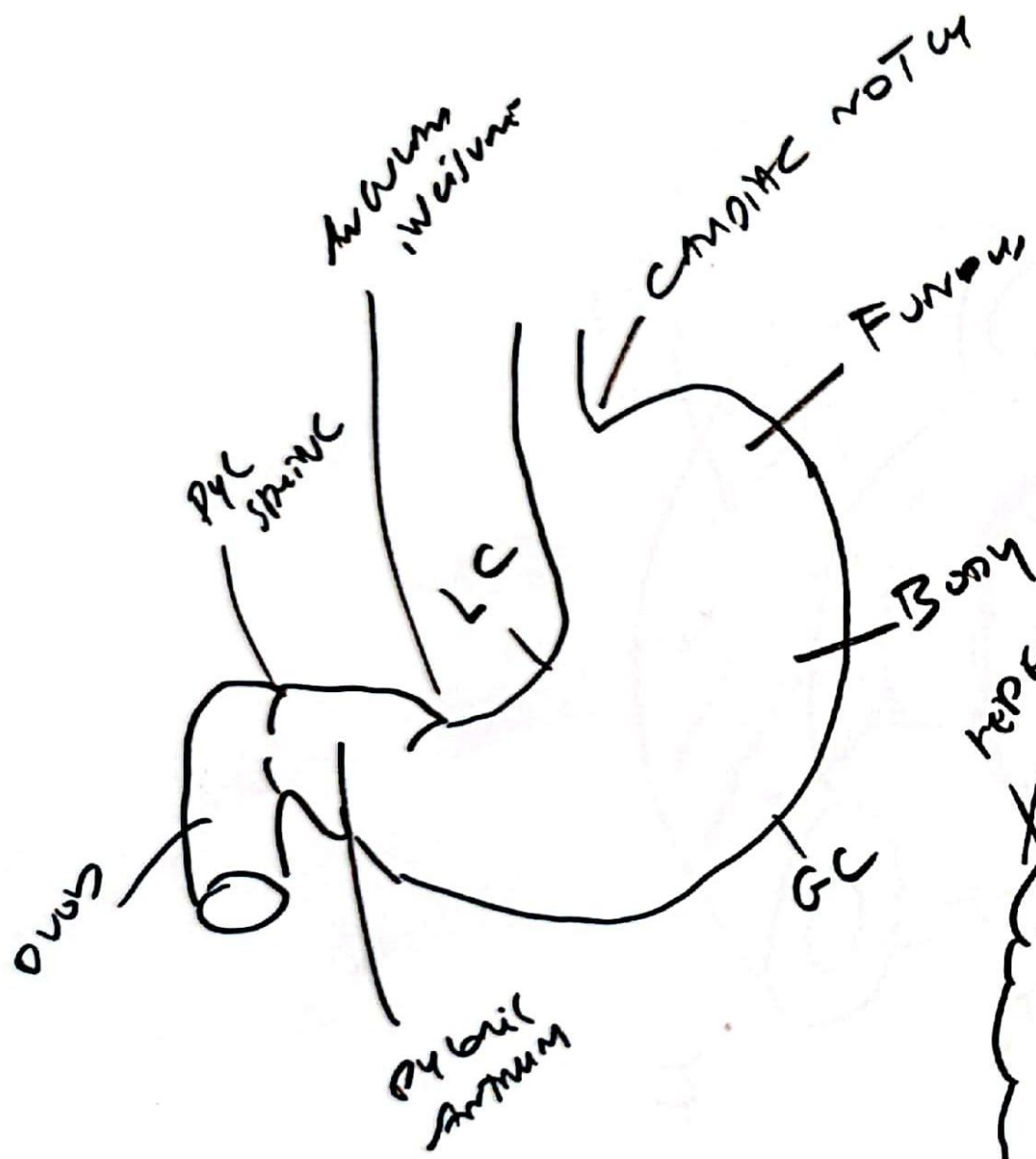





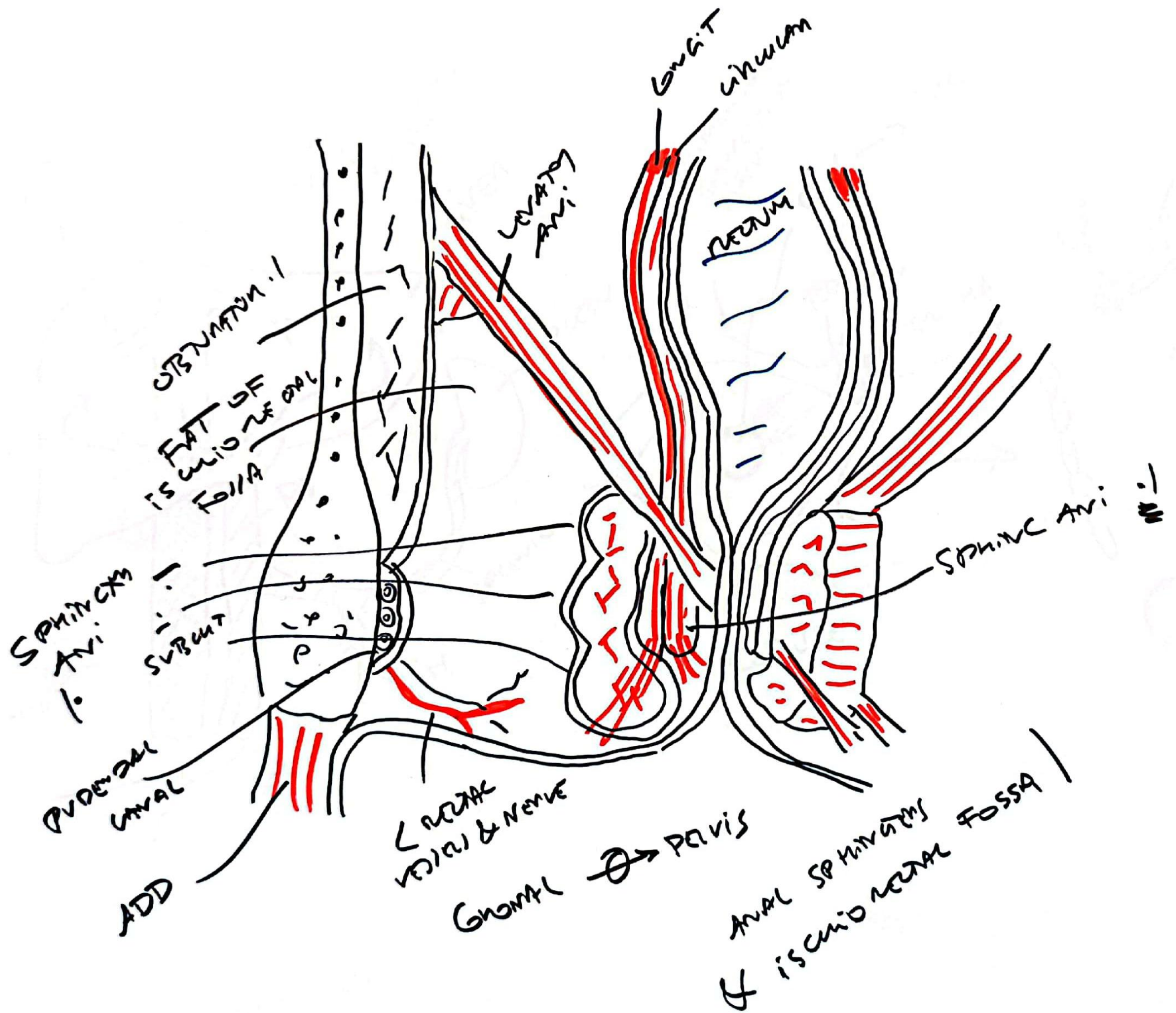


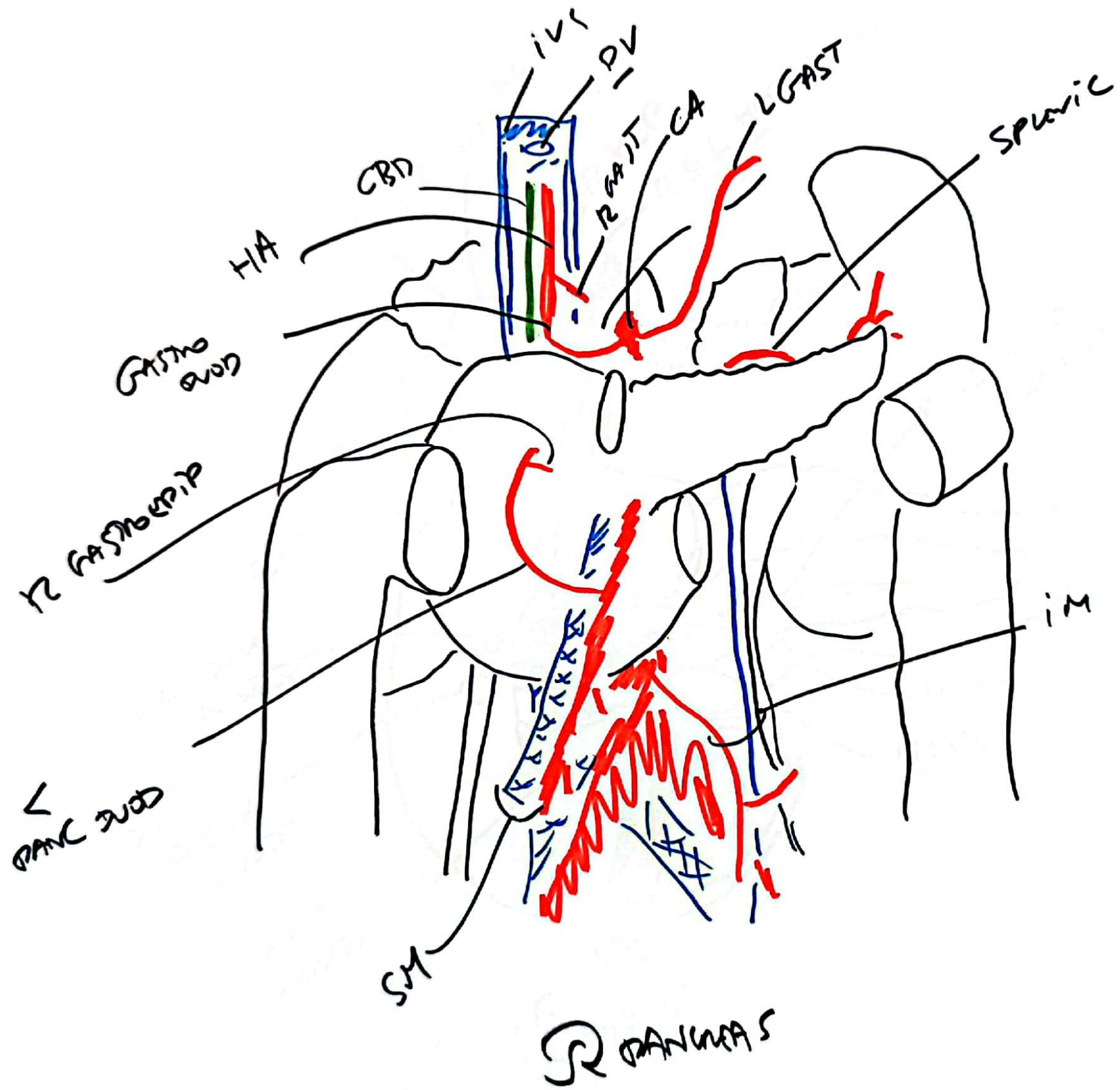
VENT → ABD
 PENT →

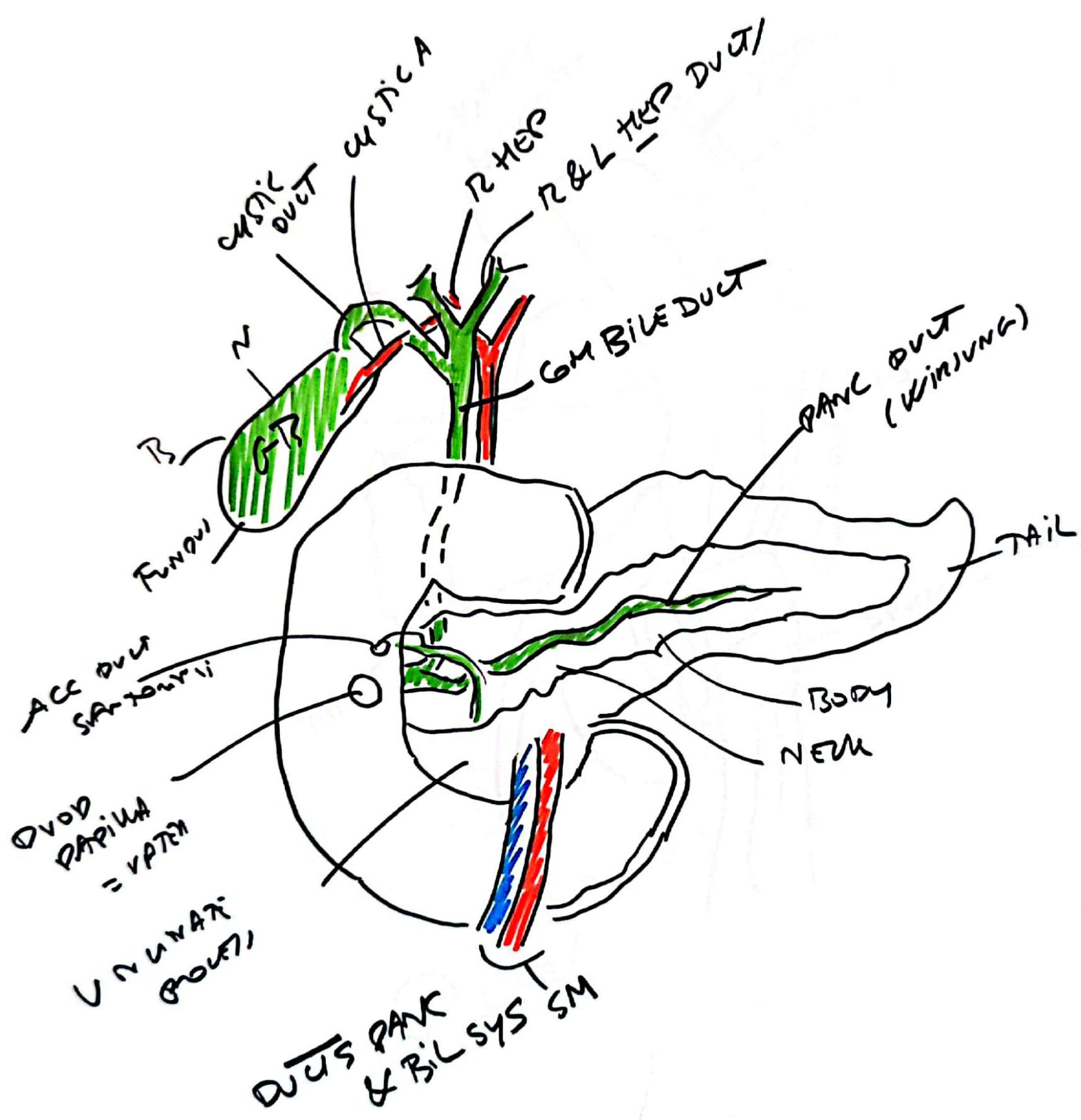
/// LESION SAC
 /// GASTRO SAC

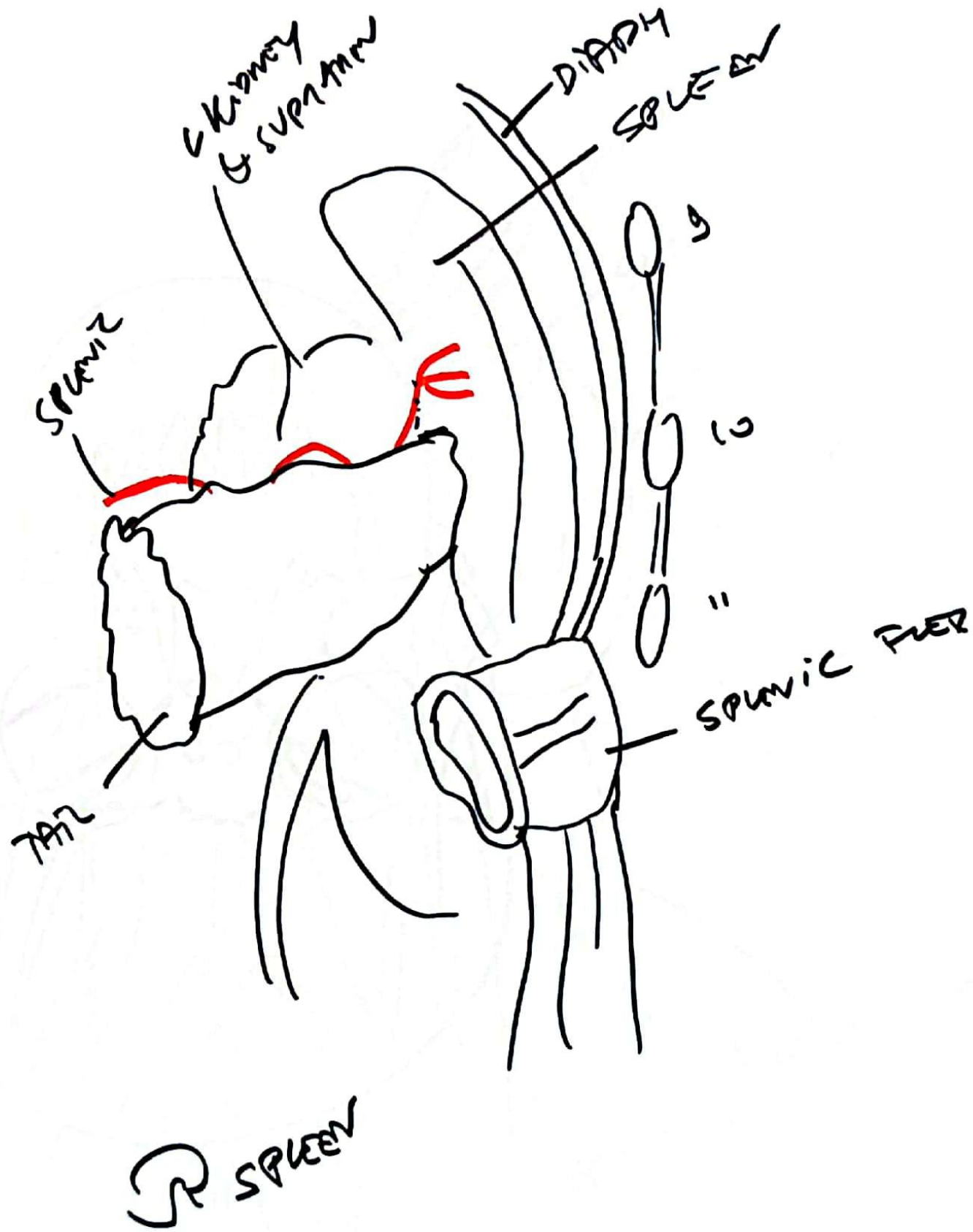


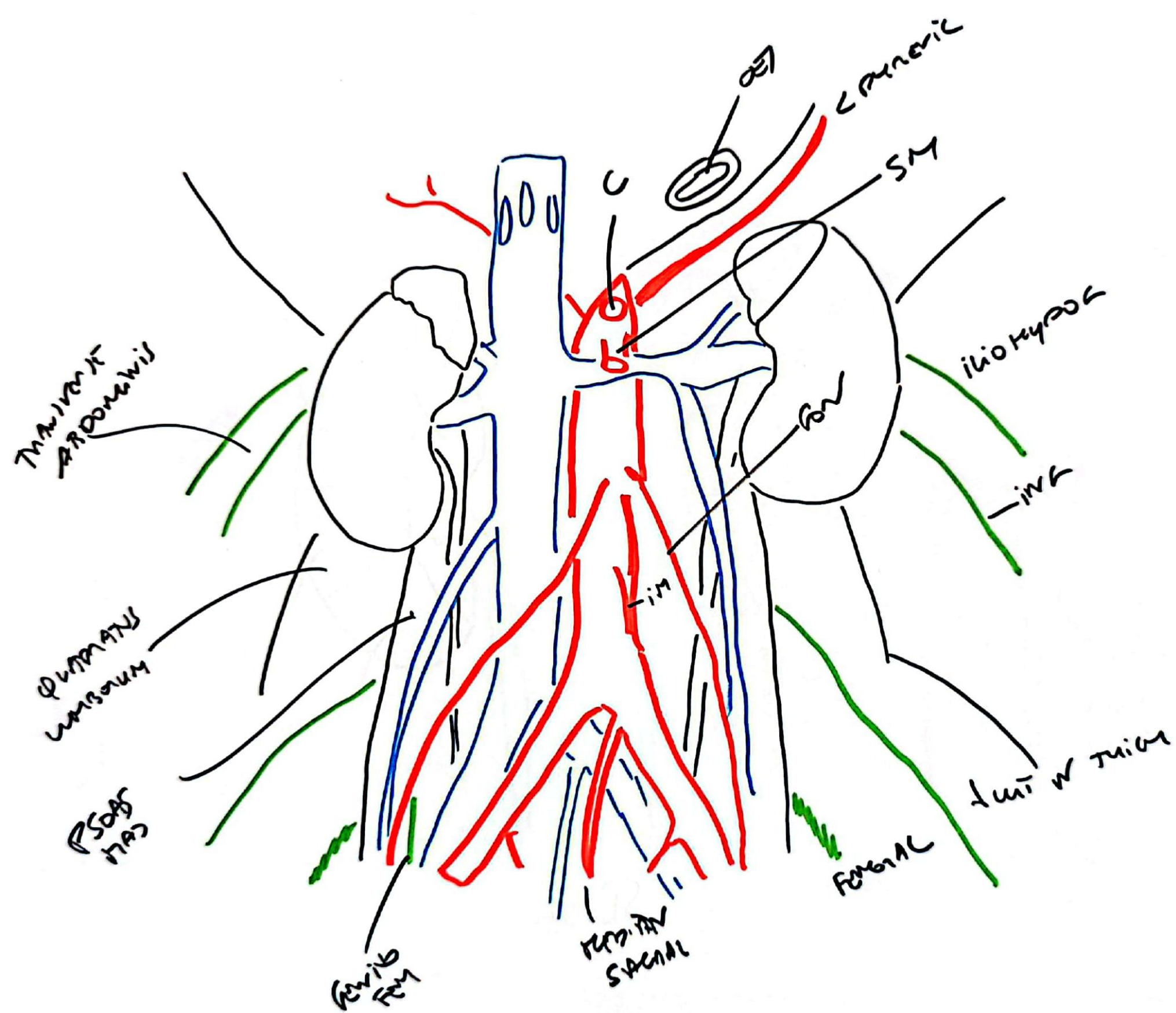


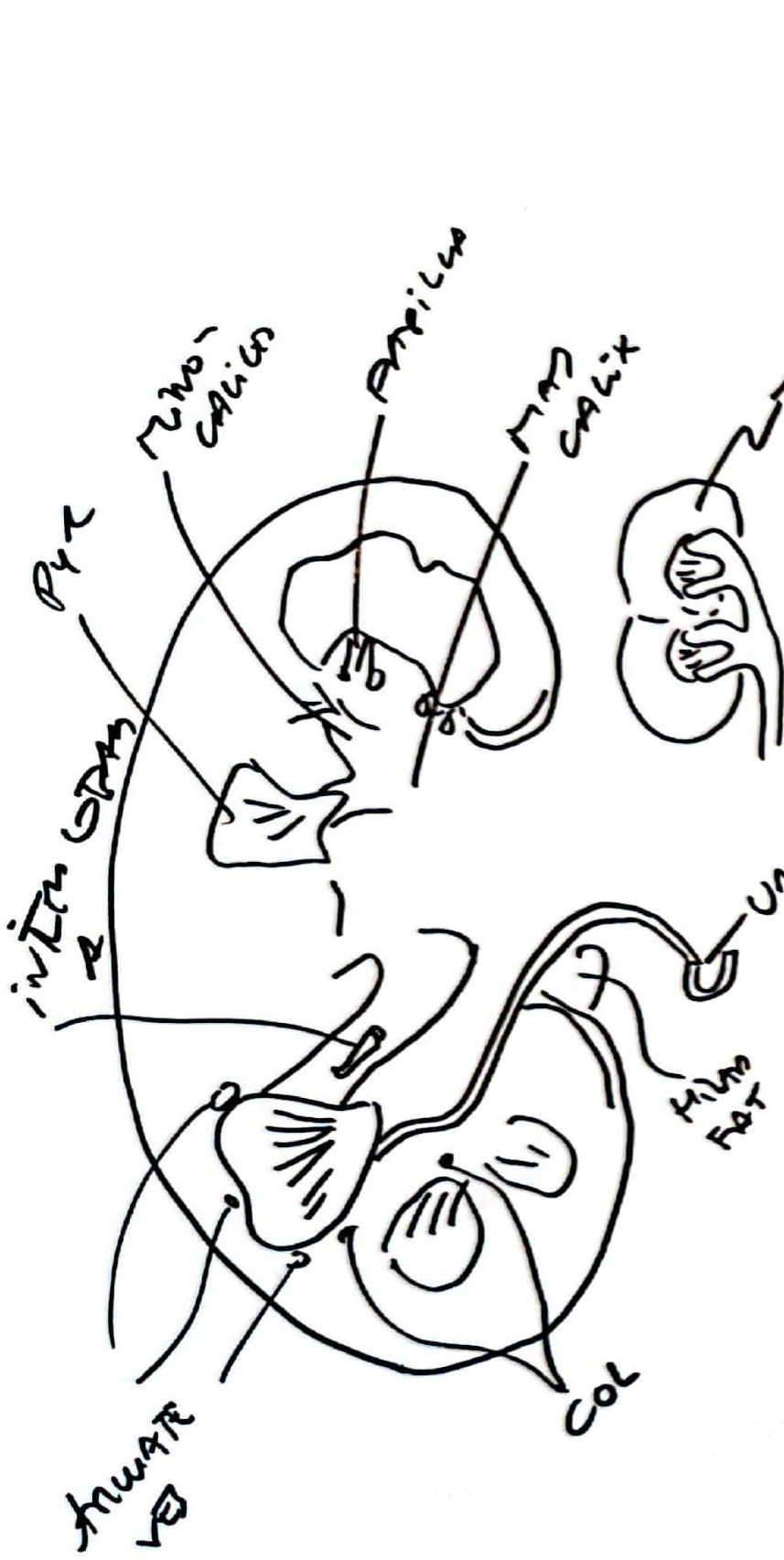




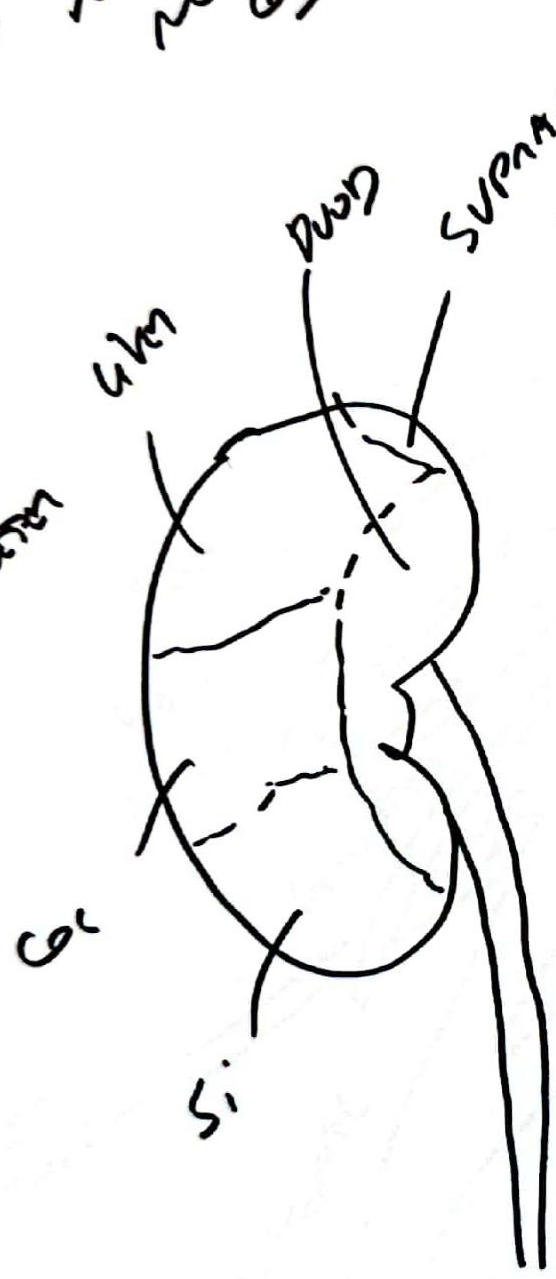




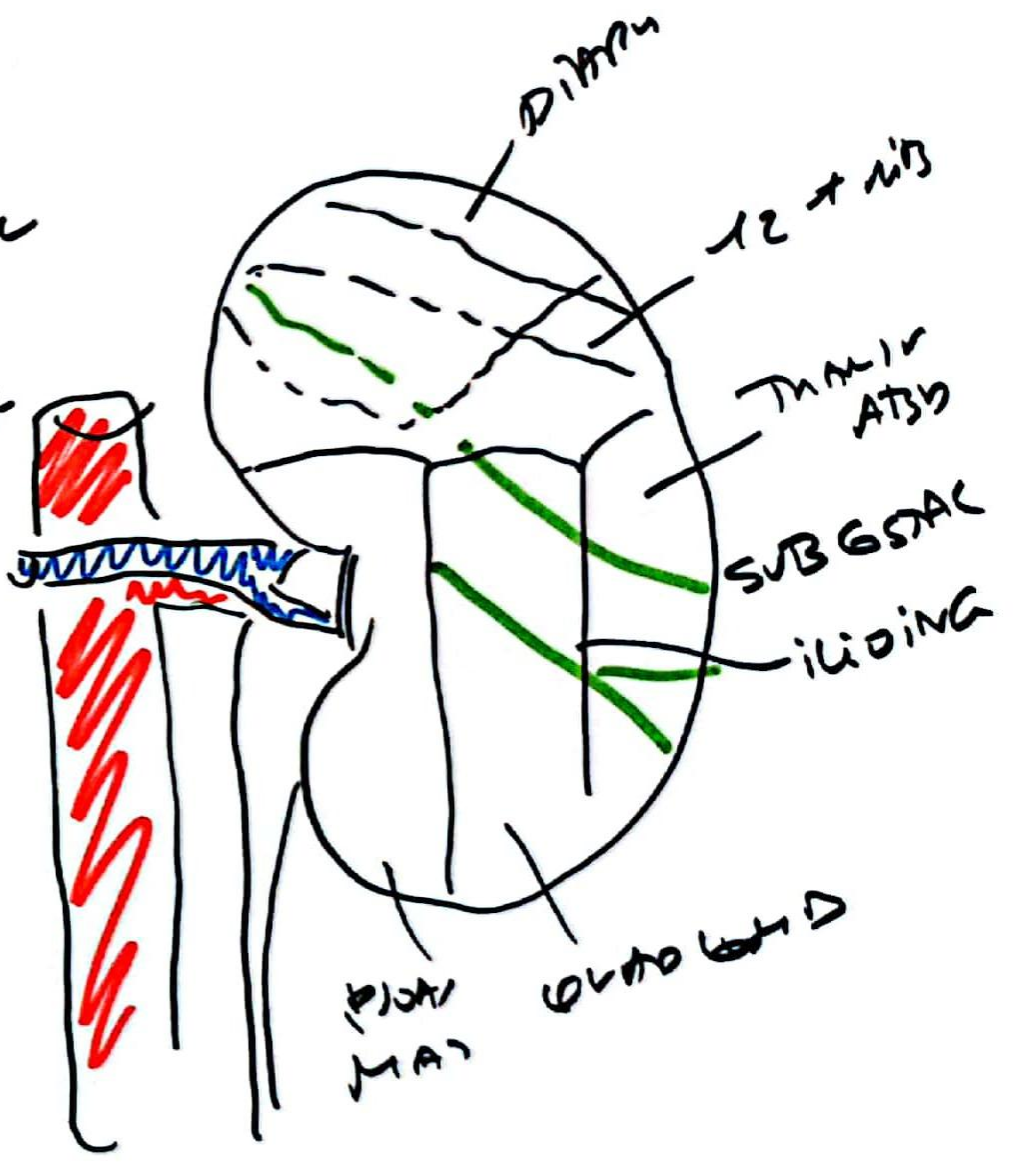






SHOWS HOW
NEW GUMM
ENTRIES OF
JOINTMENT
FUSED GBE

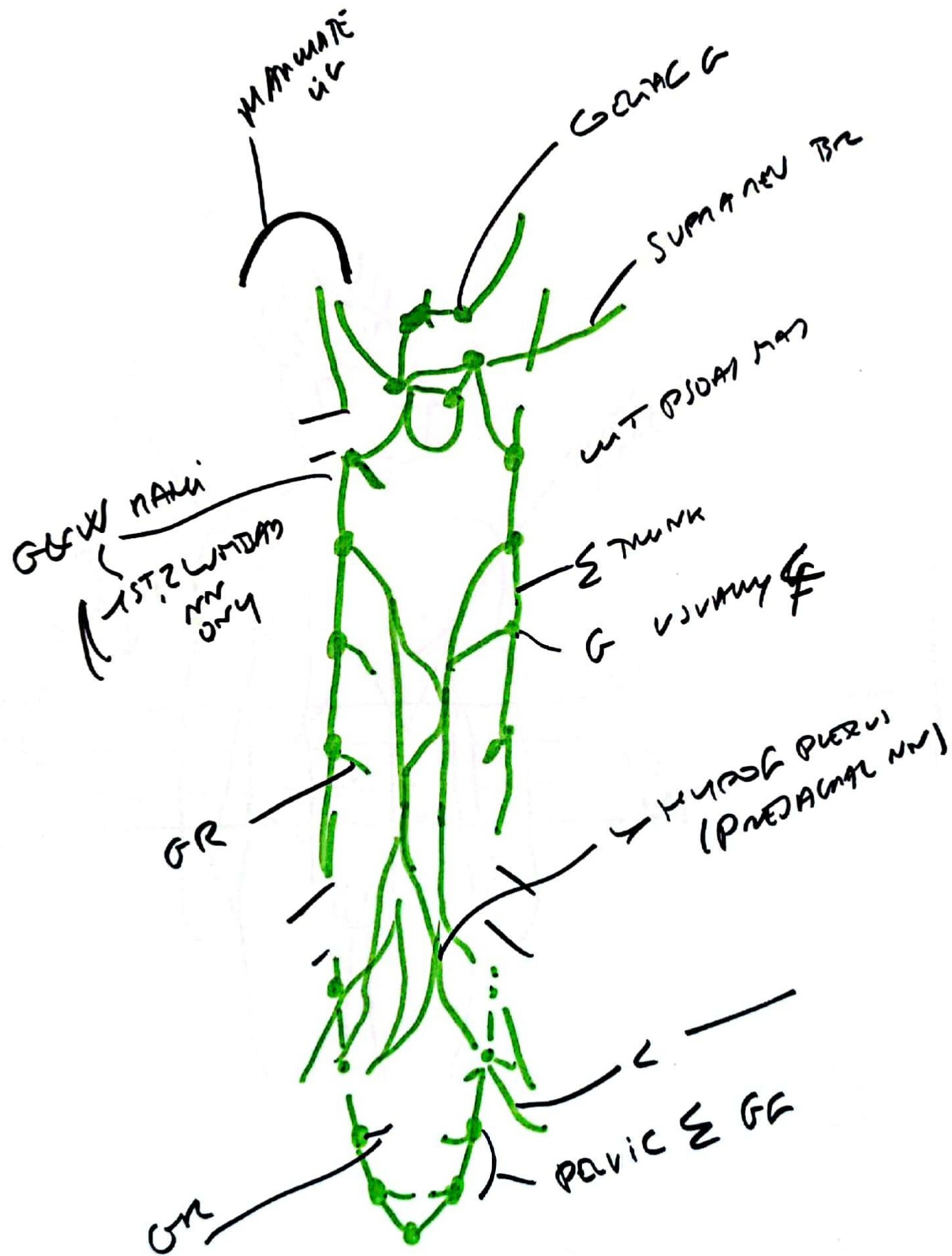


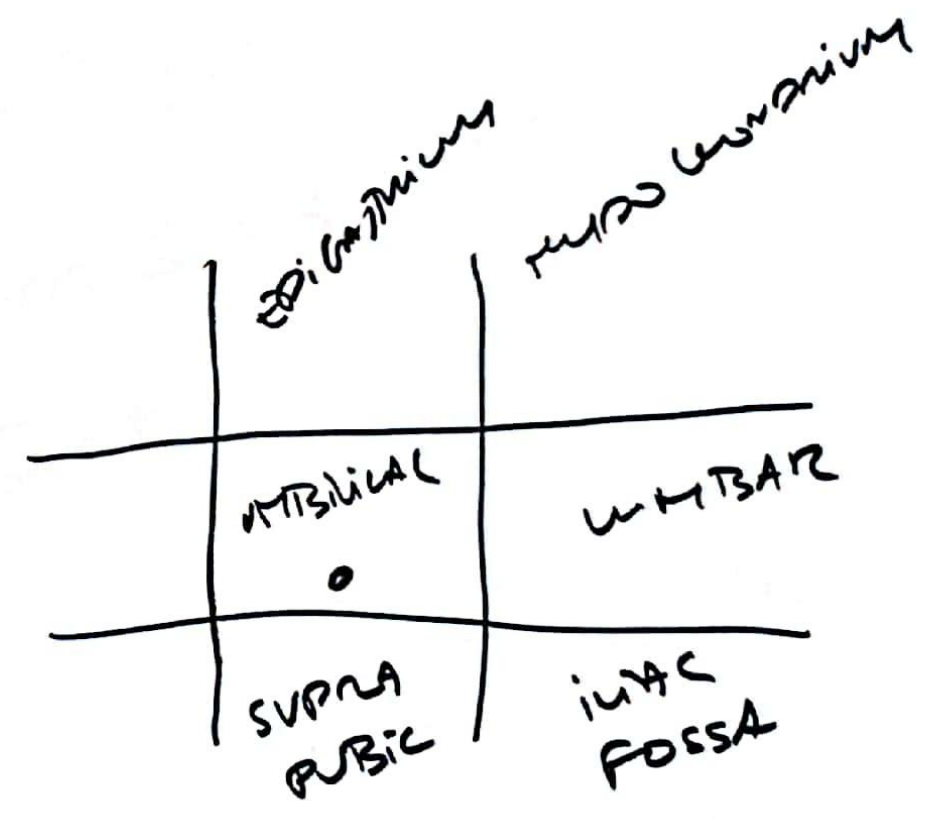
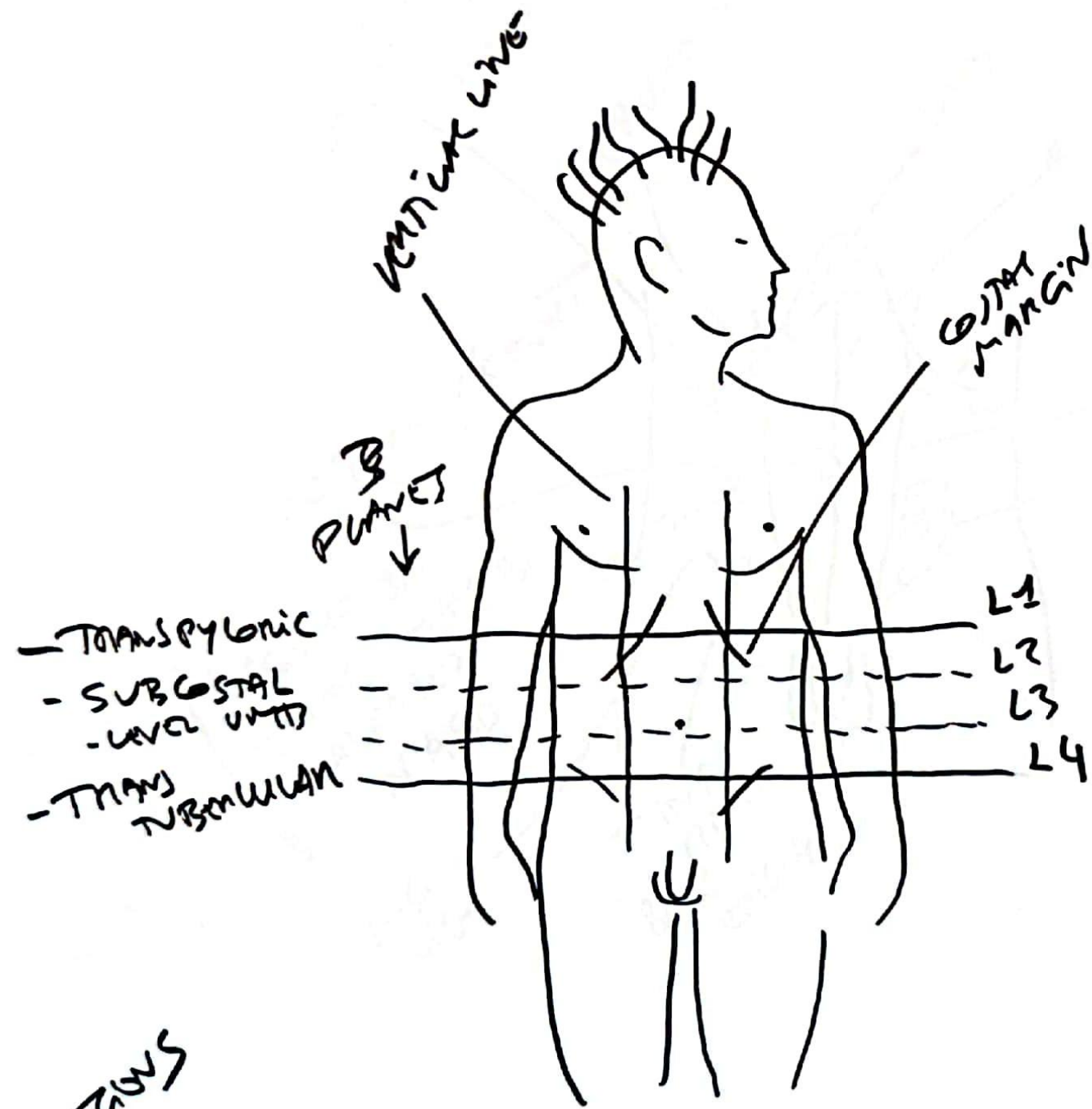
2 R



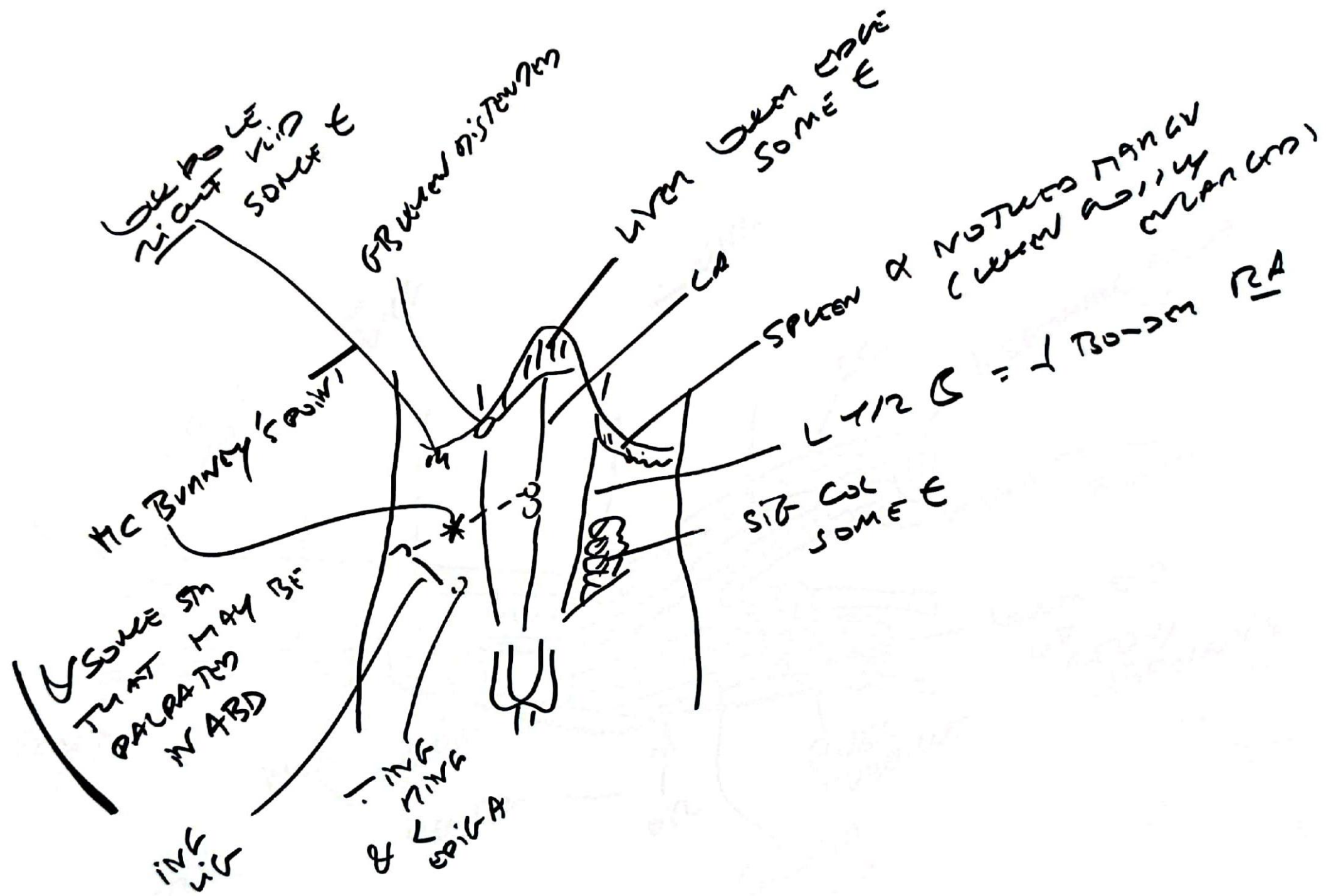
TR

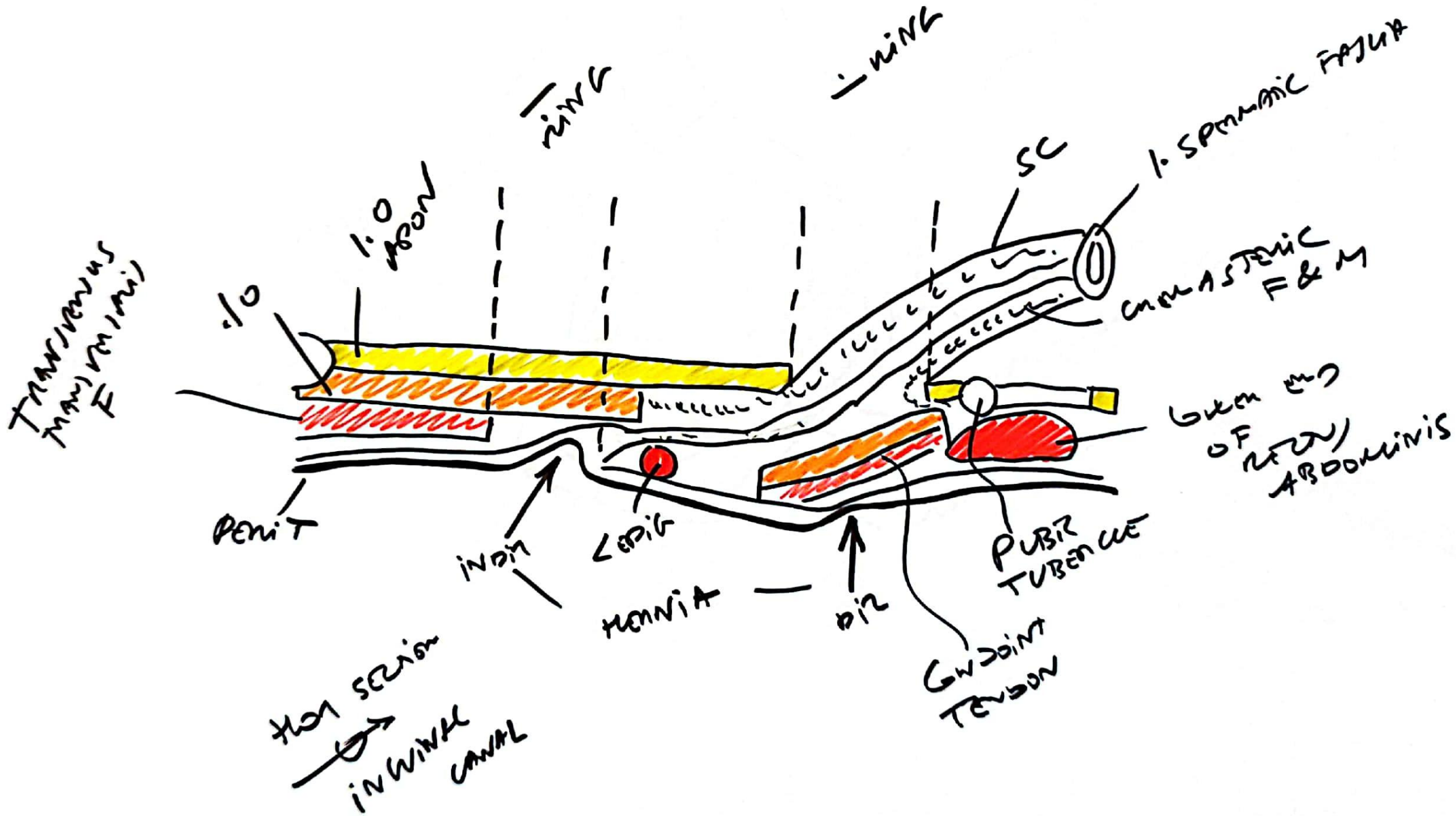


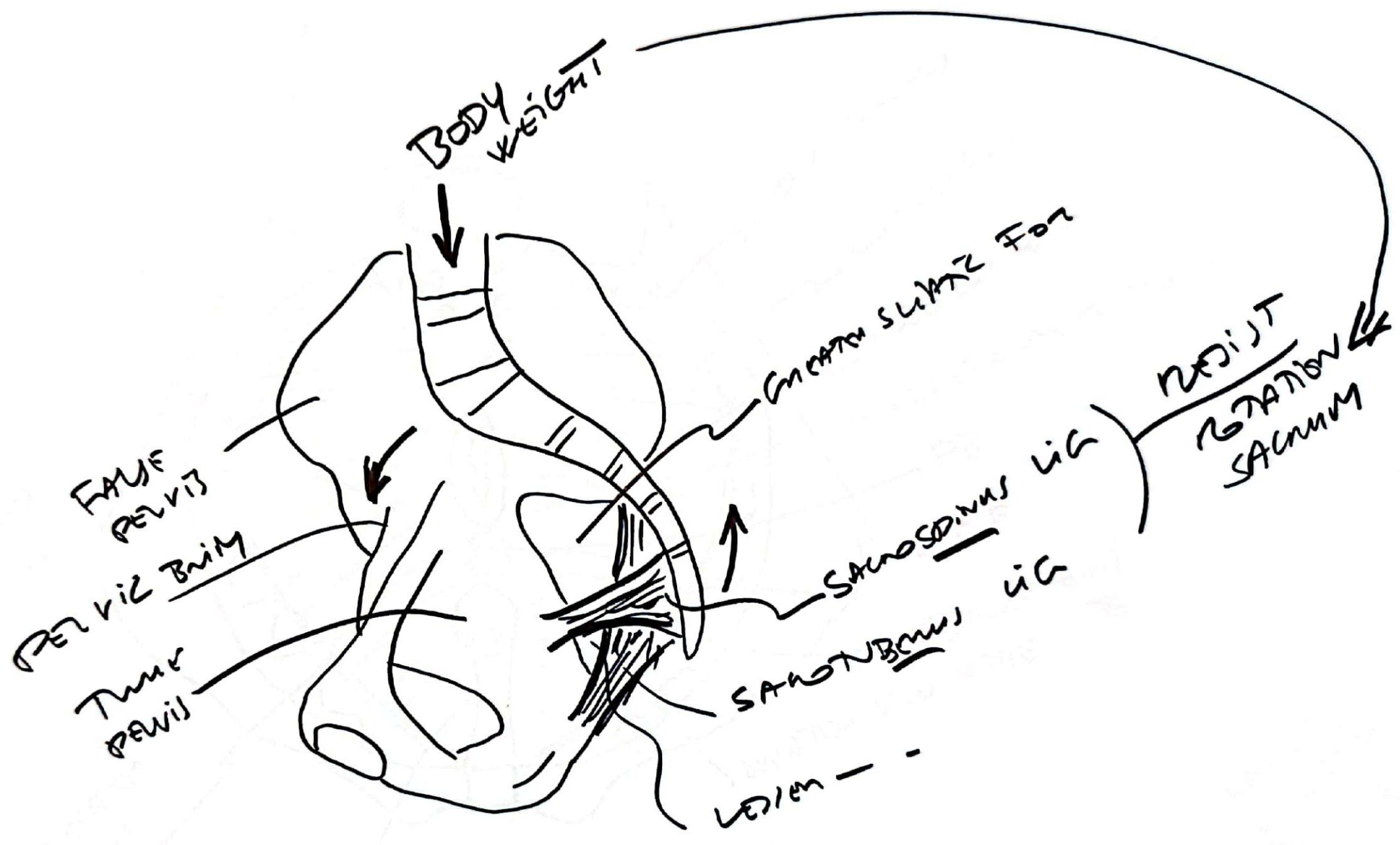


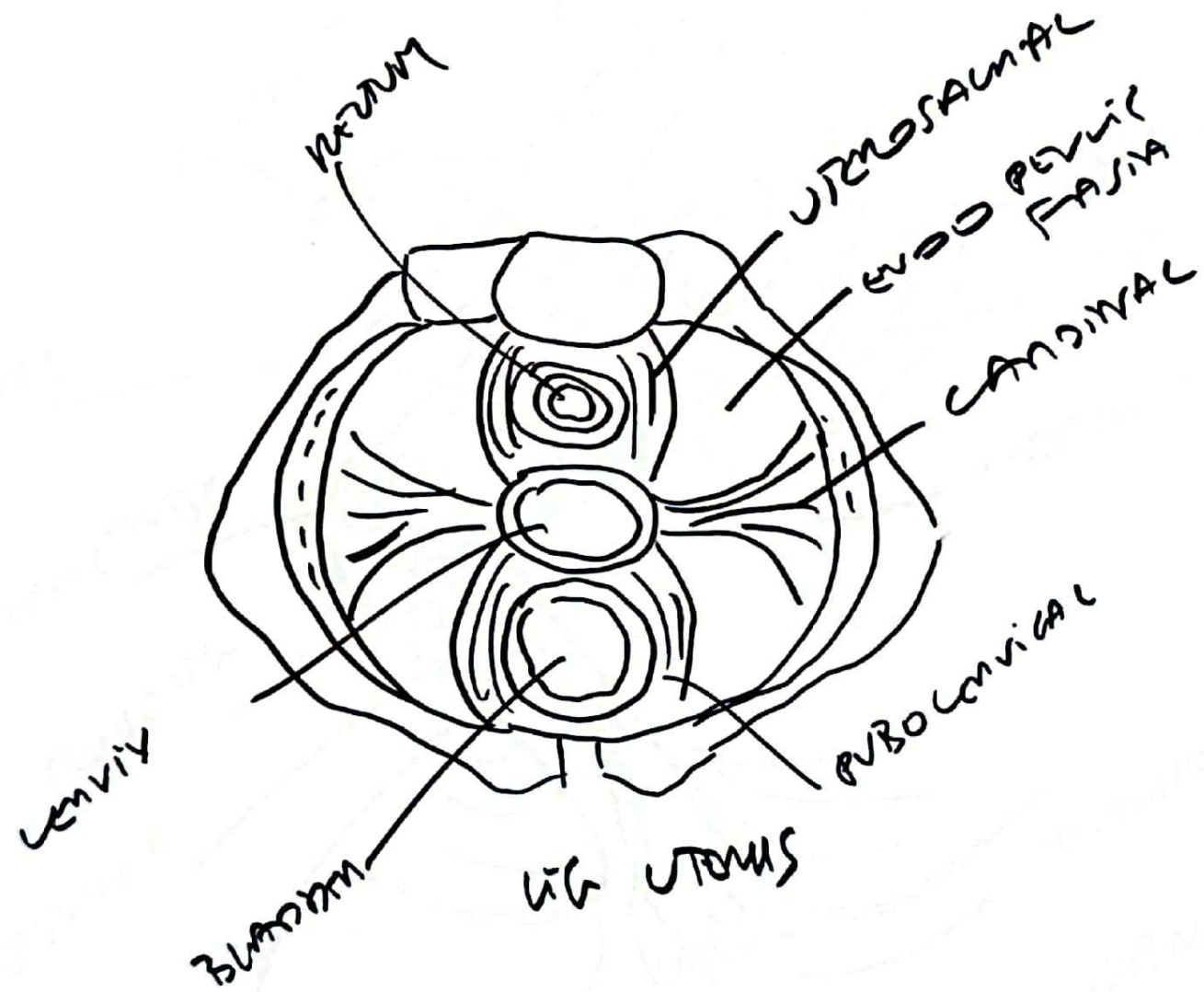


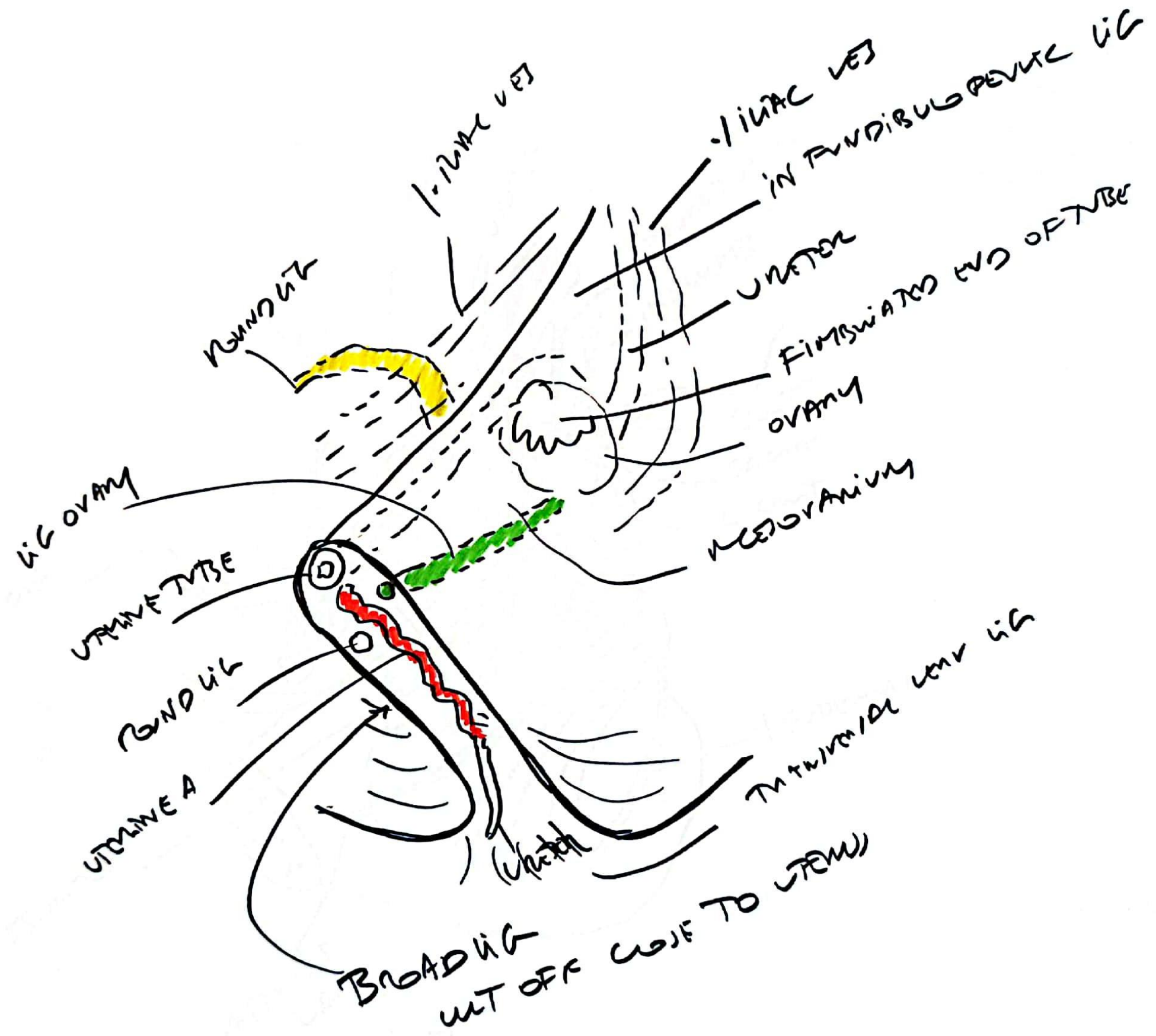
9 REGIONS
ABSD

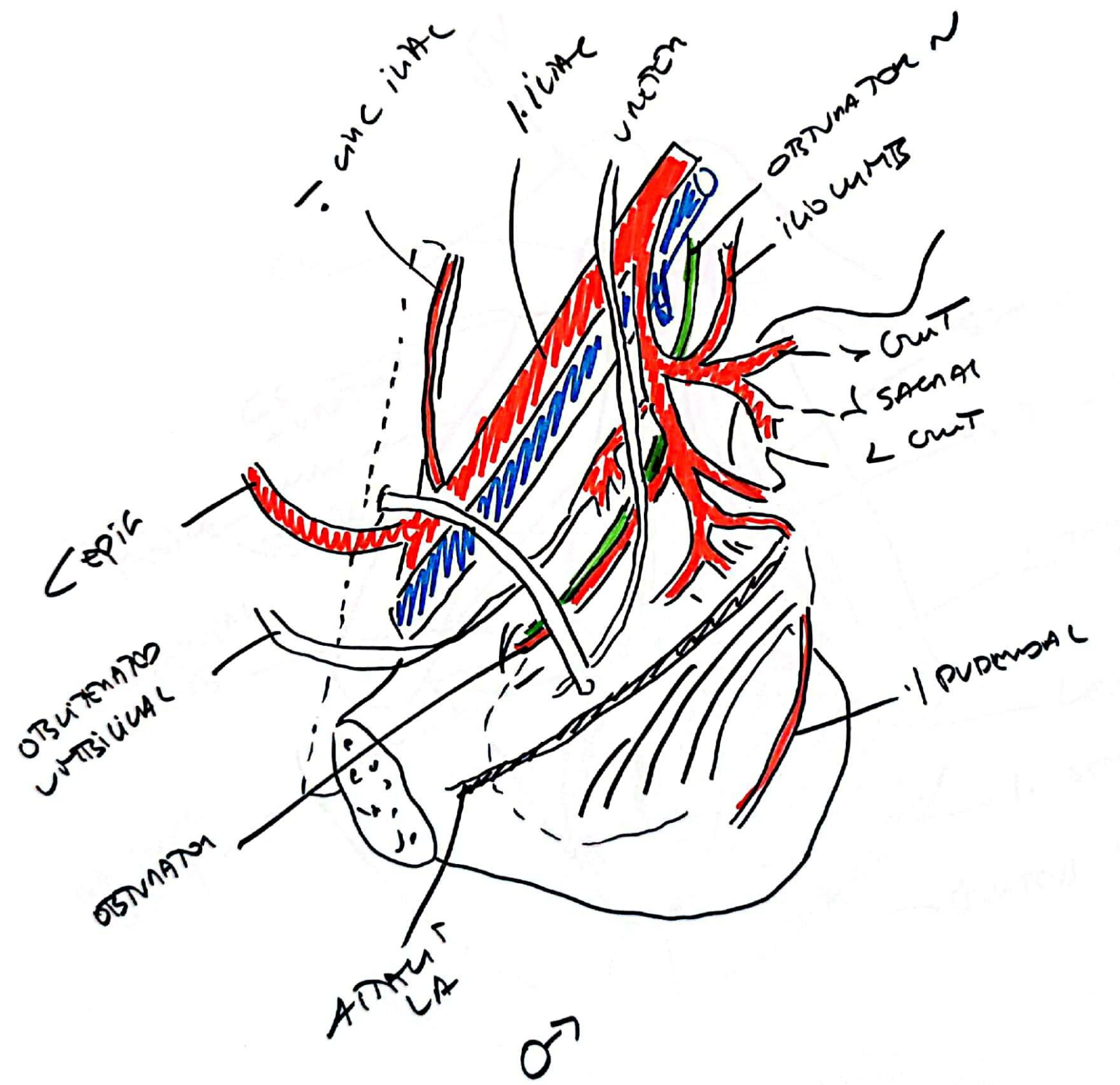




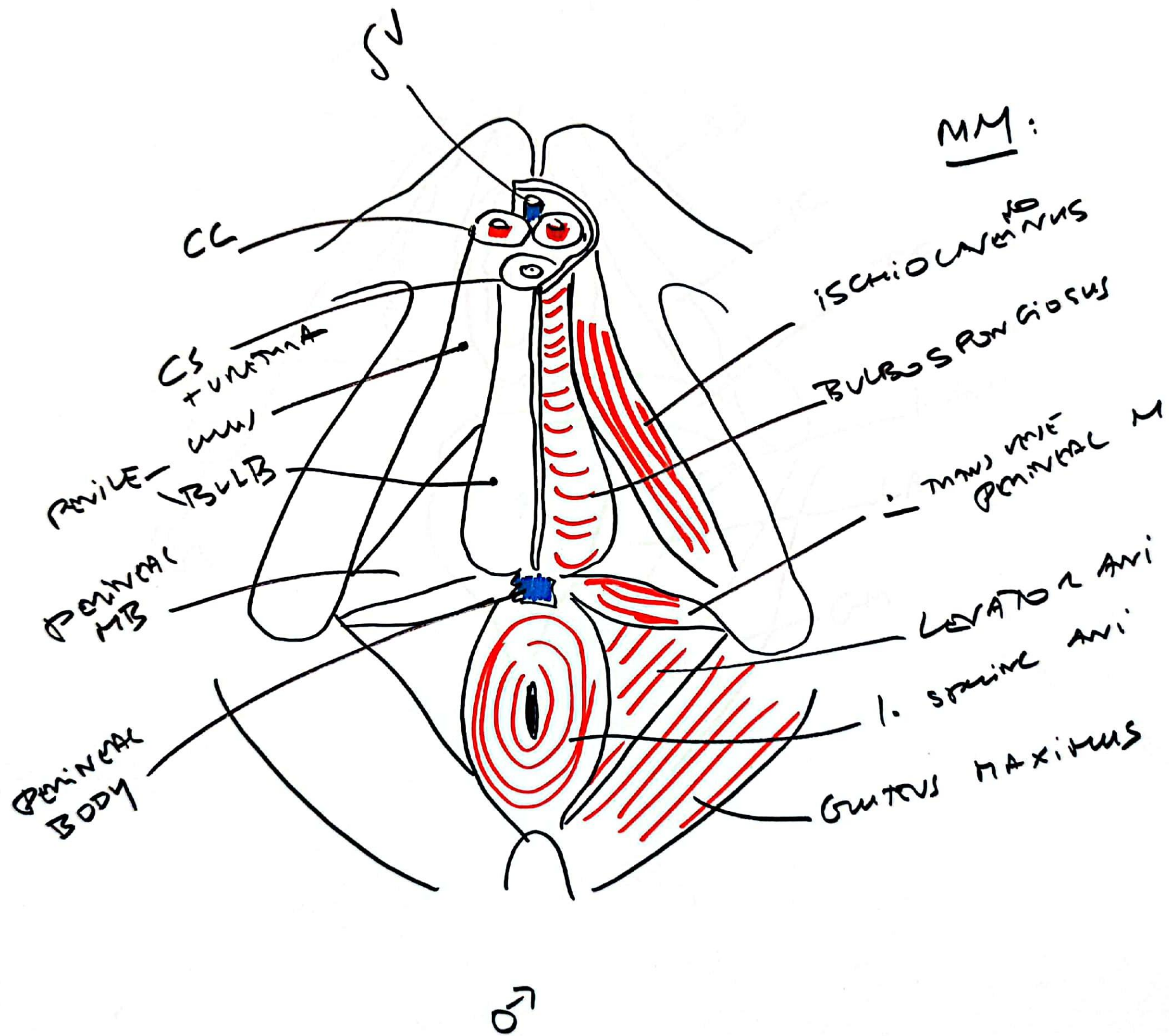


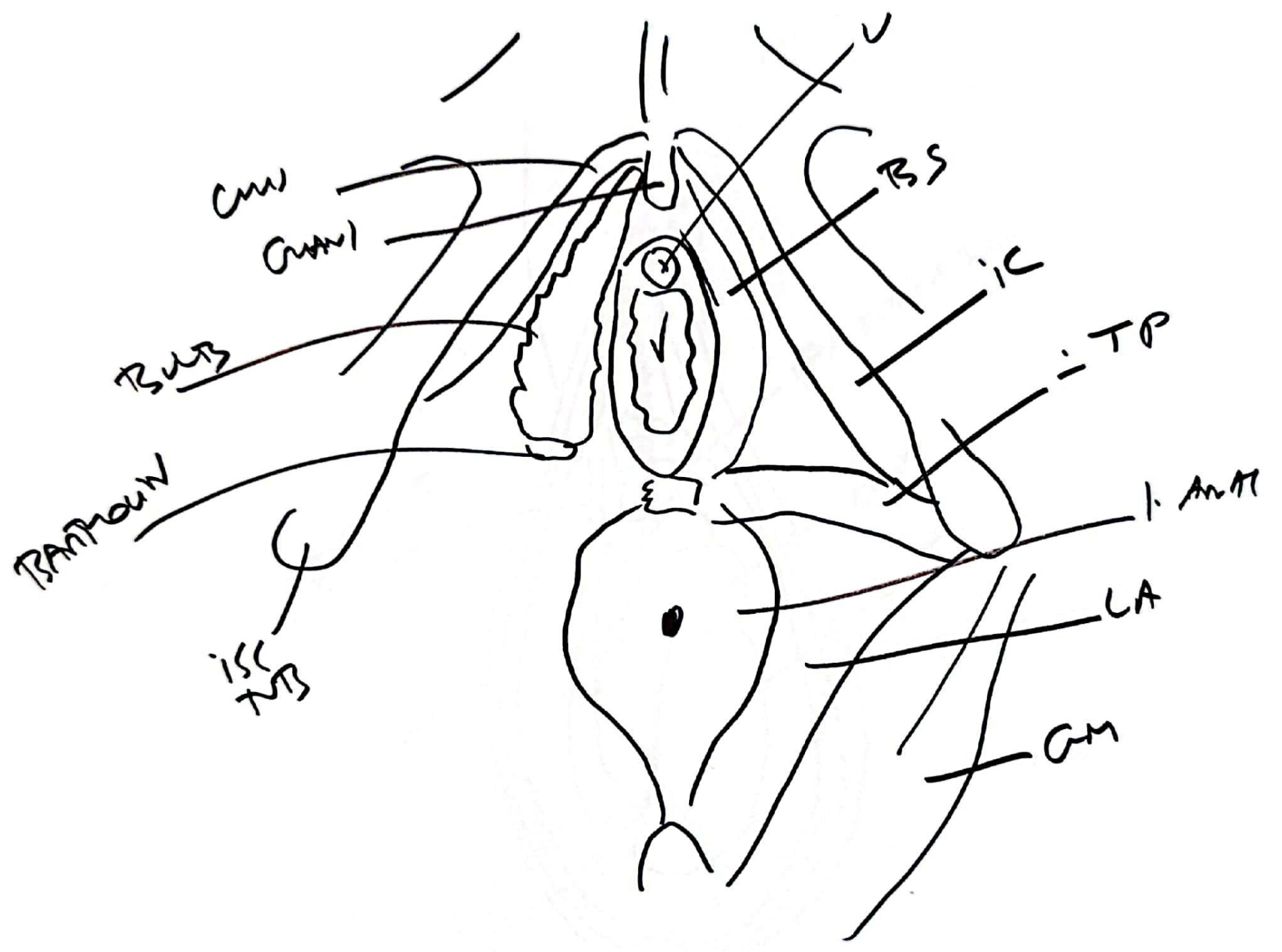


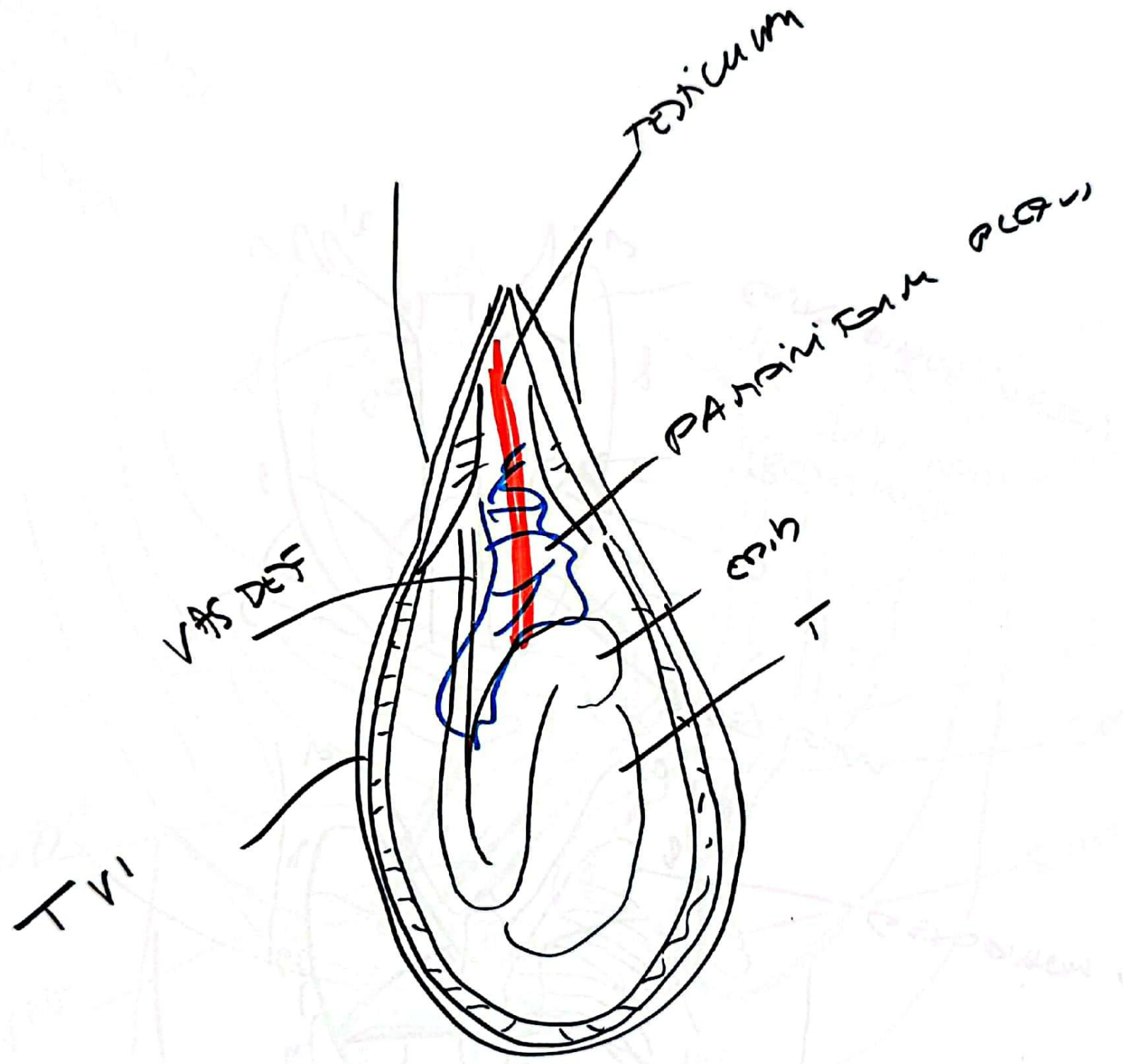


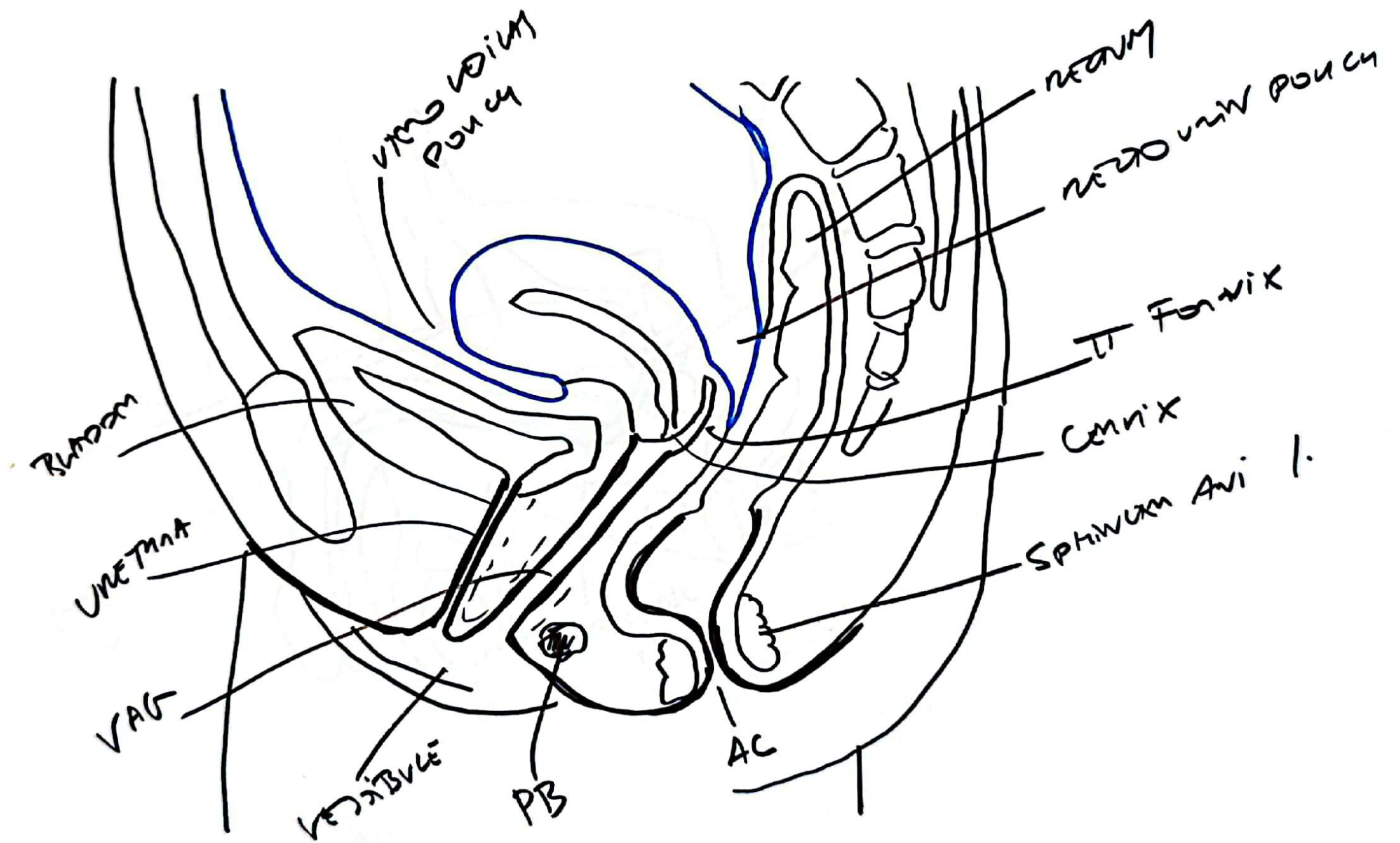


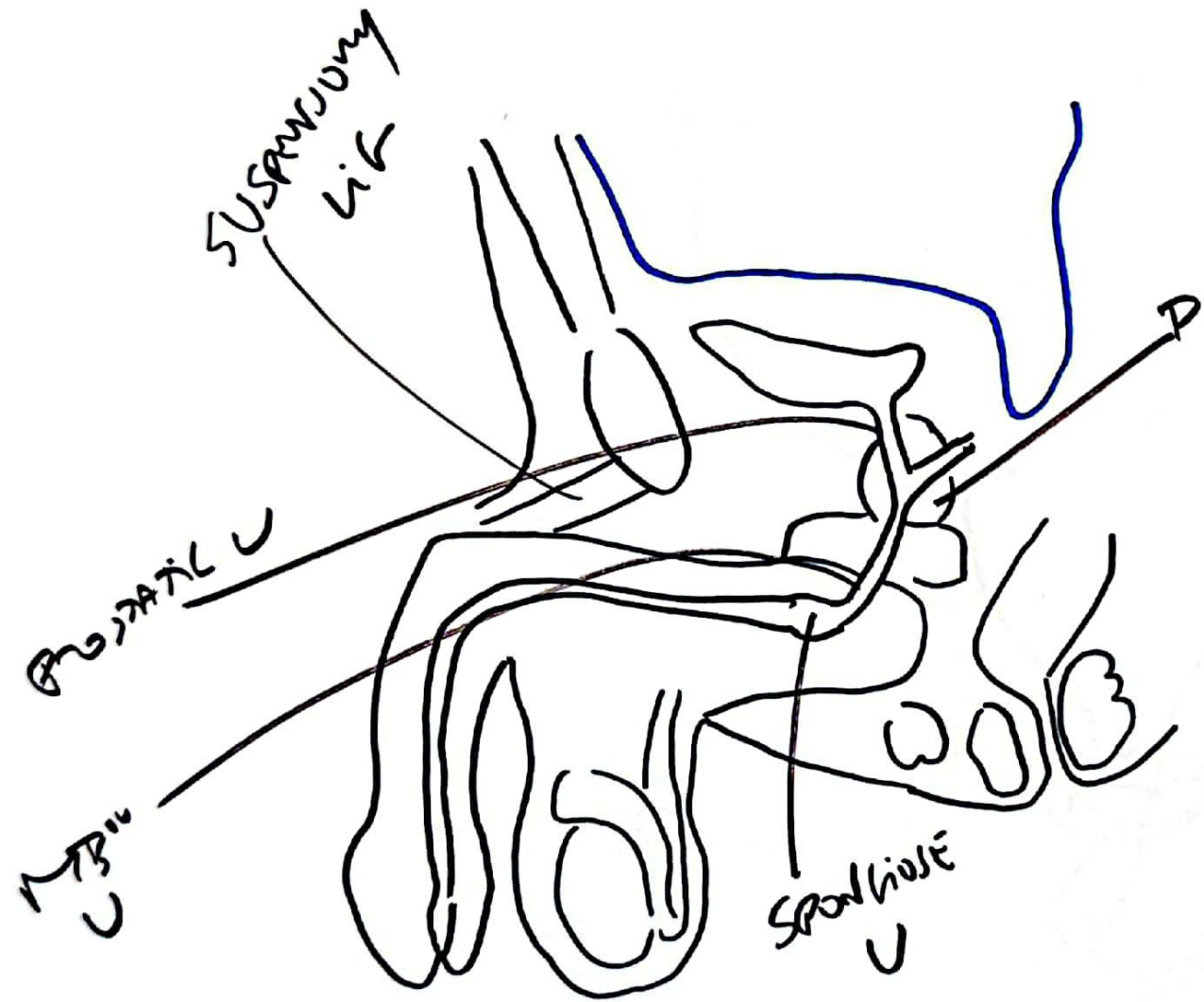
1. ...
 2. ...
 3. ...
 4. ...
 5. ...
 6. ...
 7. ...
 8. ...
 9. ...
 10. ...











UNTER

UNTER

TRICOR

PROTATE

SPINE
UNTERNAE

UNTERNA

