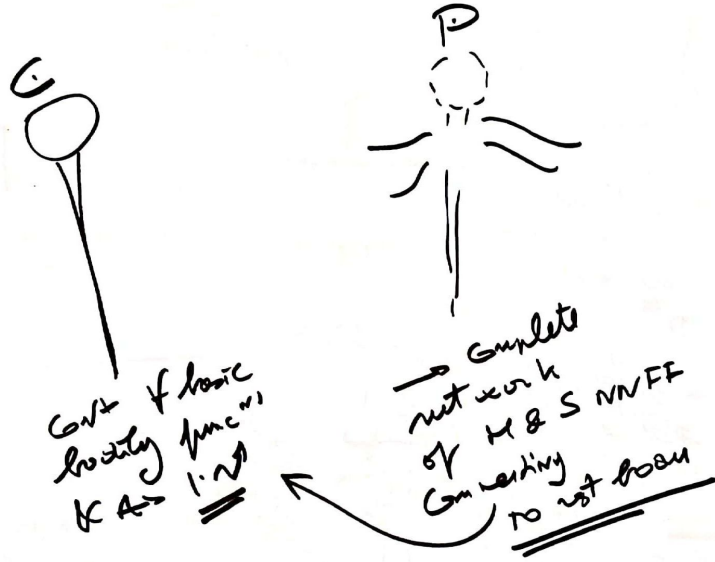
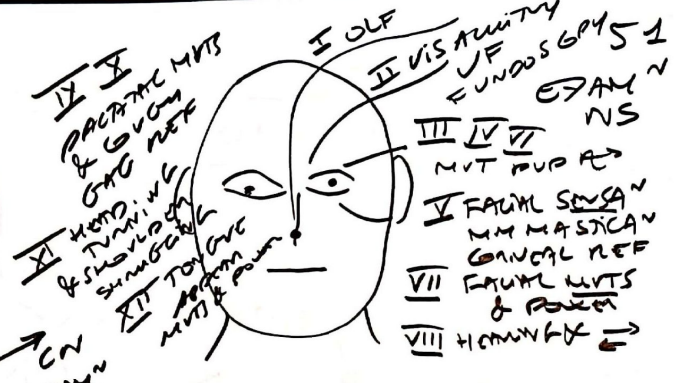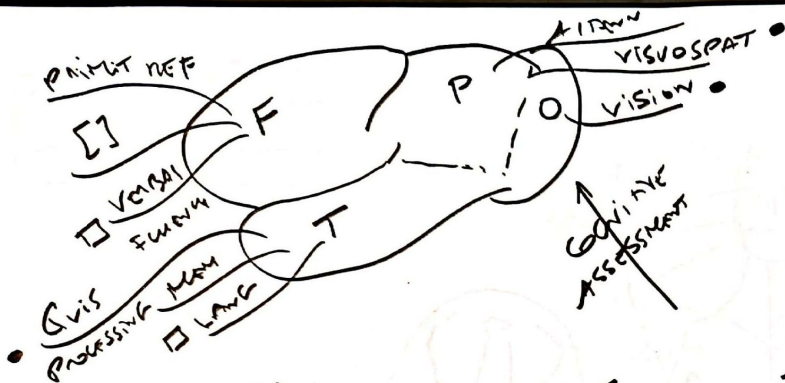


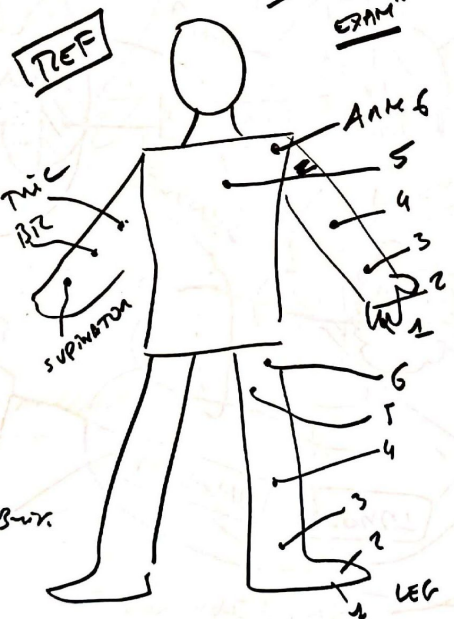
APPROXIMATE
PT WITH
NEUROLOGICAL
PROBLEMS



SDS	STs	S _g
- STROKE	Sudden onset weakness/ sensory ↓ / speech / ↓ CS	LOC / UMN / SP ↓ / LMN / SP / SP
- MS	Headache / photophobia / Nausea / Vomiting Skill marks often SUBT onset	LOC / CN / UMN / SP / STN / motor may occy have focal
- EVC	↓ delirious / odd behav, down as / maybe mnc	Rarely any focal, LOC Behav / Cognitive
- NEURODEG	Slowly prog w/ obs typy mnt & cogn	Cognitive & SP w/ V such as dementia parkinsonism / UMN & LMN S
- EPIL	infrequent typically w/ brief csm blot odd behav attacks	Most cases NO UMN / LMN S Between attacks,
- MS	episodes of brief feeling / mnt cut via upset that initially come & go w/ some d/le signs	Dep site from typy ⇒ vis acuity eye mnt cut, CN, UMN & SP / SP
- MYOCL/ - IOPATHY	For A + SP dif weakness +/- use arms / bladder spms +/- SP ↓	typy UMN UETS +/- LMN ANM, + SP FAT
- NEUROPATHY	SUBT ↓ pain & sensory w/ UETS	LMN & SP ↓ IN AFFECTED
- NEUROPATHY	SP ↓ w/ weakness cut A of CS & UETS on LOC	LMN & SP ↓ EXACT NATURE
- NMJ DISORD	FATIGABLE WEAKNESS + inton diplopia / ptosis / SP	LMN N BUT + SP weakness - NO SP
- MUSCLE DISEASE	DIF GETTING OUT ...	UPON PROX WEAKNESS TP WEAKNESS + N RARE & NO SP ↓



- MOTOR**
- OBS^N**
 M WASTING / HYPERTOMY
 INVOL MVT
 FASCICULAN SCMS
- TONE**
 CPD & LMN LES
 & CBL OR LMN -
- POWER**
- 0 FRICTION
 - 1 CHARTY
 - 2 ACUMIT
 - 3 - R
 - 4 - R
 - 5 N
- GORDMAN**
- 1 0 + + + + BUT.
- PHANTOM** →

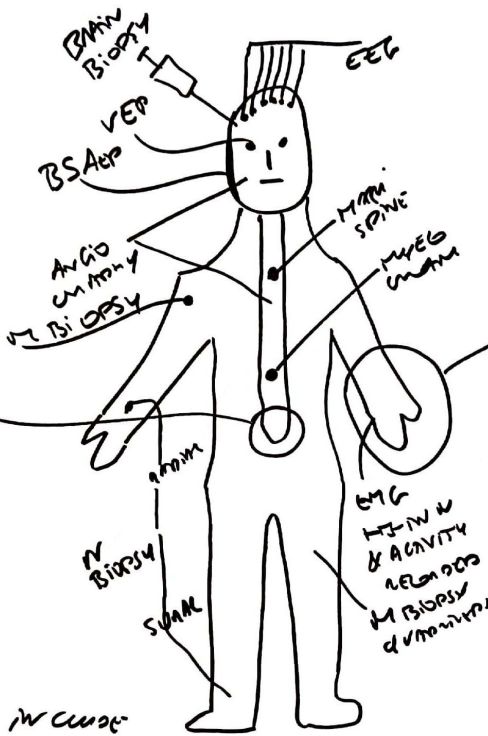



- SENSORY**
- OBS^N SCAM** (KIN N)
 LIGHT TOUCH GTON WOL
 PAIN PIN PRICK
- JOINT POSITIVE**
 LOVE DIS → PAIN
 A 1-4, 6 2 1 3 4 5
- VIBRAV PERCEPT**
 THRESHOLD WITH
 NINE FOUR QUART
 STIMULUS DIS → PAIN
 A 1 5 L 2 3 4 6
- ⊙ HOT (COLD) TUBS
 (OBS^N)

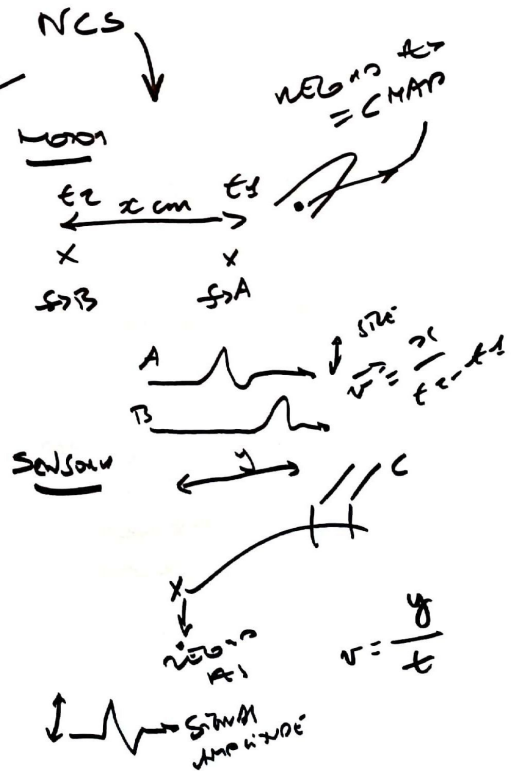
c = EXTENSION - N A →
 except in young children

q = FLEXION - N A →

HISTORY & EXAMINATION
 GENERAL
 NEUROLOGICAL

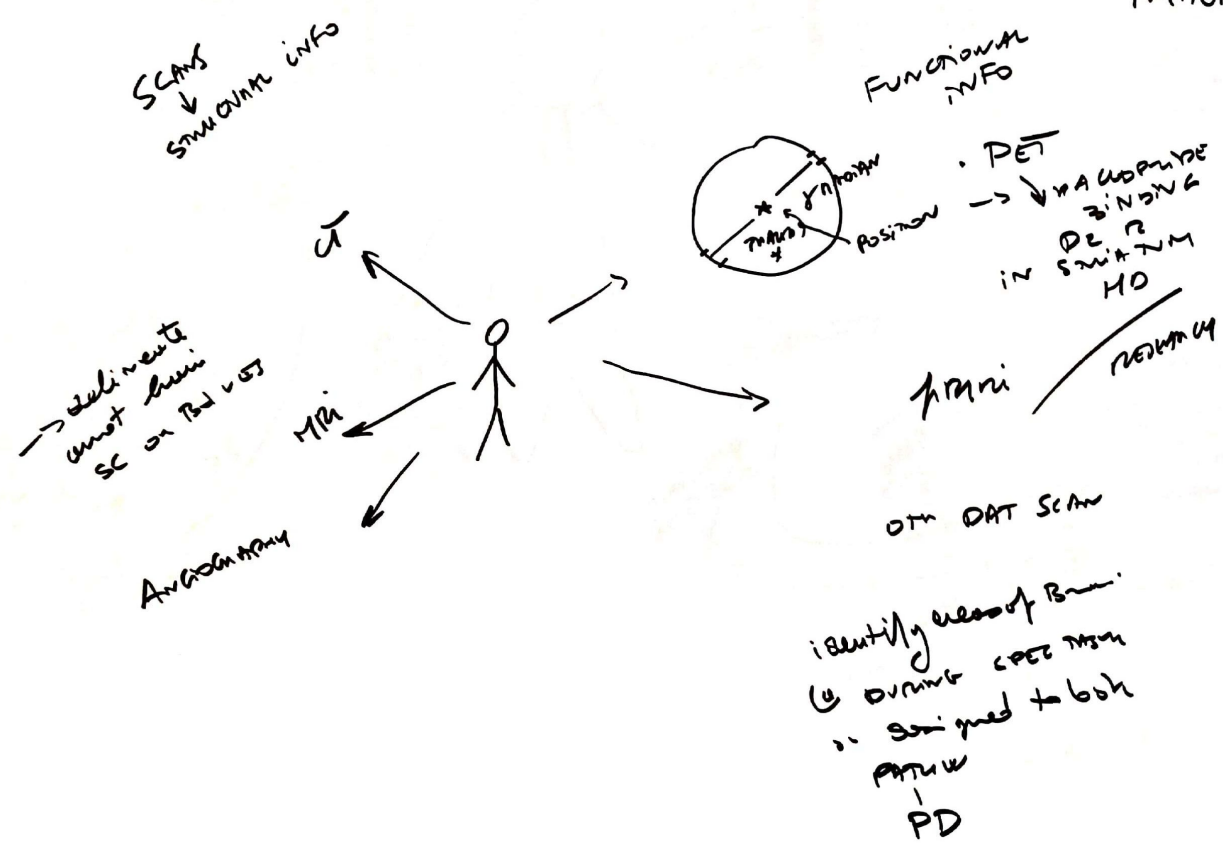


IMAGING
 SKULL XRAY / CT SCAN / MRI SCAN
 INVESTIGATION
 SPECT / PET
 NEUROLOGY SCANS



FBC
 ESR
 RENAL F
 G
 M
 CREAT
 LE TO L

GMN / CO
 MIND /
 CORTING GROW
 DMS / RL
 GROWTH TEST
 UNIT OF M...



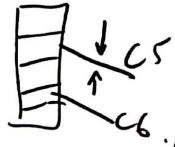
F501 DRP
 GM PAINFUL
 site ↓ ↓
 on distance
 + 6/12 root
 ✓ Fusion + erosion

⊕ ⊖
 PARADOXICAL NUMBNESS
 PAIN ANALYSIS [SENSORY ST]

SUPRA SPIN (C5)
 SMI
 ON GRAD SIDE
 HORIZONTAL PP (X)
 ON G-
 (C5) (C6)
 BUT MAY INCLUDE SD
 BS
 DEPENDING ON SITE

PAIN IN NECK
 ABOVE &
 SHOULDERS
 ↓

MAXIMUM
 SDs



54
 CLIN
 DISORDERS
 SENSORY
 SYSTEMS

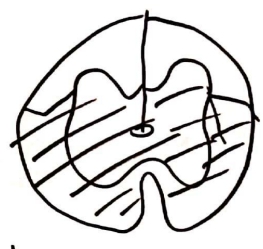
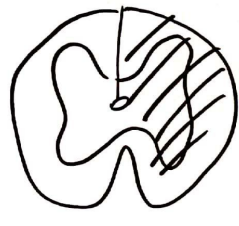
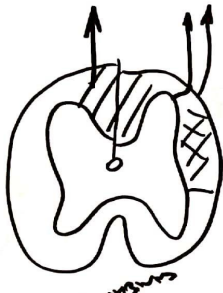
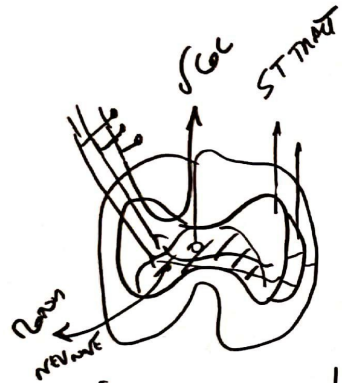
Compression
 from disc
 &/or long
 anterior rami
 (osteophytes)
 primary cause
 of sensory loss
 or sensory pain
 in some distal
 (e.g. sensory
 loss with the
 sharp distal
 down)

FOCAL N
 ENTRAPMENTS

TYPICALLY
 AT ELBOW

Wrist
 CTS
 Median
 ULNAR
 Fracture
 Vested
 hyposthenic
 division C6
 + interossei/Embiloids
 + many C6 in little
 & half of ring finger

34
SC SDS



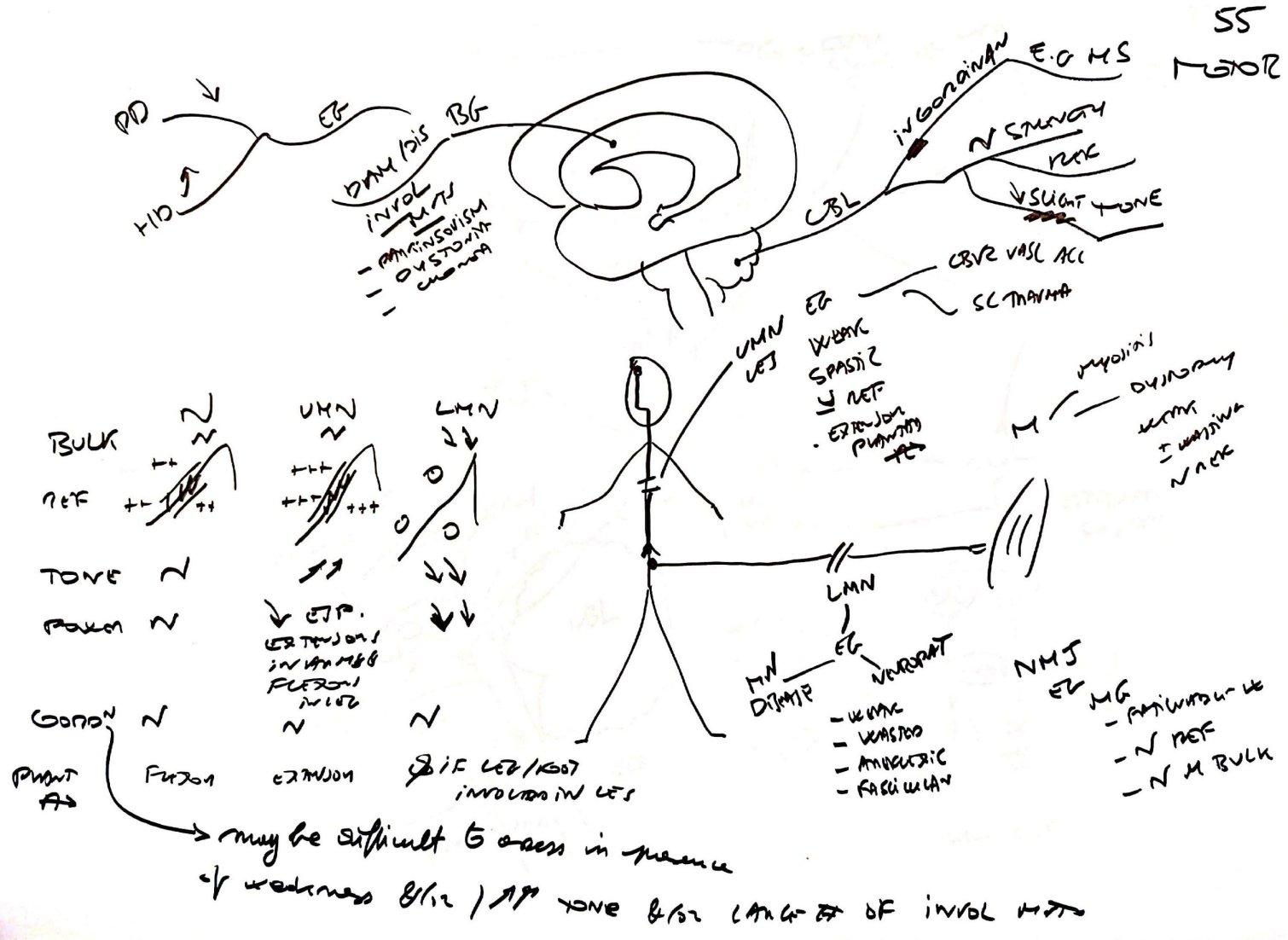
dorsal
ventral

PAIN & Θ

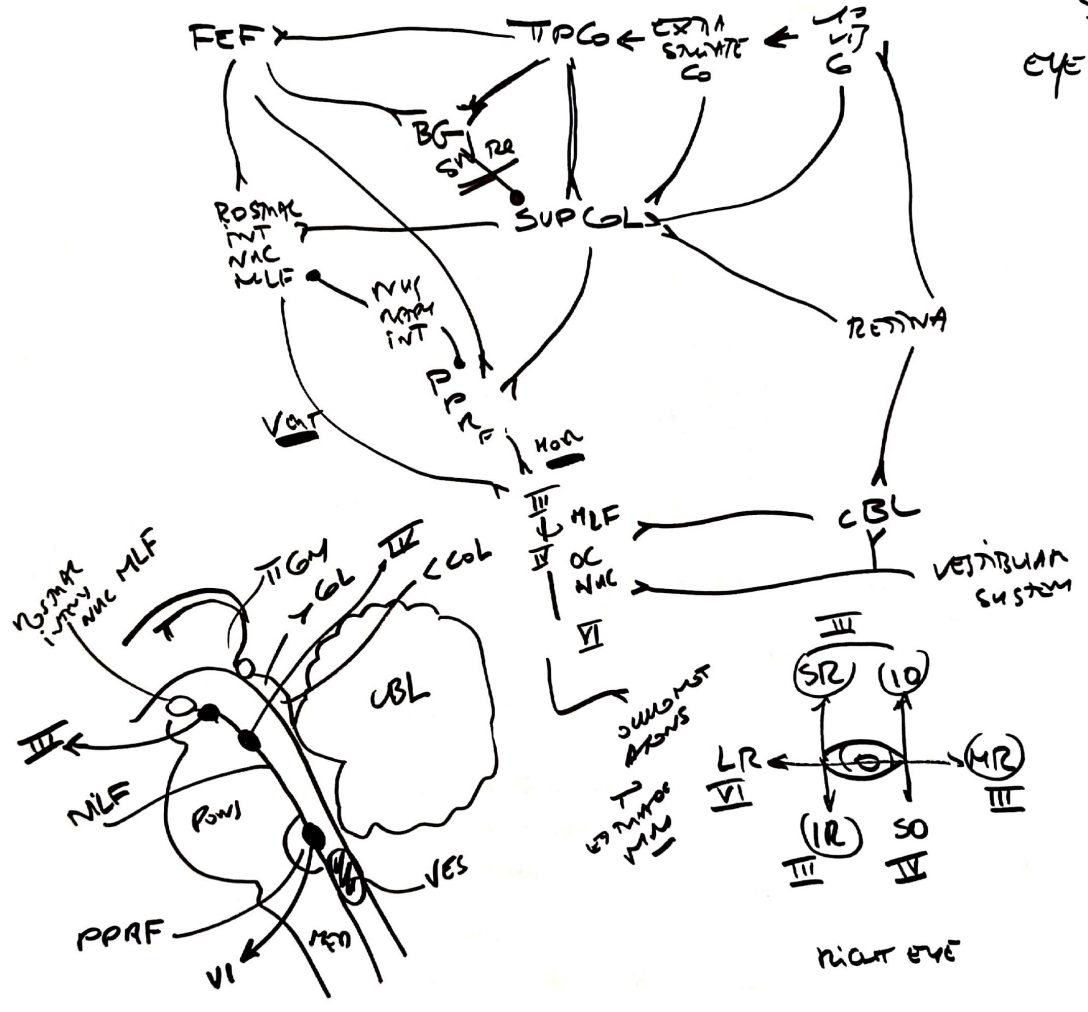
JOINT PAIN
↓
↓ touch
↓ light touch

	Synderhagren	SCDC vs Aunt	BROWN- SQUARD	ANT SPIN ANTERIOR
PAIN & Θ	XX	VV	XV	XX
JOINT PAIN ↓ ↓ touch ↓ light touch	VV	XX	VX	VV

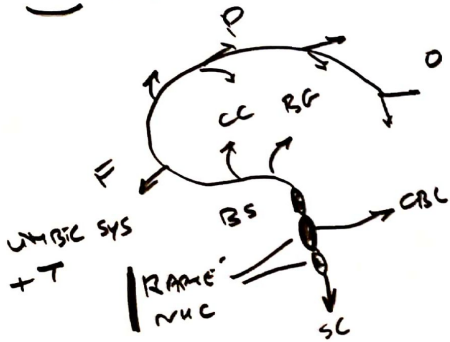
SS MOTOR




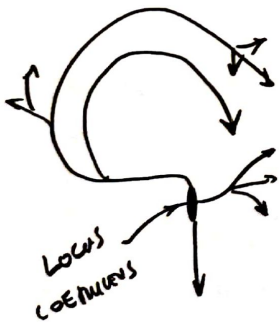
56
EYE MVTS



SHT / 5HT



NA

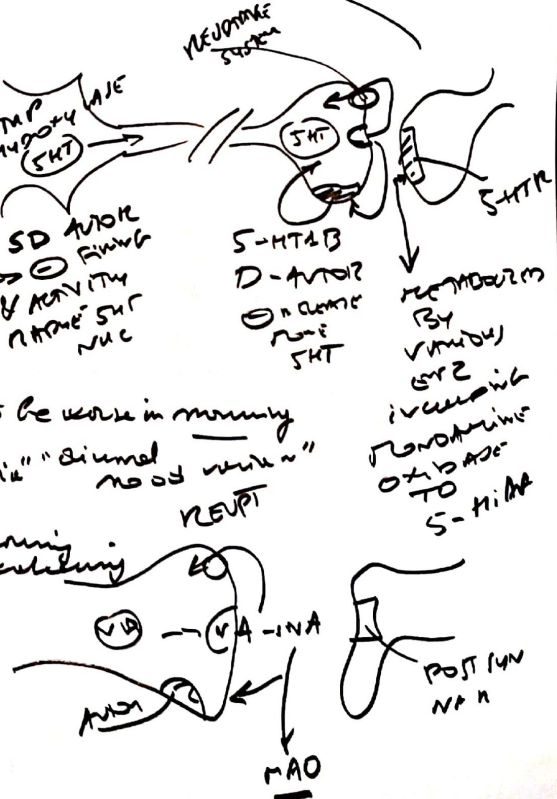


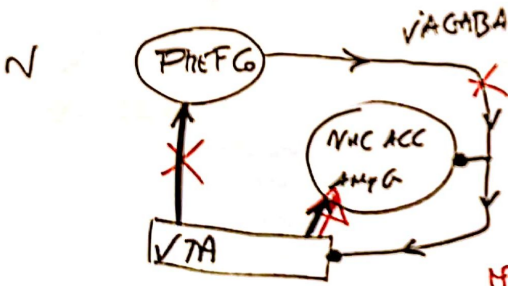
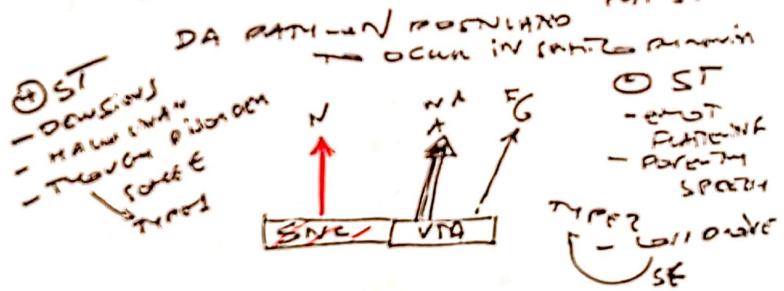
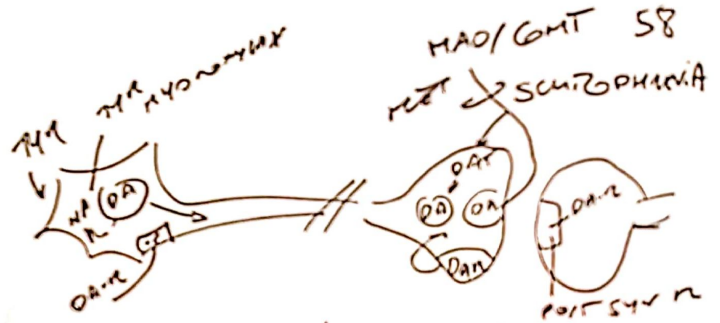
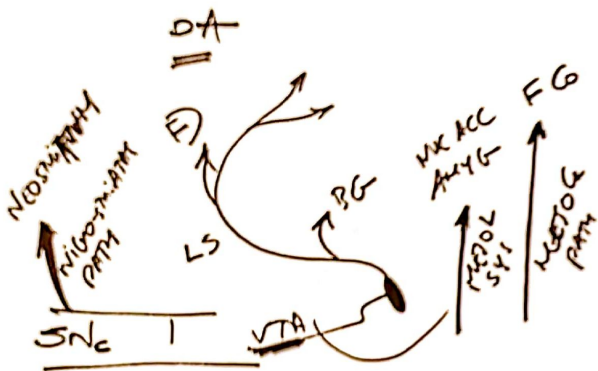
DEPU

- may comprise following
- lowered mood (feeling to be worse in morning)
 - ↓ pleasure life "anhedonia" "dimmed mood window"
 - ↓ appetite
 - sleep not (typical early morning wakening)
 - anxiety
 - feelings worthless
 - poor [] of men
 - suicidal ideas

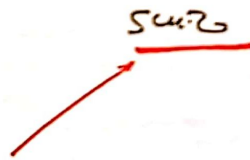
MANIA

- ↑ mood
- ↑ positive ideas & actions
- ↑ E & feelings well being





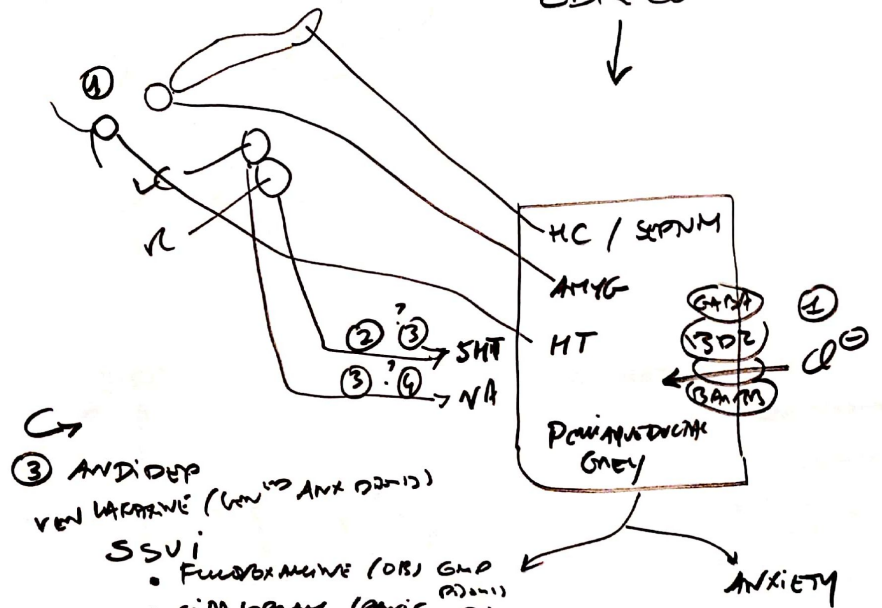
• of 2°
 GABAergic
 control
 of DA in
 LS



59
ANXIETY
1



CBR Co
↓

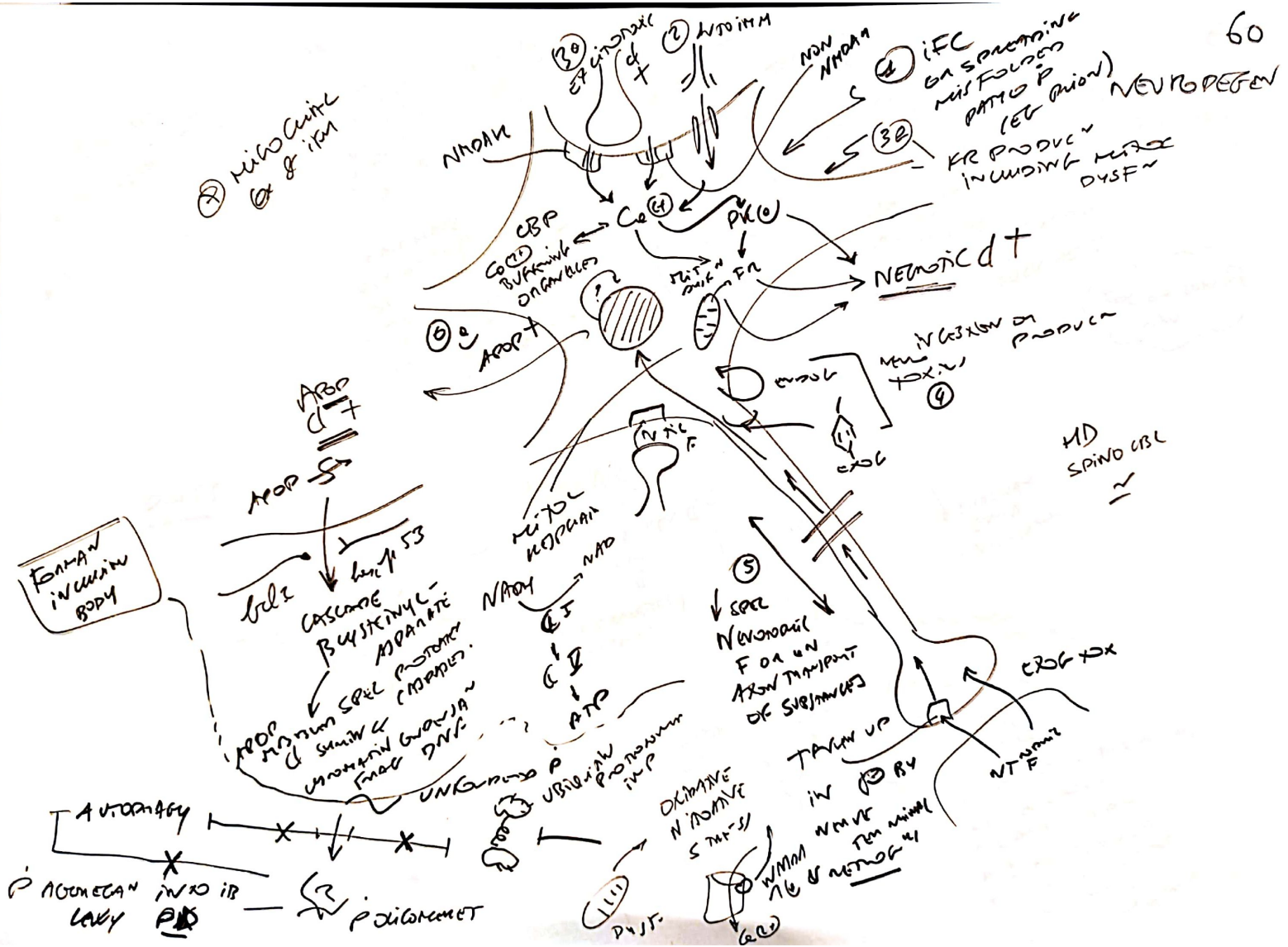


DRUGS ↓

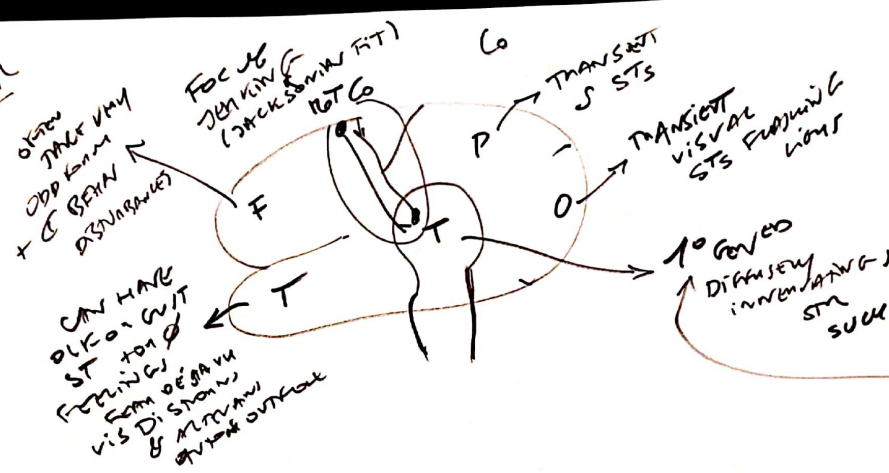
↑

- ② BZD DIAZEPAM
 - RAPID ONSET
 - SEDATIVE
 - DEPENDENCE
 - 2-4 WEEKS ONLY
- ② ON 5HT_{2A}
 - AGONISTS
 - BUSPIRONE

- ③ ANTI-DEP
VENLAFAXINE (VEN → ANX DEP)
- SSRI
 - FLUOXETINE (OF) GMP (ADULT)
 - CITALOPRAM (ANX D)
 - MAOI
- ④ ↓ ANTAGONISTS
β BLOCKERS
• PROPRANOLOL

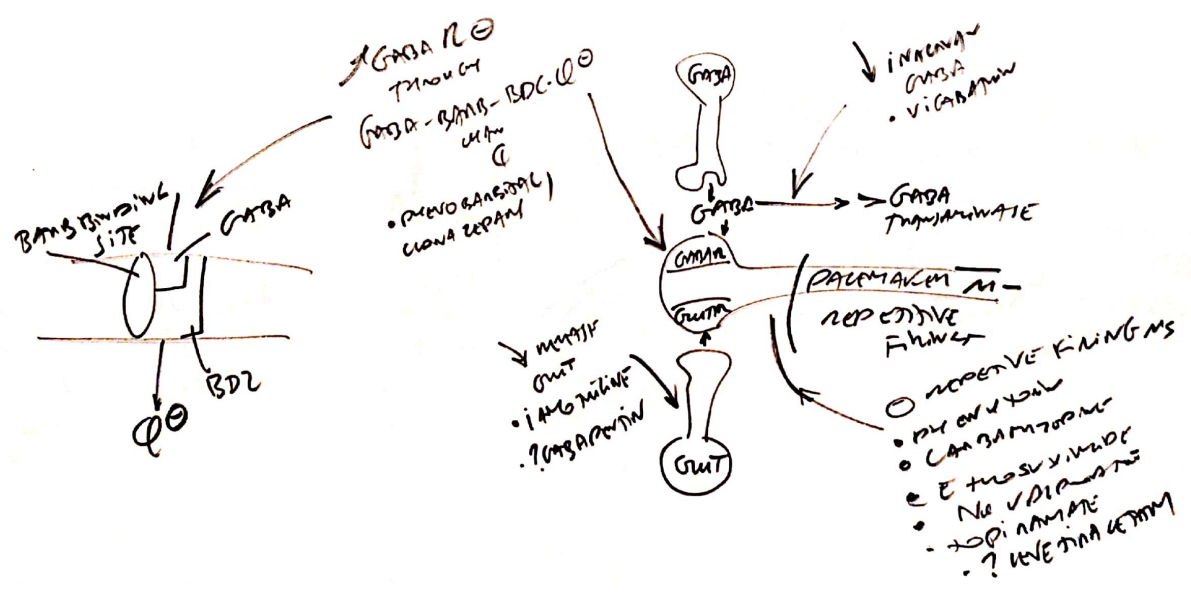


CF
 Foc when = CPMITAL
 VITR IMPACT CS = CPMITAL
 SIMPLE
 KITUR



NONPHYSIO EPILEPSY

DRUGS

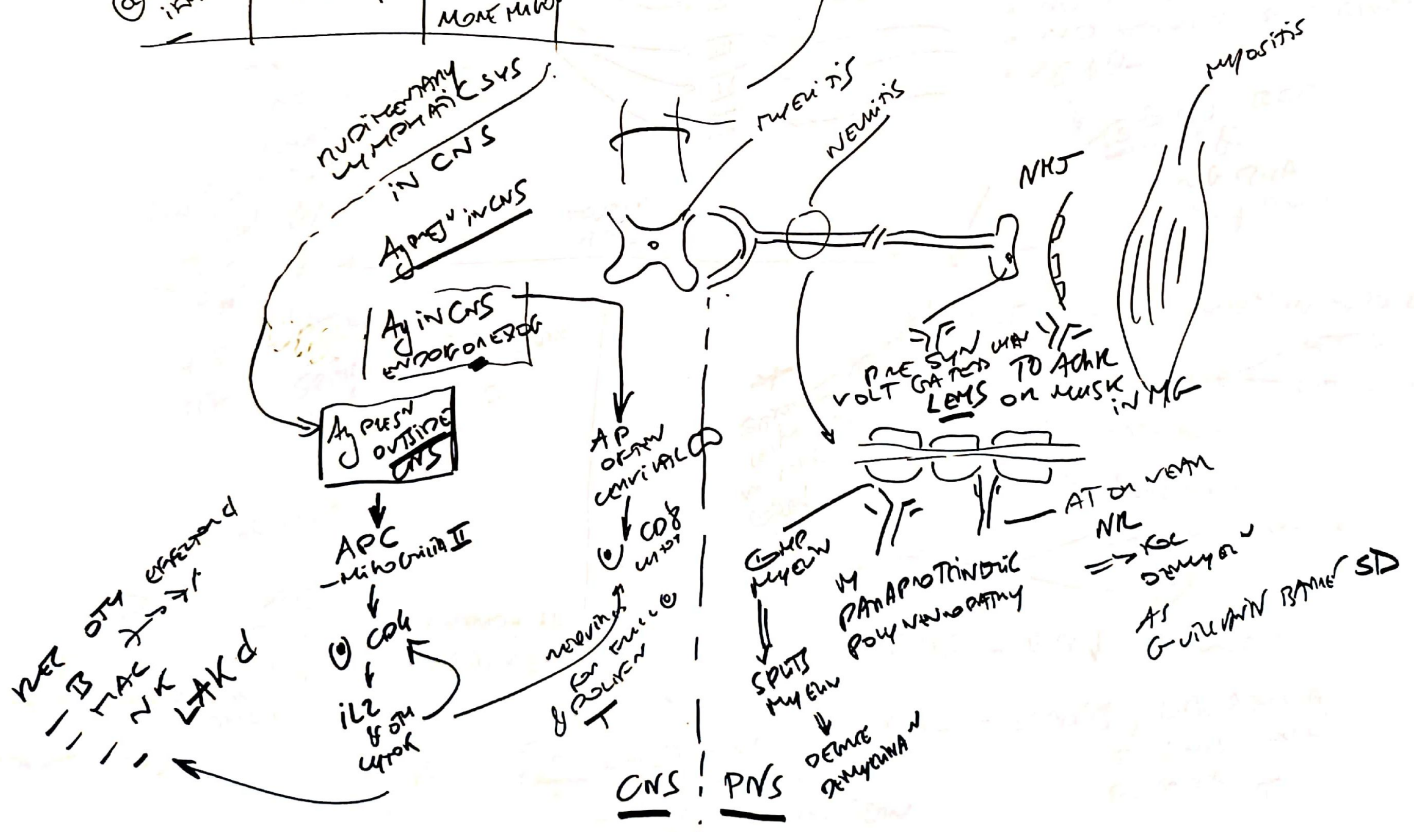


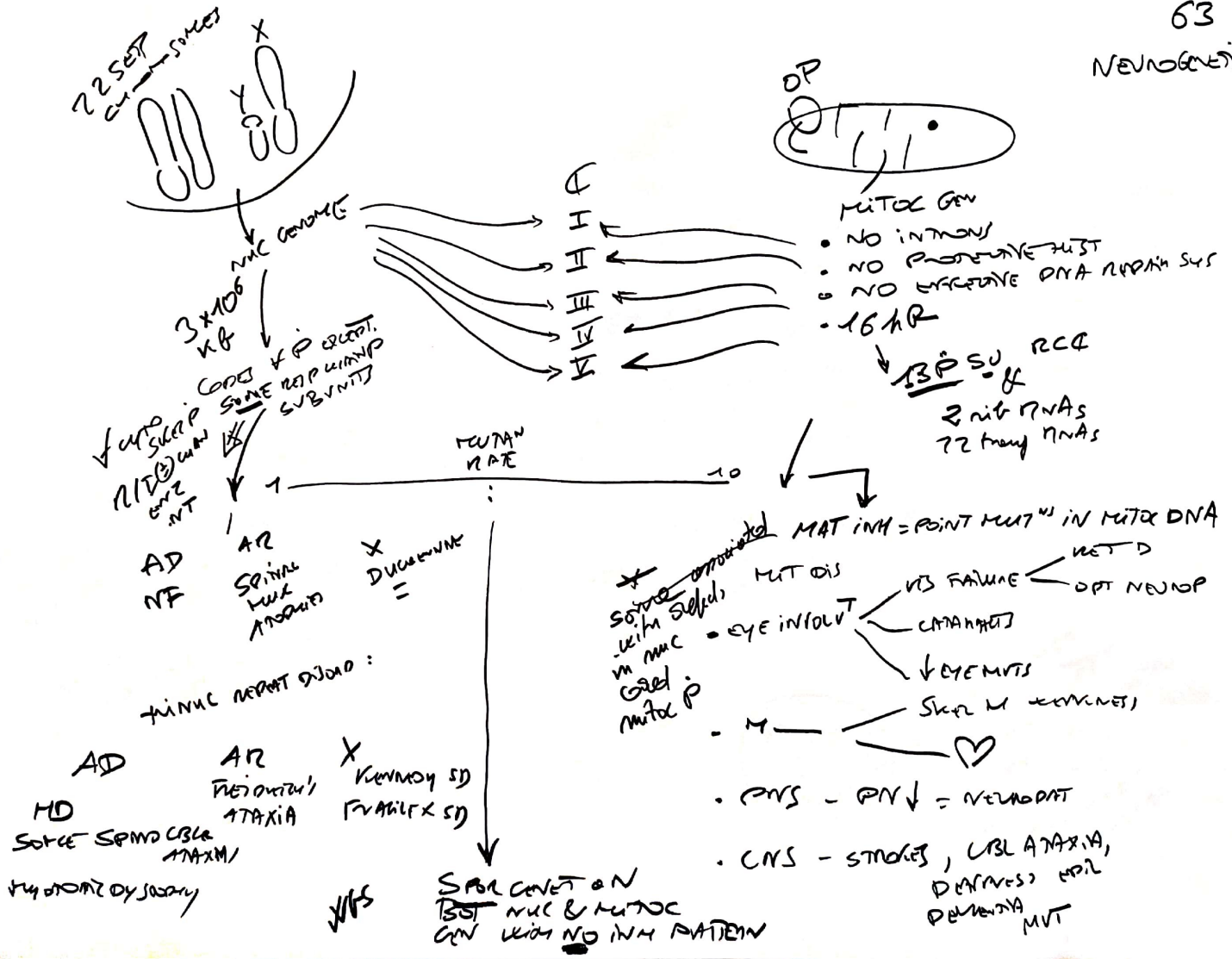
NEUROIMMUNO DISORDERS

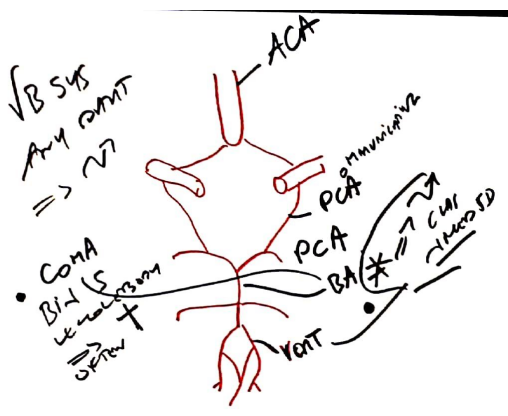
RESTING STATE	MHCI EXPRESSION	MCHI EXPRESSION
	ENDOT	MICROGLIA
① PRO IEM 4	? Astrocyte	ASTROCYTE ENDOT MORE MICROGLIA

- MS
- ADDEM
- OTM IEM 4
- EG VASCULITIS

IEM + DEMYELINATION IN WM BAWN + SC

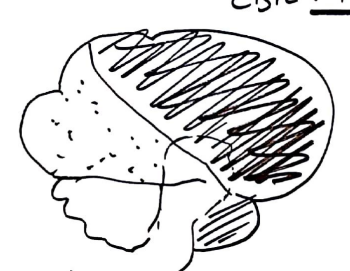






- ↓ MCD SD W/ALWAYS
- OCC PCA
 - IPSIAL SD PAX II
 - ANAXIA CRL POST + CBL MCD ORGANO
 - VENTRO INTRIN. VIII
 - HEMIP SD ↓ SYMPT
 - DYSPLASIA / OPTICIN III
-

64
CBZ VASC

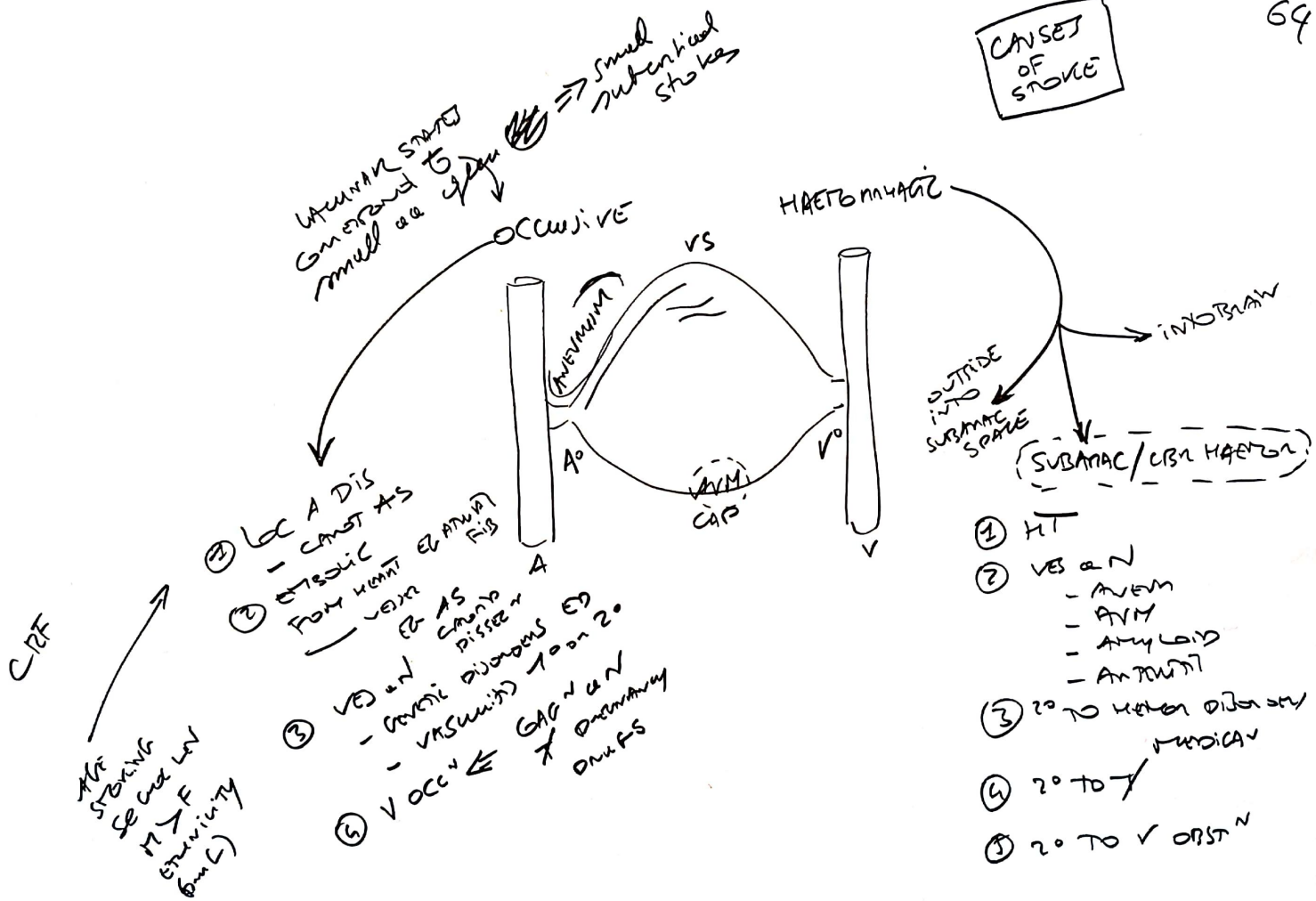


- ACA MCA PCA
- ↓ OVER GNTAL LEB
 - U IN GNTINENCE
 - FRONTAL S
 - ON MCD MCD
 - MCD MCD
 - GENT MCD MCD
 - PARALYSIS OF GNTAL LEB FOOT/LEG
- MCA
- PARAL GNTAL LEB
 - GNTAL LEB ↓
 - SPEED MCD MCD IF L MCD
 - HOMO MCD MCD
- PCA
- HOMO MCD MCD
 - GNTAL LEB ↓
 - LAY MCD MCD T/B S (SOME CASES)



- A SPINNE OCC
- ↓ VUB GNT
 - UMN + LMN MCD
 - ↓ PAN /
 - PCD MCD MCD
 - PCD MCD MCD

CAUSES OF STROKE



CIRCF

THE STROKE
SEVERE
M & F
SYMPTOMS
(6m)

- LOC A DIS - CANNOT AS
 - EMBOLIC FROM HEART OR ARTERIAL FIB
 - VEIN OR ARTERIAL DISSECTION
 - VOCULOPATHY
- GENETIC DISORDERS
10 on 20
ORIGINATING