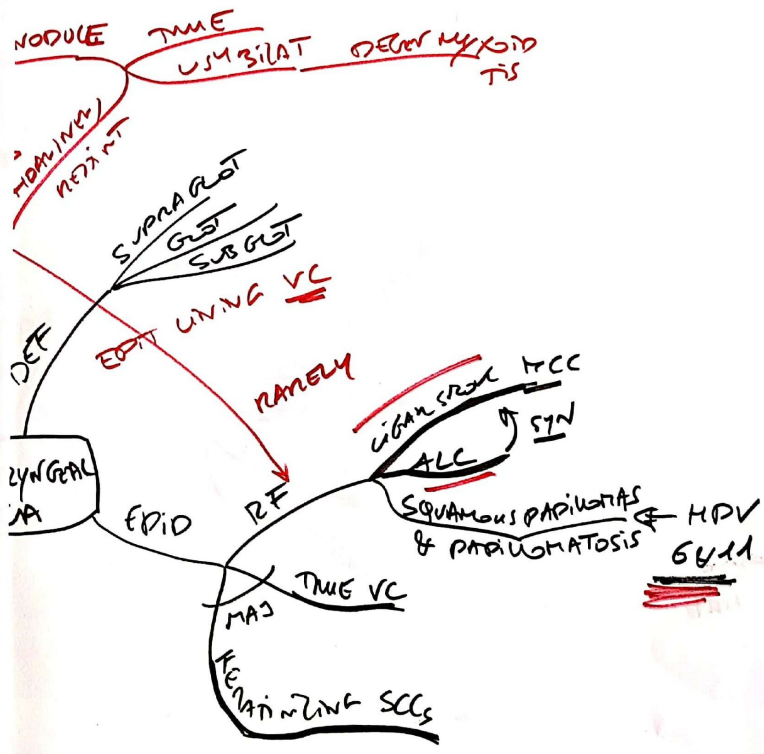

GOLJAN RR RESPIRATORY

ADENOCARCINOMA
NODULE
TAME
USUAL TIS

~~ADENOCARCINOMA~~

~~ADENOCARCINOMA~~
~~ADENOCARCINOMA~~
~~ADENOCARCINOMA~~

ADENOCARCINOMA

ADENOCARCINOMA

ADENOCARCINOMA

ADENOCARCINOMA

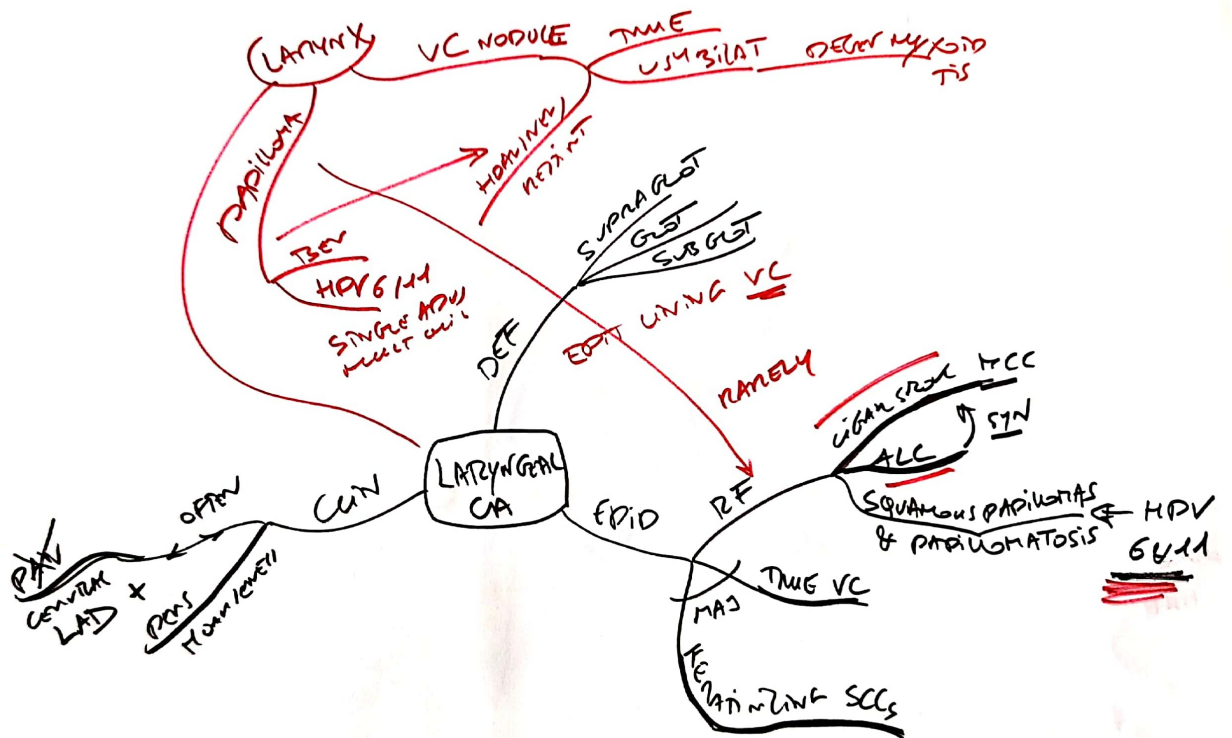
ADENOCARCINOMA

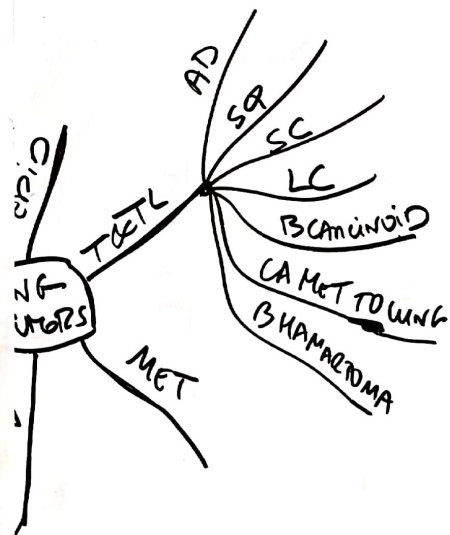
ADENOCARCINOMA

ADENOCARCINOMA

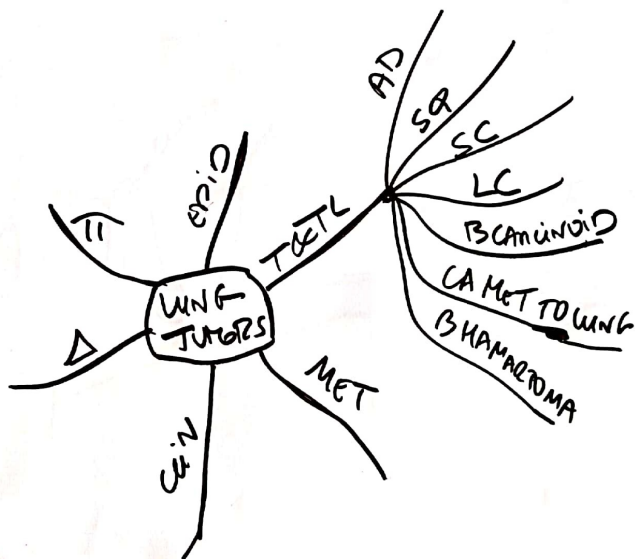
ADENOCARCINOMA
ADENOCARCINOMA
ADENOCARCINOMA

ADENOCARCINOMA

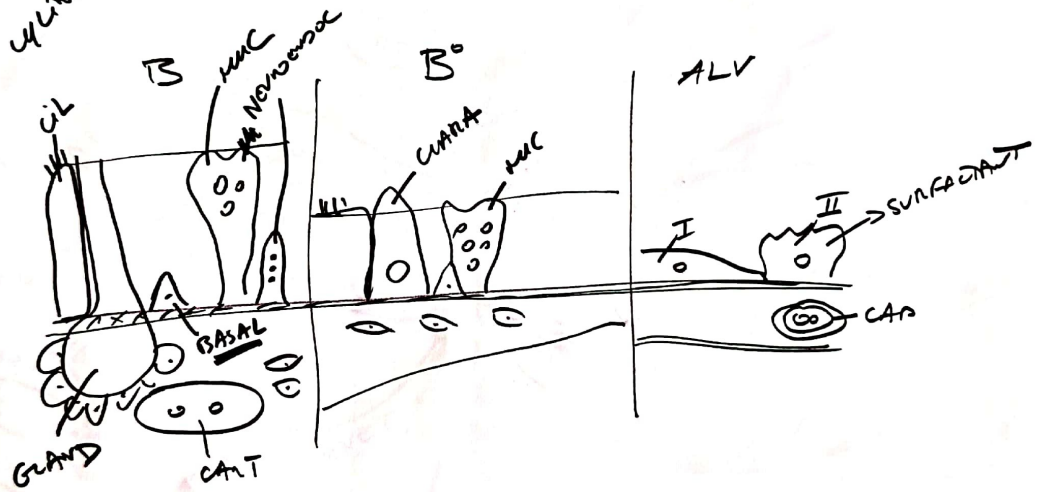


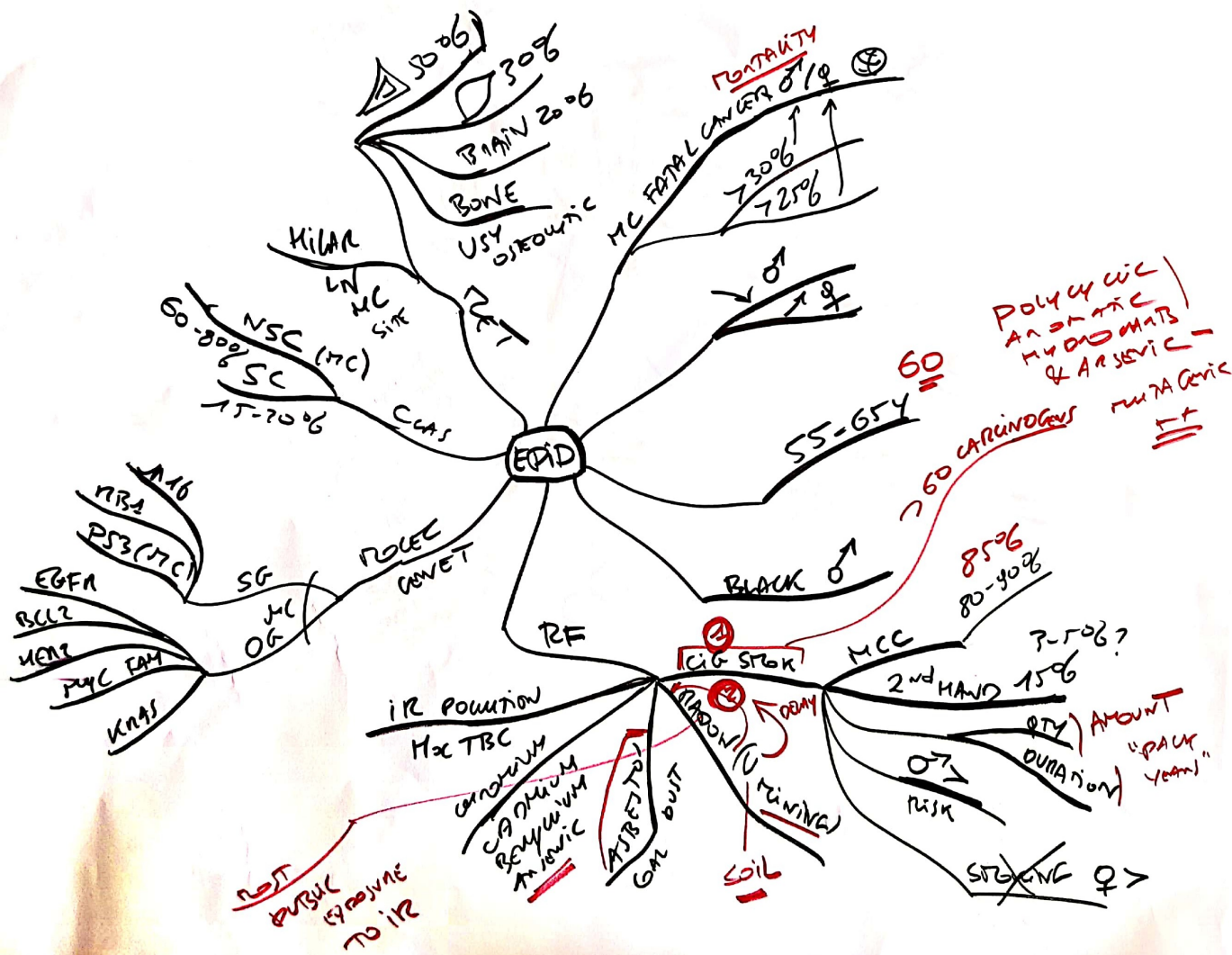


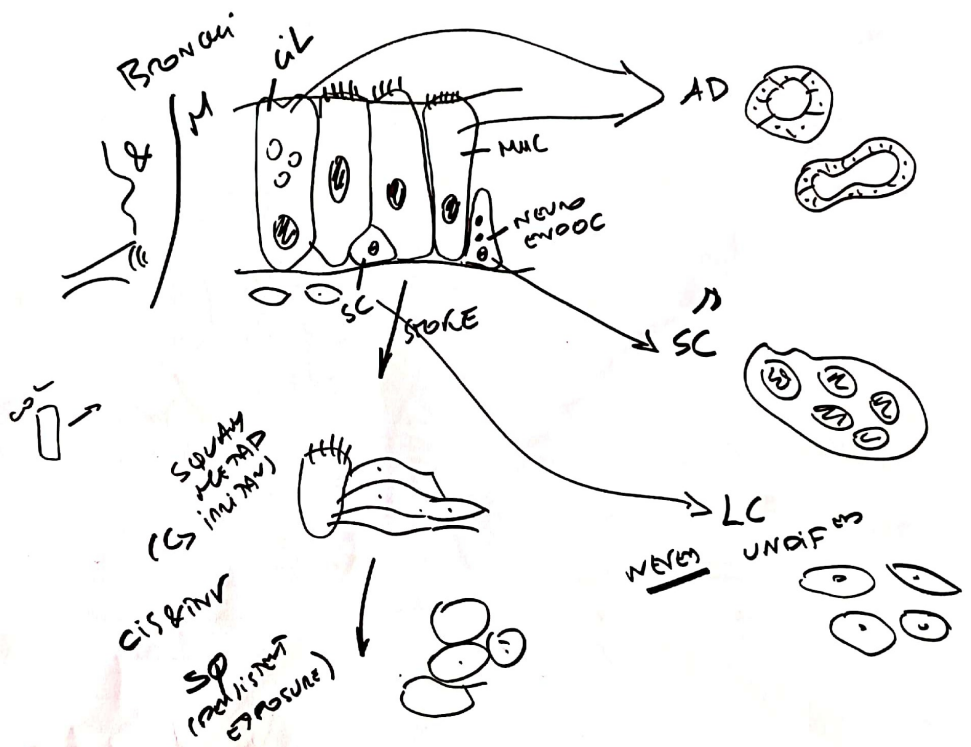
LUNG TUMORS

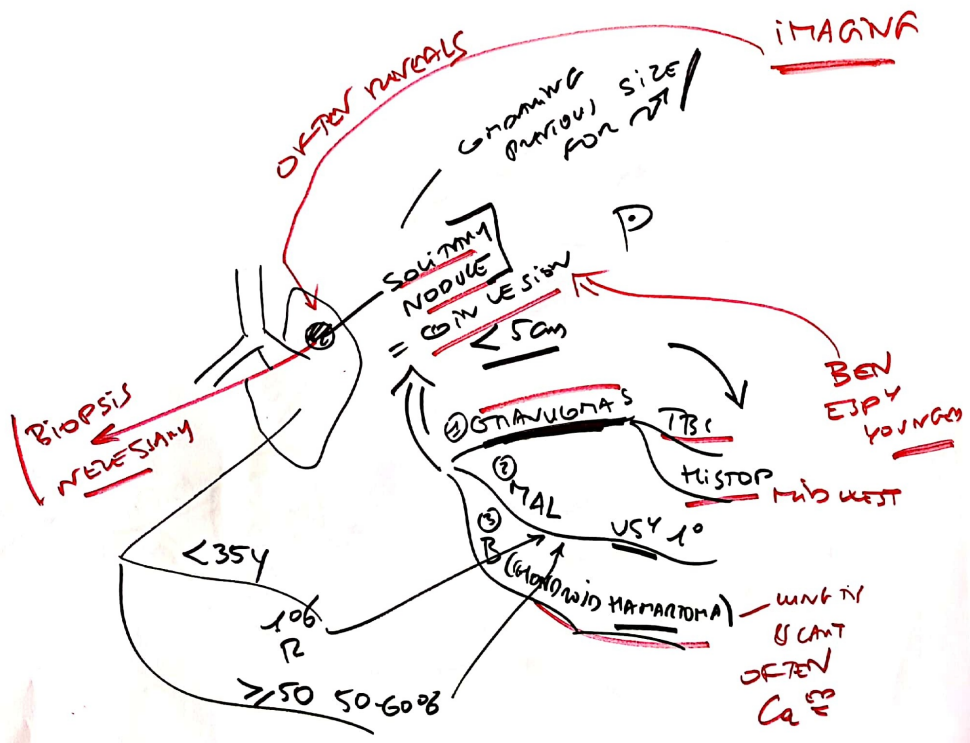


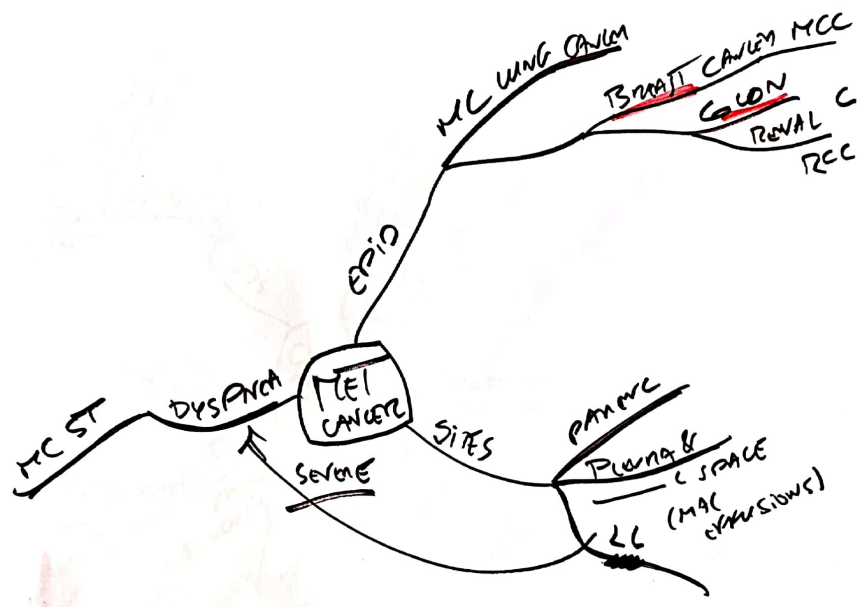
CYLINDRIT

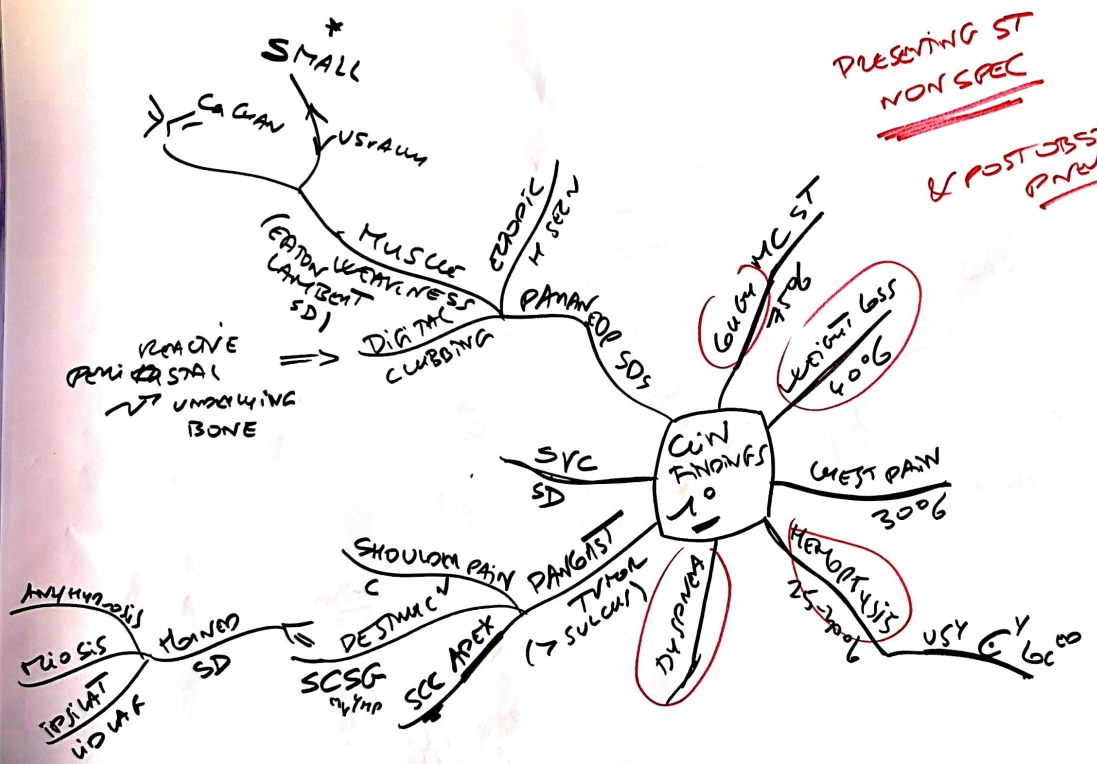




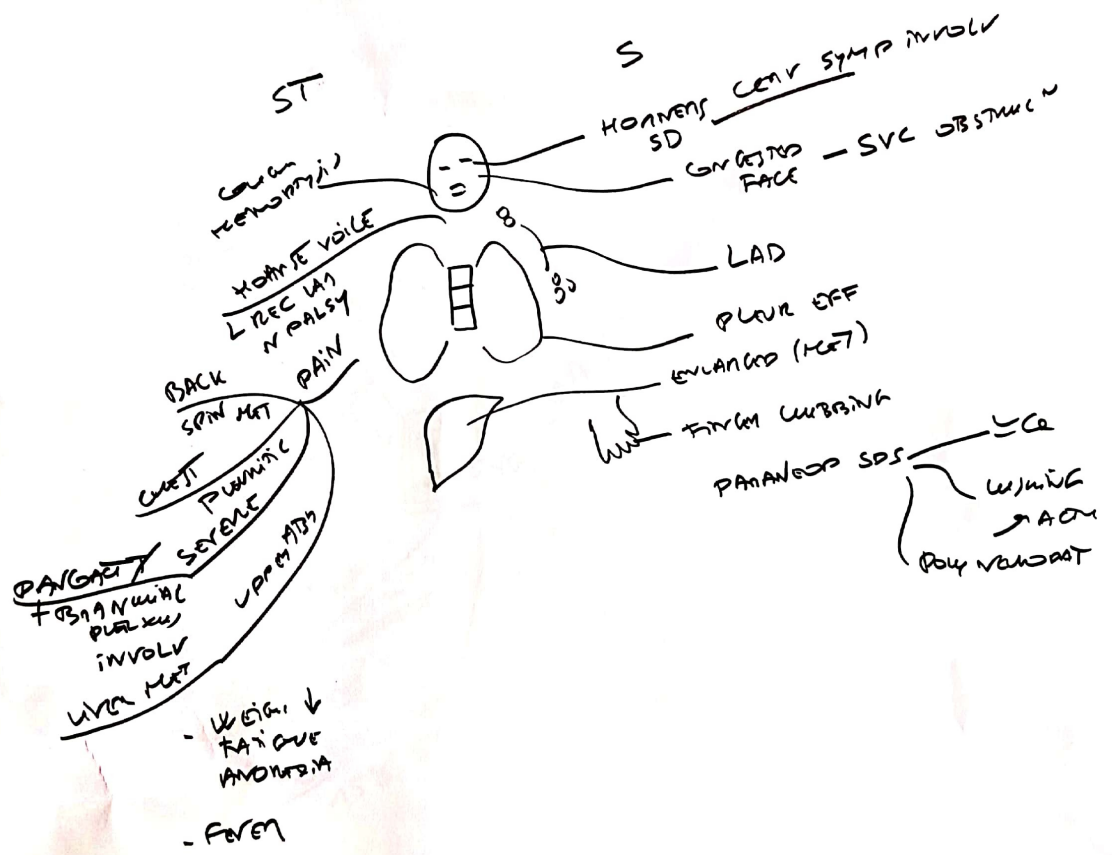




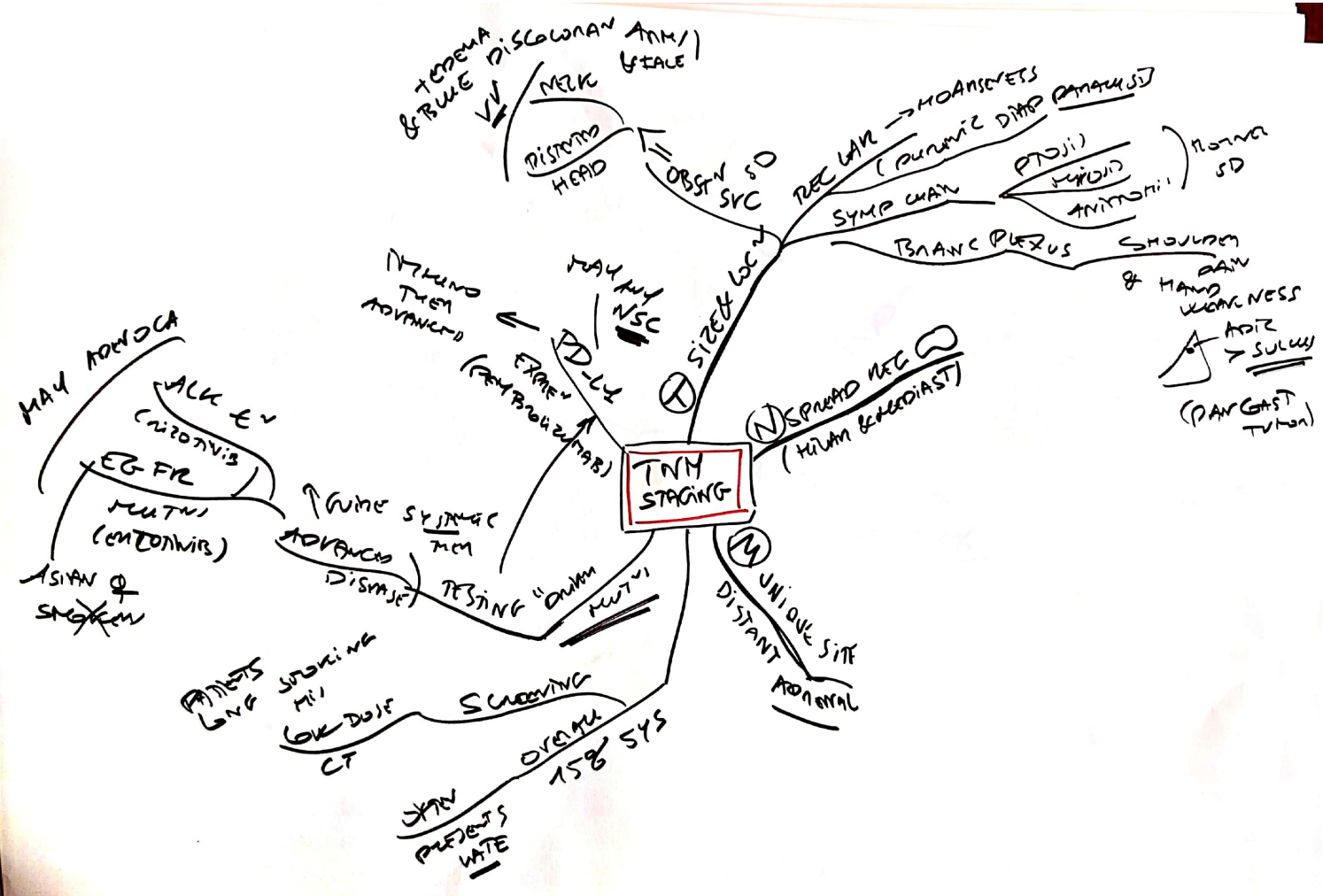




PRESENTING ST
NON SPEC
 & POST OBSTRUCTIVE PNEUMONIA



TNM STAGING



$\frac{1}{\parallel} \xrightarrow{NACC} \text{ACC}$

