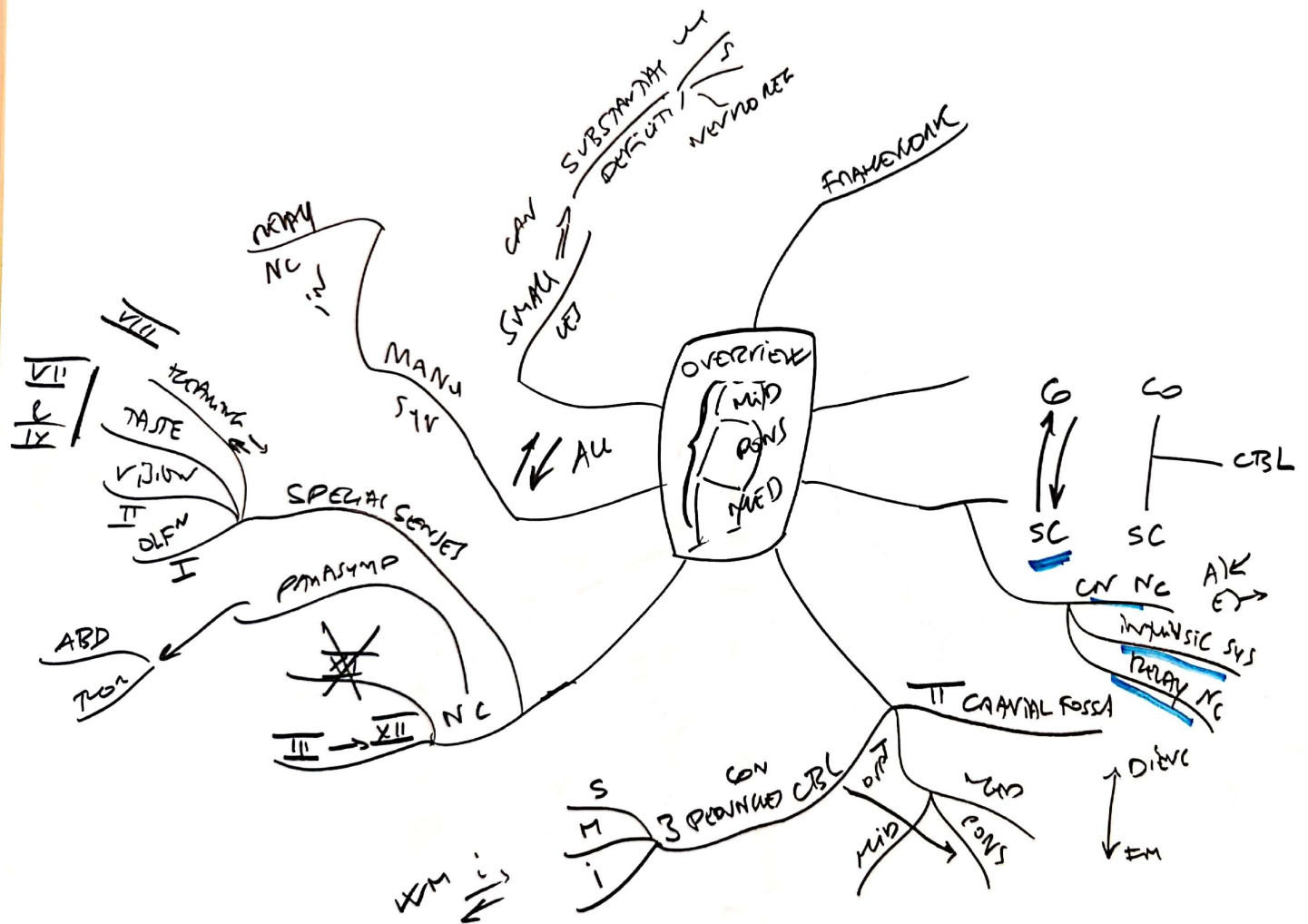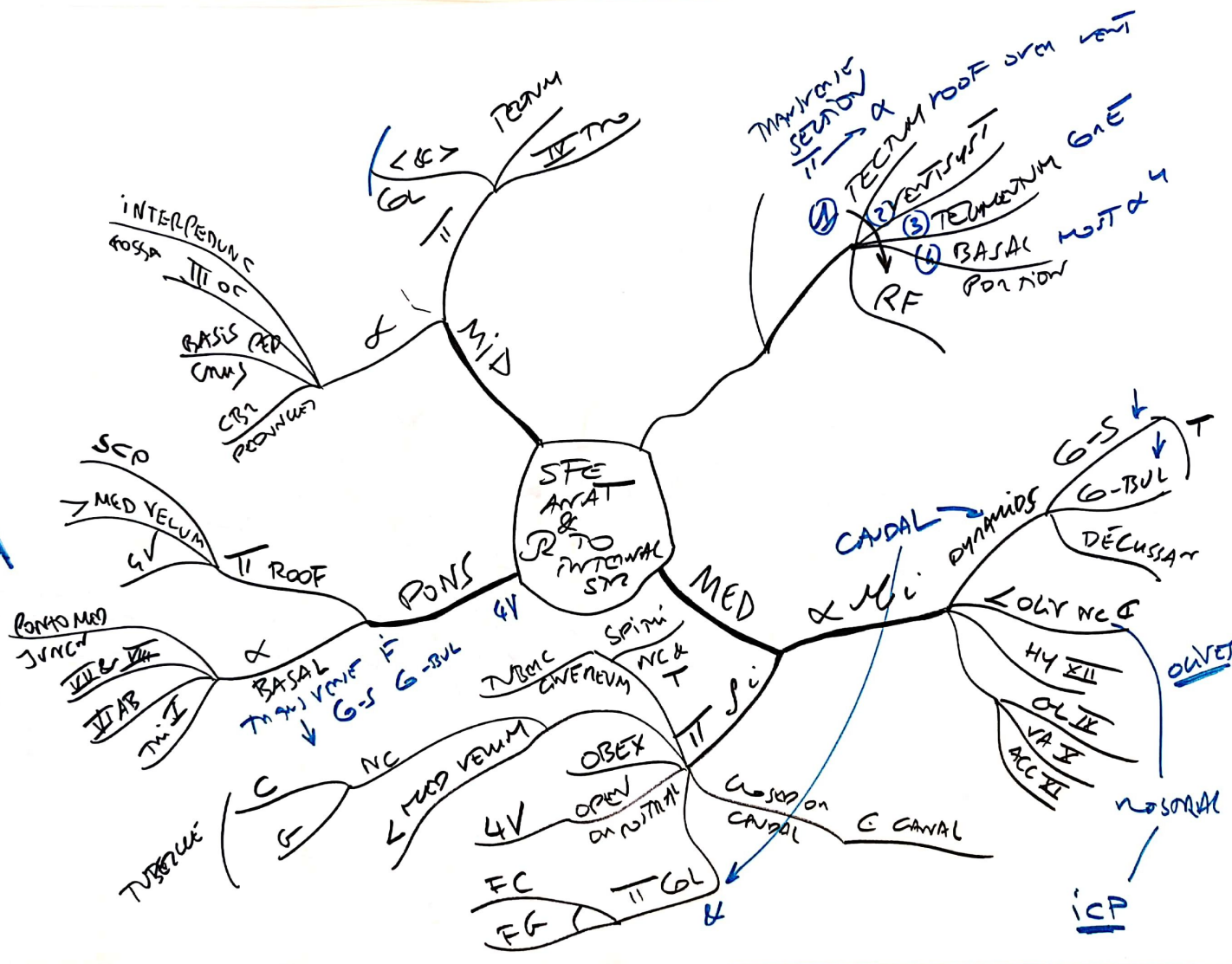
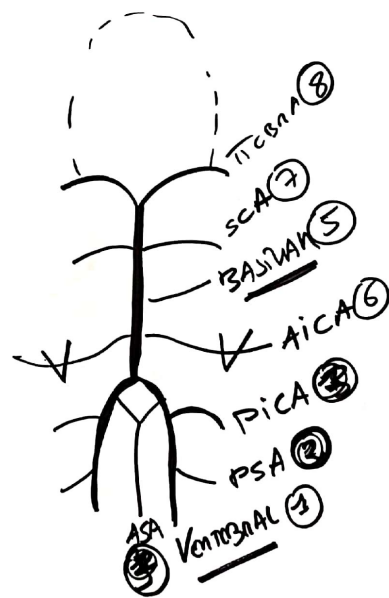


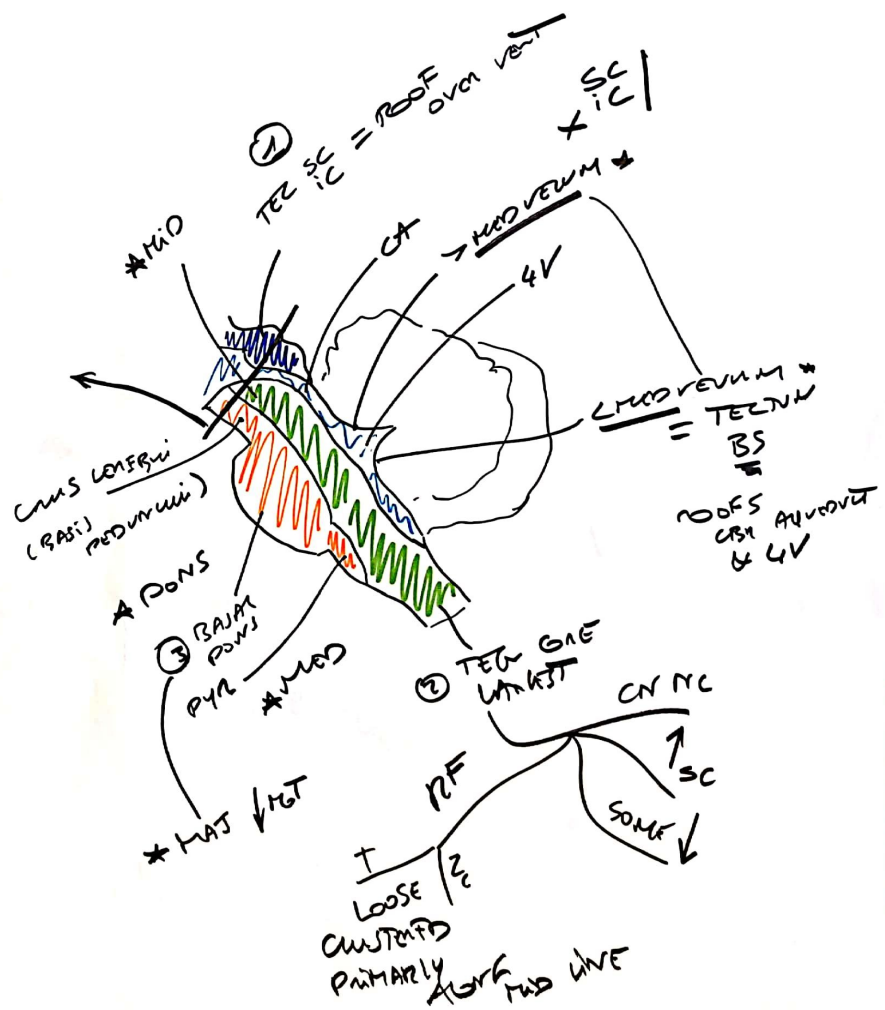
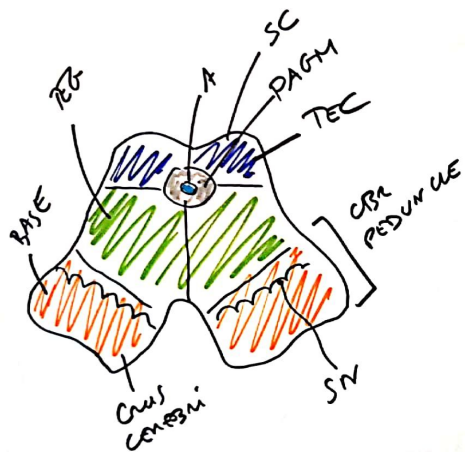
SCP  
MCP

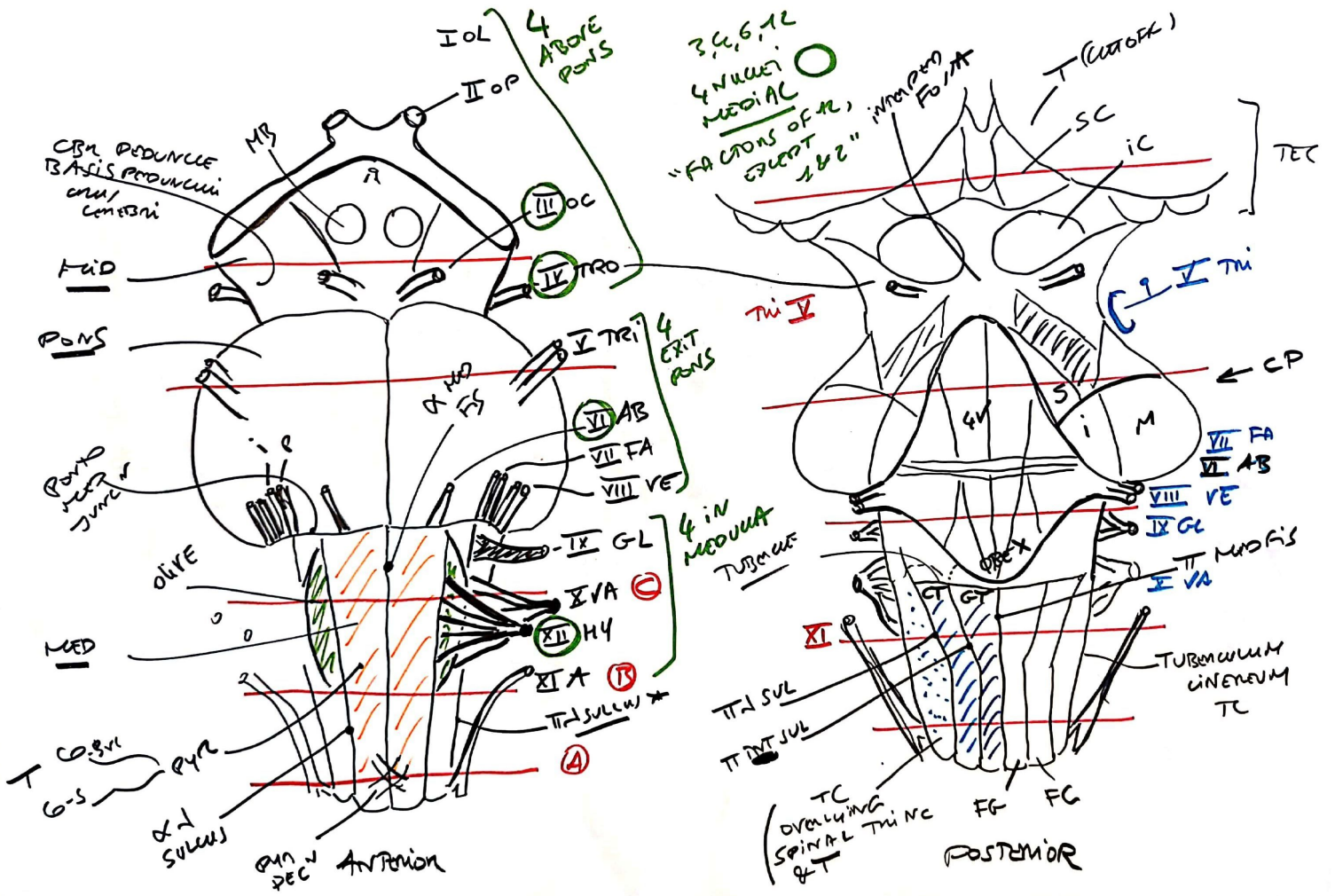


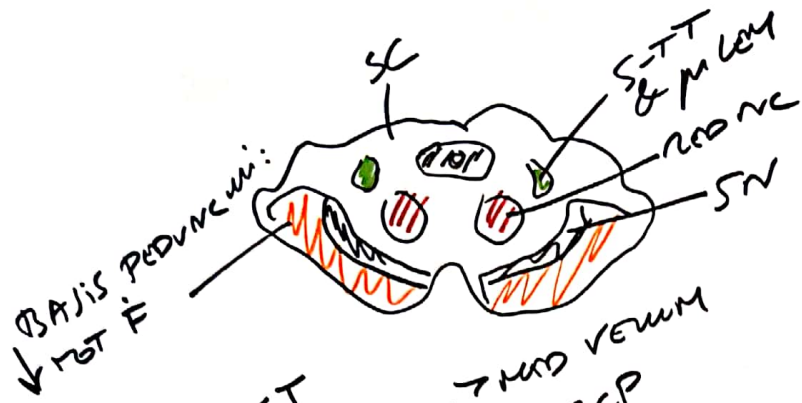




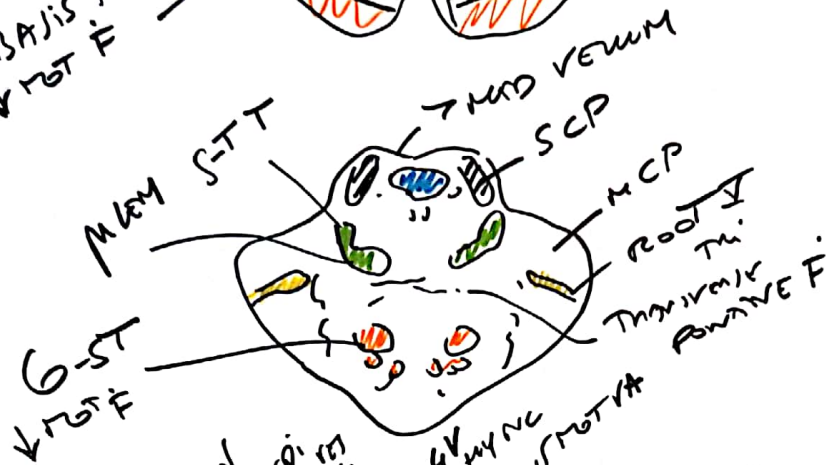



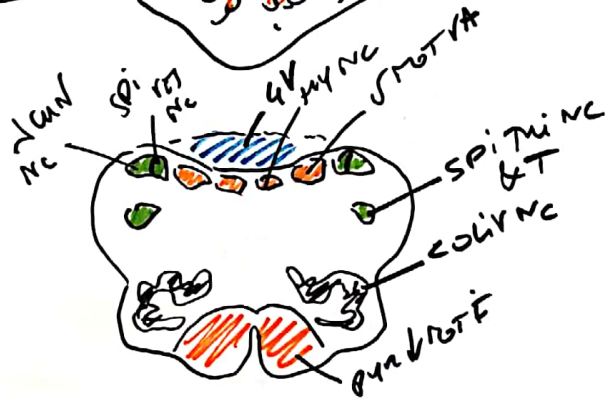




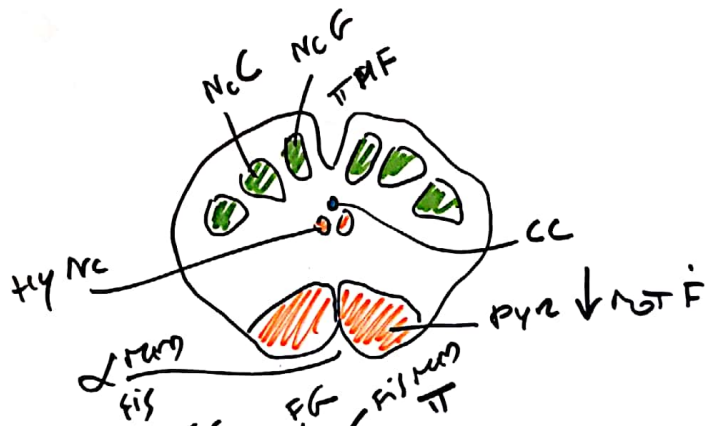
MID



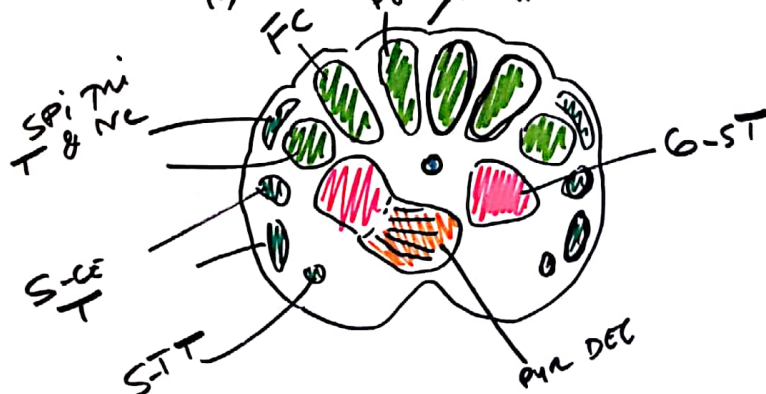
PONS



MED  
C

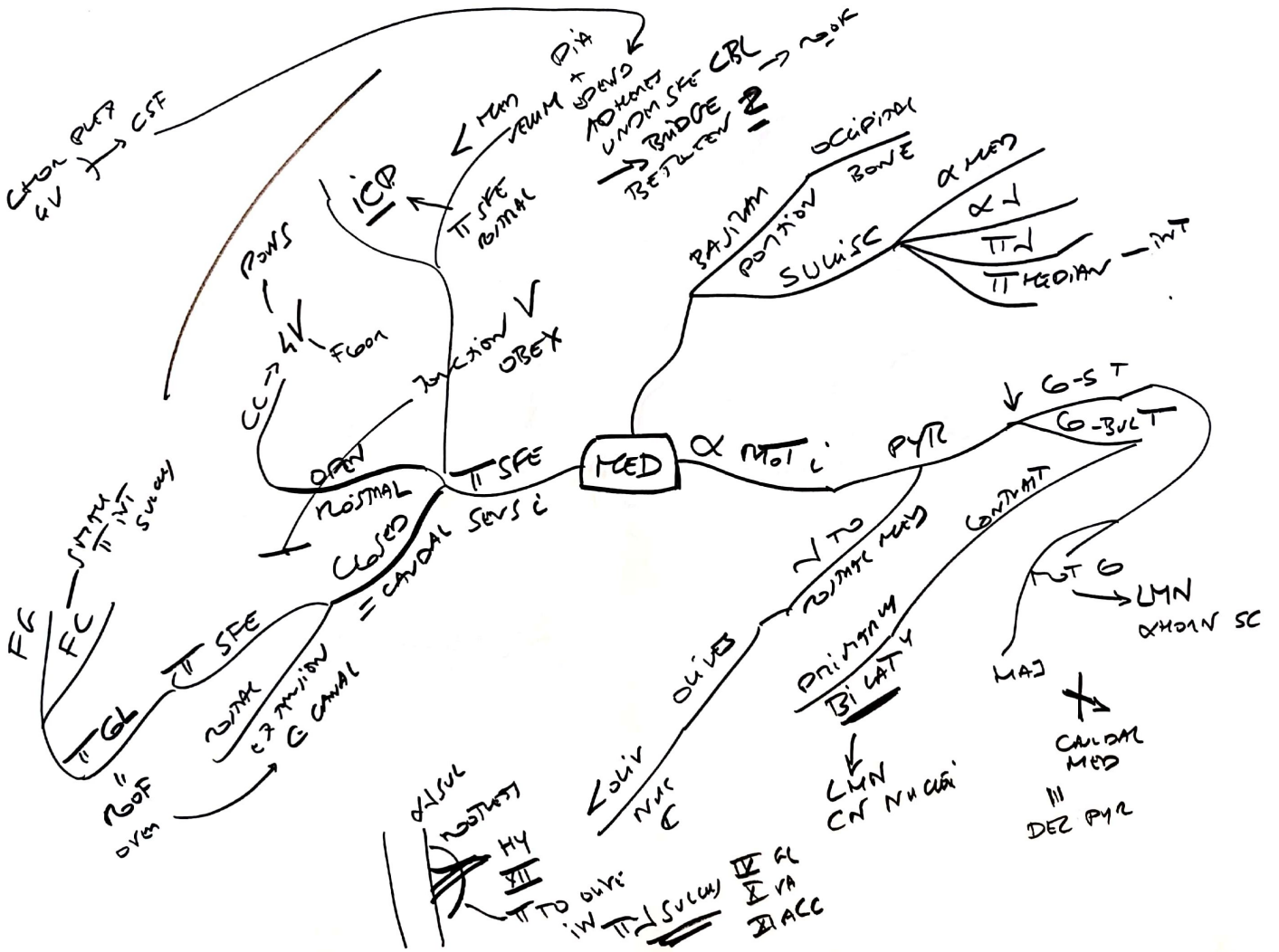


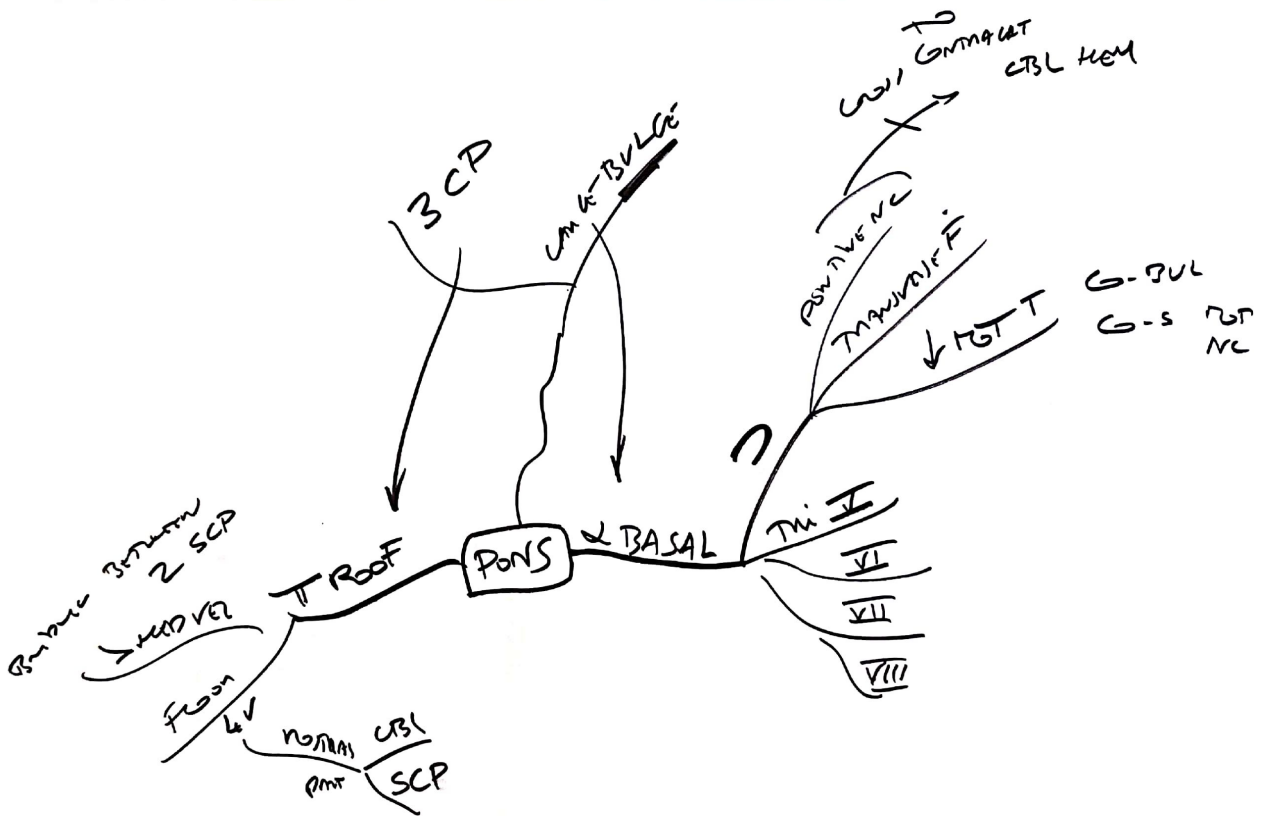
B

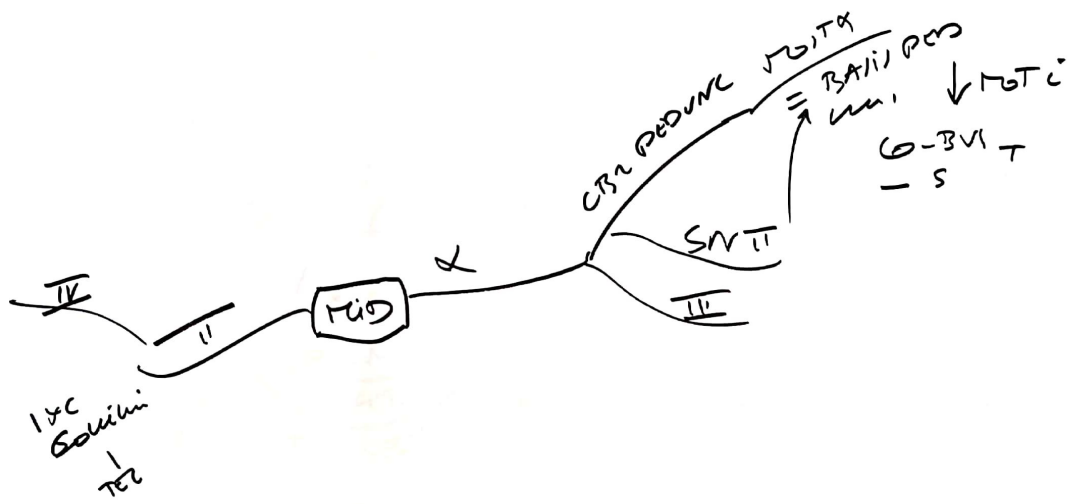


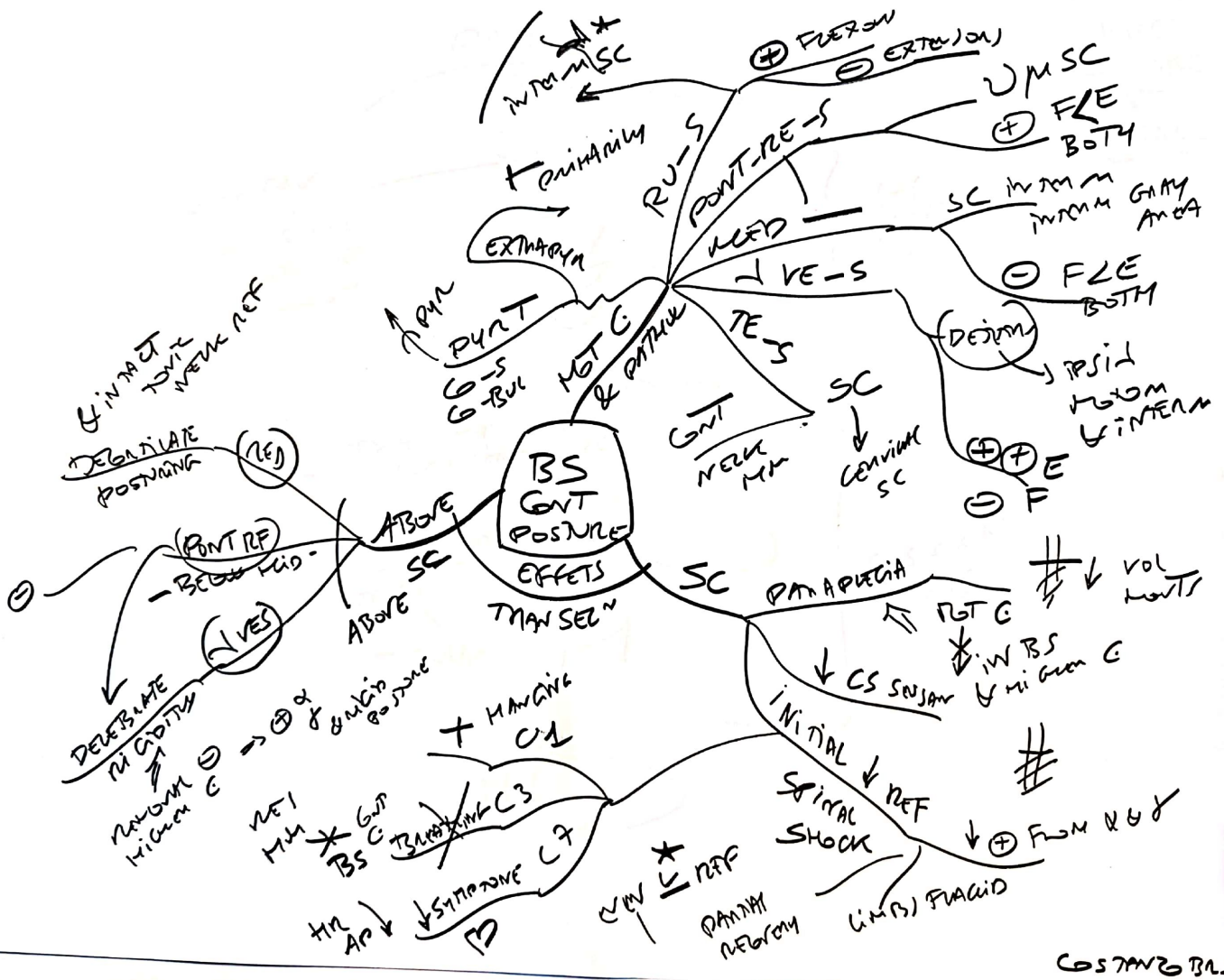
A



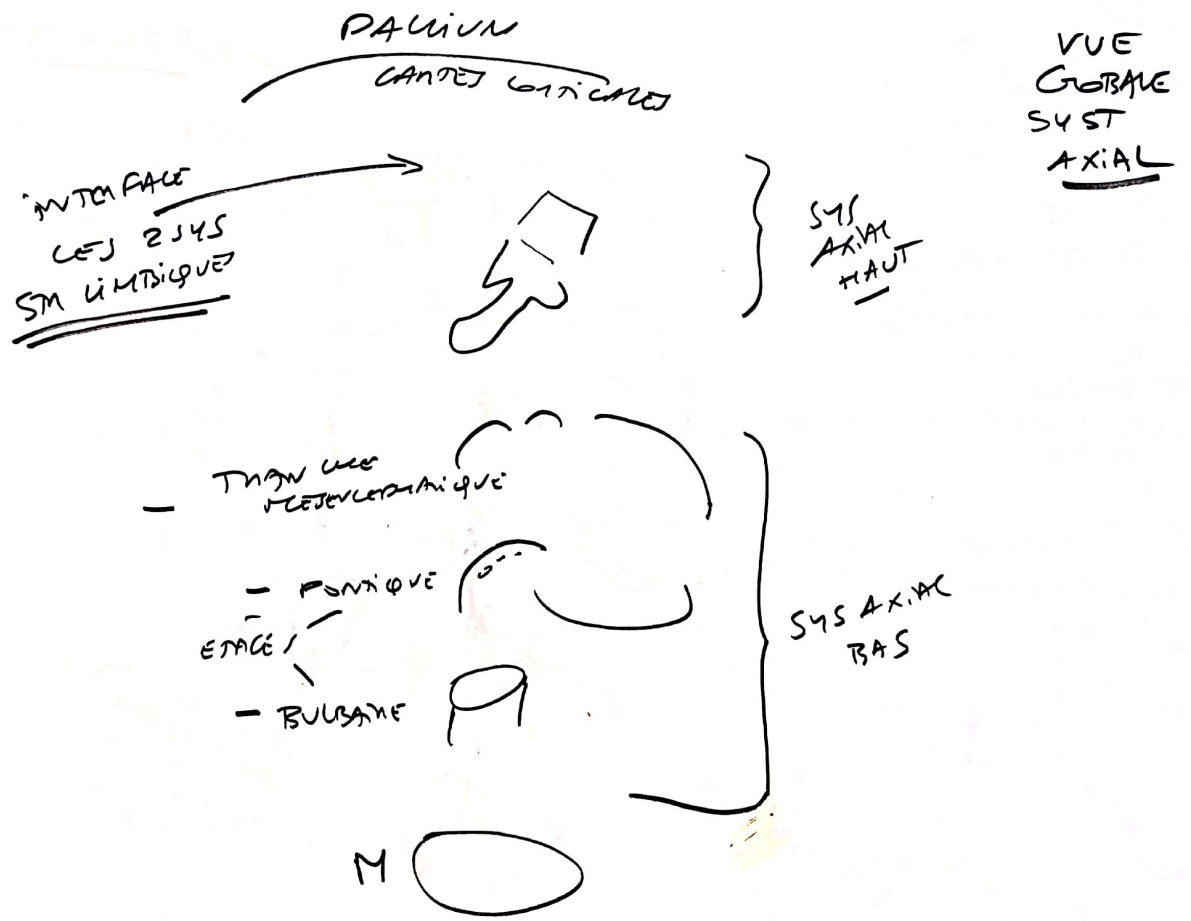


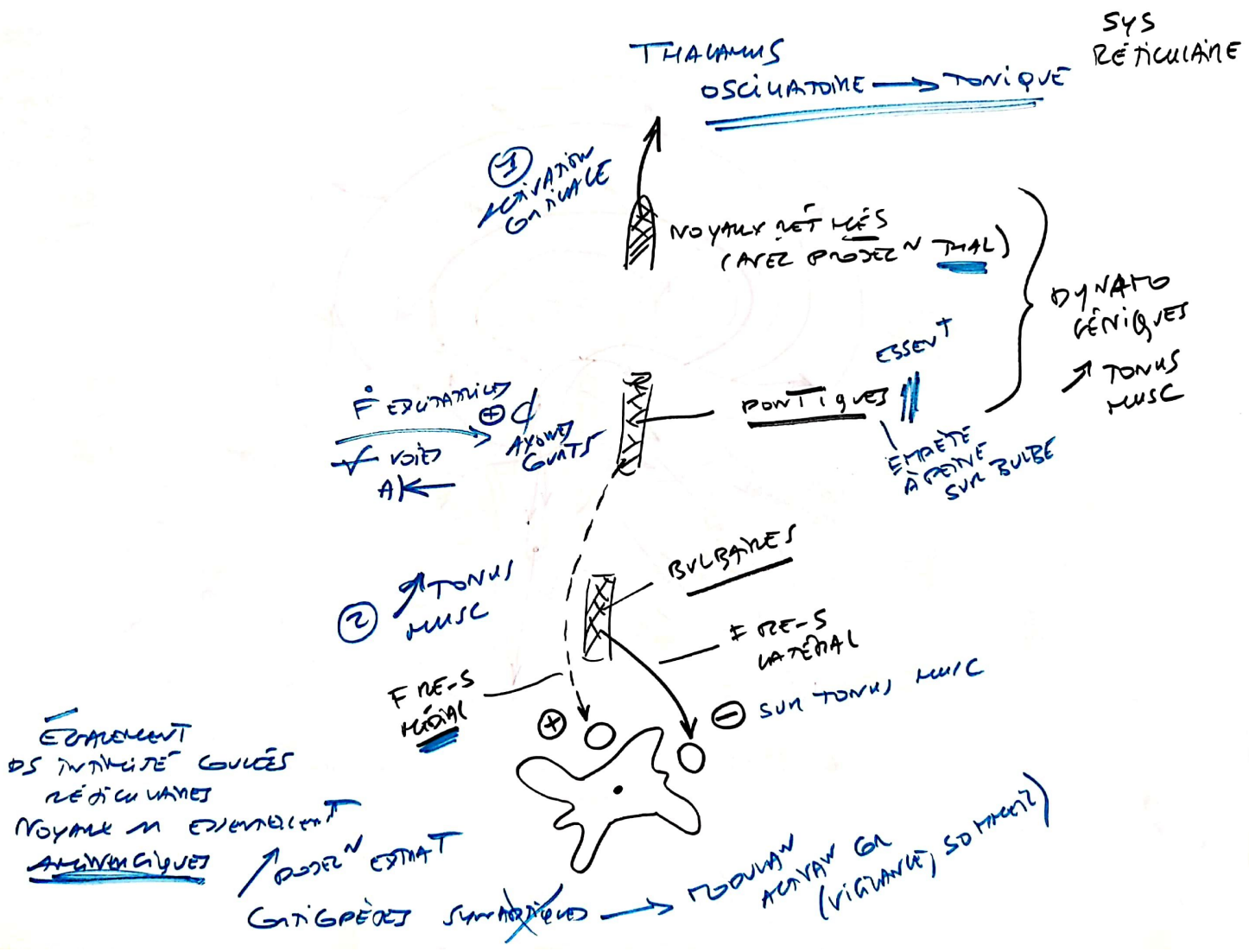








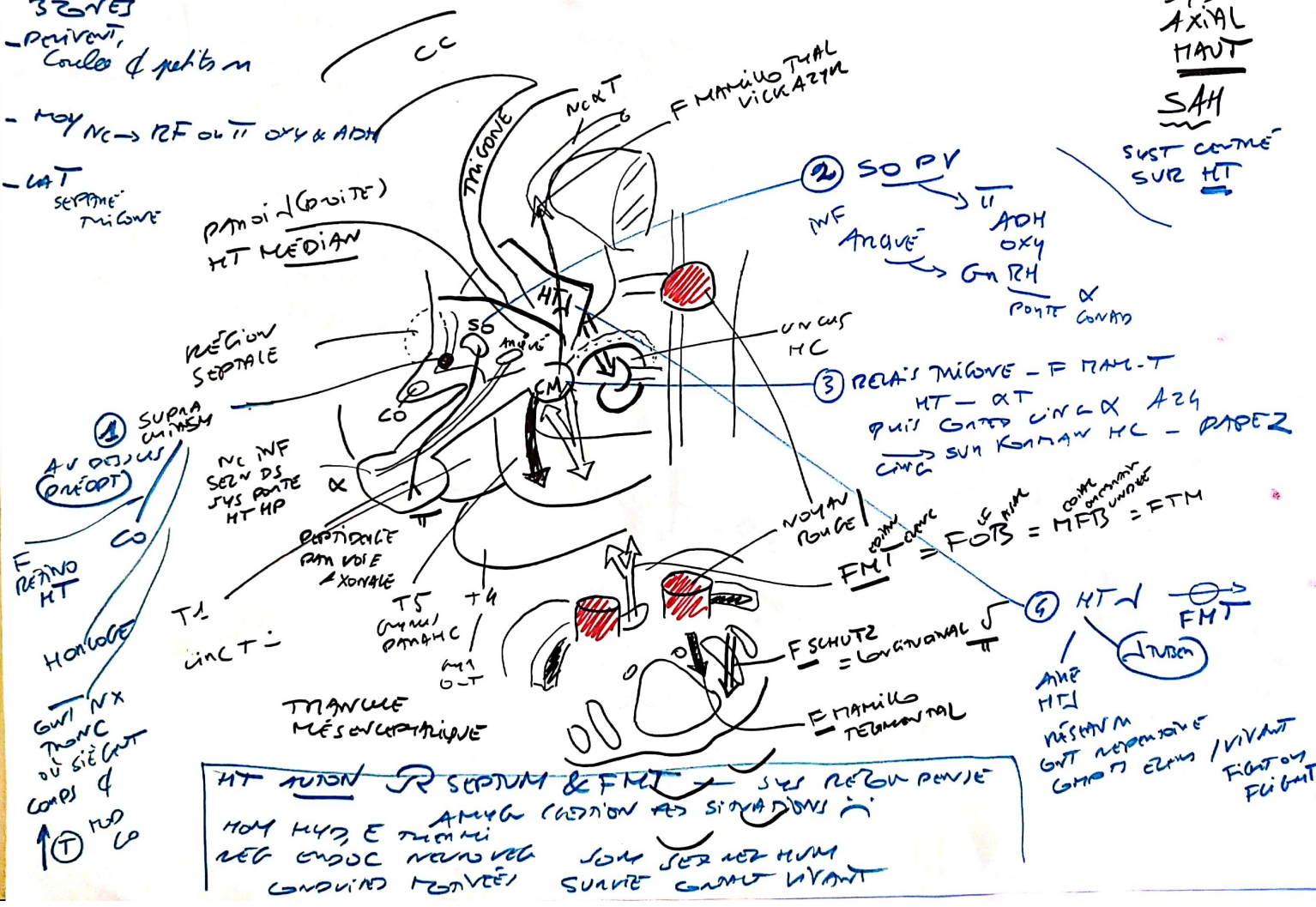




3 ZONES  
- PAVILION, Couloir & petits m

- MOY NC → RF OUT OXY & ADH

- LAT SEPTEME MIGONE



SYS AXIAL HAUT

SAH

SYST CONTRE SUR HT

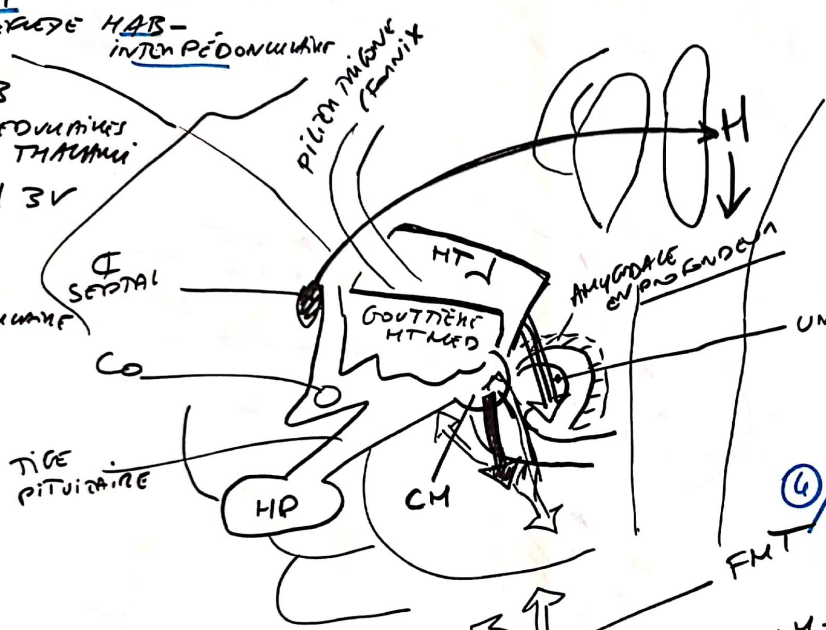
③ REA'S MIGONE - F MAM-T  
HT - AT  
Puis GATED UNO & AZG  
CING → SUR KAMAW HC - PAPER

④ HT ↓ FMT

HT AUTON R SEPTUM & FMT → SYS REGION PAVILE  
MOY H4D, E TUMMI  
REG ENDOC NERVOUS  
CONDUIT FONVEE

③ SEUL MONTANT SHUNT / SHUNT  
 FERMAT RÉTROGRADÉ HAB -  
 INTEN PÉDONCULAIRE

CSPT - HAB  
 PAR SAIE MEDULLAIRE  
 VISIBLES UN THALAMUS  
 PUIS ETEND HAB →  
 TROU INTEN PÉDONCULAIRE



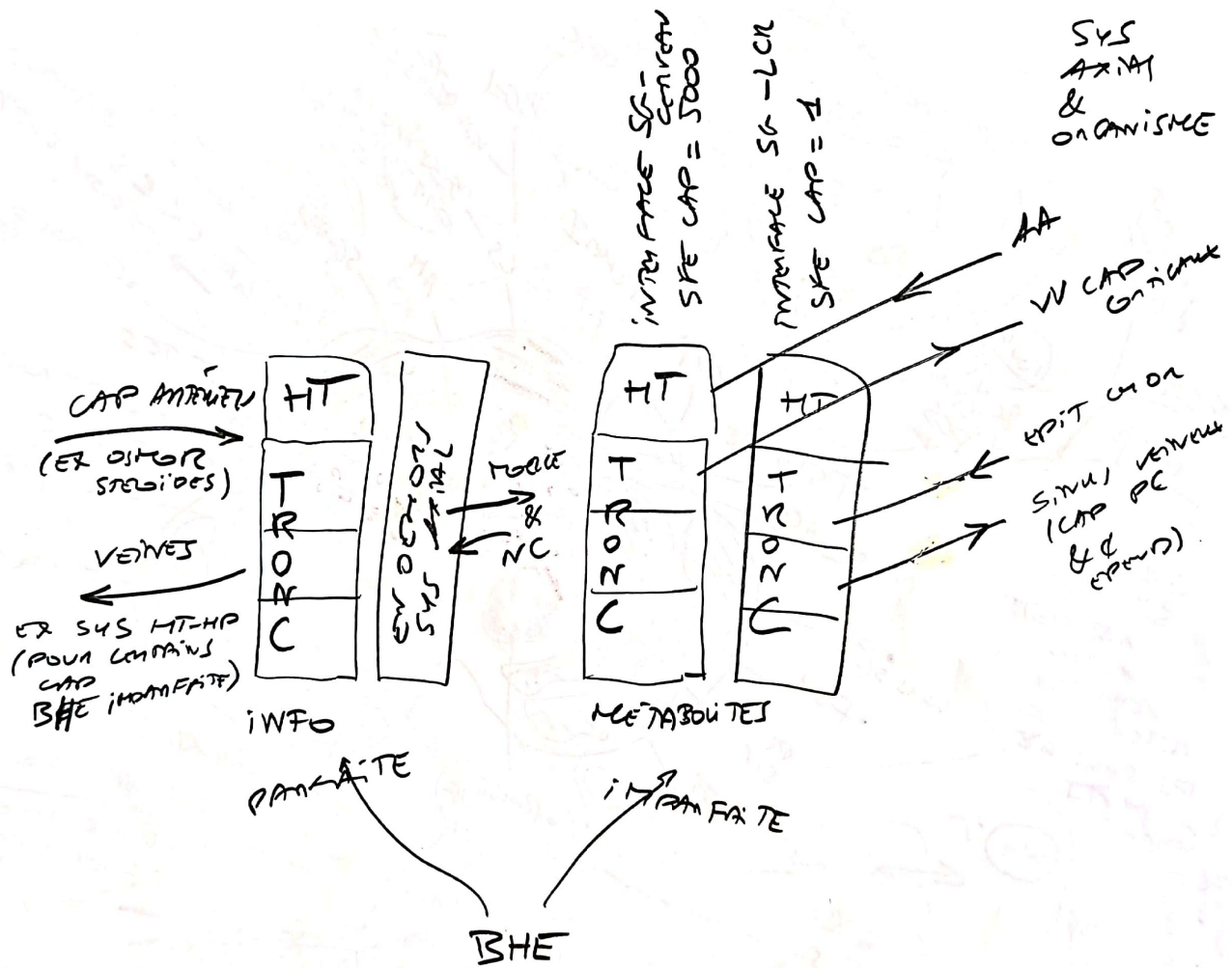
④ ELTD ESSENTIEL "SATELLITE SCPTAL" NORMAUX DI SYL LUMB  
 BIDIR "BU" 2 VOIE ESSENTIELLE SYS MÉSOLIMB A A10  
 CSPT (ACCUMBUS)

JONCTIONS  
 SYS AXIAL  
 HANT  
 &  
 SYS AXIAL  
 BAS  
 CROIES  
 BIDIR

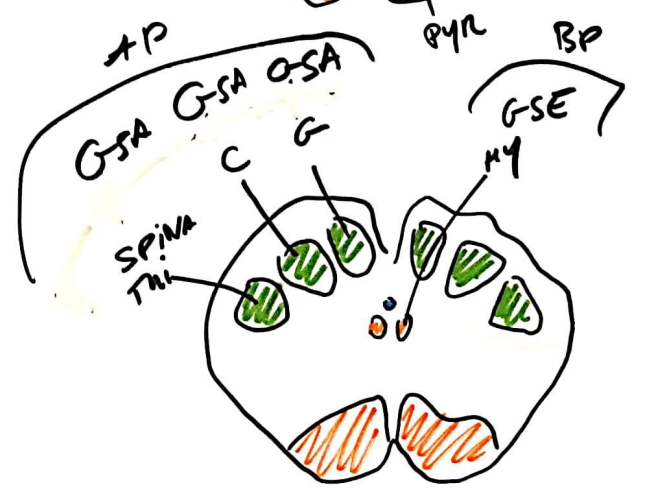
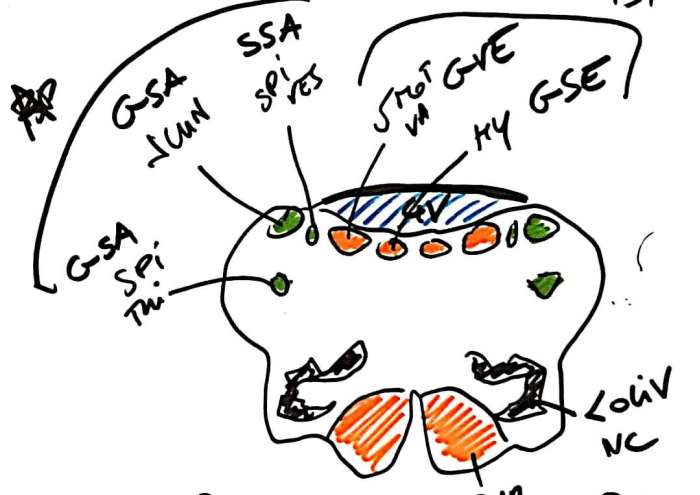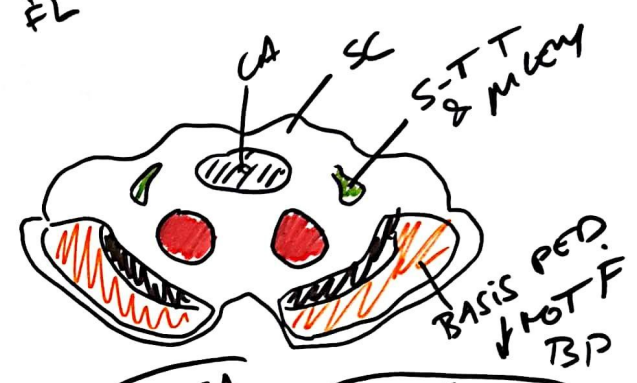
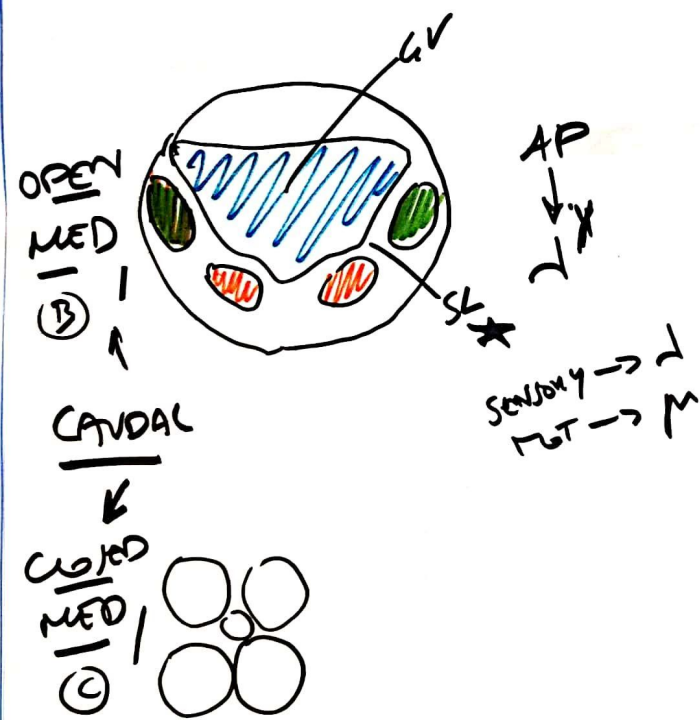
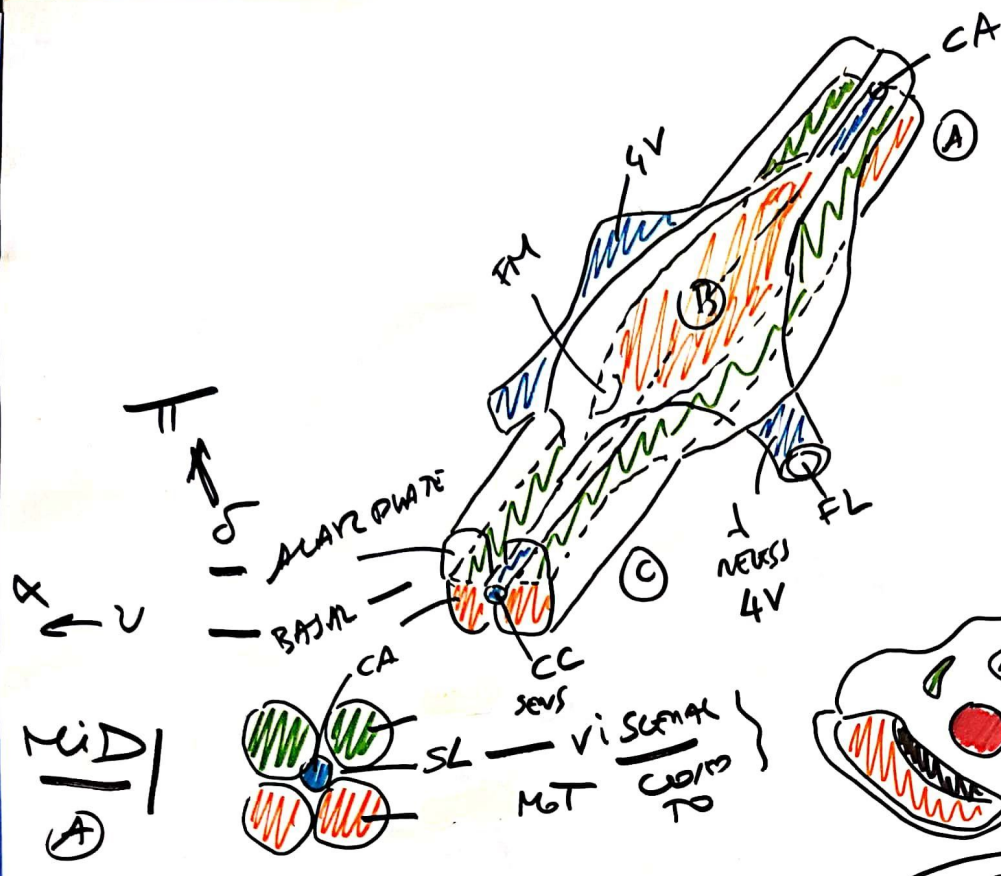
NOYAU INTOMPED / F VENTR HAB  
 F HAM-TEG ①  
 F LONGITUDINAIRE / SCHÜTZ ②  
 TEG J GUDEN  
 ANNE UTERMINALE TJAi = ANNE 10 (OOPANIMIGUE)

ZONE POUVENT  
 ↓  
 WORM & MAREL \*  
 \* SAB





ANNAN CENTR  
NUCET  
DERIVED  
FROM  
ALAN &  
BASAL  
PLATES

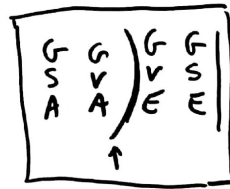
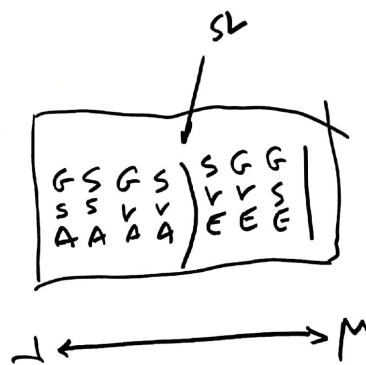
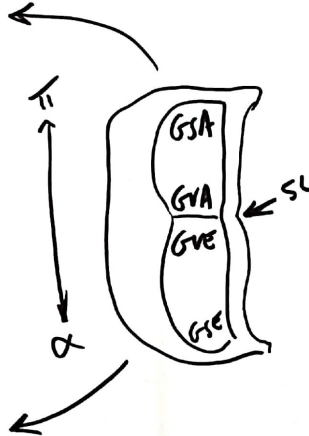
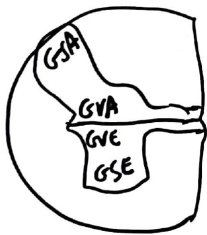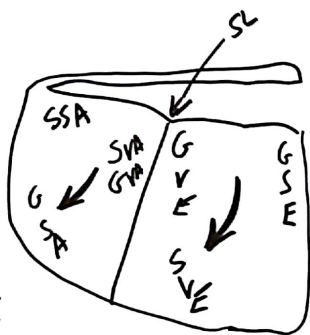


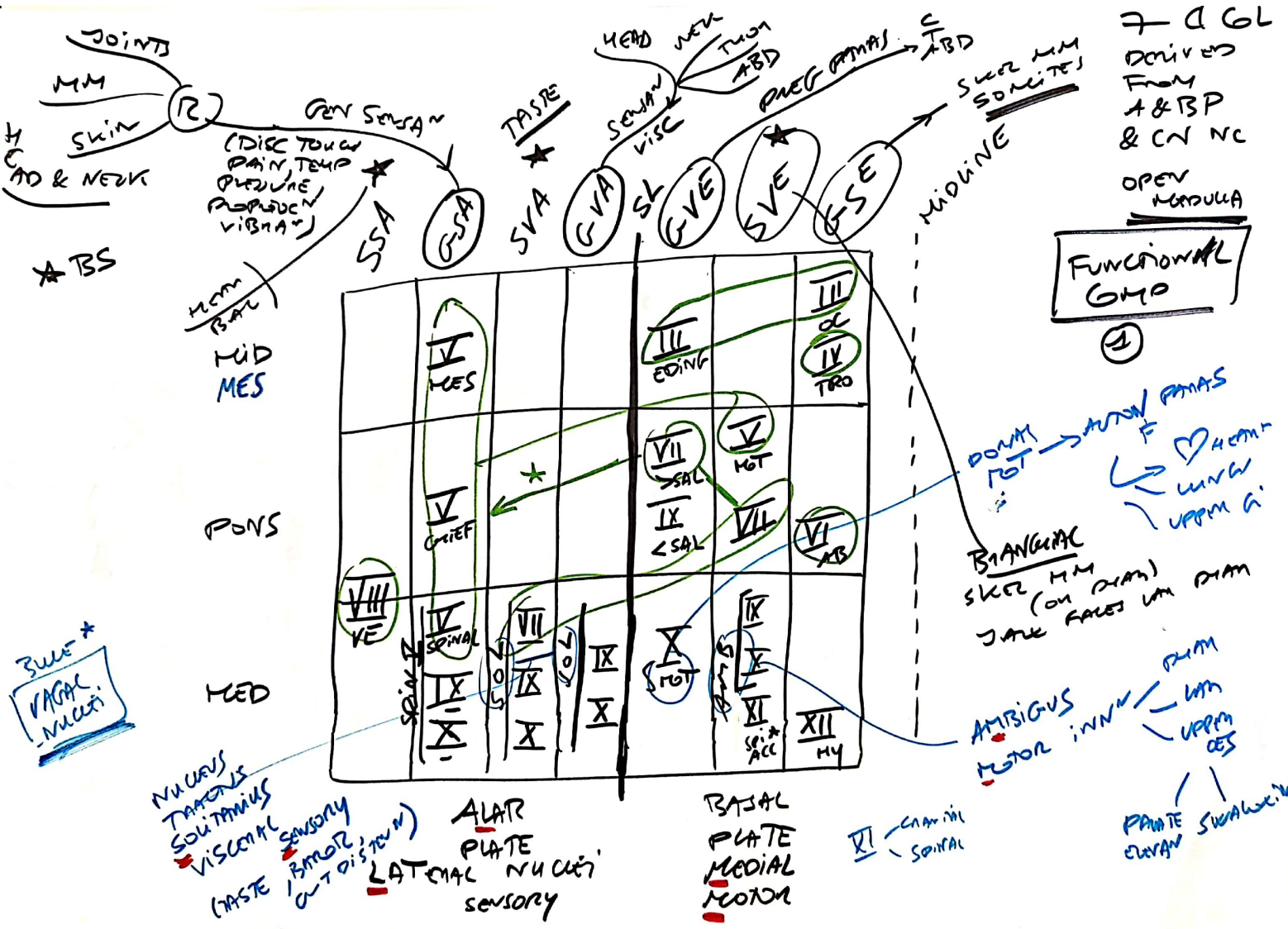
Joint

MIGRATION  
of GL  
DURING  
DRIFT

② GUMMATH  
ORF

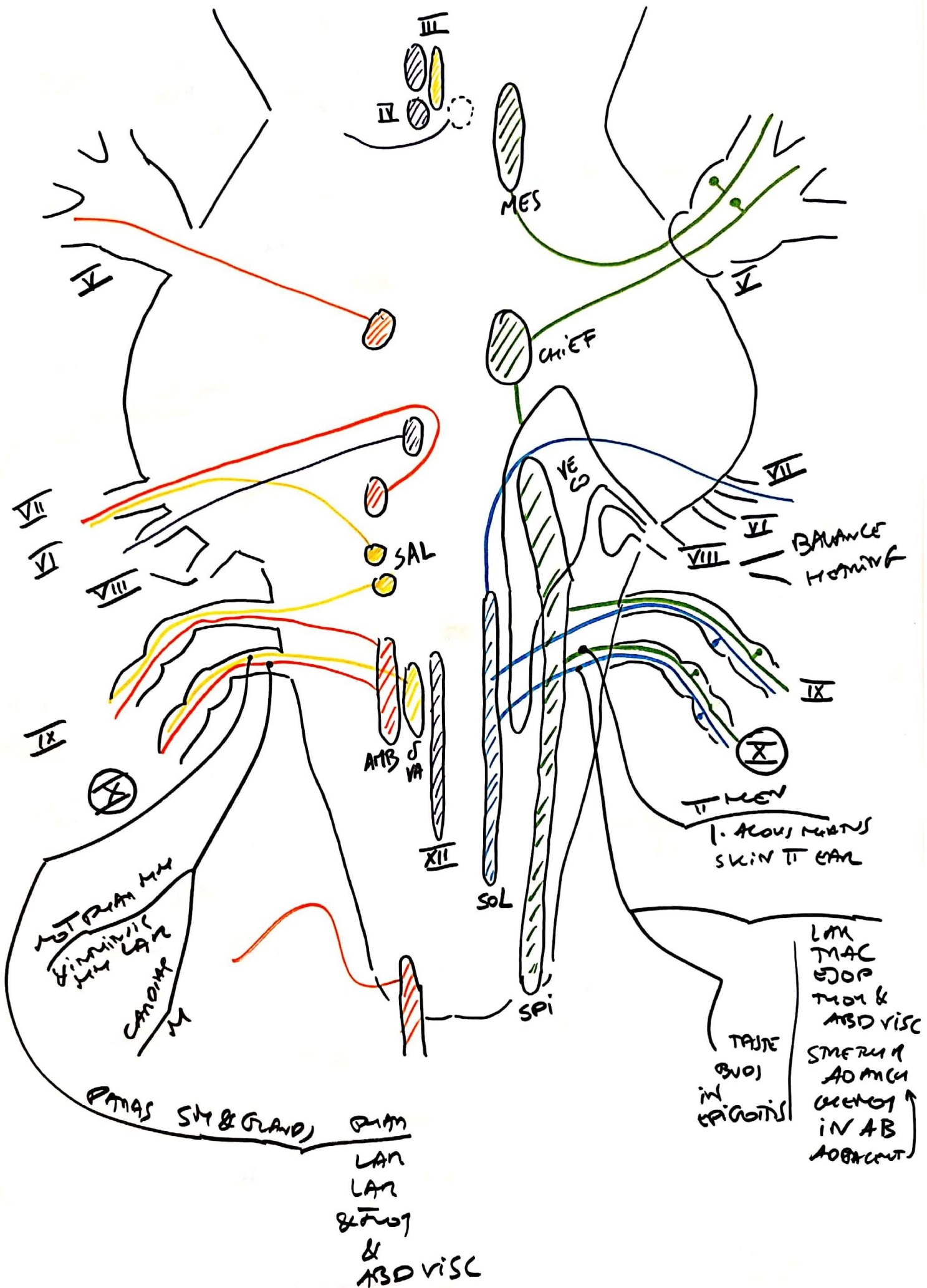
LATERAL  
MOVEMENT  
+  
ADDITIONAL



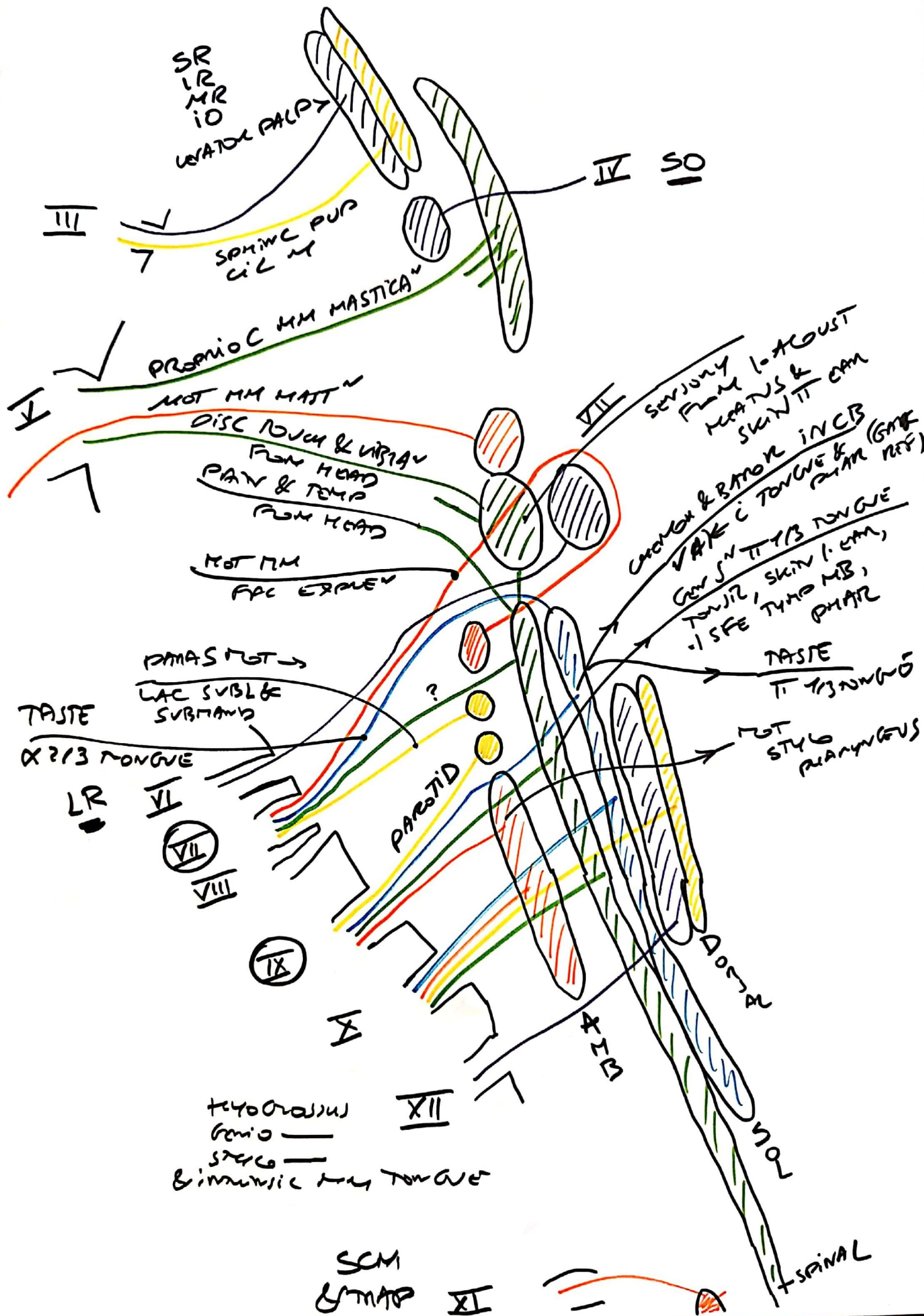


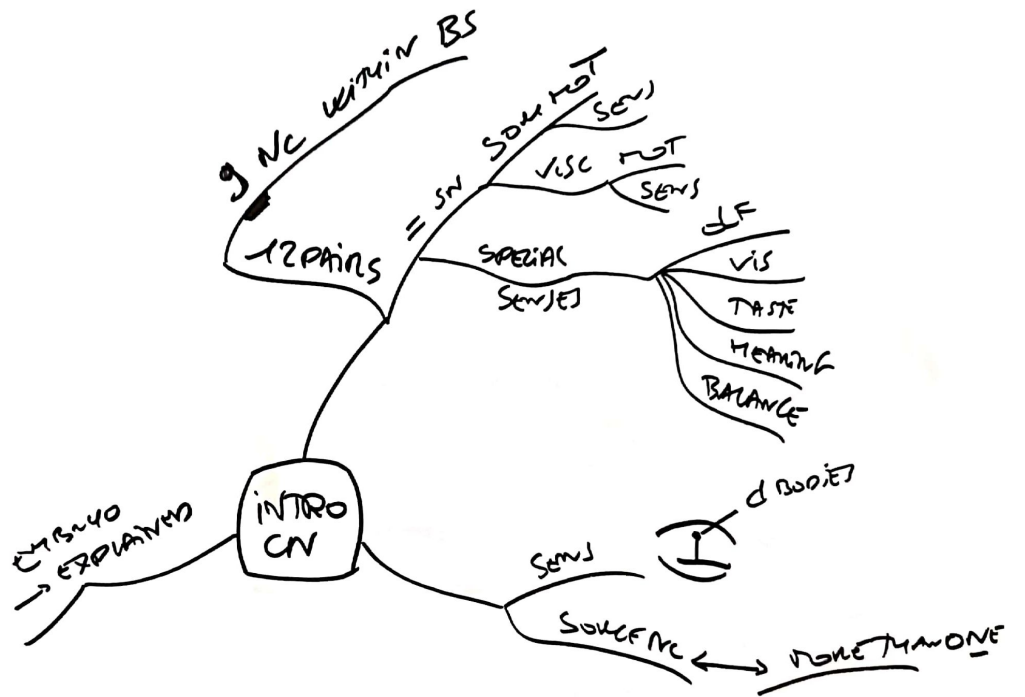


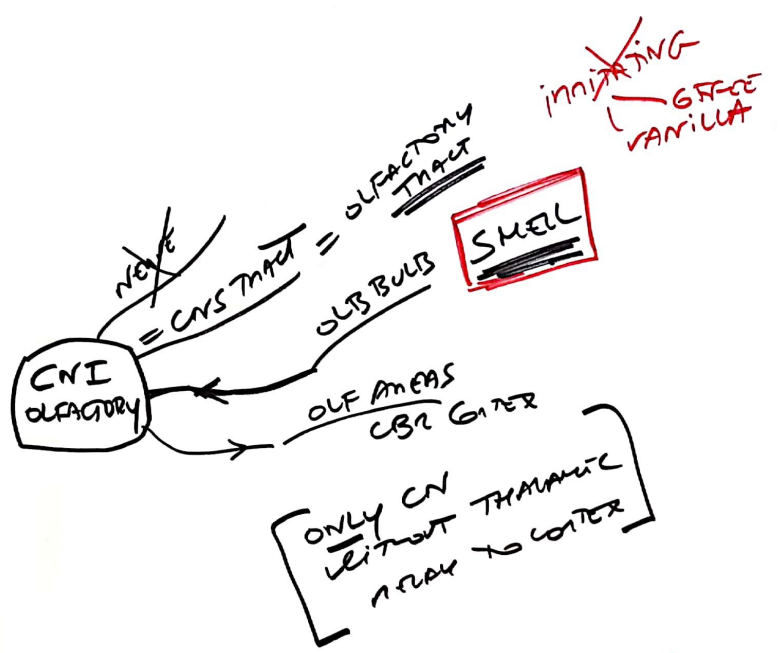








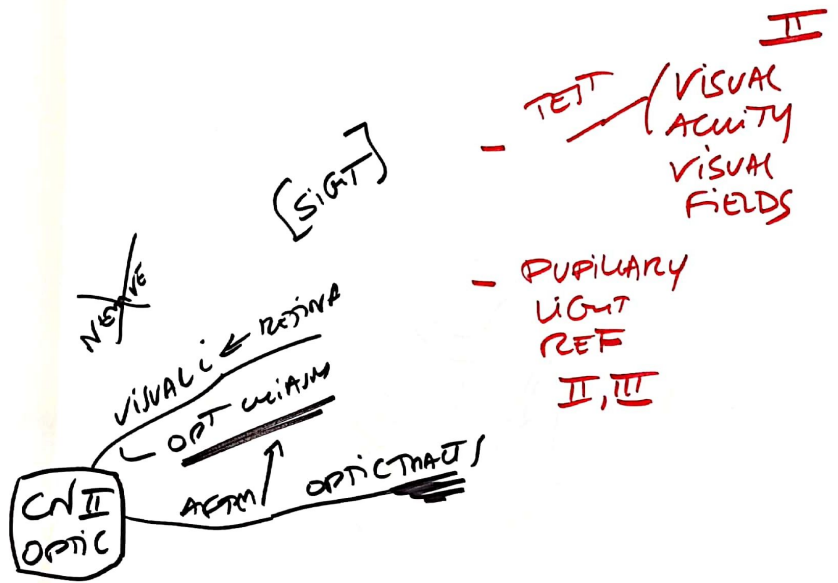




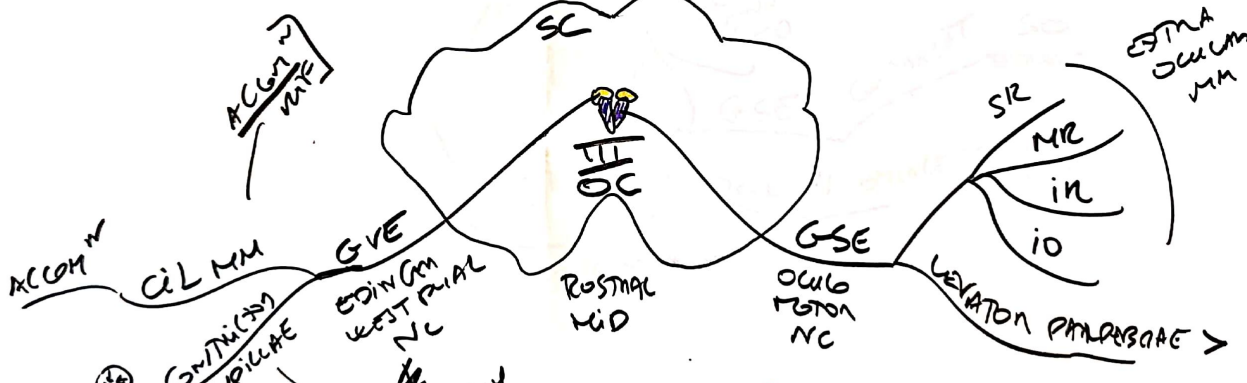
SCREENING

CINICAL





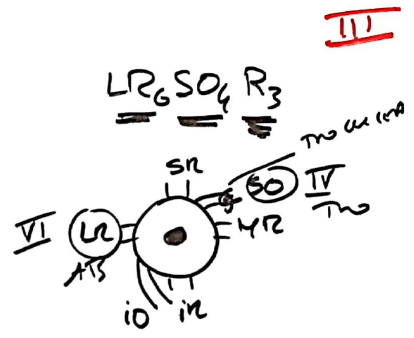
MUSCARINIC R

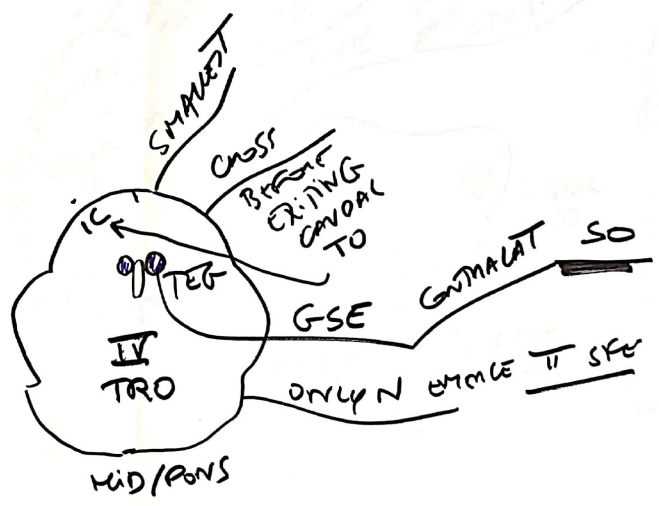


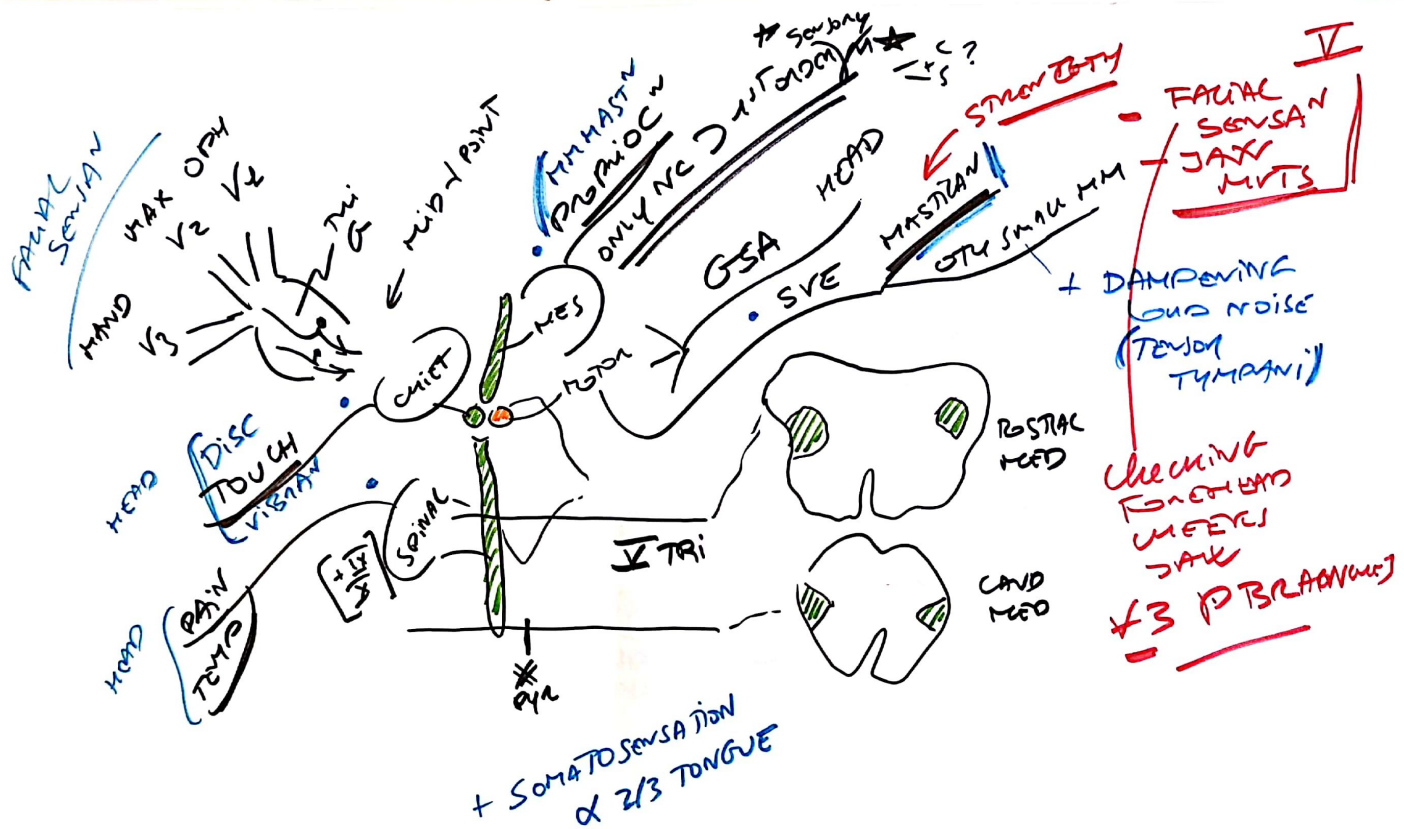
(PUPILLARY  
MOTOR  
NERVE  
II, III)

III OC  
IV Tro  
VI AB  
EXTRA OCUUM  
MOTS

H-TEST



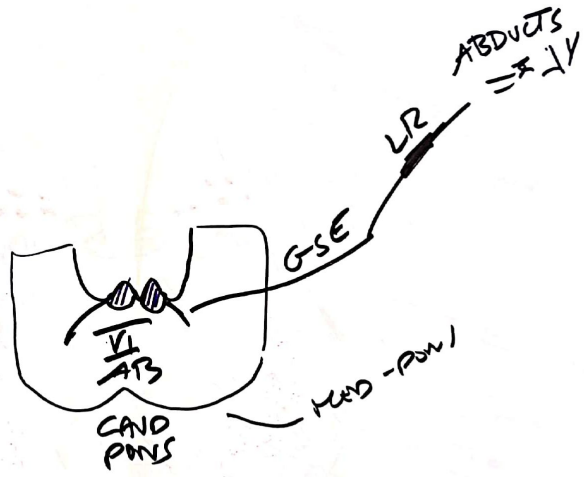




VI :

]

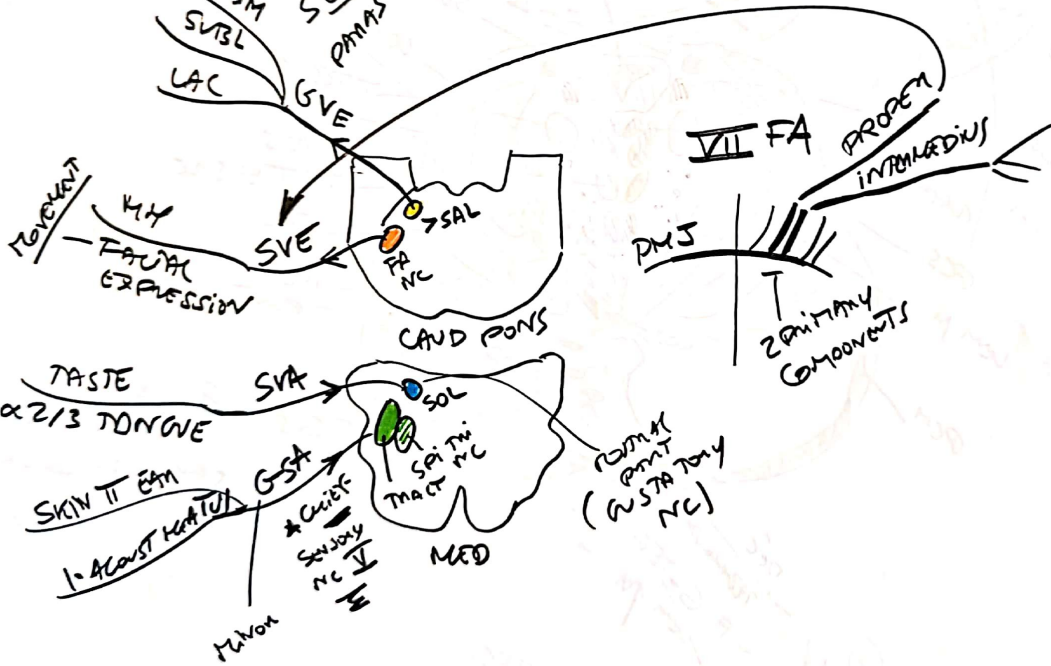
3





- EYE CLEFT (ORBITICULUS OCULI)
- NOSE VOL TUBULAR (STABEDIUS)

SUBM SVISL LAC  
 SECRETOMOTOR PHARYNX + MOUTH NOSE PHARYNX SINUS & SOFT PALATE

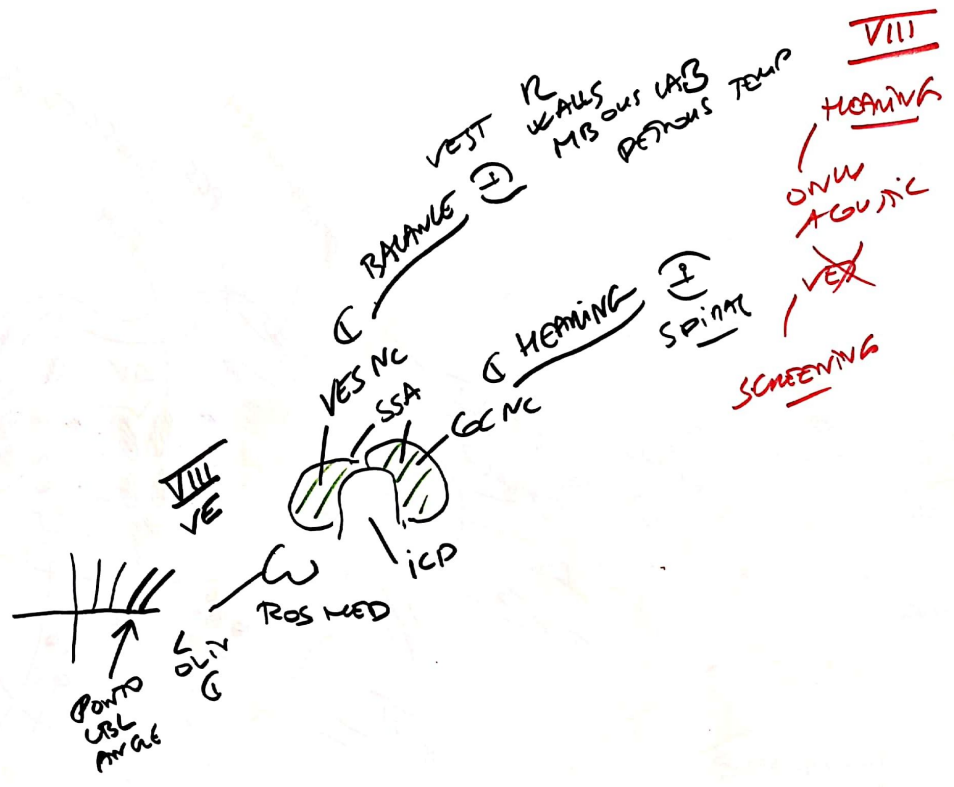


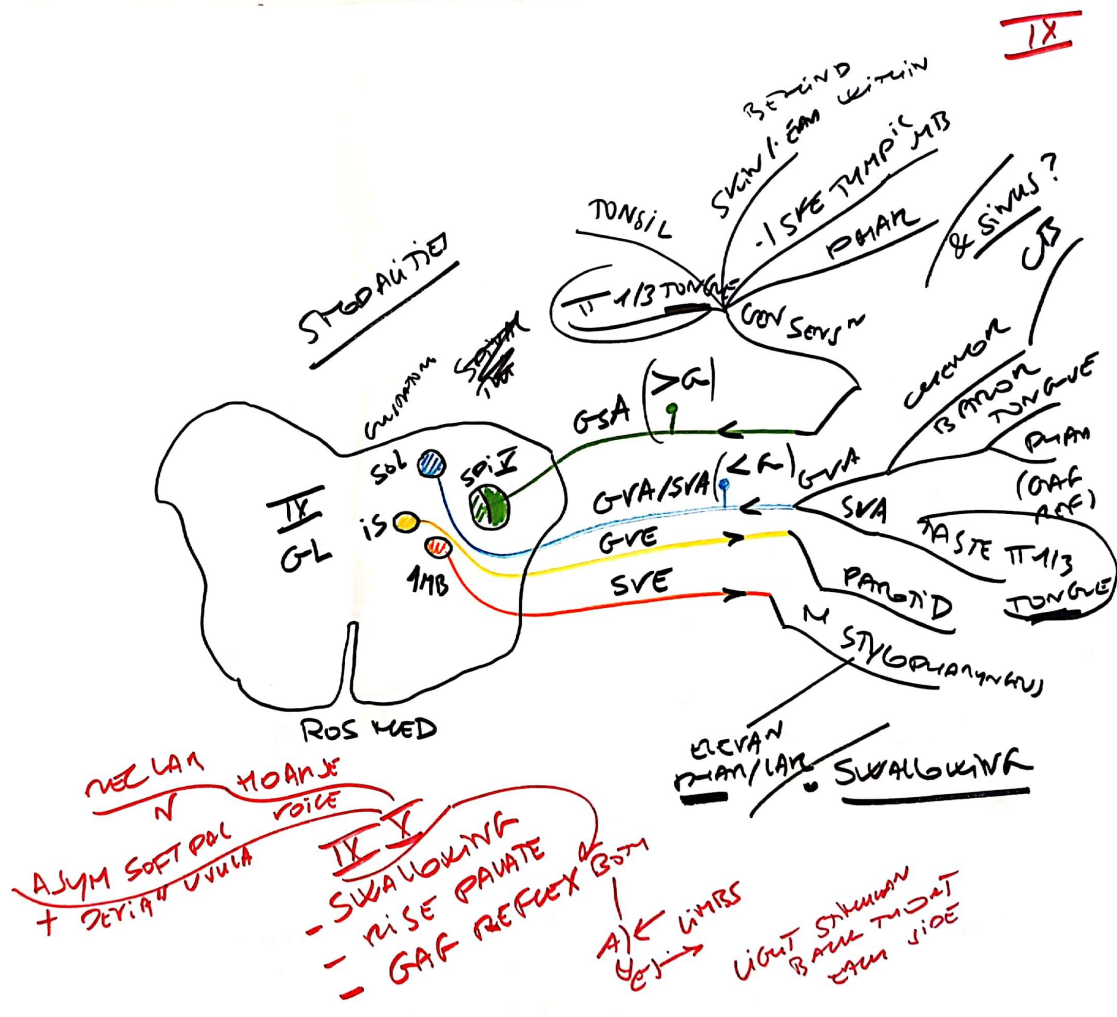
VII  
 EPPEN / FACIAL MOVEMENTS

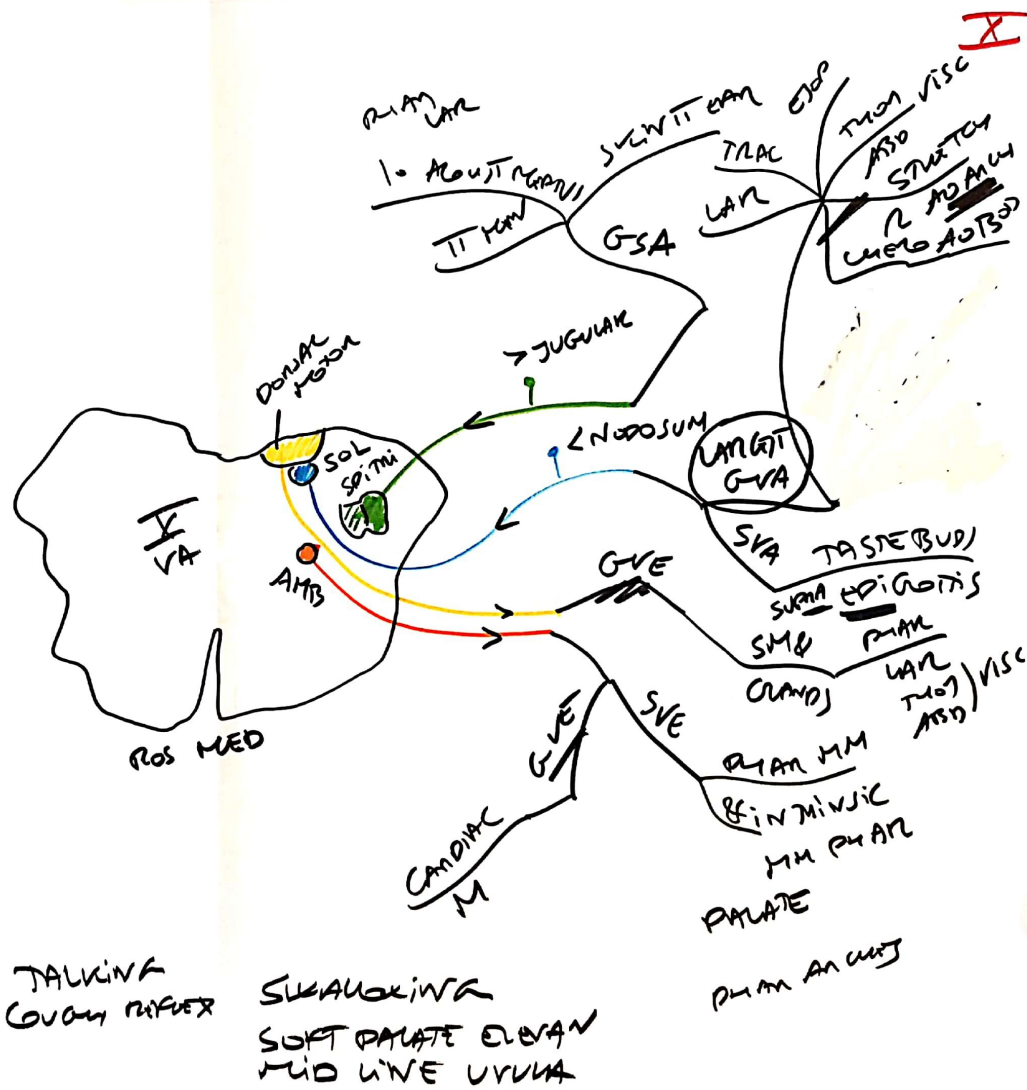
MOTOR - lower UPPER

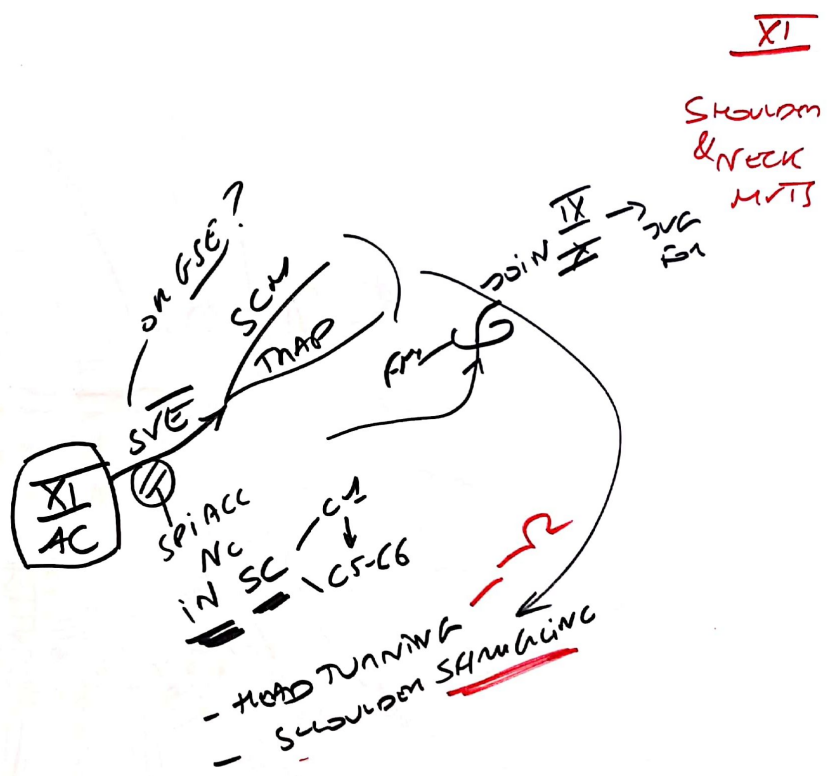
SYMMETRY?

- WRINKLE FOREHEAD
- CLOSE EYES TIGHTLY
- SHOW TEETH & SMILE







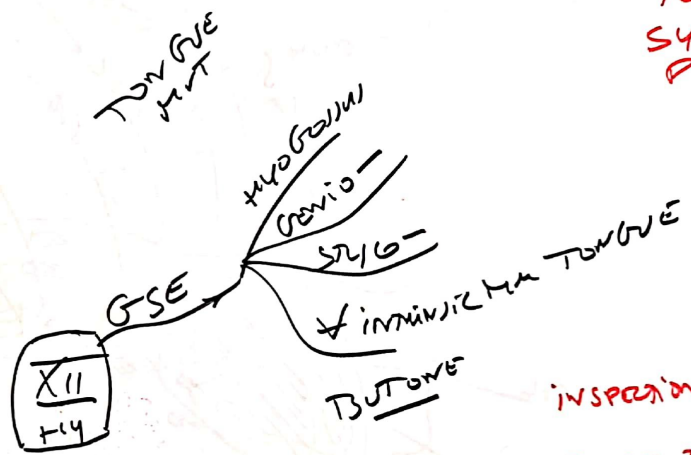


XI  
 SHOULDEN  
 & NECK  
 M/T'S



XII

TONGUE  
SYM &  
POSITION



INSPECTION  
POSTURE TONGUE  
FOR ASYM  
& DEVIAN

