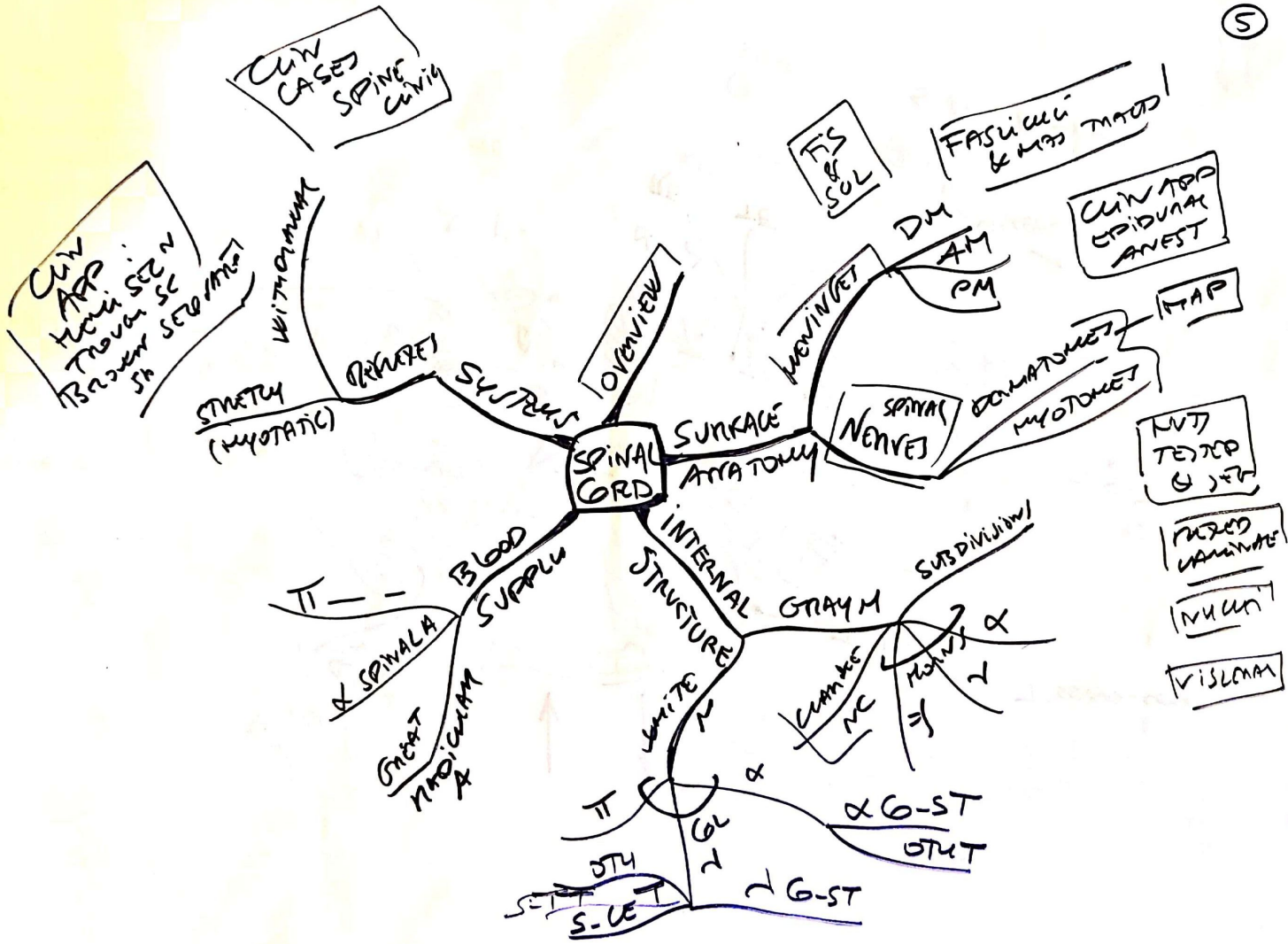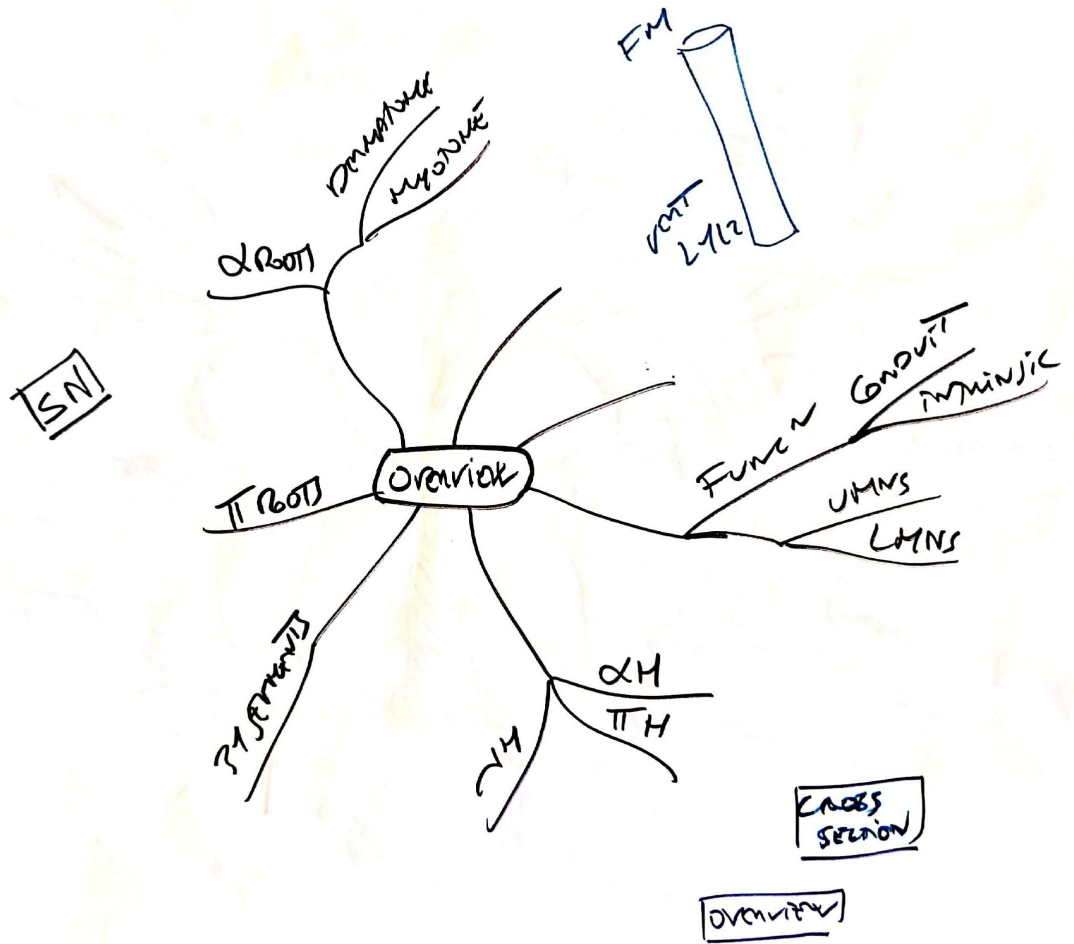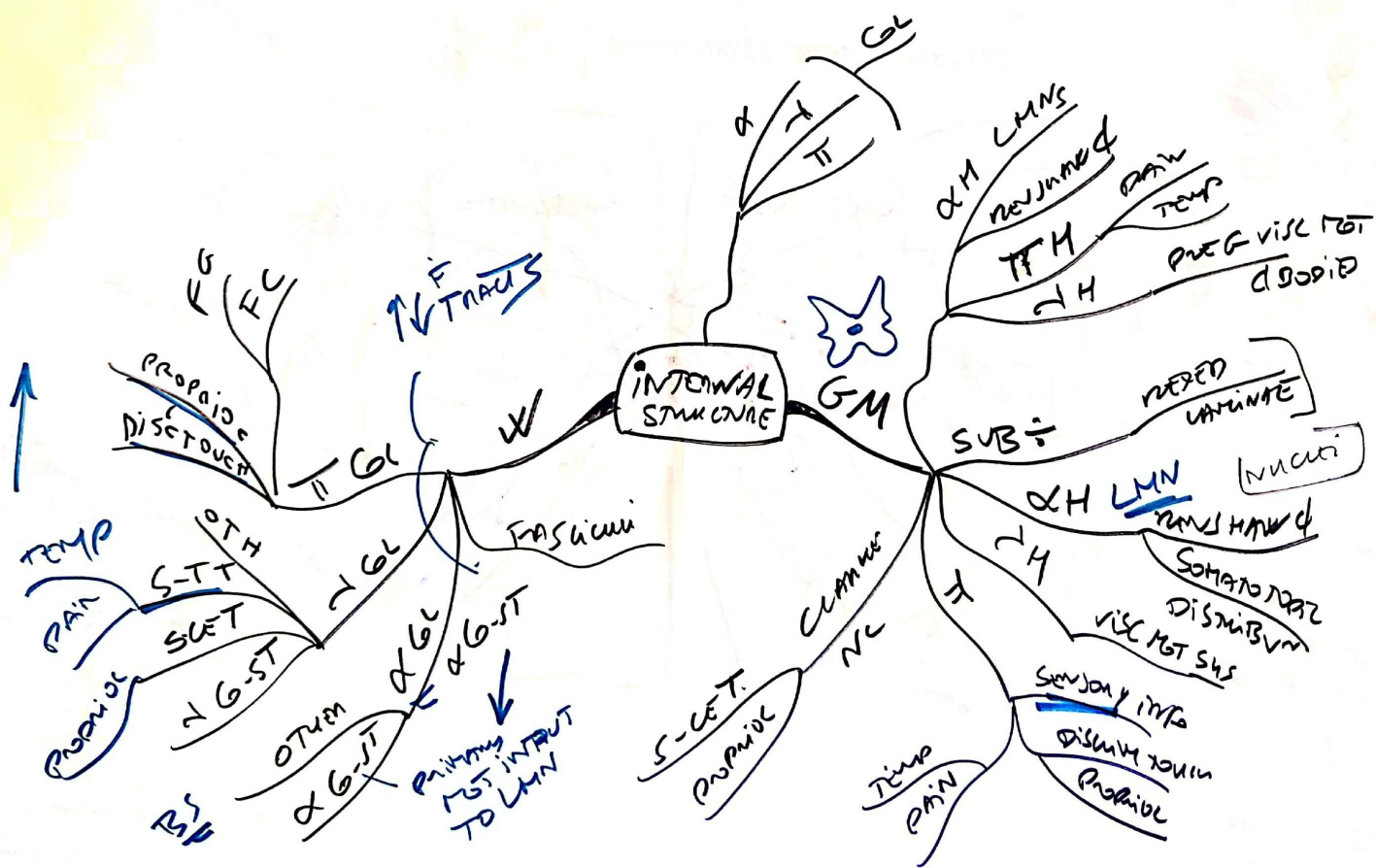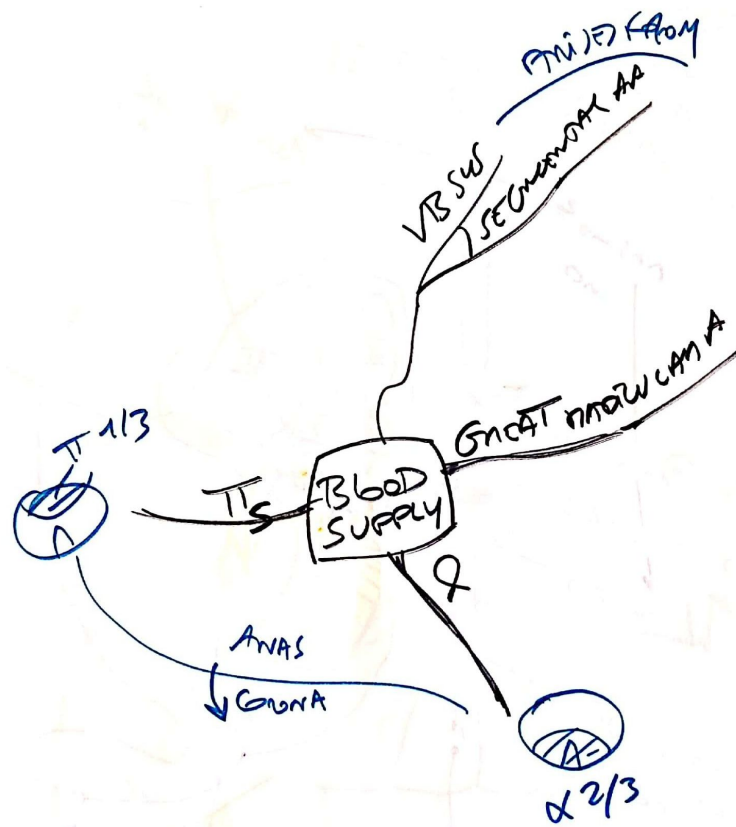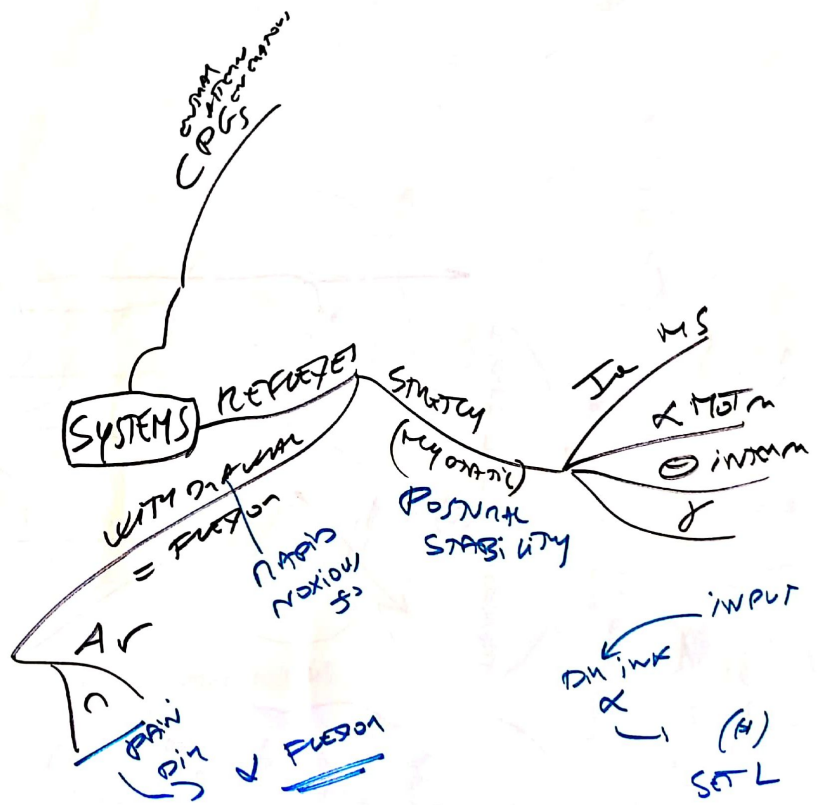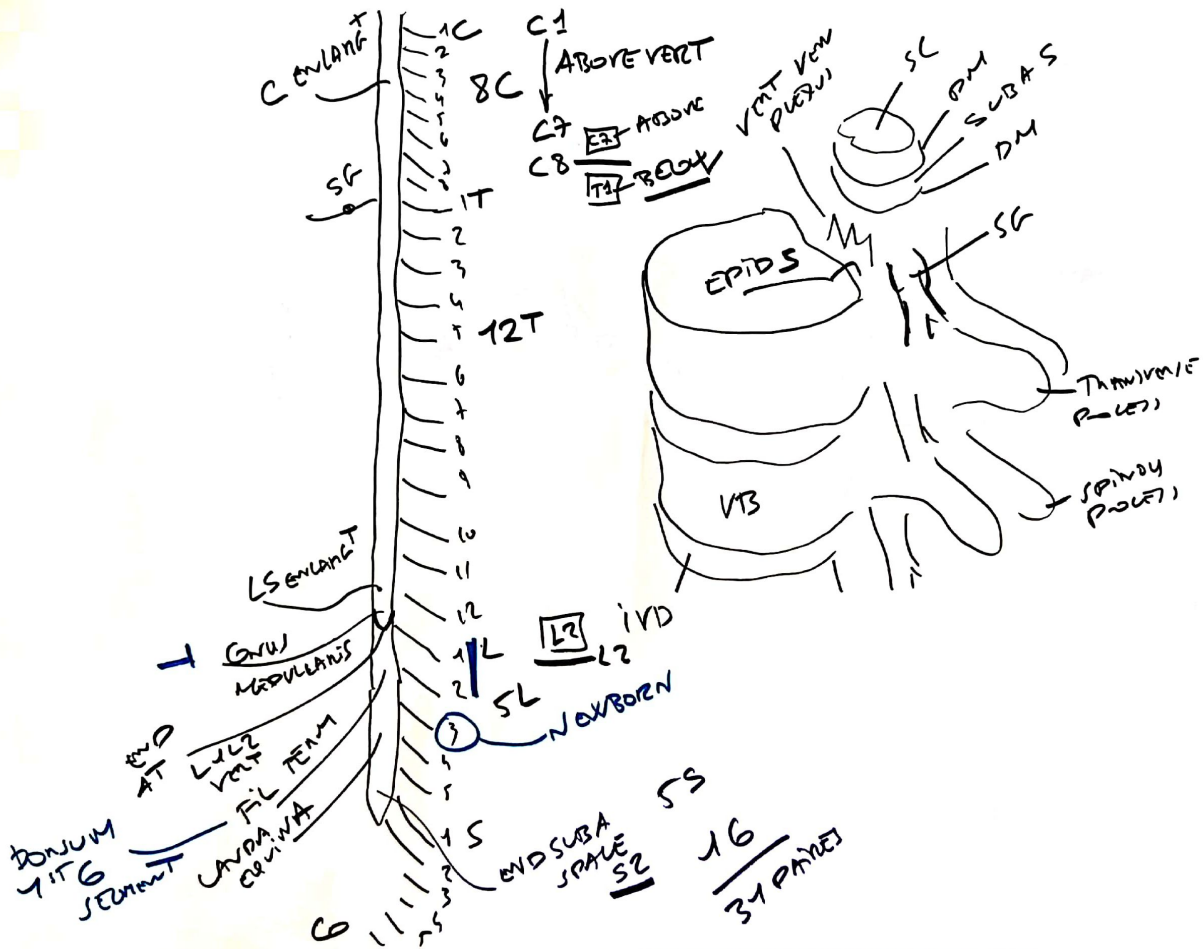
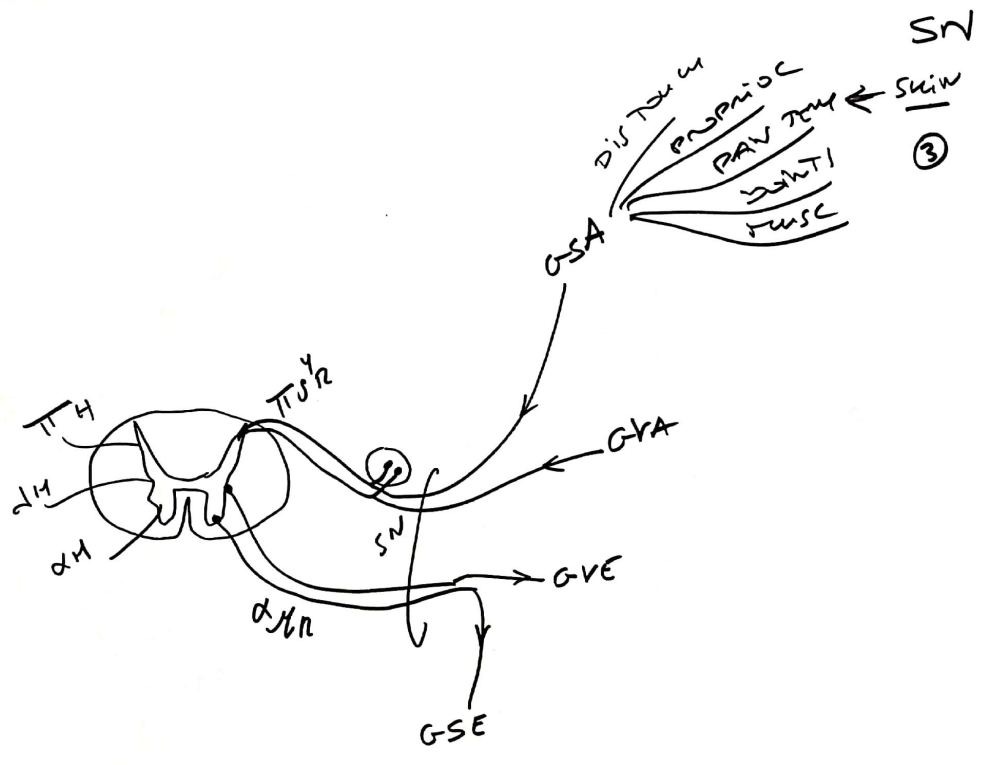




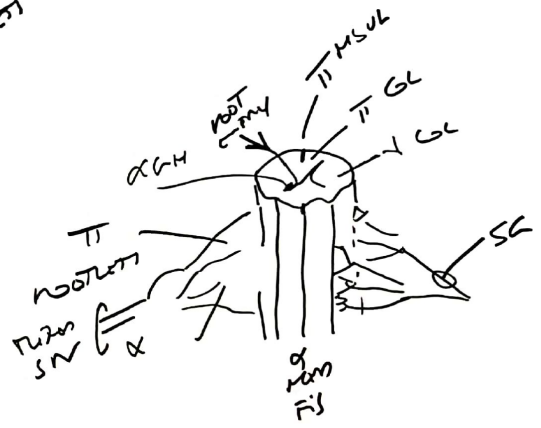
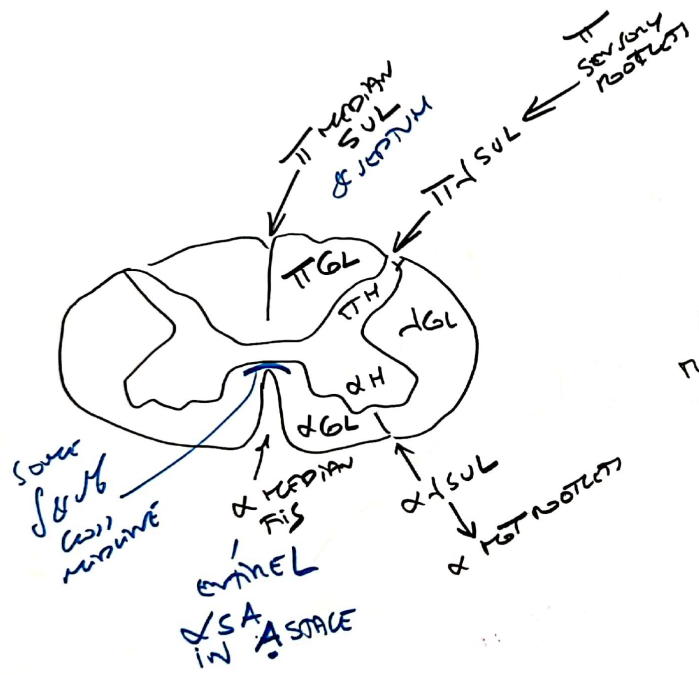
OVERVIEW  
SC  
②

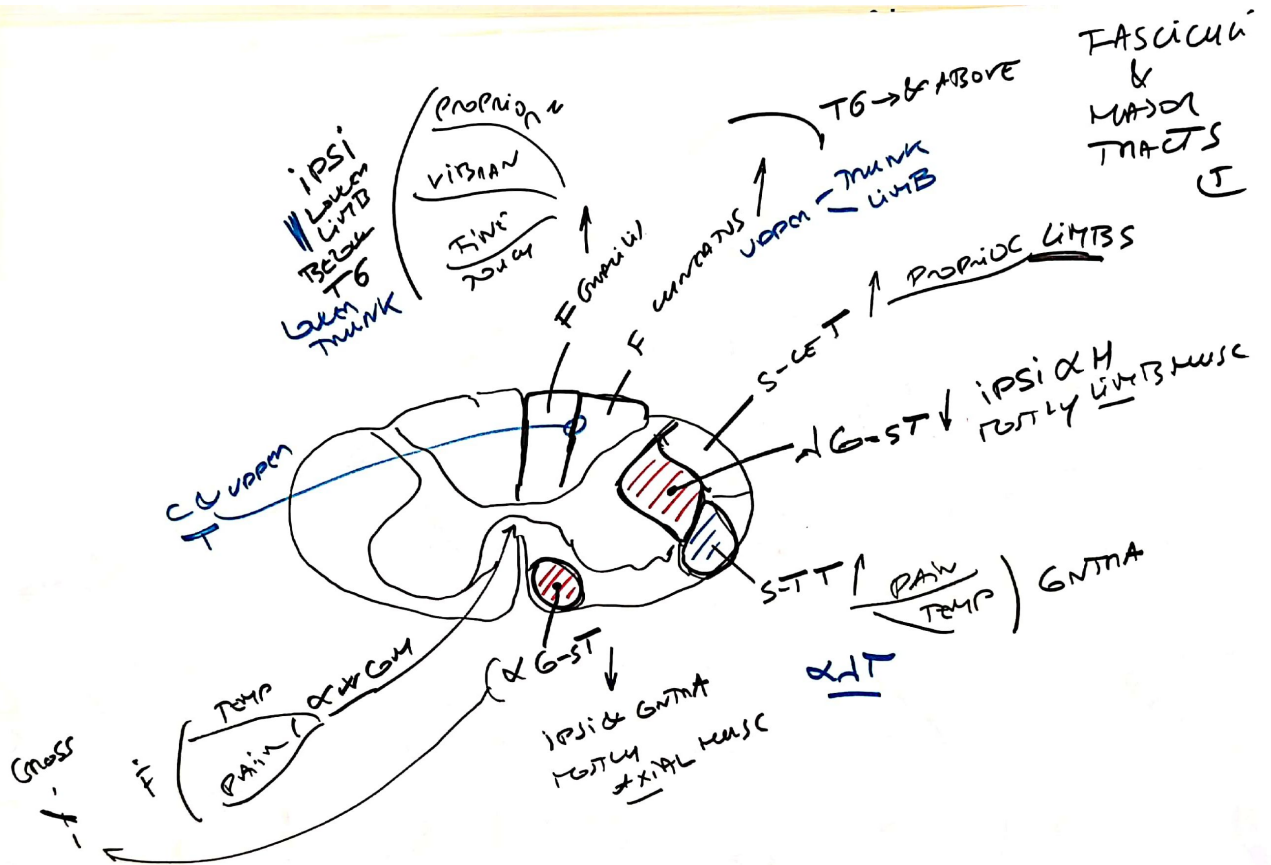




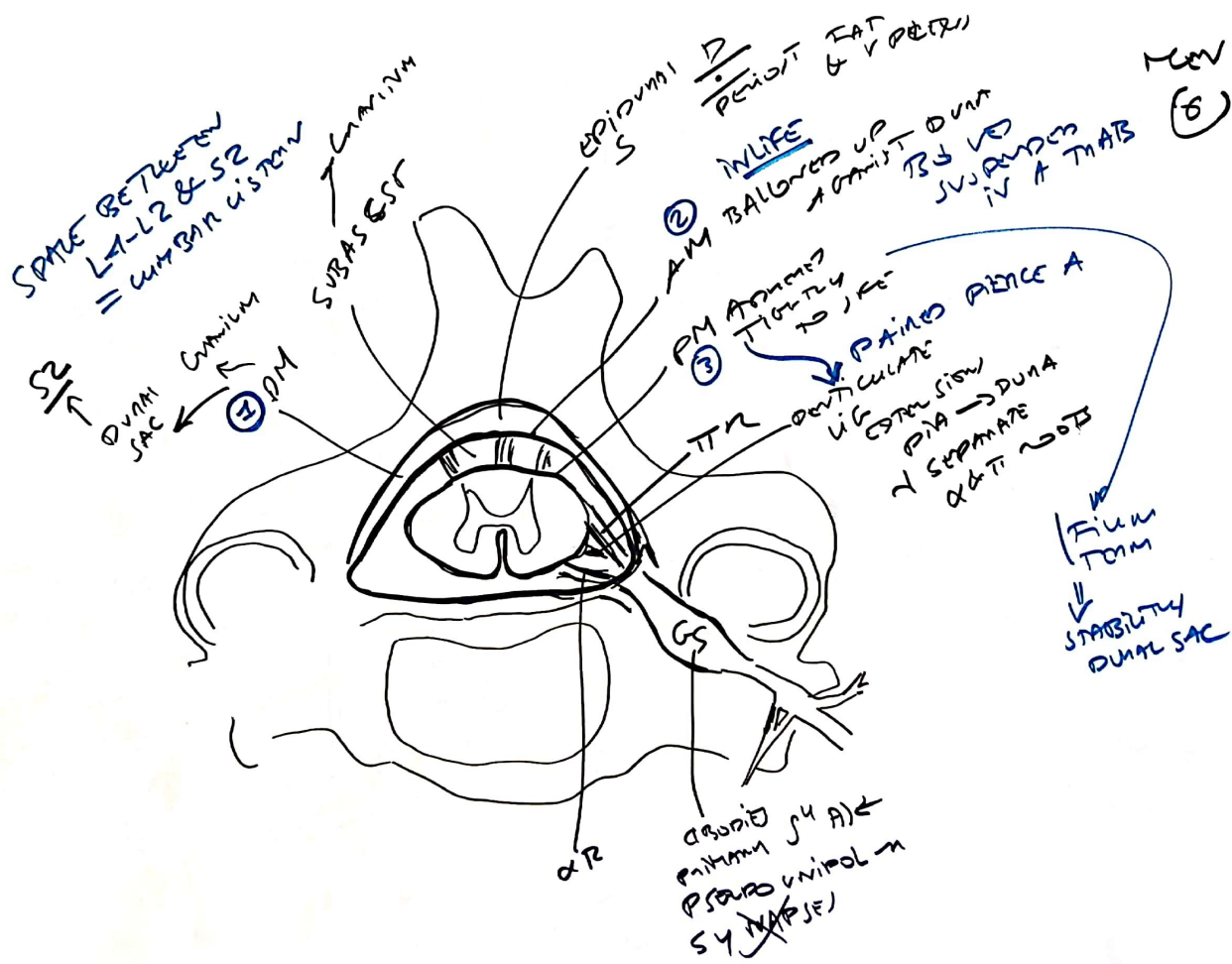


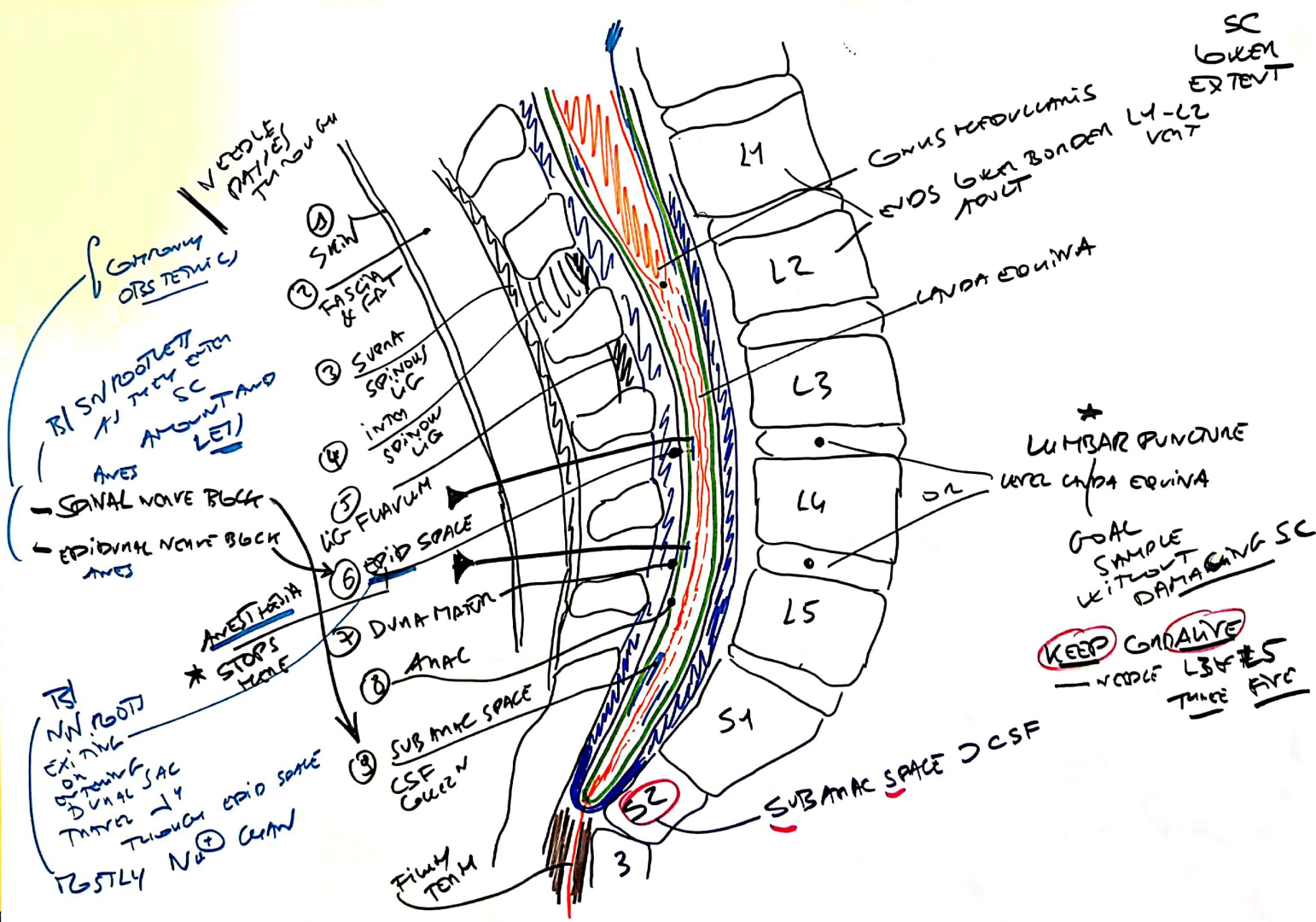
FISSURE & SULCI (K)



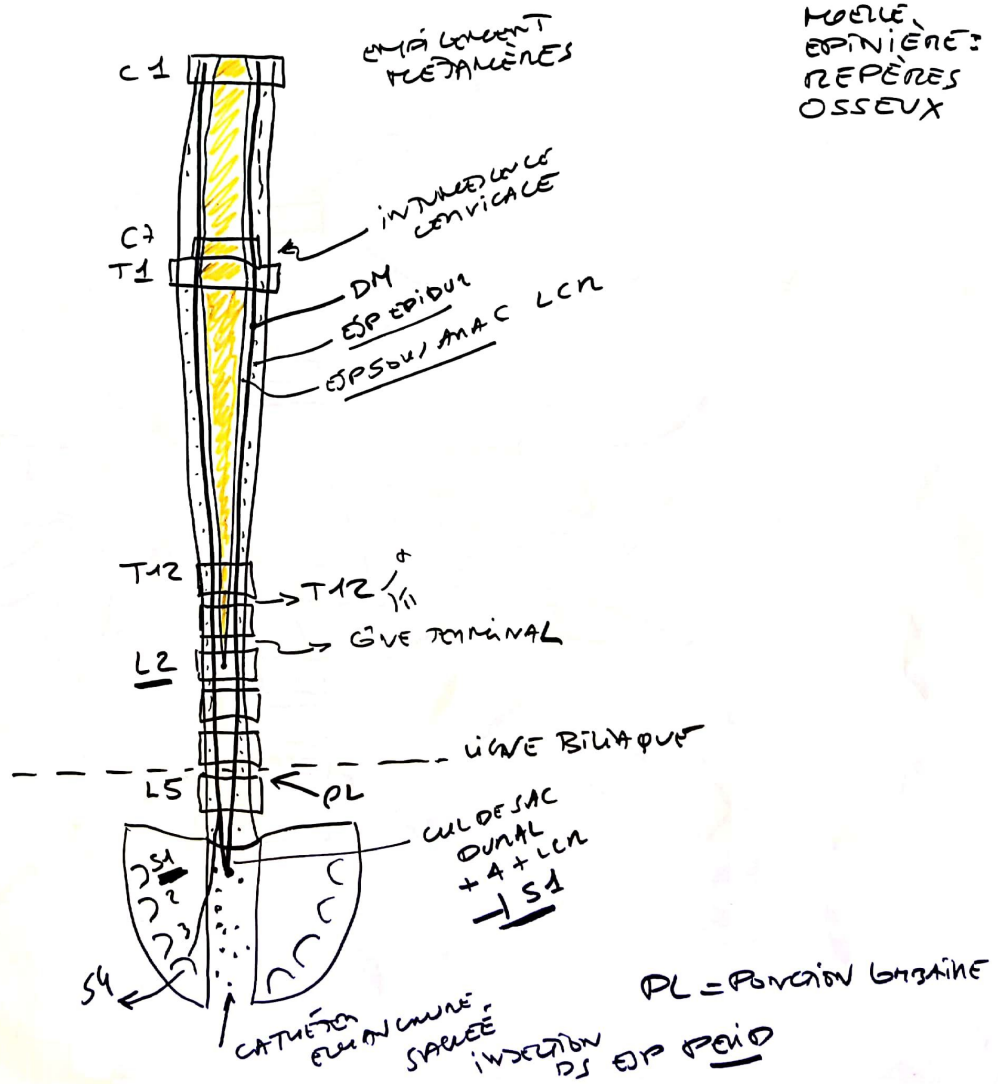


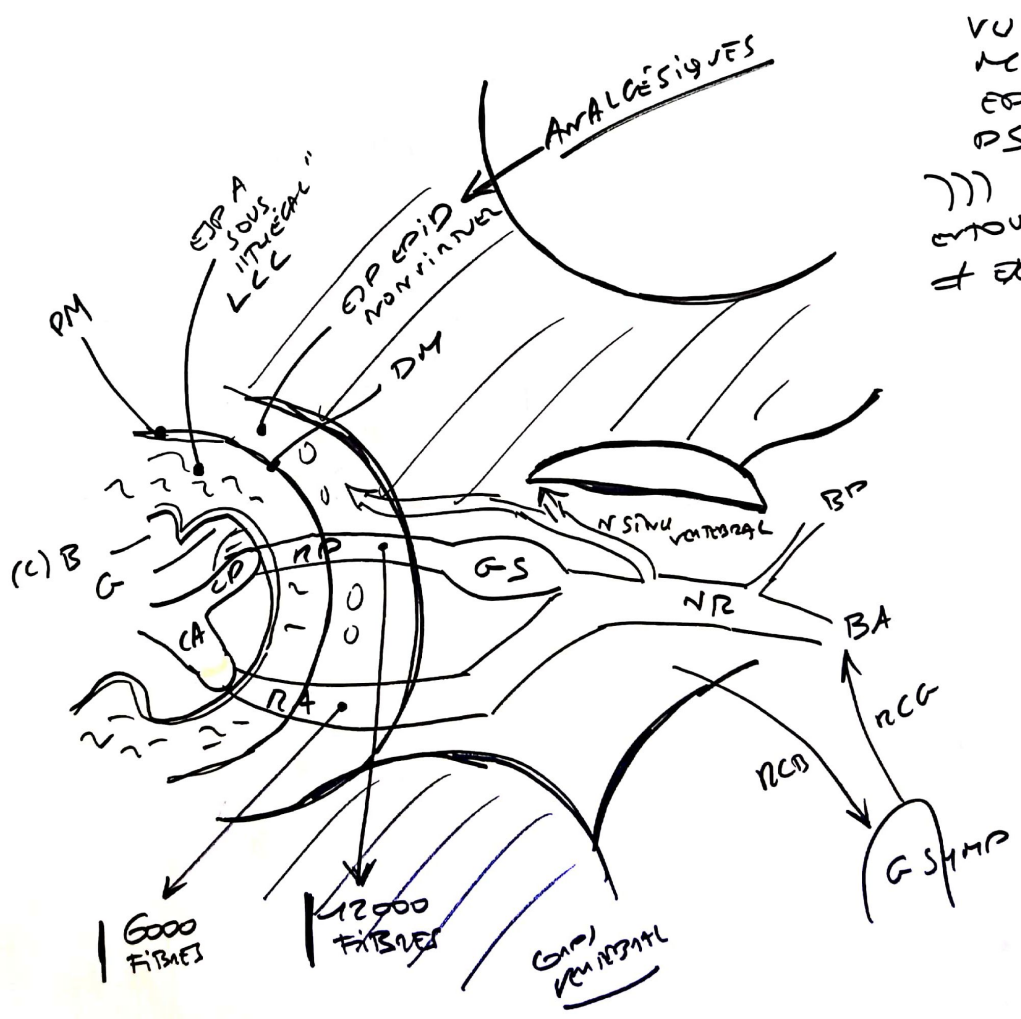


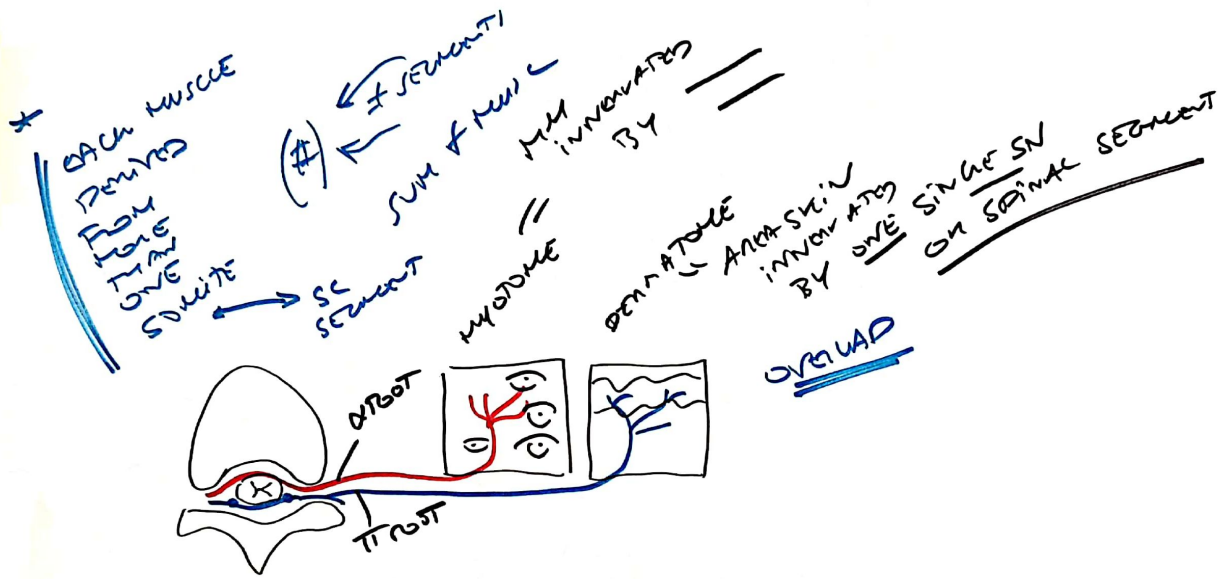




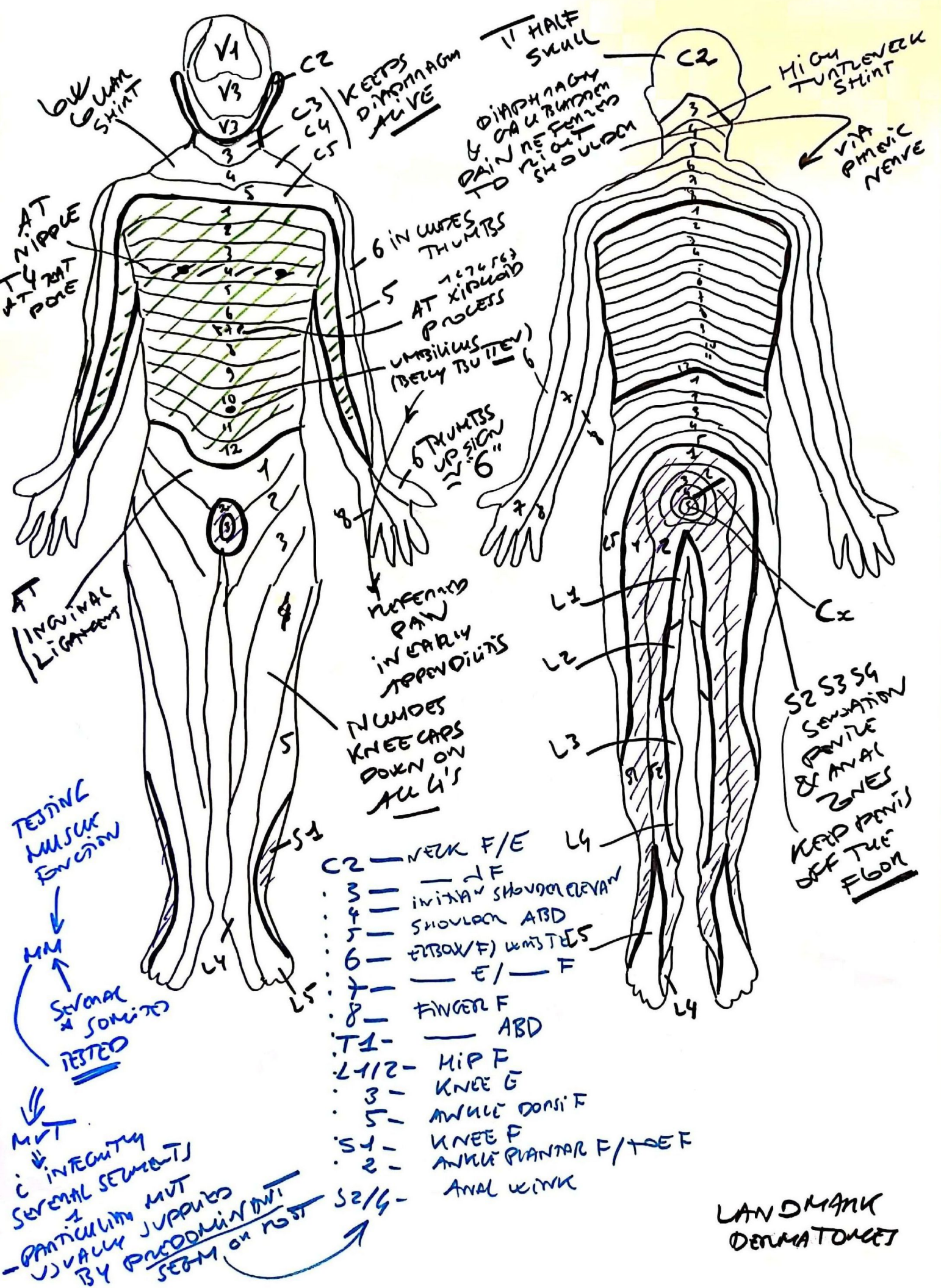








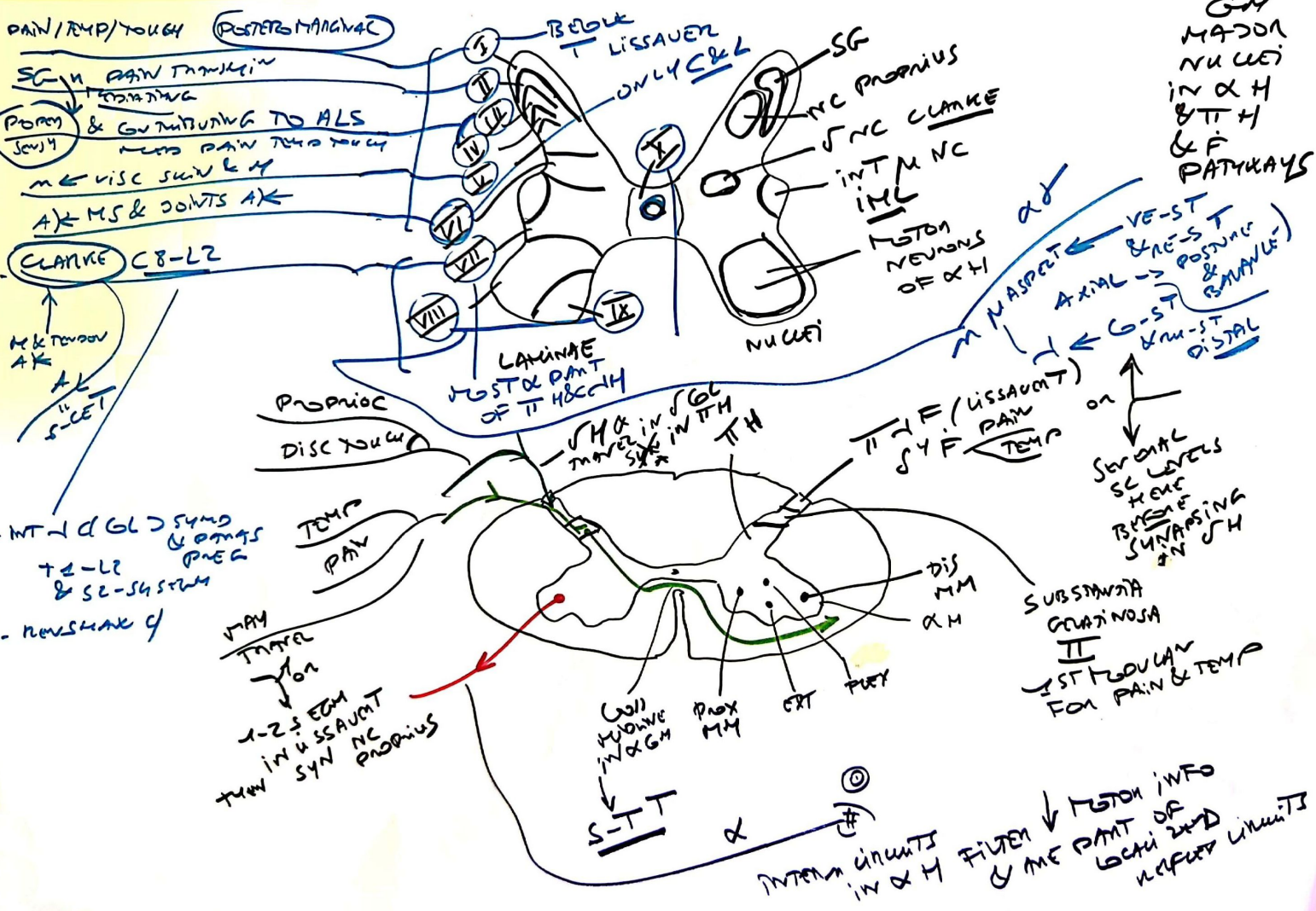




- C2 — NECK F/E
- 3 — — F
- 4 — INTRAV. SHOULDER CLAVAN
- 5 — SHOULDER ABD
- 6 — ELBOW/F) WRISTES
- 7 — — E/ — F
- 8 — FINGER F
- T1 — — ABD
- T2-12 — HIP F
- 3 — KNEE G
- 5 — ANKLE DORSI F
- S1 — KNEE F
- 2 — ANKLE PLANTAR F/TOE F
- S2/4 — ANAL WINK

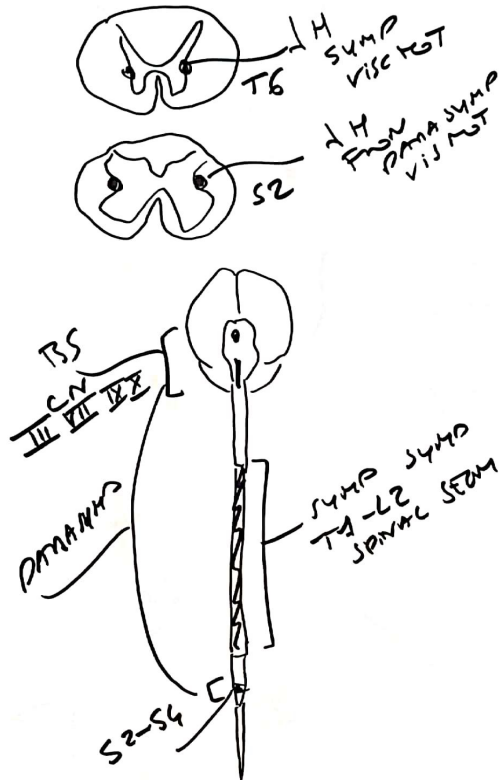
LANDMARK DERMATOMES

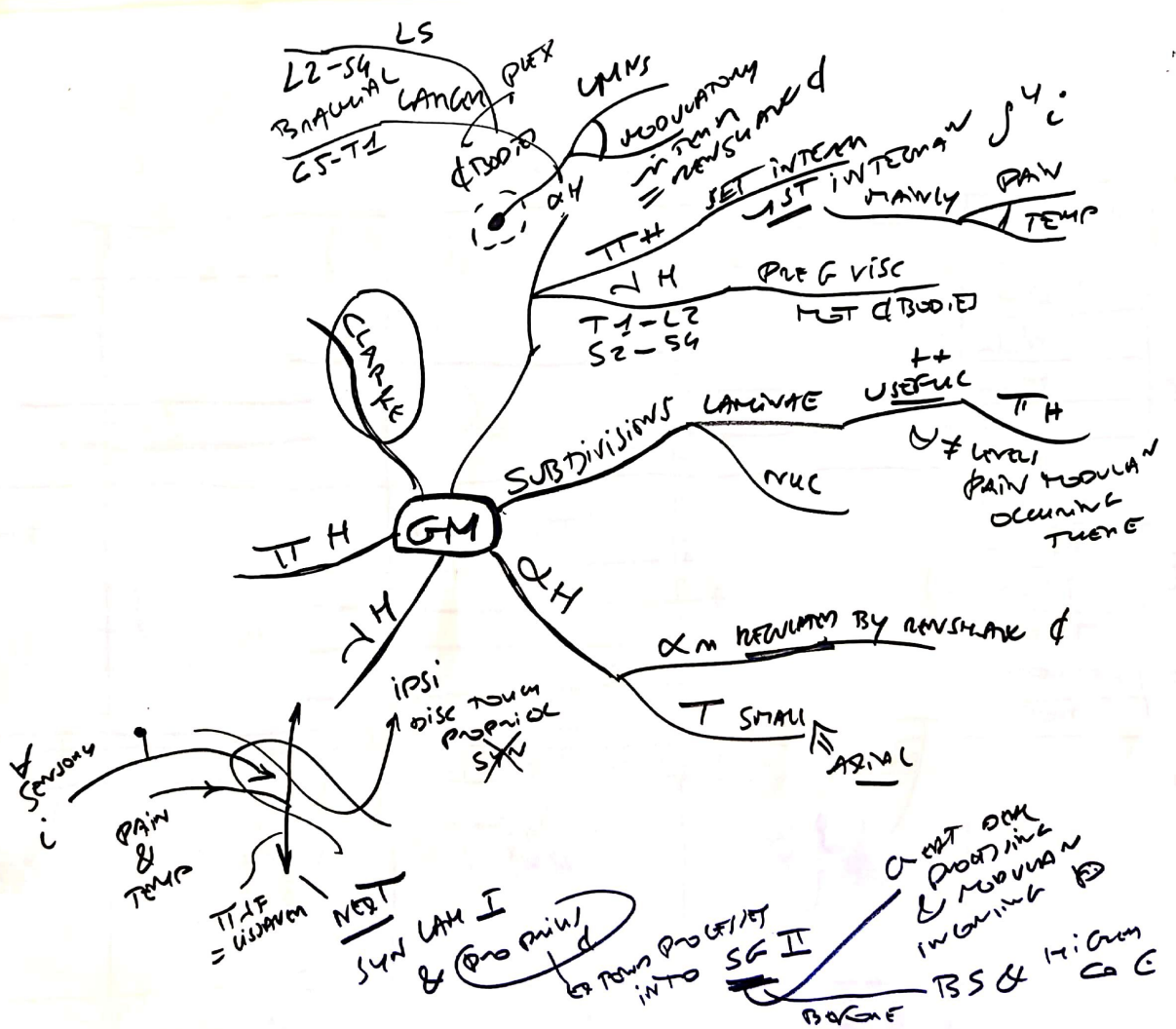


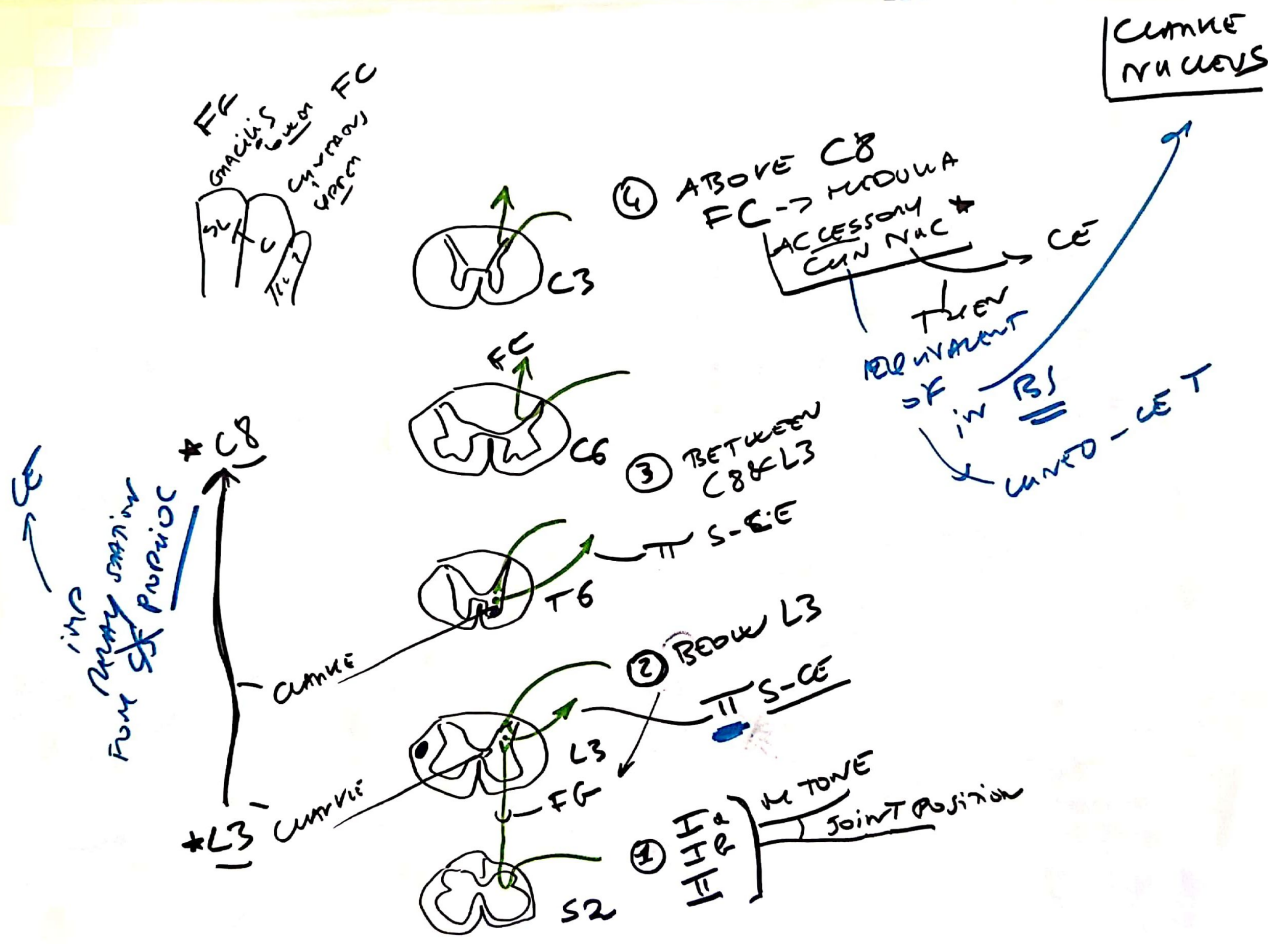




Visceral  
NS

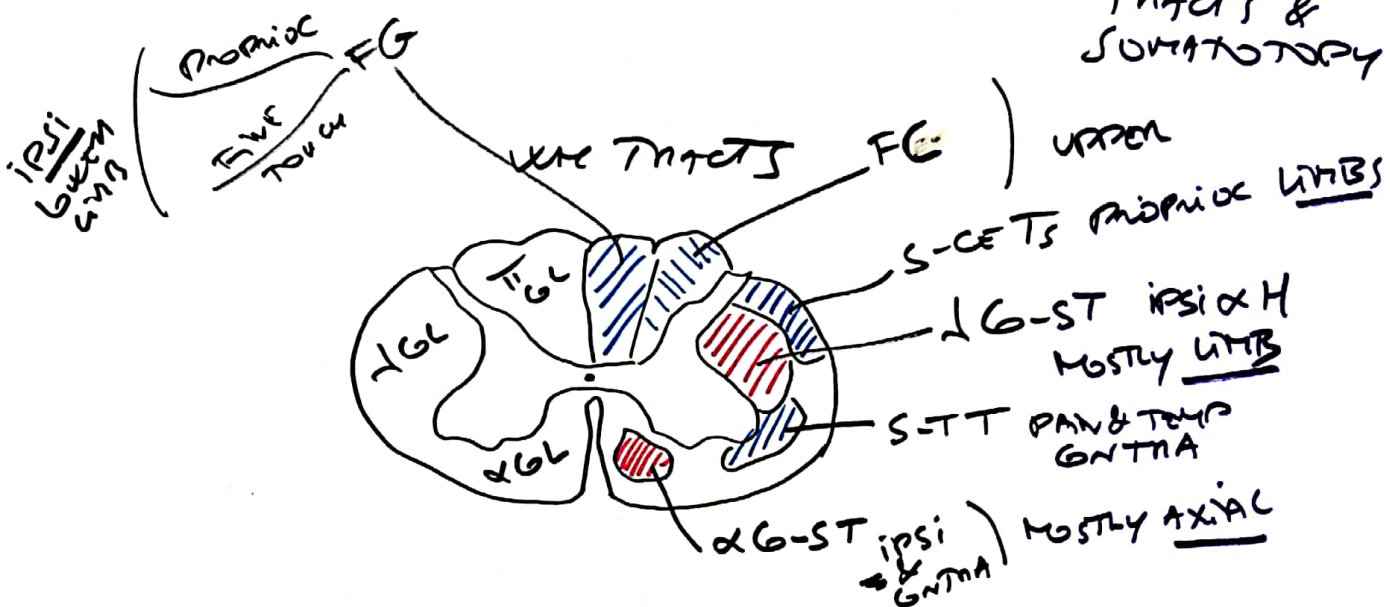




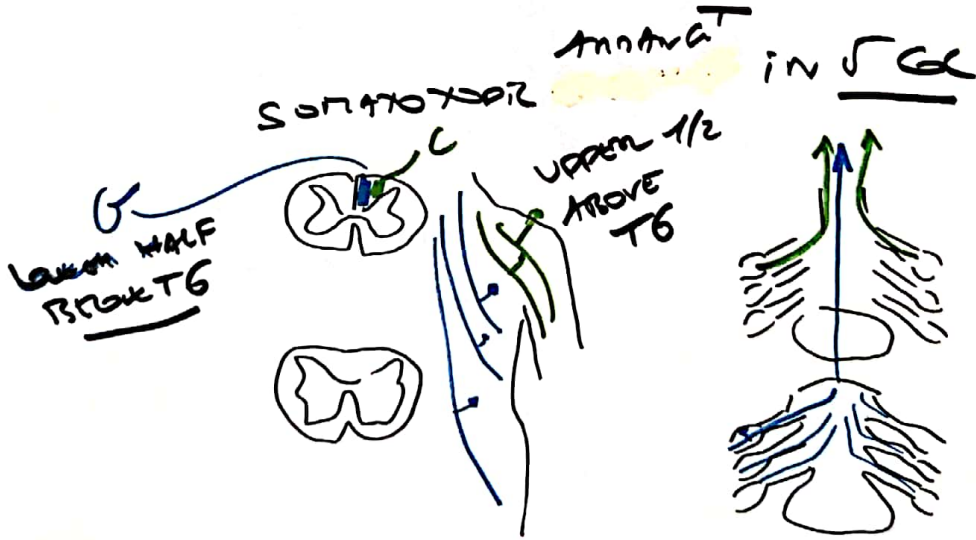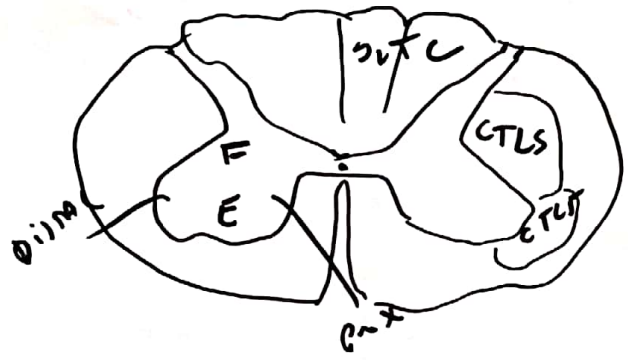




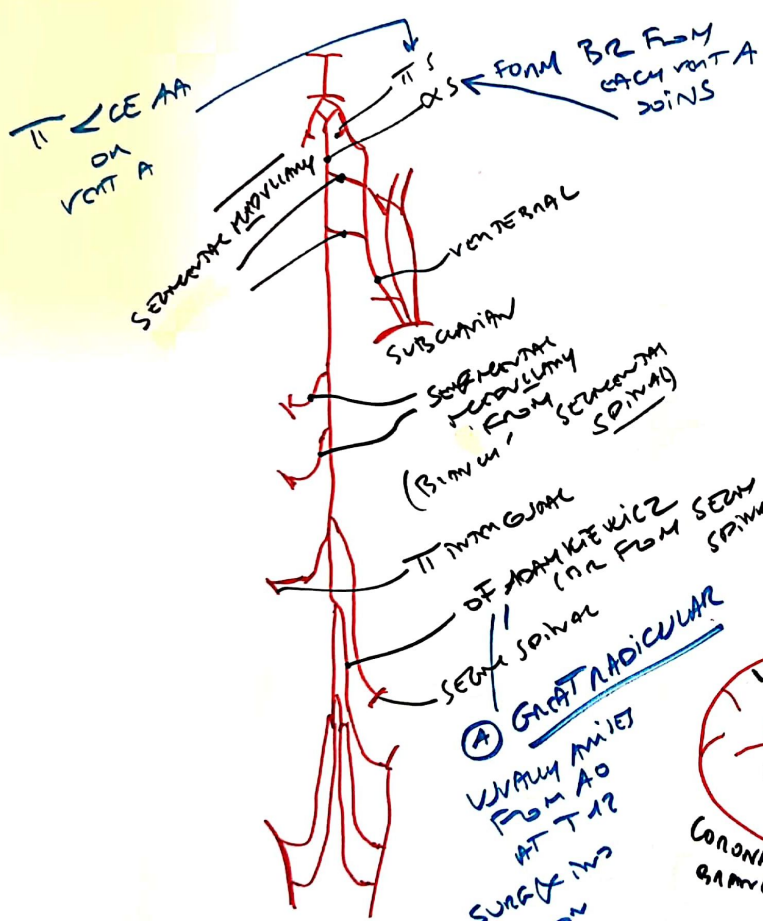
WHITE MATTER: TRACTS & SOMATOTOPY



SOMATOTOPIC DISTURBANCE IN WMT

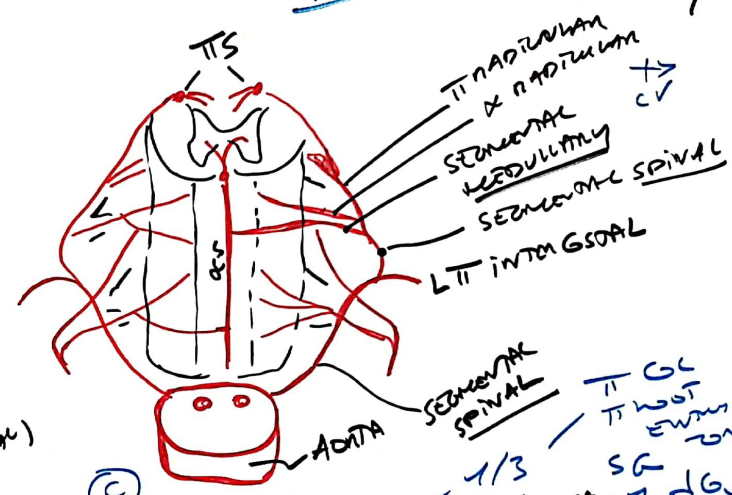




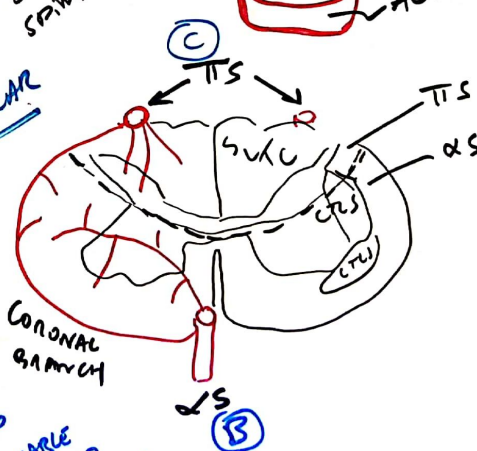


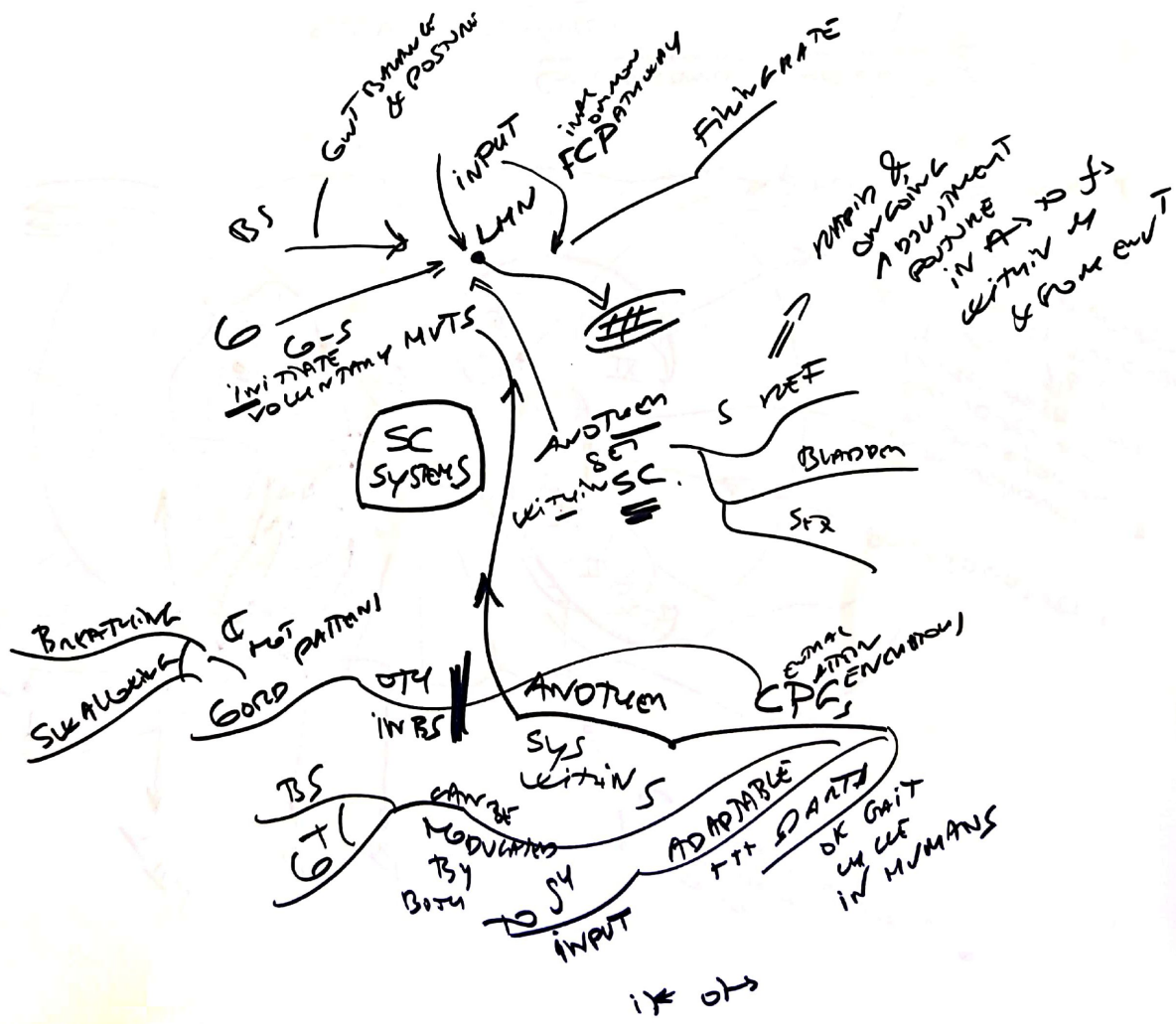
(A) GREAT RADICULAR  
 VASCULAR ARTERY FROM AO AT T12  
 SURFACE HAS DISTANCE  
 USE LS G10  
 ALSO VASCULAR IN AO ANEURYSM LOCATED BELOW THAN

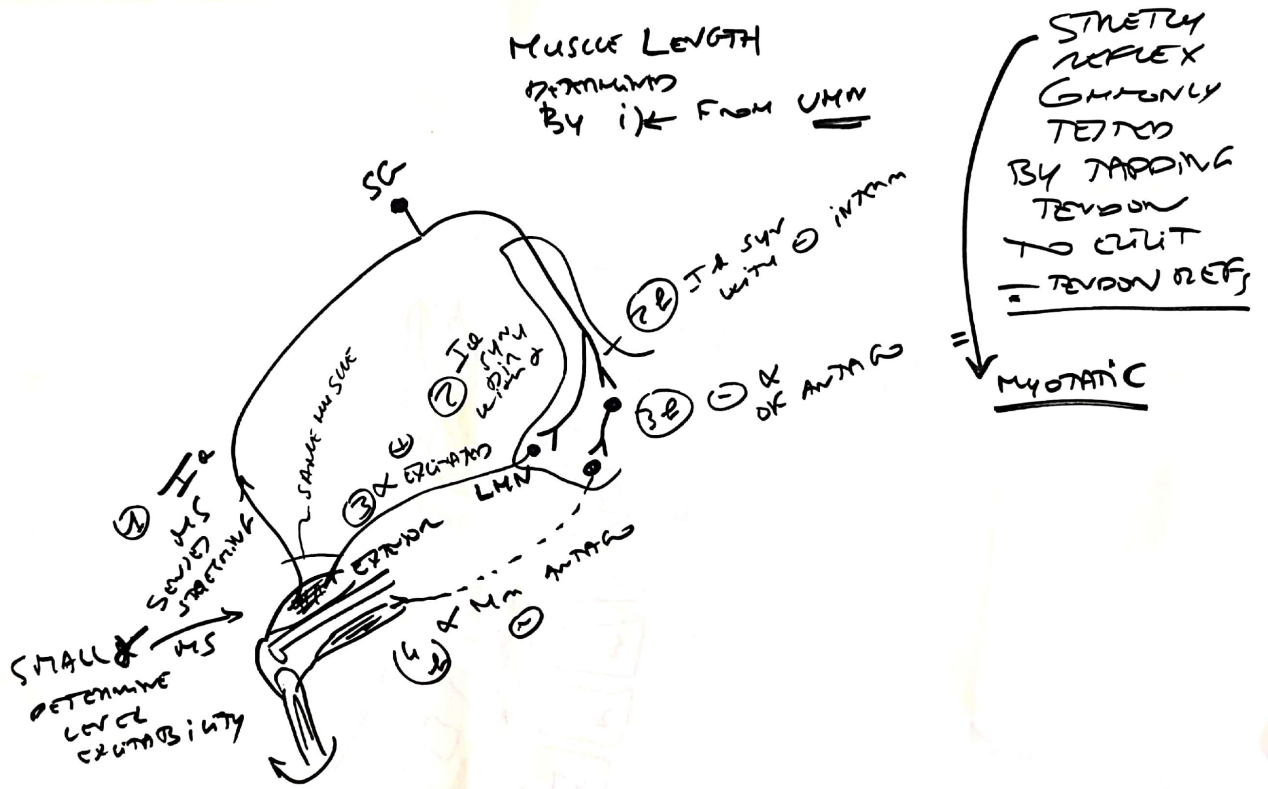
SEGMENTAL VB 2 SOURCES BLOOD SUPPLY



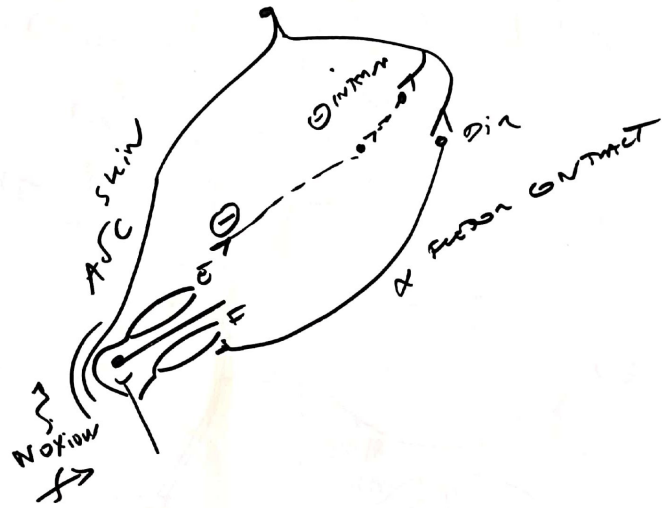
SEMANTERIOR SPINAL  
 T1 G1  
 T1 NOT ENOUGH  
 SG  
 1/3  
 TTS ANASTOMOSIS  
 2/3  
 BASE T14 & UP POSITIONS  
 6-5 T

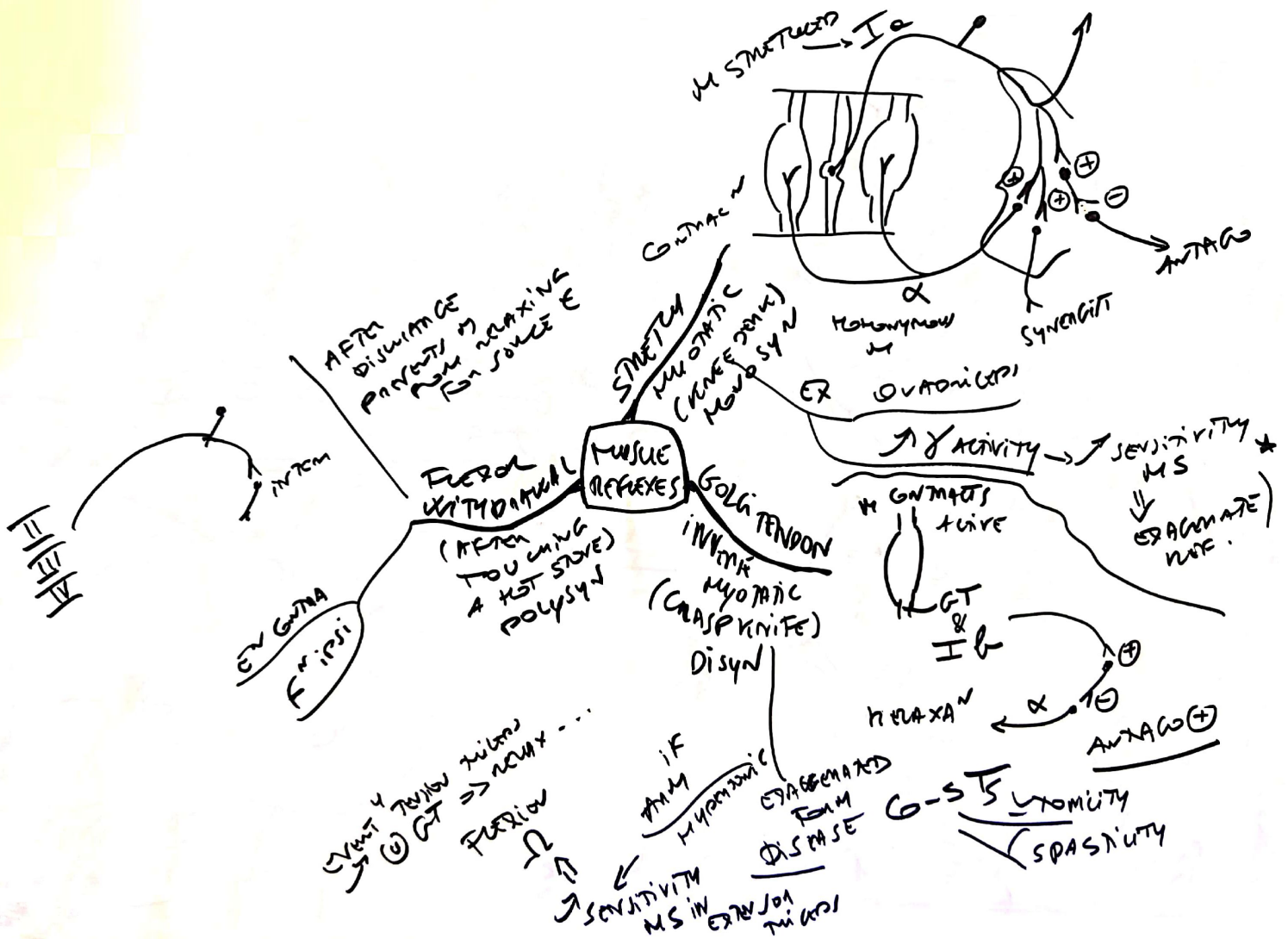




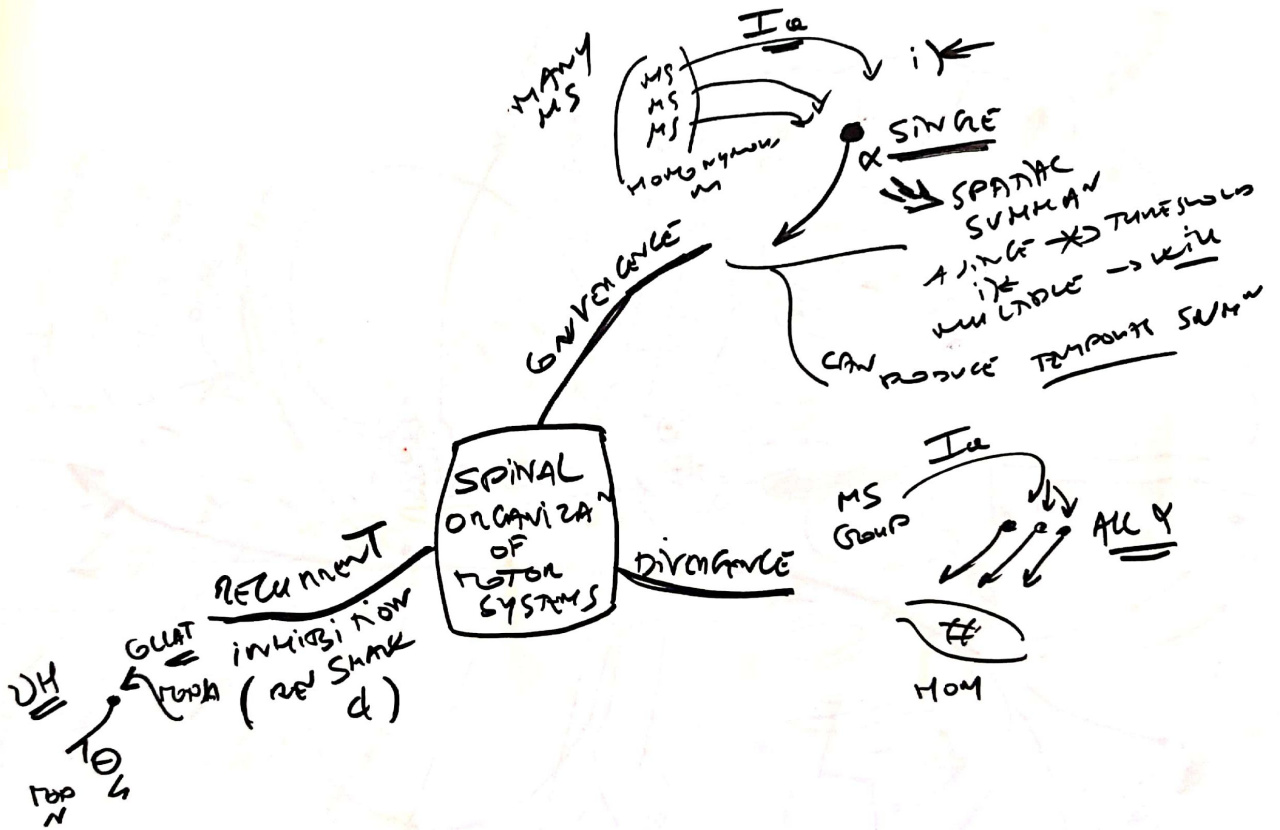


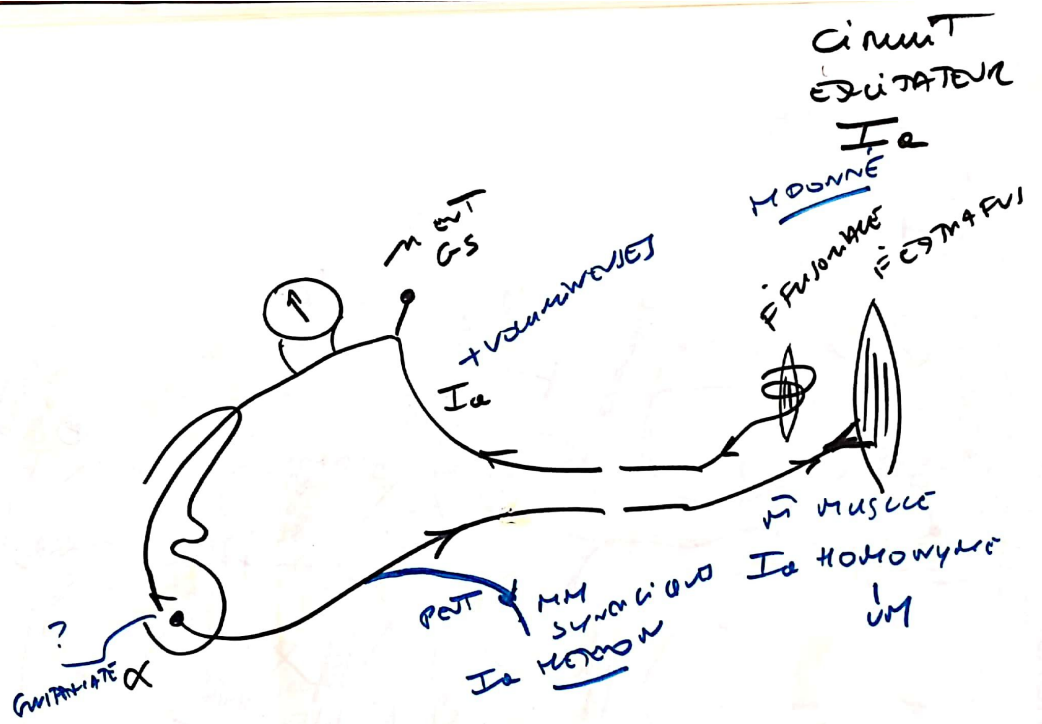
WITHDRAWAL  
REF  
||  
FLEXION  
ANALGIC

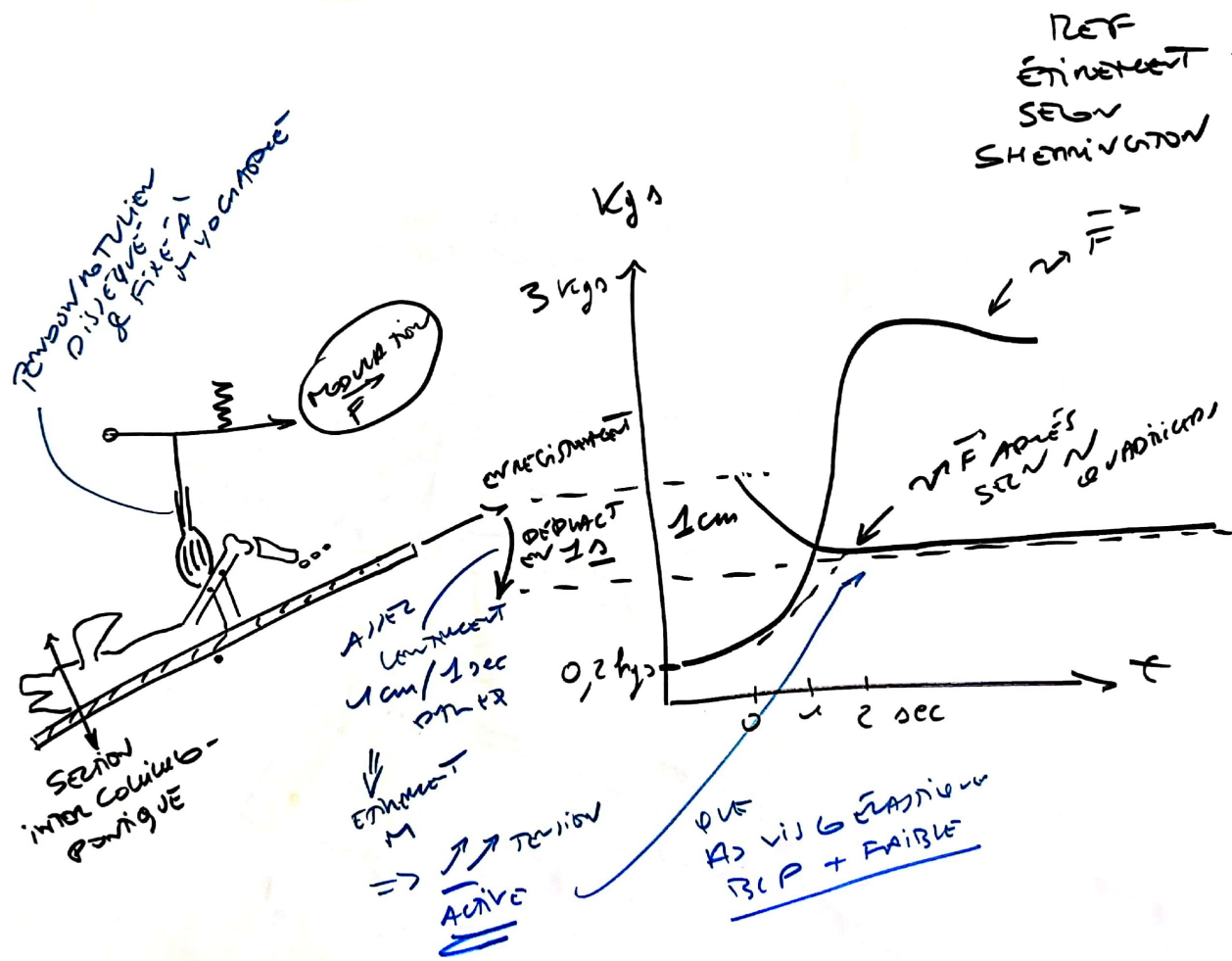


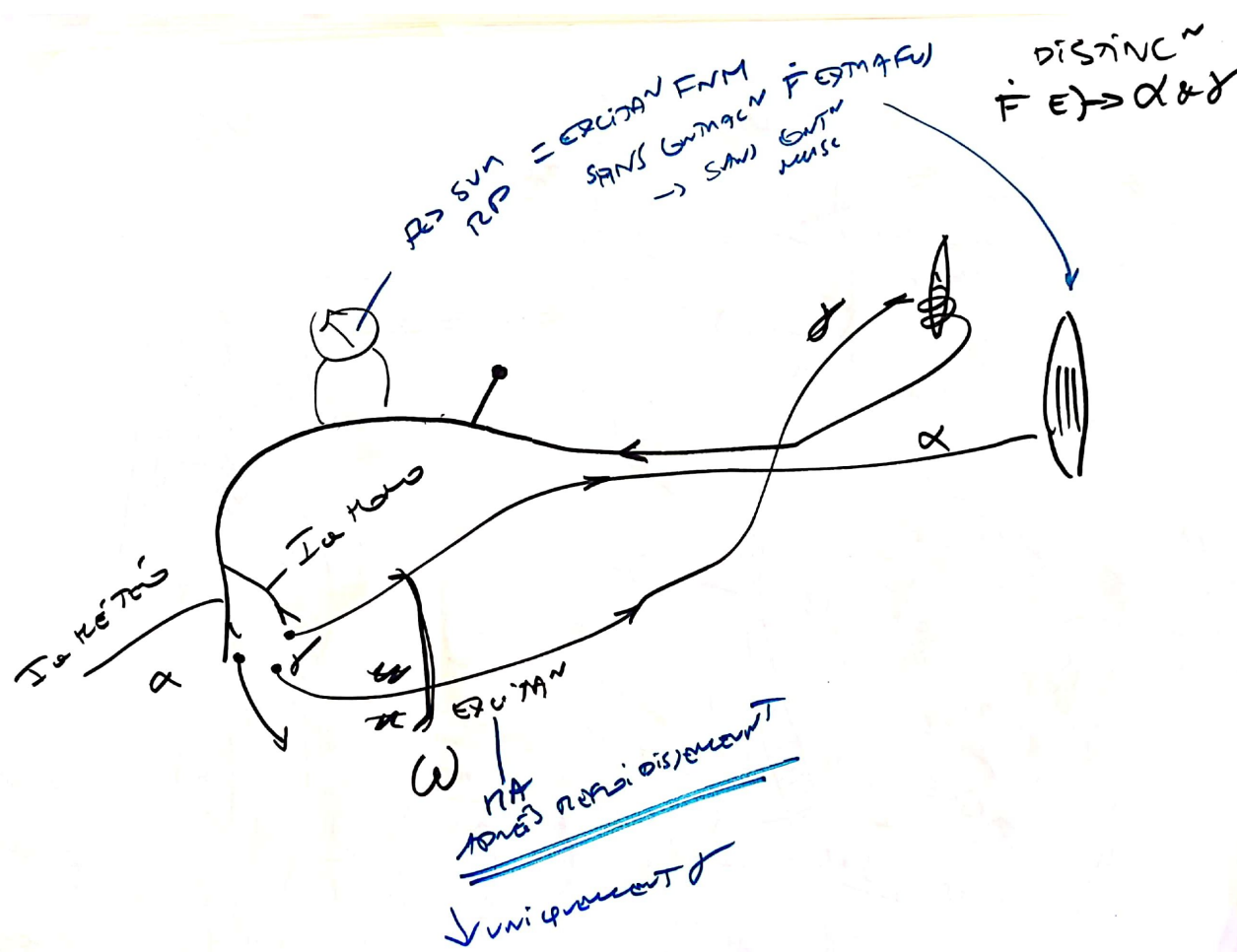




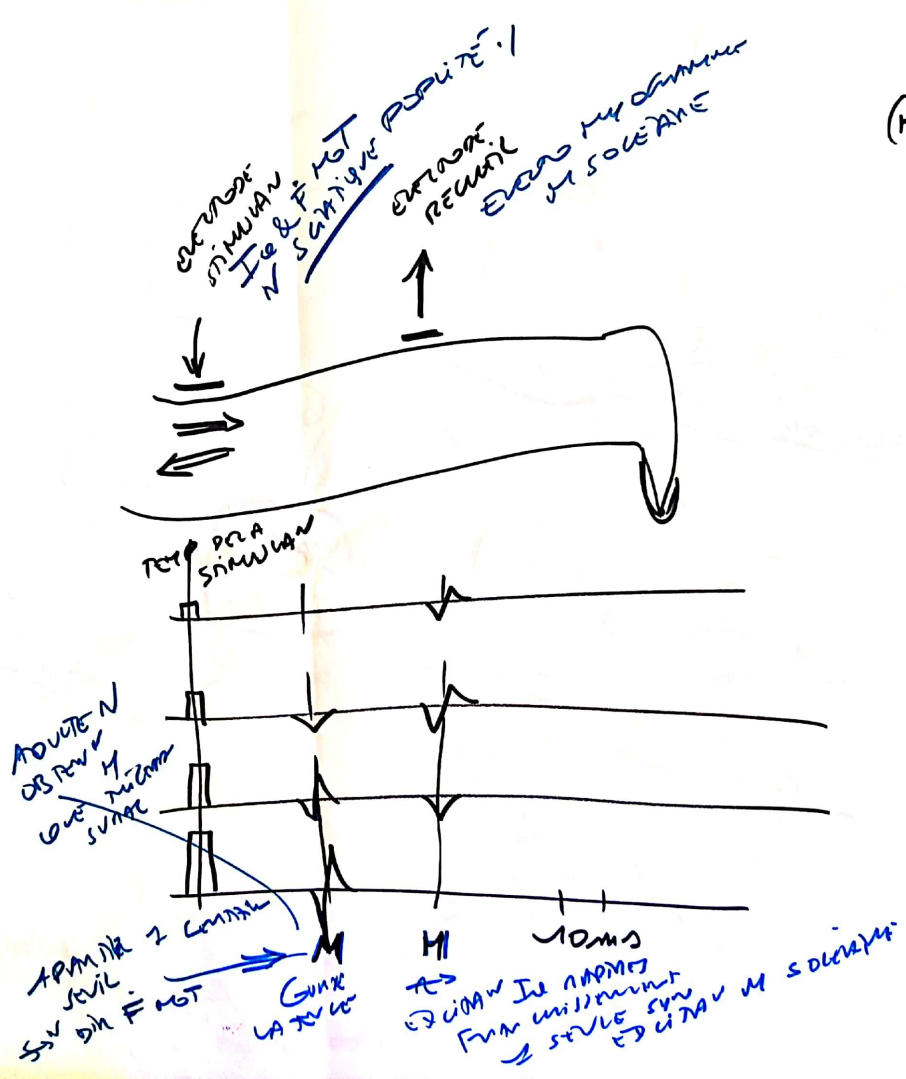








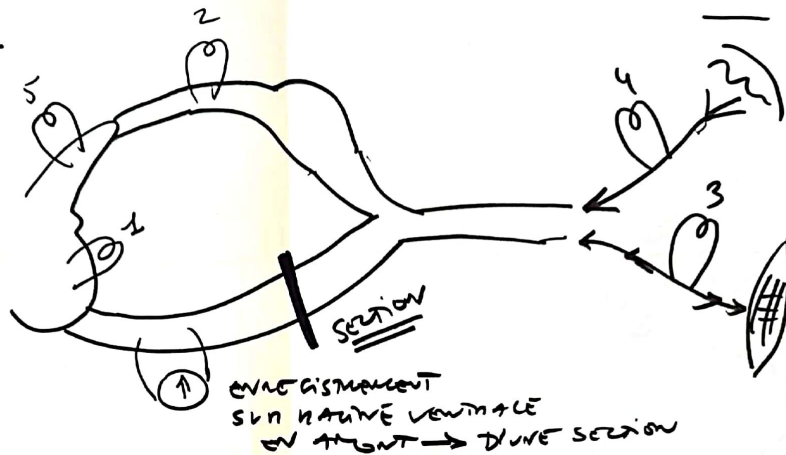
REF  
H  
(HOFFMANN)



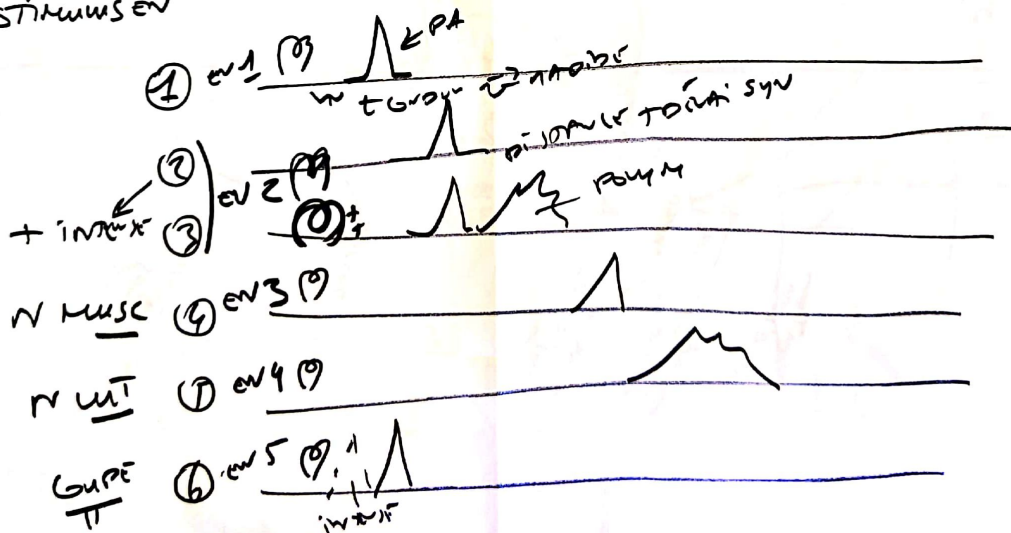


⊙ = EXCITATION  
 ⊕ = INHIBITION

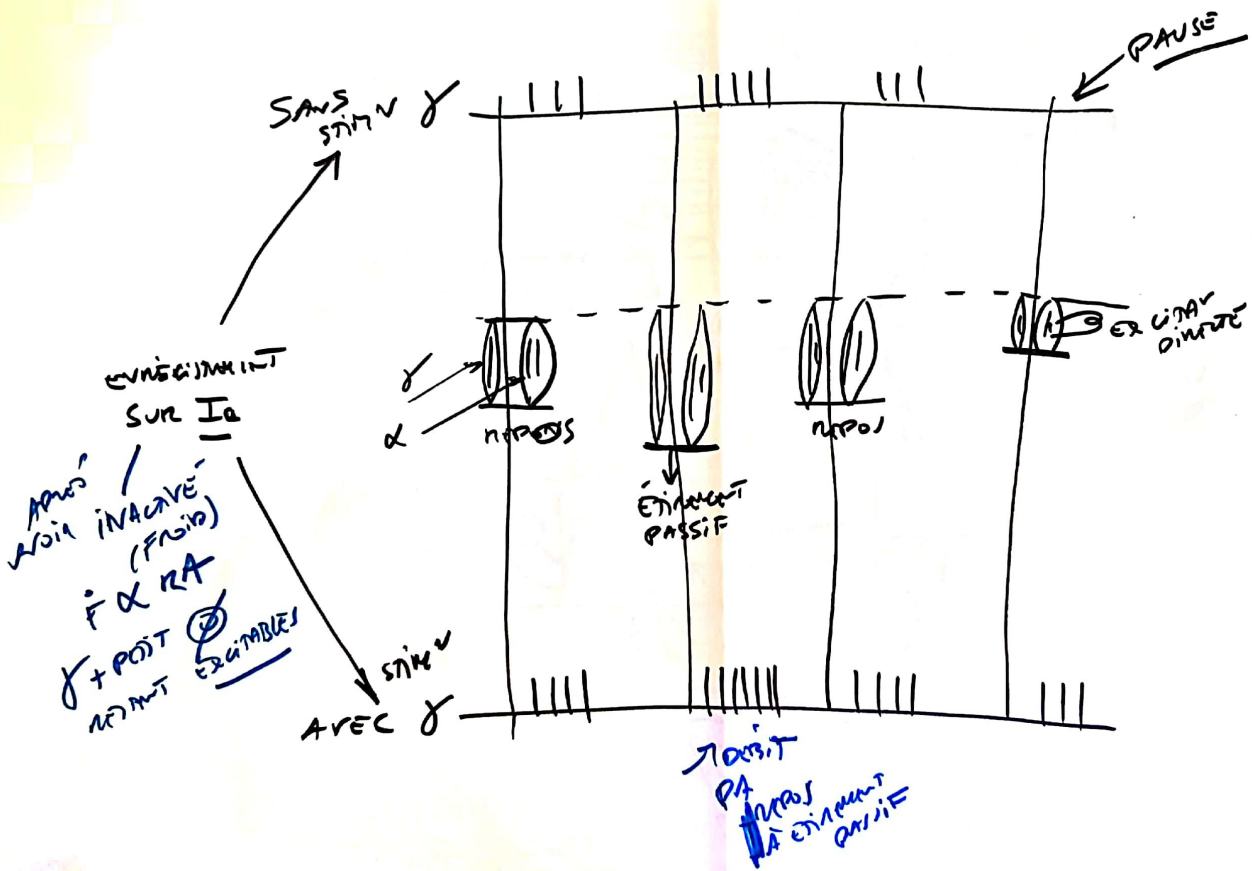
REF MEMO SYN EXT  
 — POT — FLEX



STIMULUS EV



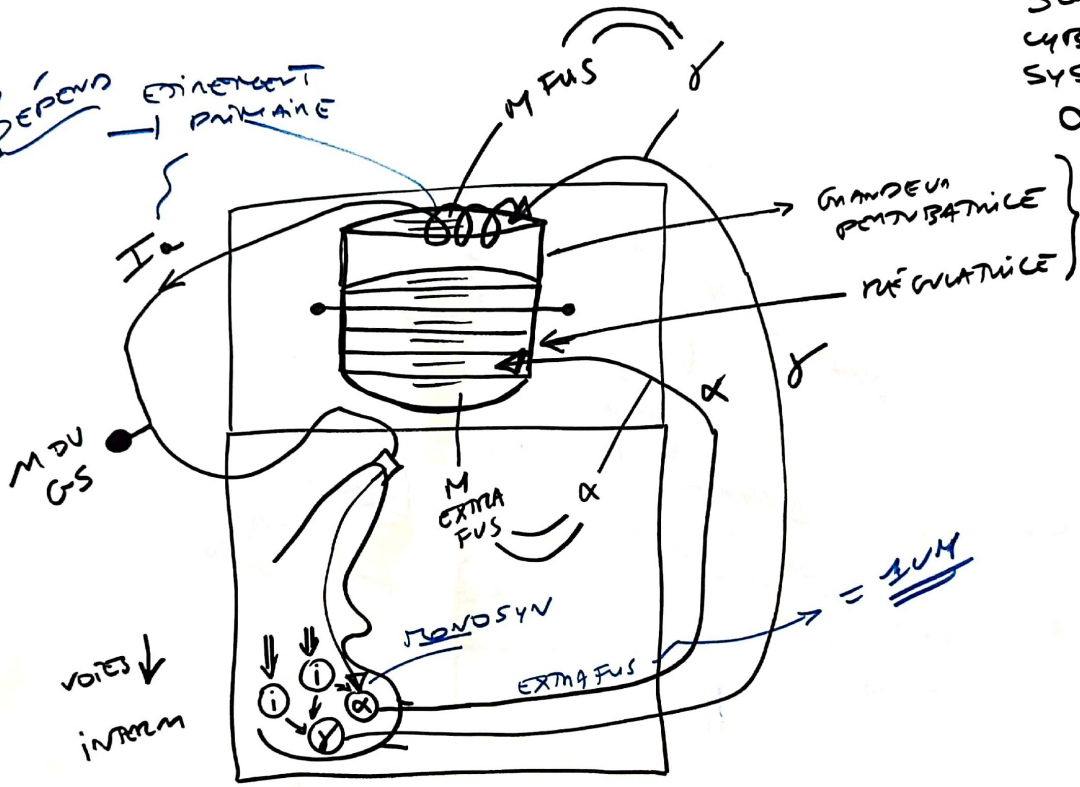
$R \rightarrow$  FUSIONIALE  
 $EN FN \rightarrow$  MUSCLE  
 $\&$  EXCITAV  $\gamma$



SCHEMA CYBERNETIQUE SYSTEME  $\alpha-\delta$

MISE EN ROUTE DEPEND F FUS  $\delta$  MUSCLES

ETIENNETE PRIMAIRE



VOIES INTERNES

= SUM

LANGUE RELATIVE M EXTRA FUS & CORD AFFI LITEJ RM F  $\delta$

GRANDEUR PERTURBATRICE

REGULATRICE

SYNOPTIC

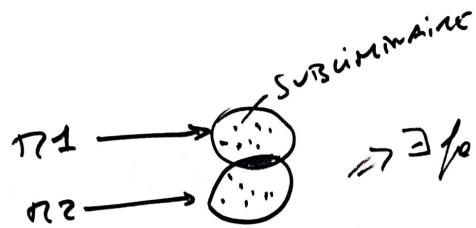
EXTRA FUS

CONTINUITÉ ASSURÉE NIVEAU F FUS RM F  $\delta$

IL N'Y A PAS DE "POUCE" ANNEAU DE CCF

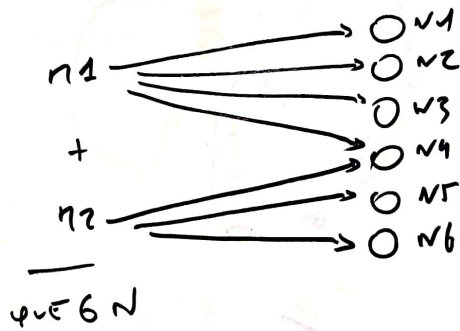
PM

LIMIT EN SPINALE



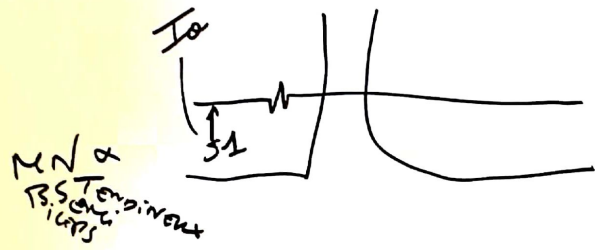
$\Rightarrow \exists$  facilitation spatiale  
 au niveau de la  
 frange sous cumine

SOM N SPATIAL



il y a eu occlusion  
 au niveau de n  
 60% aux 2  
 champs n

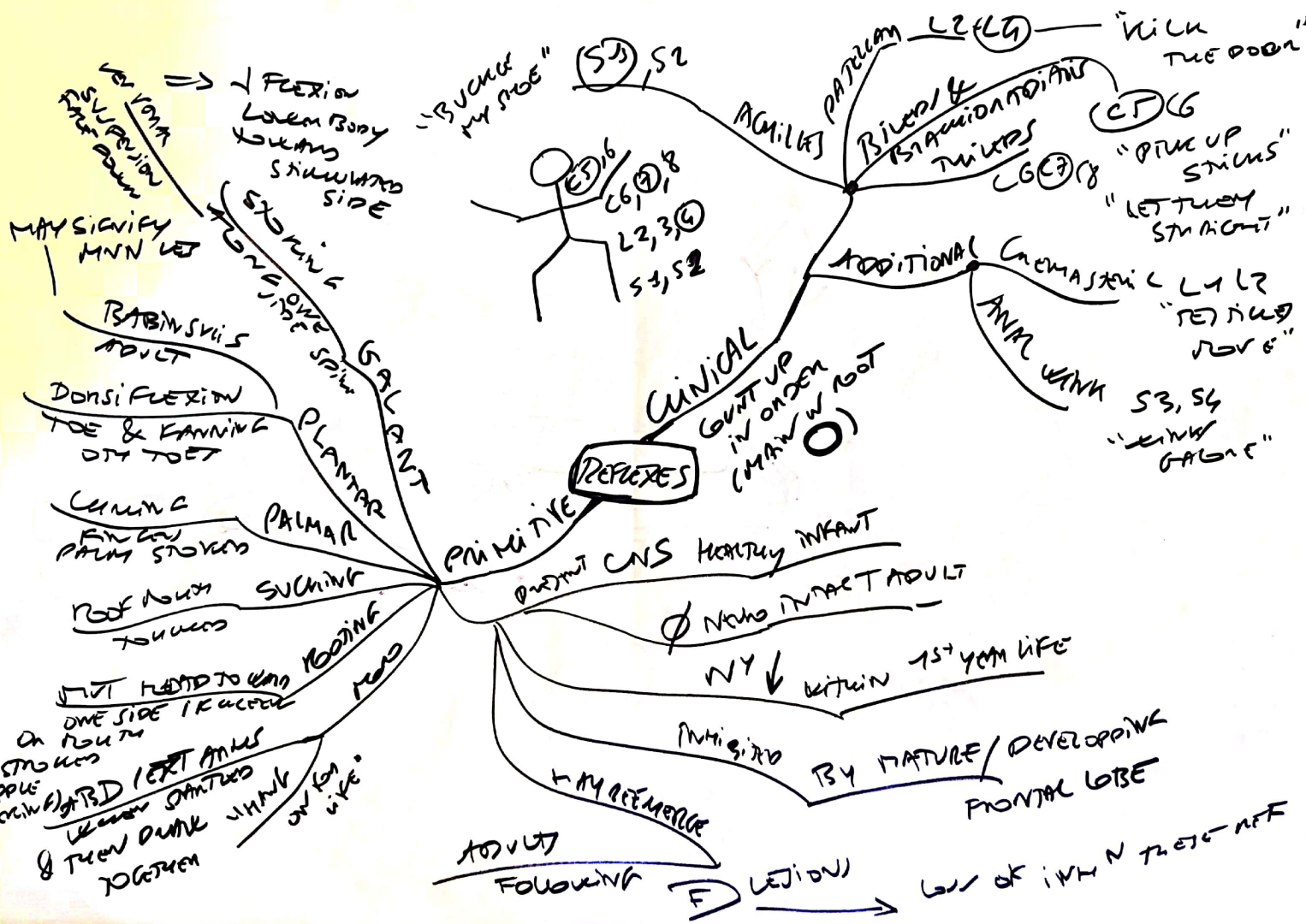
OCCUSION

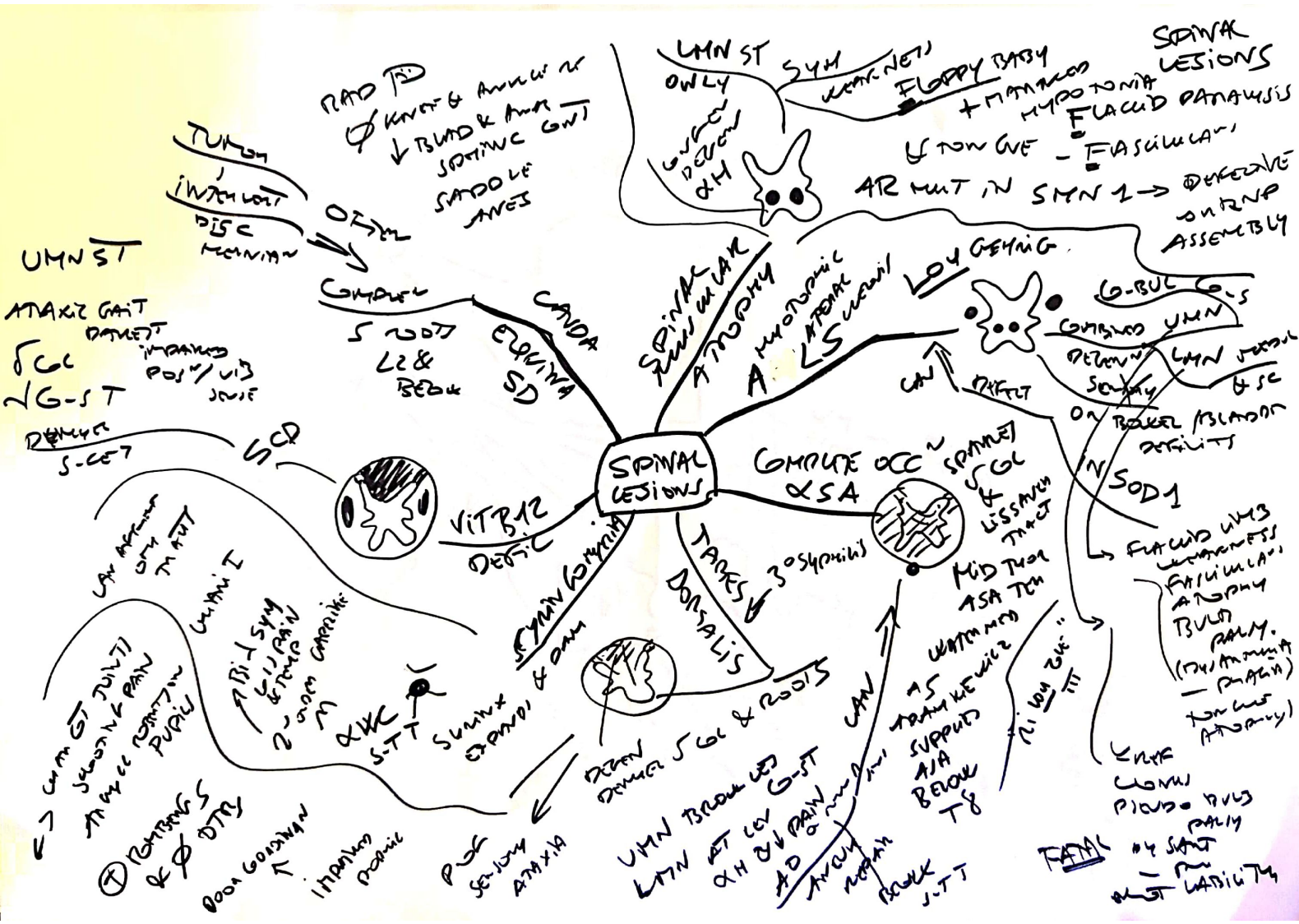


INHIBITION  
POST SYN

INHIBITION  
PRE SYN







POLYMYELITIS

