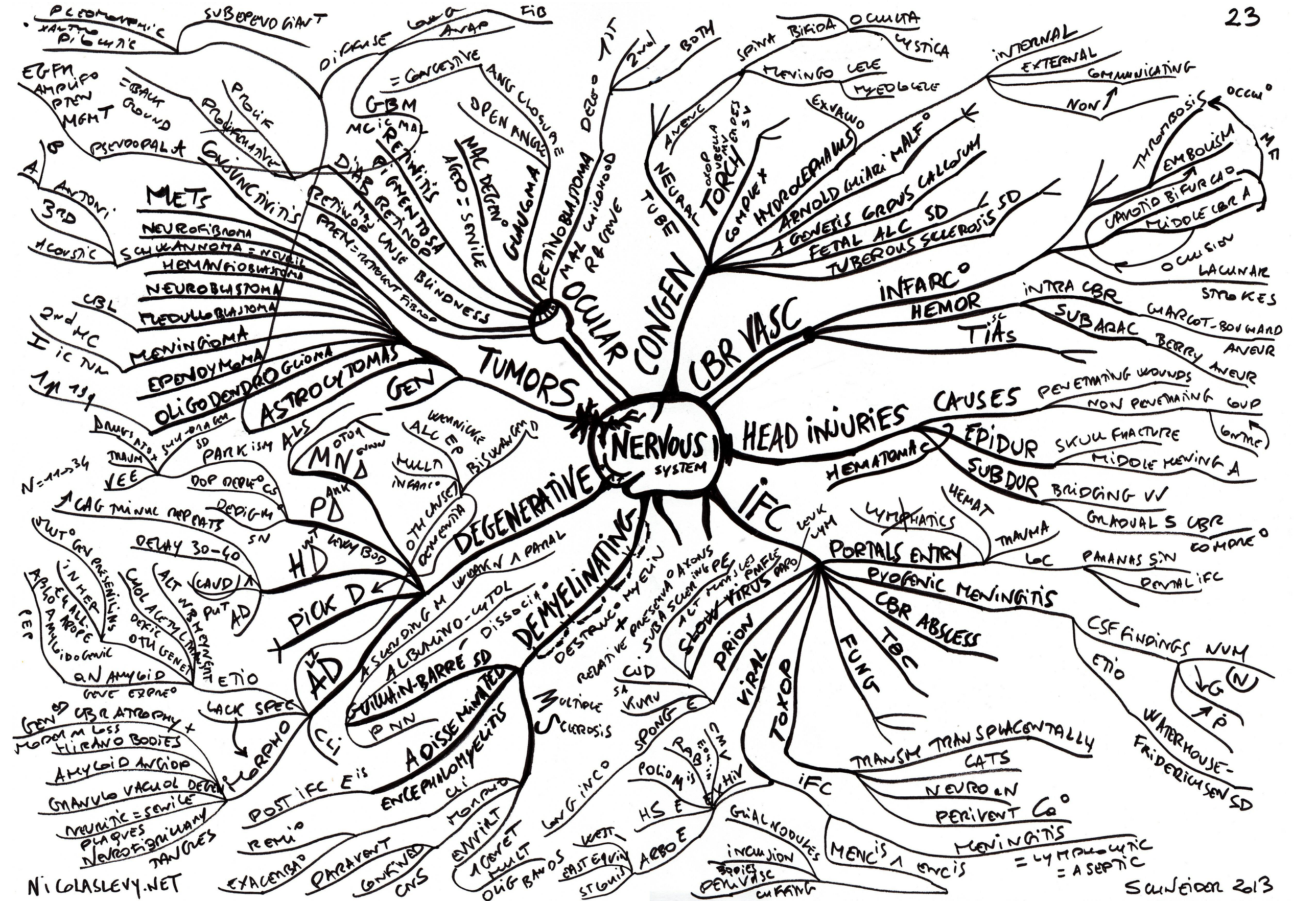
NERVOUS SYSTEM
TUMORS
OCULAR
CONGEN
CBR VASC
HEAD INJURIES
IFC
DEGENERATIVE
DEMYELINATING
GEN
ASTROCYTOMAS
OLIGODENDROGLIOMA
EPENDYMOMA
MENINGIOMA
MEDULLOBLASTOMA
NEUROBLASTOMA
HEMANGIOBLASTOMA
SCHWANNOMA = NEURIL
NEUROFIBROMA
METS
GBM
RETINITIS PIGMENTOSA
RETINOPATHY
CATARACT
GLAUCOMA
RETINOBLASTOMA
NEURAL TUBE
TORCH
HYDROCEPHALUS
ARNOLD CHIARI MALF
AGENESIS CORPUS CALLOSUM
FETAL ALC SD
TUBEROUS SCLEROSIS SD
SPINA BIFIDA OCCULTA
MYELOMENINGOCELE
INTERNAL
EXTERNAL
COMMUNICATING
NON
THROMBOSIS
EMBOLISM
MIDDLE CBR A
LACUNAR STROKES
INFARCT
HEMOR
TIAs
INTRA CBR
SUBARAC
CHARCOT-BOUCHARD ANEUR
BERRY ANEUR
CAUSES
PENETRATING WOUNDS
NON PENETRATING COUP
EPIDUR
SKULL FRACTURE
MIDDLE MENING A
SUBDUR
BRIDGING VV
GRADUAL S CBR COMPRE
HEMATOMAS
PORTALS ENTRY
PYOGENIC MENINGITIS
CBR ABSCESS
TBC
FUNG
PRION
VIRAL
TOXOP
CSF FINDINGS NVM
ETIO
WATERHOUSE-FRIDERICHSEN SD
TRANSPLACENTALLY
CATS
NEUROCN
PERIVENT CO
MENINGITIS = LYMPHOCYTIC = ASEPTIC
MENCIS
ENCIS
GLIAL NODULES
INCLUSION BODIES
PERIVASC CUFFING
ARBO E
HS E
WEST NILE
EAST EQUIN
ST LOUIS
LYMPHOMA
LEUK
HEMAT
TRAUMA
LOC
PARANAS SIN
DENTAL IFC
MULTIPLE SCLEROSIS
ADISSEMINATED ENCEPHALOMYELITIS
GUILLAIN-BARRÉ SD
ALBUMINO-CYTOL DISSOCIA
ASCENDING M WEAKN
DESTRUC MYELIN
RELATIVE PRESERVA AXONS
SUBACUTE
ALT MASSES
SLOW VIRUS
CJD
SPONGE
RABIES
POLIOMYE
HIV
MORPHO
LACK SPEC
ETIO
AD
PICK D
HD
PD
MND
ALS
PARKINSON
DEMENTIA
DEPRESS
DELIRIUM
DEPRIV
DEMYELIN
ALT NEUROTRANSM
DEFIC OTH GENET
CHOL ACETYLTRANSF
ALT NEUROTRANSM
DEFIC
OTH GENET
ETIO
GENE EXPRES
AN AMYLOID
AMYLOIDOGENIC
PEP
ALL ROPE
INHER
DEMENTIA
DELAY 30-40
CAG TRINUC REPEATS
MUTO GEN PRESENILINS
CAUD
PUT
AD
GEN SD CBR ATROPHY
NEURON LOSS
LEWY BODIES
AMYLOID ANGIOP
GRANULOVACUOL DEGEN
NEURITIC = SENILE PLAQUES
NEUROFIBRILLARY TANGLES
POST IFC E is
REMIO
EXACERBAD
PARAVENT
GRAN'NED
CNS
ENVIRT
CONVET
MULT
OLIGBANDS
MONPHO
CLI
LONG INCO
MULTI INFARCT
OTH CAUSES
DEMENTIA
WERNICKE
ALC EP
BISWANGER
SYMPTOMATIC
SD
DRUGS ATD
TRAUM
VEE
DOP DEPRESS CS
PARKISM
DEDIGM
SN
N=11->34
ICP
AM 199
ICTUS
2nd MC
CBL
ACOUSTIC
3RD
ANTONI
A
B
PSEUDOPALA
EGFR
AMPLIFICATION
PTEN
MGMT
=BACK GROUND
PROGNOSTIC
PROGRESSIVE
GANGLIONCYTOMA
DIFF RETINOP
MAL DEGEN
AGED = SENILE
OPEN ANGLE
ANG CLOSURE
=CONGESTIVE
DIFFUSE
ANAP
FIB
PLEOMORPHIC
XANTHO ASTROCYTOMA
SUBEPENDYMOGIANT
DECUS
1ST
2nd
BOTH
ANEURY
EXVACUO
MAL UNIONWOOD
RAGONE
PNEM=NEONATAL FIBROP
BLINDNESS
NON
INTERNAL
EXTERNAL
COMMUNICATING
OCCLU
MT
OCCLUSION
MIDDLE CBR A
CAROTID BIFURCATION
THROMBOSIS
EMBOLISM
MT
NICOLASLEVY.NET
SCHNEIDER 2013

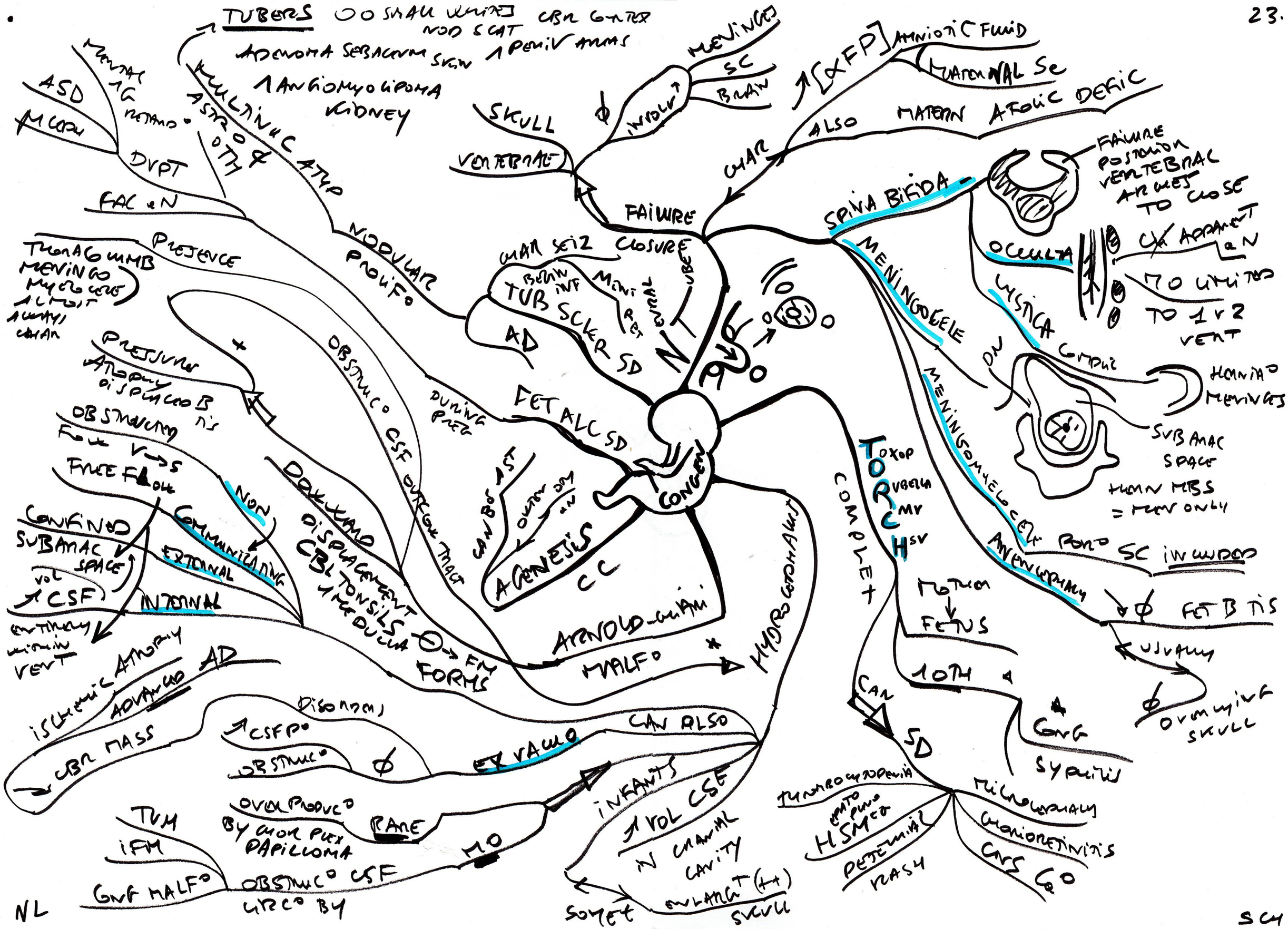
TUBERS
ADENOMA SEBACEUM
ANGIOMYOLIPOMA KIDNEY
ASD
MCDM
DVPT
FAC & N
MULTINUC ATYP
ASTRO & OTH
NODULAR PROLIFO
PRESENCE
THORACOLUMB MENINGO MYELOCELE ALMOST ALWAYS CHIAR
PRESSURE ATROPHY DISPLACED B NS
OBSTRUCTION FOR V→S
FREE FLOW
CONFINED SUBARAC SPACE
CSF
ENTIRELY WITHIN VENT
NON COMMUNICATING
EXTERNAL
INTERNAL
OBSTRUCTION CSF OUTFLOW
DURING PREG
DAWSONS
DISPLACEMENT CBL TONSILS INTO DURA → FM FORMS
ISCHEMIC ATROPHY
ADVANCED AD
CBL MASS
TUM
IFM
GNG MALFO
OBSTRUCTION CSF
CIRCO BY
OVERPRODUCTION BY CHOR PLEX PAPILLOMA
RARE
NO
CSFP
OBSTRUCTION
DISORDERS
EX VACUO
CAN ALSO
INFANTS
↑ VOL CSF IN CRANIAL CAVITY
ENLARGT (++) SKULL
SOMET
HYDROCEPHALUS
ARNOLD-CHIARI MALFO
AGENESIS CC
CAN BE AS OVERLOW IN
CONGEN
NORMAL VENTRICLE
INVOLVT
MENINGES
SC
BRAIN
SKULL
VERTEBRATE
FAILURE
CHIAR SEIZ CLOSURE
BRAIN INF
MENINGOCELE
TUB SCLER SD
AD
FETAL ALC SD
NL
TORCH
TOXOP
RUBELLA
MV
HSV
COMPLET
CAN
SD
MOTHER → FETUS
10TH
GNG
SYPHILIS
TUMOROLYMPHOPENIA
HSMCO
PETECHIAL RASH
MICROPHTHALMIA
CHORIORETINITIS
CNS CO
SCH
CHIAR
ALSO
MATERN ATOMIC DEFIC
AMNIOTIC FLUID
MATERNAL SE
[AFP]
SPINA BIFIDA
OCCULTA
MENINGOCELE
MYELOMENINGOCELE
LIPOMA
CAUDAL
FAILURE POSTERIOR VERTEBRAL ARCHES TO CLOSE
CX APPARENT ON
NO LIMITS TO 1 V 2 VENT
HERNIATED MENINGES
SUBARAC SPACE
THIN MBS = FEW ONLY
ANEURYSMALLY
PONS
SC INVOLVED
FETB TIS
USUALLY
OVERLYING SKULL

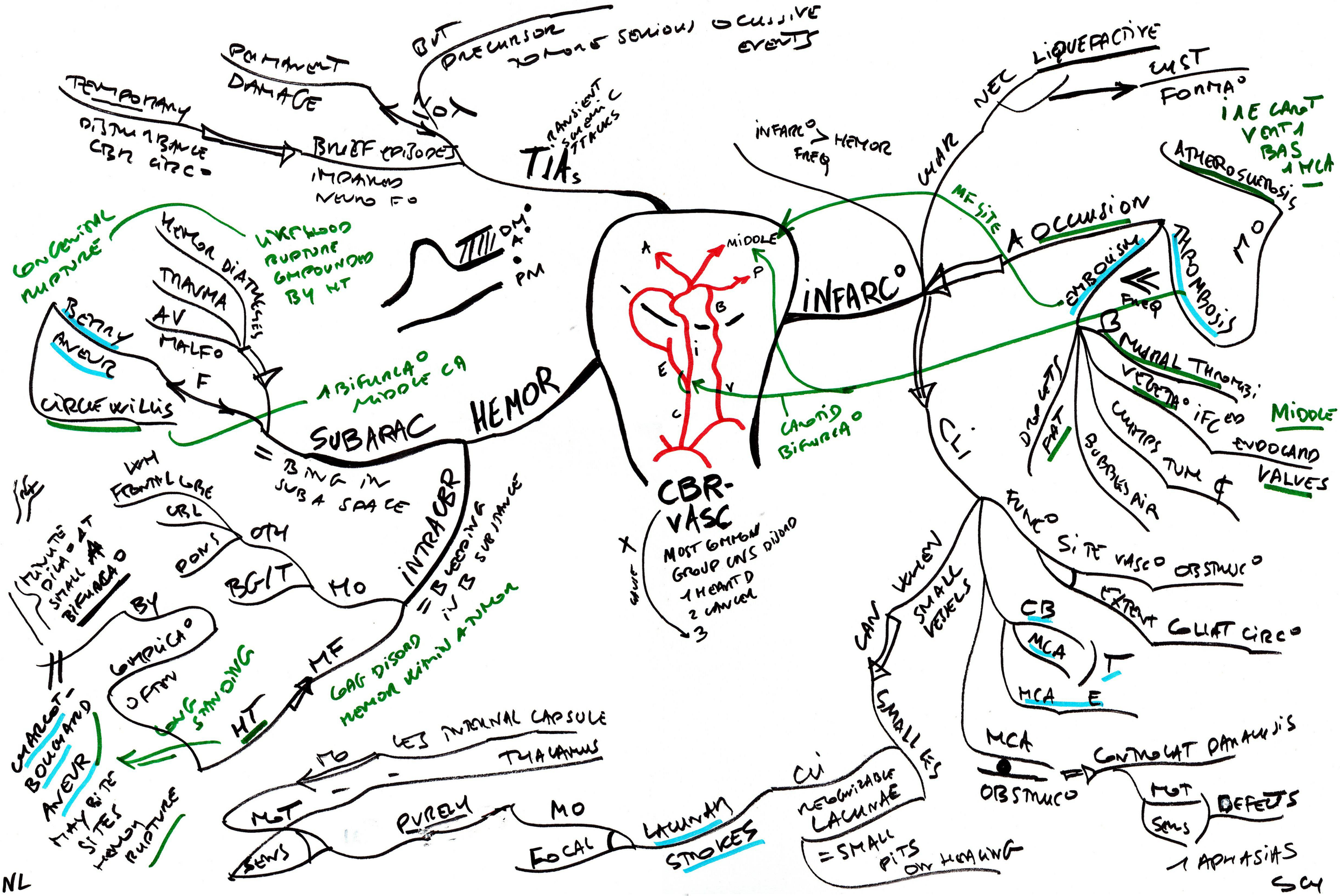

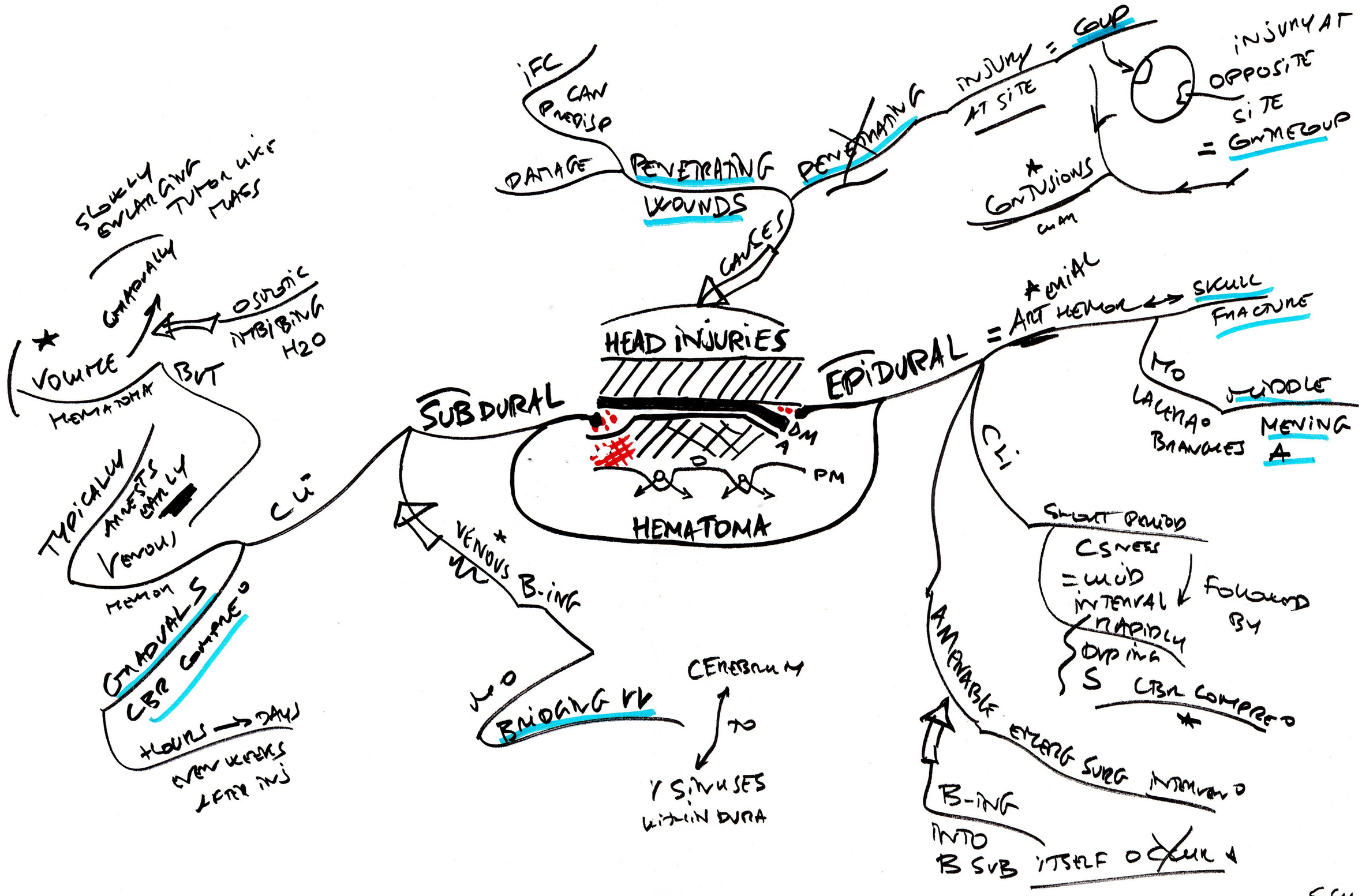
HEAD INJURIES
SUBDURAL
EPIDURAL
HEMATOMA
DM
A
PM
CAUSES
PENETRATING WOUNDS
DAMAGE
IFC
CAN PREDISP
PENETRATING
INJURY AT SITE = COUP
INJURY AT OPPOSITE SITE = CONTRECOUP
CONTUSIONS
CAN
EMIAL
ART HEMOR
SKULL FRACTURE
MO
LACERAO BRANCHES
MIDDLE MENING A
CLI
SILENT PERIOD
CS NERS = MOD INTERVAL
RAPIDLY DVPING S
FOLLOWED BY
CBR COMPRES
ANNEURISM
EMERG SURG INTERVEN
B-ING INTO B SUB ITSELF OCCURS
VENOUS B-ING
MO
BRIDGING VV
CEREBRUM
TO
V SINUSES WITHIN DURA
CLI
TYPICALLY AMNESTS EARLY
VENOUS
HEMOM
GRADUALLY CBR COMPRES
HOURS → DAYS
EVEN WEEKS LATER INJ
VOLUME BUT
HEMATOMA
GRADUALLY
OSMOTIC IMBIBING H2O
SLOWLY ENLARGING TUMOR LIKE MASS

NL

SCH

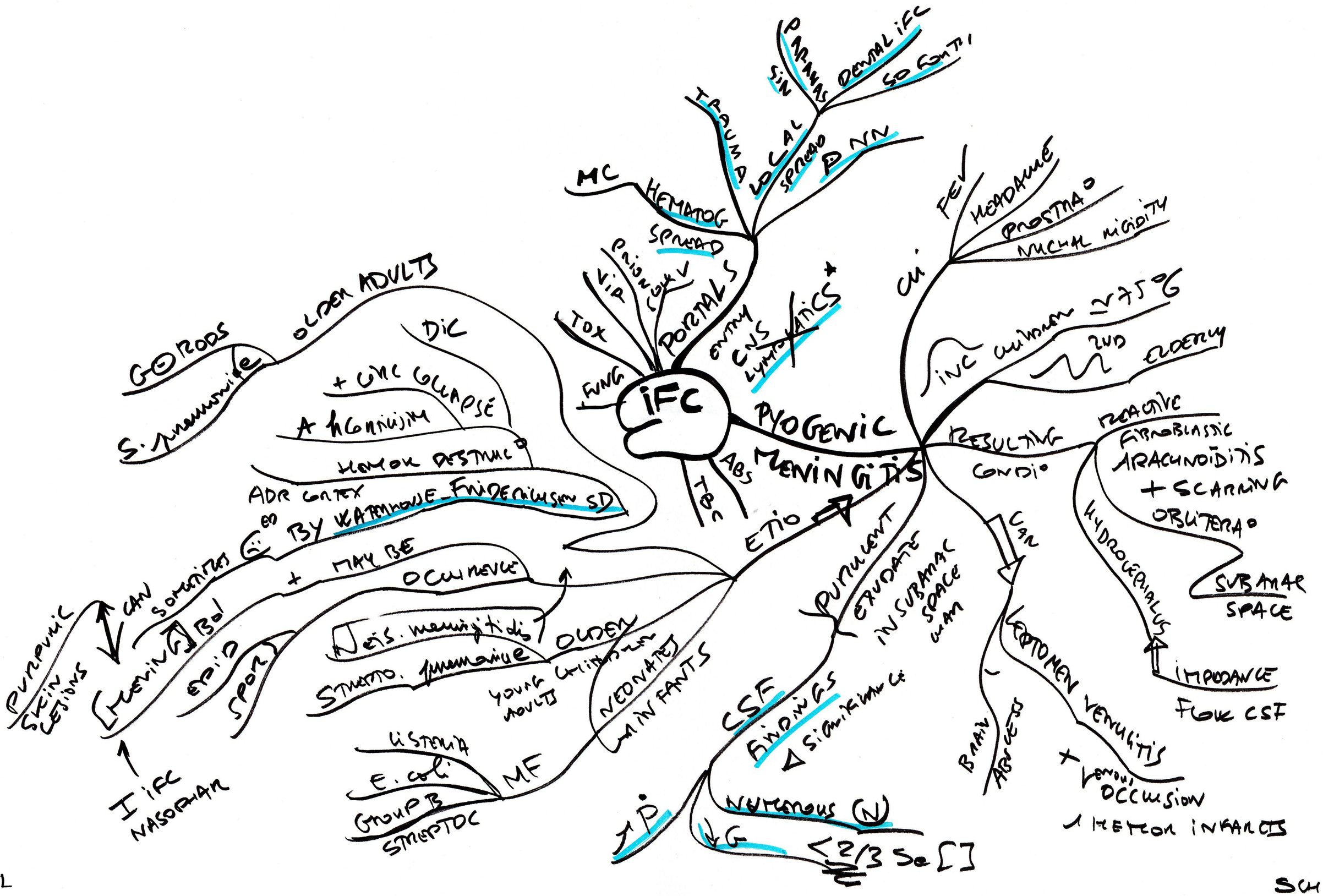
iFC
PYOGENIC MENINGITIS
ETIO
TRAUMA
SIN
PARANAS
DENTAL iFC
SO CONTI
LOCAL SPREAD
PNN
MC
HEMATOG
SPREAD
PRIONS
VIR
TOX
FUNG
PORTALS
ENTRY
CNS LYMPHATICS
CNS
FEV
HEADACHE
PROSTRATION
NUCHAL RIGIDITY
iNC CONSCIOUSNESS ≈75%
ZUD
ELDERLY
RESULTING CONDI
REACTIVE FIBROBLASTIC ARACHNOIDITIS + SCARRING OBLITERATION
HYDROCEPHALUS
IMPEDANCE FLOW CSF
SUBARAR SPACE
CAN
EPTOMEN VENULITIS
+ VENOUS OCCLUSION
BRAIN ABSCESS
1 METEOR INFARCTS
PURULENT EXUDATE IN SUBARAC SPACE WAM
CSF FINDINGS
SIGNIFICANCE
NEUTROPHILS (N)
<2/3 Sa []
↑P
↓G
ABS
TBC
OLDER ADULTS
GONADS
S. pneumoniae
DIC
+ CNC COLLAPSE
A HOMOGENEOUS
HEMOR DESTRUCTION
ADR CORTEX
BY WATERHOUSE-FRIDERICHSEN SD
SOMETIMES
MAY BE
OCCURRENCE
N. meningitidis
STRETTO. pneumoniae
OLDER
YOUNG ADULTS
NEONATES
INFANTS
PURPURIC SKIN LESIONS
CAN
MENING
EPID
SPORD
iFC NASOPHAR
LISTERIA
E. coli
GROUP B STREPTOC
MF

NL

SCH

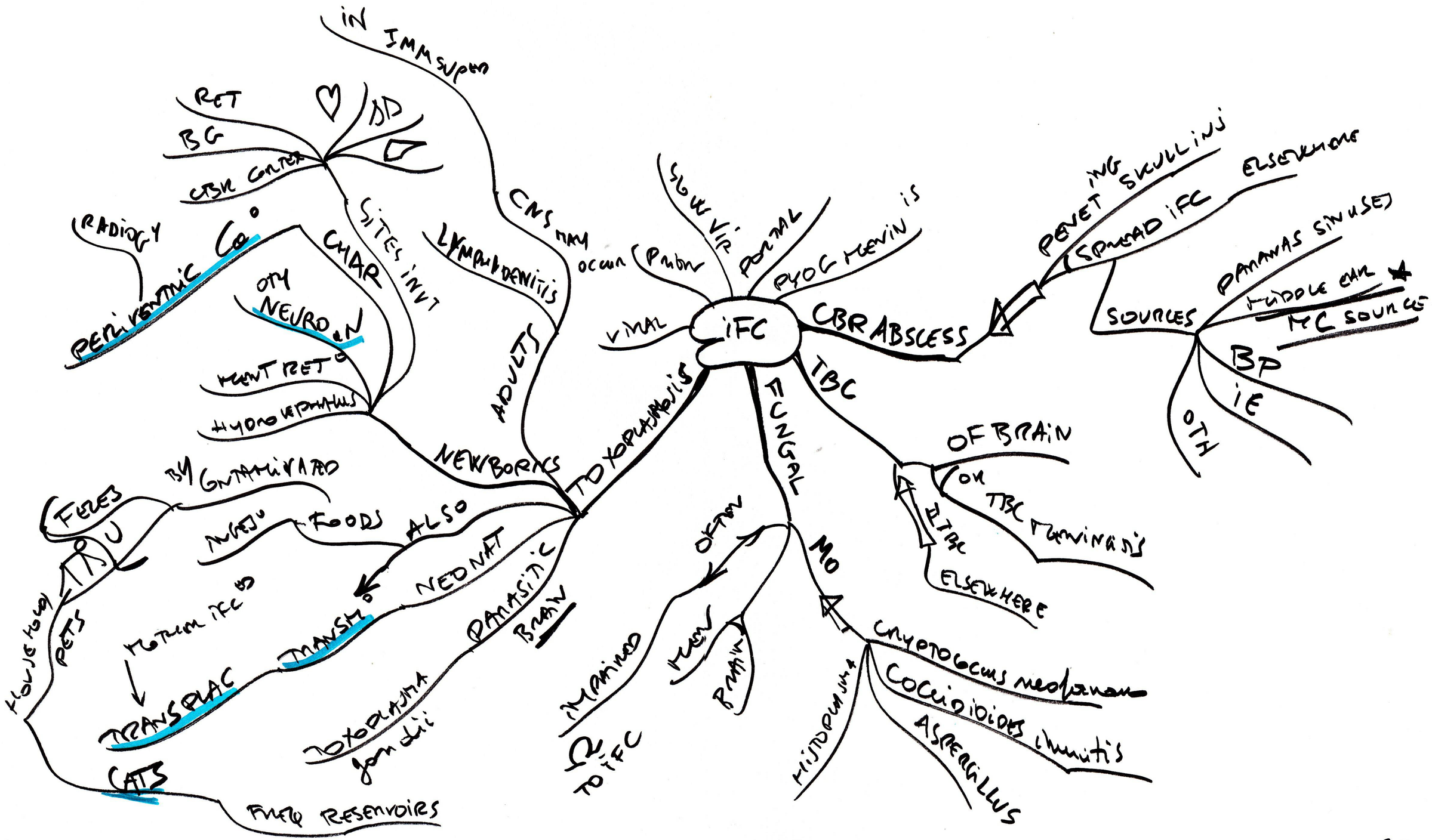
iN IMMSUPPR
RET
BG
CSF CULTURE
SITES INVT
CHAR
RADIOGY
PERIVENTRIC
OTH NEURO
HEMIT RET
HYDROCEPHALUS
LYMPHADENITIS
CNS MAY occur
ADULTS
NEWBORNS
TOXOPLASMOSIS
BY GUTTAMIRAED
FERES
INGEST
FOODS
ALSO
HOUSEHOLD PETS
TRANSPLAC
TRANSM
NEONAT
PARASITIC BRAIN
TOXOPLASMA gondii
CATS
FELID RESERVOIRS
SLOW VIR
PORTAL
PYOG MENIN is
PROBN
VIRAL
iFC
CBR ABSCESS
PENET ING SKULL INJ
SPREAD iFC
ELSEWHERE
SOURCES
PARANAS SINUSES
MIDDLE EAR
MC SOURCE
BP
iE
OTH
TBC
OF BRAIN
OR TBC MENINGIS
ELSEWHERE
TUNGAL
OFTEN
MO
IMPAIRED
TO iFC
MENIN
BRAIN
CRYPTOCOCCUS neoformans
COCCIDIOIDES immitis
ASPERGILLUS
HISTOPLASMA

NL

SCM

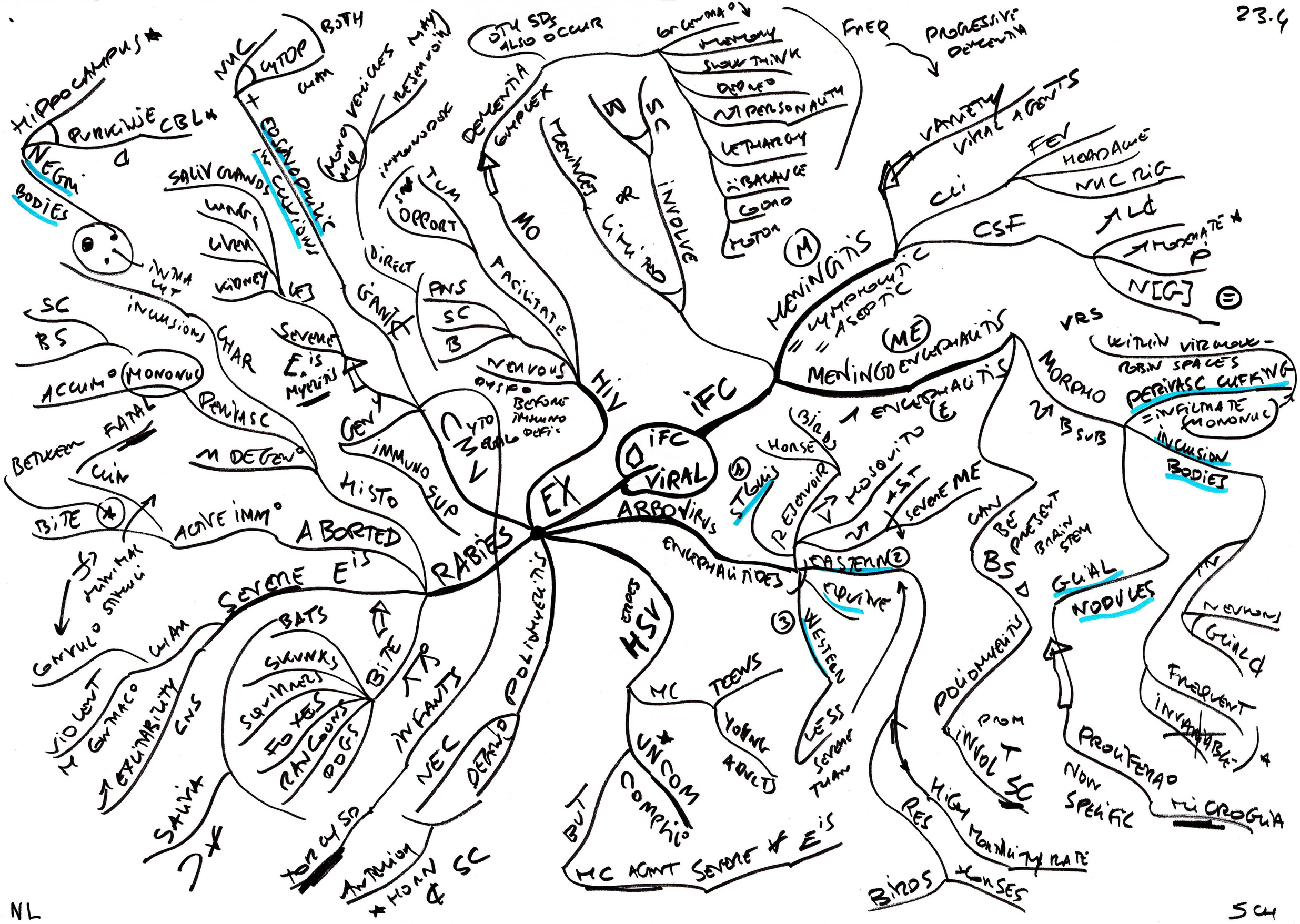
HIV
EX
RABIES
iFC
iFC
VIRAL
ARBOVIRUS
ENCEPHALITIDES
EASTERN
WESTERN
EQUINE
HSV
MENINGITIS
MENINGOENCEPHALITIS
ENCEPHALITIS
PERIVASC CUFFING
INFILTRATE (MONONUC)
INCLUSION BODIES
GLIAL NODULES
POLIOMYELITIS
PROLIFERAD
MICROGLIA
FREQUENT
INVARIABLE
NEUROND
GRANULA
MORPHO
BSUB
VRS
KEITLIN VIRCHOW-ROBIN SPACES
CSF
CLI
VARIETY VIRAL AGENTS
FEV
HEADACHE
NUC RIG
ALT
MODERATE
N[G]
DEMENTIA
COMPLEX
MO
FACILITATE
MENINGES
OR LIMBIC
INVOLVE
SC
B
DTH SDS ALSO OCCUR
DEMENTIA
MEMORY
SLOW THINK
DEPRES
PERSONALITY
LETHARGY
IMBALANCE
GOND
MOTOR
FREQ
PROGRESSIVE DEMENTIA
HIPPOCAMPUS
PURKINJE
CBL
NEGRI BODIES
SALIV GLANDS
LUNGS
LIVER
KIDNEY
LEG
INTRA CYT INCLUSIONS
SC
BS
ACCUM
MONONUC
CHAR
PERIVASC
FATAL
BETWEEN
CLIN
M DEGEN
BITE
ACTIVE IMM
ABORTED
SEVERE E is
GANGL
DIRECT
PNS
SC
B
OPPORT
IMMUNOSUP
NUC
CYTOP
BOTH
CHAR
EOSINOPHILIC CUCUIONS
MONO VESICLES
RESERVOIR
MONO MYE
IMMUNOSUP
CYTO MEGALO
CMV
GEN
IMMUNO SUP
HISTO
SEVERE E is MYELITIS
NERVOUS DYSF
BEFORE IMMUNO DEFIC
GRANULO SINUSI
SEVERE
CHAR
BATS
SKUNKS
SQUIRRELS
FOXES
RACCOONS
DOGS
BITE
INFANTS
NEC
DEFAND
POLIOMYELITIS
SALIVA
TOR CYSD
ANTRUM
HORN
SC
VIOLENT
GRMACO
EXTINARILITY
CNS
GRMULO SINUSI
CHAR
HORSE
BIRDS
RESERVOIR
MOSQUITO
AST
SEVERE ME
STLOUIS
CAN BE PRESENT BRAIN STEM
BS
GRIOS
HSV
MC
TEENS
YOUNG ADULTS
UNCOM
COMPLIC
BUT
MC ACMT SEVERE E is
WESTERN
LESS SEVERE THAN
EQUINE
POLIOMYELITIS
FROM INVOL SC
HIGH MORBIDITY RATE
RES
BIRDS
HORSES
NOW SPECIFIC
NL
SCH

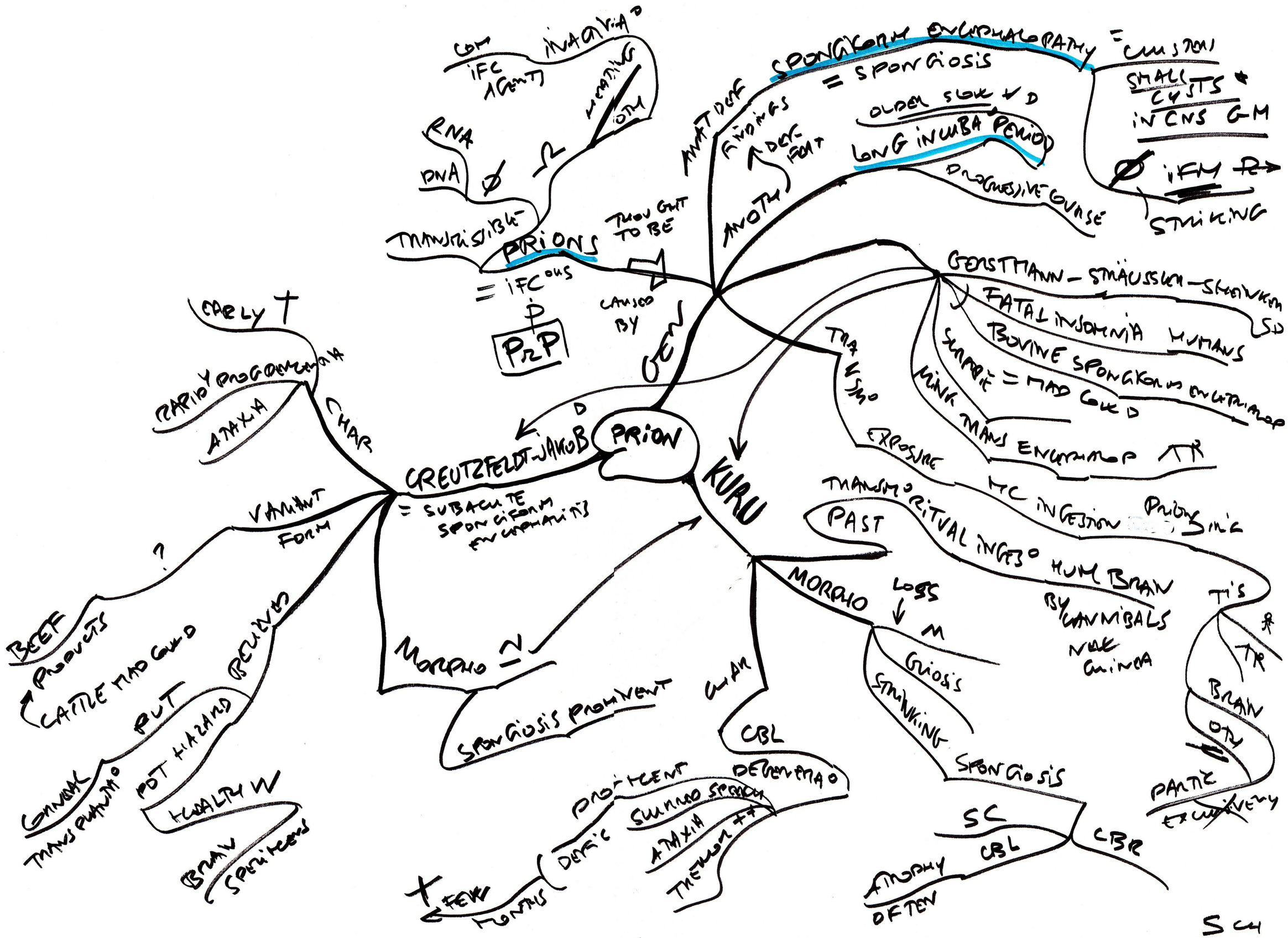
PRION
CREUTZFELDT-JAKOB
= SUBACUTE SPONGIFORM ENCEPHALITIS
CHAR
EARLY +
RAPID PROGRESSIVE DEMENTIA
ATAXIA
VARIANT FORM
?
BEEF PRODUCTS
CATTLE MAD COWS
BUT
BELIEVED
GENERAL TRANSMISSIBILITY
POT HAZARD
HEALTH W
BRAIN SPECIMENS
MORPHO ~
SPONGIOSIS PROMINENT
+ FEW MONTHS
DEFIC
PROMINENT
SLURRED SPEECH
ATAXIA
TREMOR ++
CBL
DEMENTIA
GUAN
KURU
PAST
TRANSMORTIVAL INGES
HUM BRAIN
BY CANNIBALS
NEW GUINEA
MORPHO
LOSS
M
GLIOSIS
SHRINKING
SPONGIOSIS
SC
CBL
CBR
ATROPHY
OFTEN
TRANSMISSIBLE
PRIONS
= IFC OUS
PrP
THOUGHT TO BE
CAUSED BY
GENE
RNA
DNA
INVADING
MEANING
OTHER
ANATOMIC FINDINGS
DEGENERATE
ANOTH
SPONGIFORM ENCEPHALOPATHY
= SPONGIOSIS
OLDER SLOW V D
LONG INCUBATION PERIOD
PROGRESSIVE COURSE
= CLUSTERS
SMALL CYSTS
IN CNS GM
IFM
STRIKING
GERSTMANN-STRÄUSSLER-SCHEINKER SD
FATAL INSOMNIA HUMANS
BOVINE SPONGIFORM ENCEPHALOPATHY
SCRAPIE = MAD COWS
MINK TRANS ENCEPHALOP
EXPOSURE
HC INGESTION
PRIONS IN
TI'S
TR
BRAIN
OTHER
PARTIE
EXCLUSIVELY
NL
SCH

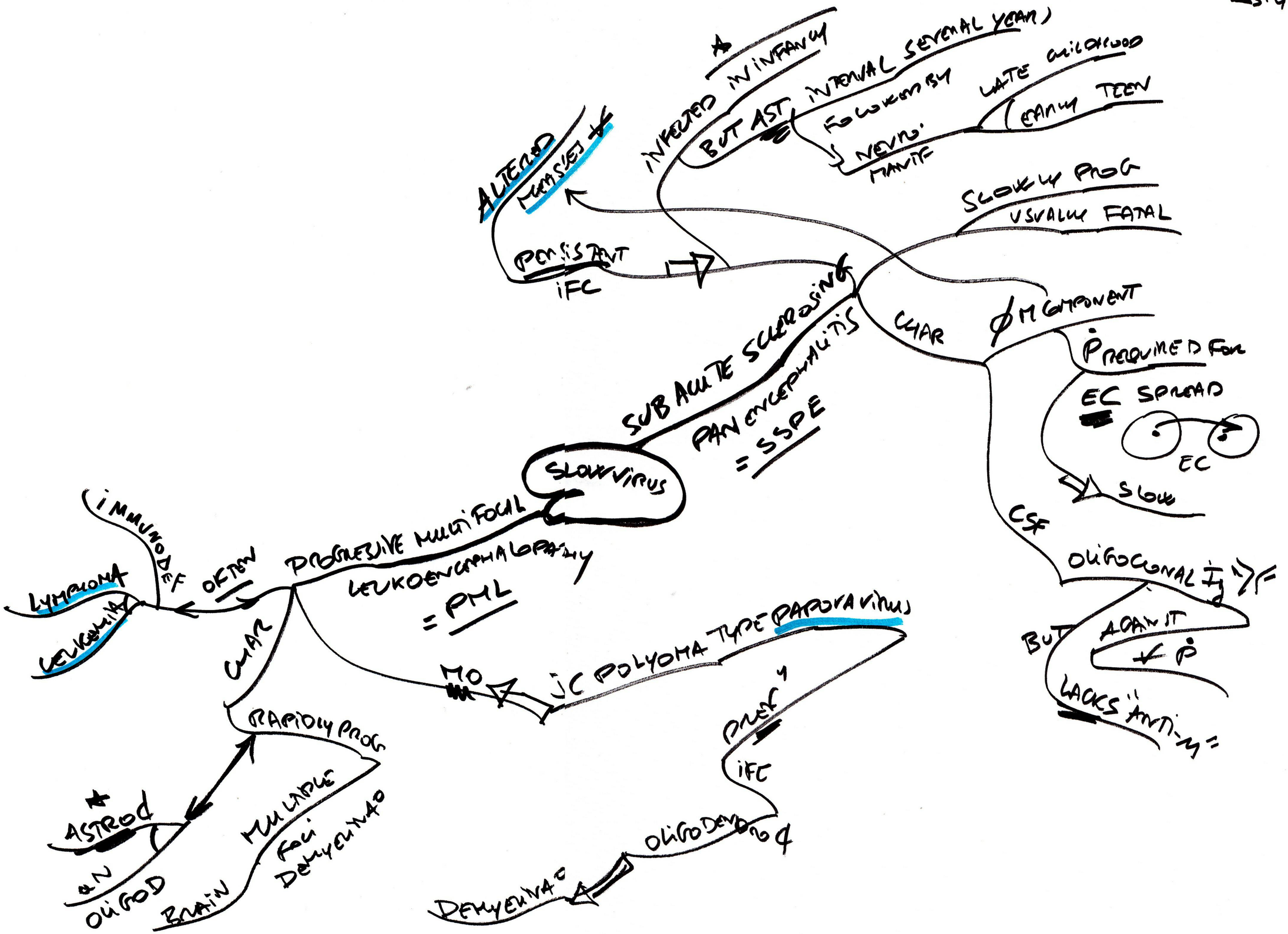
SUBACUTE SCLEROSING PANENCEPHALITIS = SSPE
INFECTED IN INFANCY
BUT AST
INTERVAL SEVERAL YEARS
FOLLOWED BY NEURO MANIF
LATE CHILDHOOD
EARLY TEEN
SLOWLY PROG
USUALLY FATAL
ALTERED MENTATION
PERSISTENT IFC
CHAR
Ø M COMPONENT
PREFERRED FOR EC SPREAD
EC
SLOW
CSF
OLIGOCLONAL Ig
BUT AGAINST ↓ P
LACKS "ANTI-M"
SLOW VIRUS
PROGRESSIVE MULTIFOCAL LEUKOENCEPHALOPATHY = PML
IMMUNODEF
OFTEN
LYMPHOMA
LEUKEMIA
CHAR
RAPIDLY PROG
MULTIPLE FOCI DEMYELINATION
BRAIN
ASTROCYTE
OLIGOD
MO
JC POLYOMA TYPE PAPOVAVIRUS
PREF
IFC
OLIGODENDROCYTE
DEMYELINATION

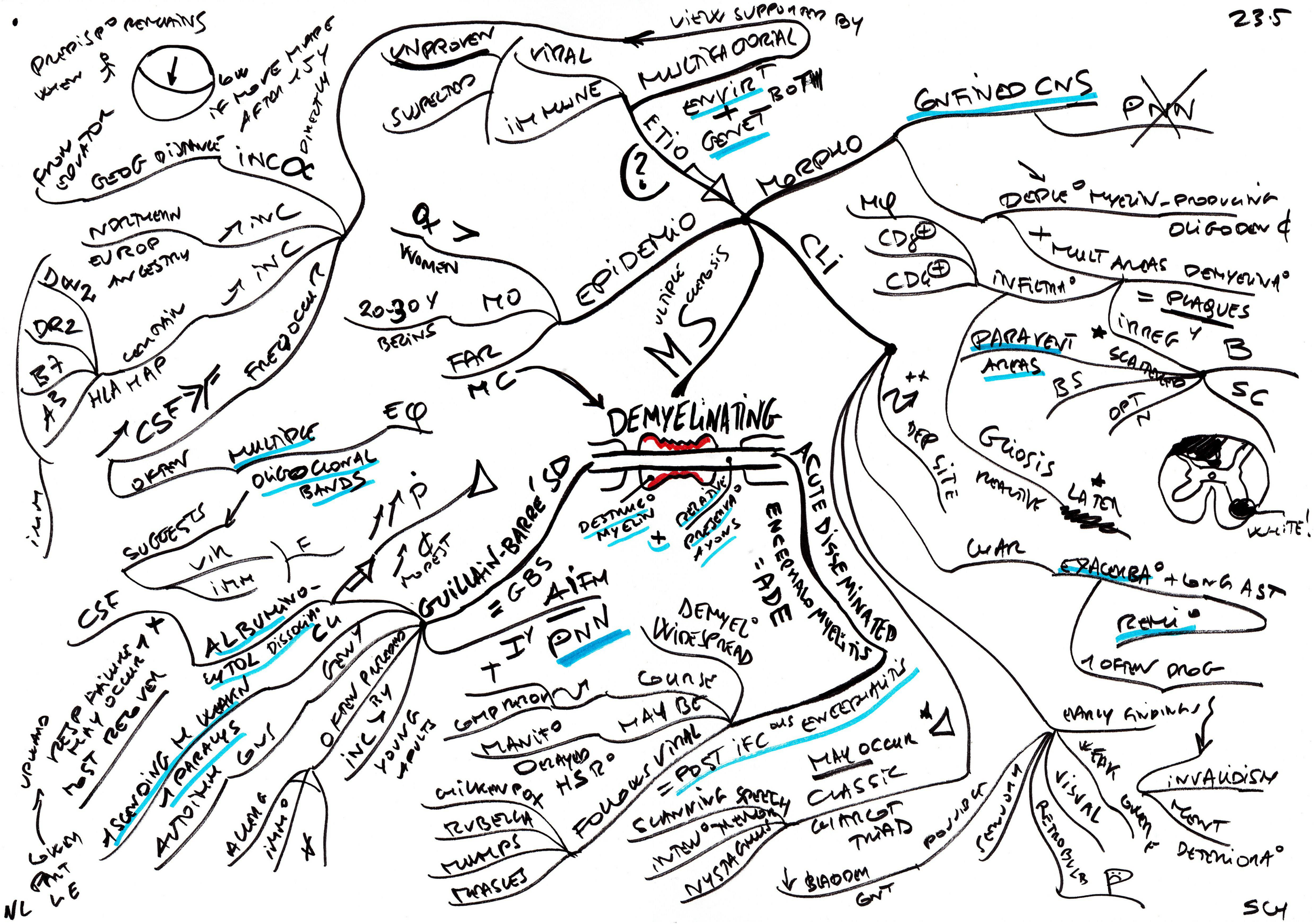
DEMYELINATING
MS
unique
EPIDEMIO
Q > women
20-30 y begins
MO
FAM MC
Q
PREDISPO REMITTING
low if move away after 15 y
GEOG DISTANCE
INC
NORTHERN EUROP ANCESTRY
DR2
DR2
B7
A3
HLA HAP
certain
CSF
frequent
OFTEN
MULTIPLE OLIGOCLONAL BANDS
EQ
SUGGESTS
VIR
IMM
F
CSF
ALBUMINO-CYTOL DISSOCIATION
ASCENDING M WEAKN
PARALYS
AUTONOM SYS
OFTEN PARADOXICAL
INCL TRY
YOUNG ADULTS
ALLERG
IMMO
GUILLAIN-BARRÉ SD
= GBS
AIFM
PNN
DESTRUCTO MYELIN
REPAIRING PROCESSES
ACUTE DISSEMINATED ENCEPHALOMYELITIS
= ADE
DEMYEL WIDESPREAD
COURSE
MAY BE
MANIFO
ERRATIC
HSP
FOLLOWS VIRAL
= POST IFC
MAY OCCUR
CLASSIC
CHARCOT TRIAD
SCANNING SPEECH
INTENTION TREMOR
NYSTAGMUS
BLADDER
GUT
POSSIBLE
SENSORIUM
VISUAL
RETROBULB
WEAK
GAIT
INVALIDISM
MENT
DETERIORATION
EARLY FINDINGS
CHAR
EXACERBATION + LONG AST
REMISSION
1 OFTEN DROP
GLIOSIS
PERIVENT
AREAS
BS
SCATTERED
OPT N
SC
LATER
WHITE!
INFILTRATION
INFLAM
= PLAQUES
B
CLI
MORPHO
GENERALIZED CNS
PNN
DEPLETION MYELIN-PRODUCING OLIGODEN
+ MULT AREAS DEMYELINATION
MΦ
CD8⊕
CD4⊕
VIRUS SUPPORTED BY
MULTIFACTORIAL
VIRAL
IMMUNE
UNPROVEN
SUSPECTED
ETIO
ENVIRT + GENET
BOTH
?
CSF
UPWARD
RESP FAILURE MAY OCCUR
MOST RECOVER
GRAM
NL
ANT
LE
SCH

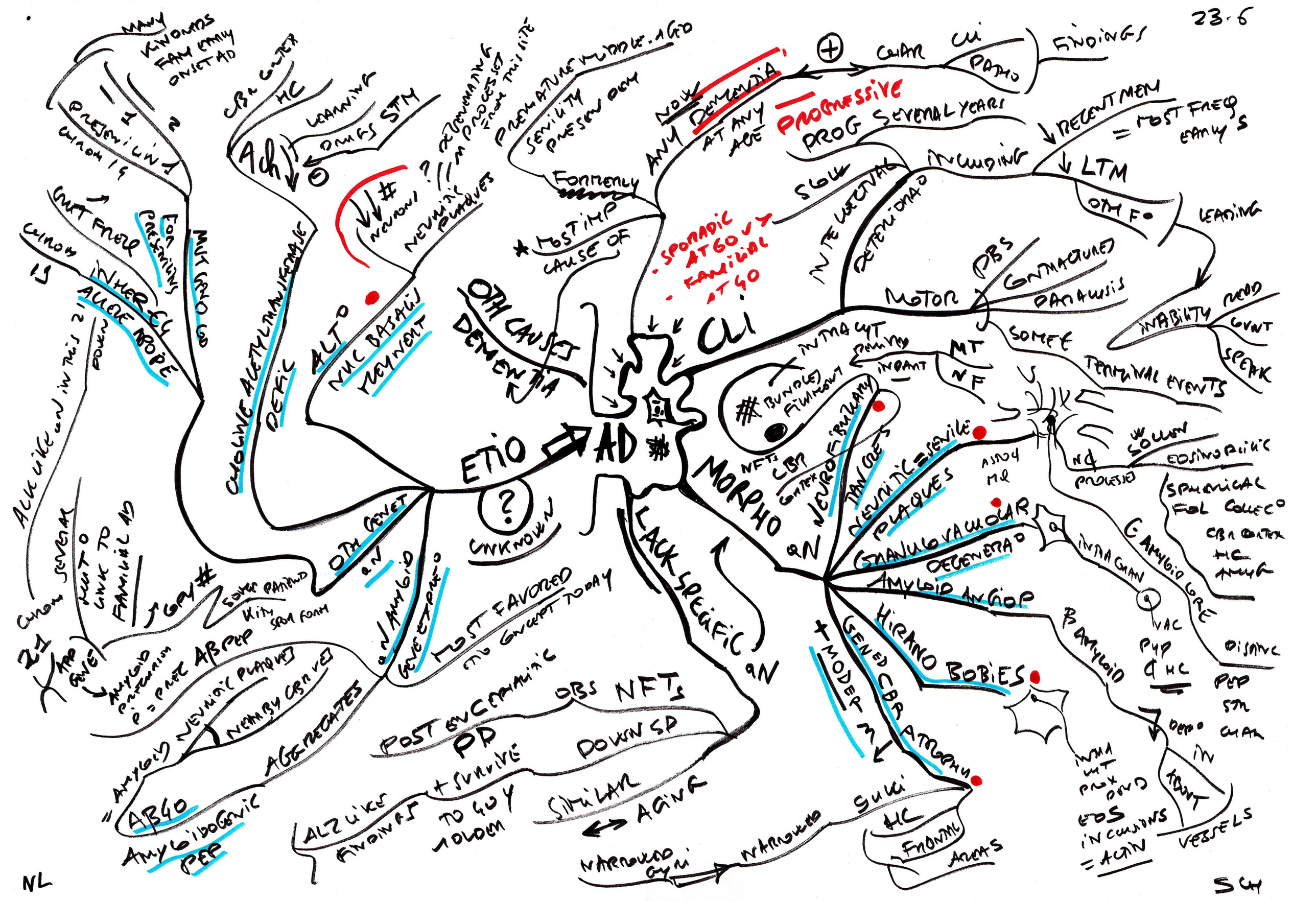
ETIO
AD
CLI
MORPHO
LACK SPECIFIC
UNKNOWN
OTH CAUSES DEMENTIA
ALT
NUC BASAL MEYNERT
CHOLINERGIC DEFIC
ACETYLCHOLINESTERASE
MULTIFACTORIAL
ENERGY
ACUTE NEURONAL
ACUTE LIKE
CHRON SENILE
FAMILIAL AD
OTH GENET
AN
AMYLOID
GENETICS
MOST FAVORED
GENETICS TODAY
ABPP
AMYLOID PRECURSOR
PLAQUES
NEURITIC PLAQUES
NEARBY CBR VES
AGGREGATES
AB40
AMYLOIDOGENIC
PEP
ALZ LIKE FAMILIAL
+ SURVIVE
TO 40Y
TOLOM
POST ENCEPHALITIC
PD
OBS
NFTs
DOWN SD
SIMILAR
AGING
NARROWED GYRI
NARROWED
SULCI
HC
FRONTAL
AREAS
MODERN
GENED CBR ATROPHY
NEURONAL
NFTs
CBR CORTEX
TANGLES
NEURITIC = SENILE
PLAQUES
GRANULOVACUOLAR
DEGENERATION
AMYLOID ANGIOP
HIRANO BODIES
B AMYLOID
INTRA CHAN
VAC
PYR & HC
C AMYLOID CORE
SPHERICAL FOL COLLECT
CBR CORTEX
HC
AMYGD
DISTINCT
PEP
STR
CHAR
DEPO IN
TRUNK
VESSELS
INTRA MT PROX DIVD
EOS INCLUSIONS = ACTIV
NO PROTEIN
SOLID
EOSINOPHILIC
ASTRO MG
MT
NF
INFANT
INTRA CYT PRUNING
BUNDLED FILAMENT
VOCABULARY
ILE
SOME
TERMINAL EVENTS
INABILITY
READ
COUNT
SPEAK
LEADING
OTH F
LTM
RECENT MEM
= MOST FREQ EARLY S
INCLUDING
MOTOR
PBS
CONTRACTURED
PARALYSIS
DETERIORATED
INTELLECTUAL
SLOW
SPORADIC AT 60Y
FAMILIAL AT 40
PROGRESSIVE
PROG SEVERAL YEARS
ANY DEMENTIA
AT ANY AGE
NOW
CLIN
PATHO
FINDINGS
CHAR
PREMATURE MIDDLE-AGED
SENILITY
PRESENILE
FORMERLY
MOST IMP
CAUSE OF
NEURONAL
NEURITIC PLAQUES
ALCOHOL
HC
CBR CORTEX
LEARNING
DRUGS STM
Ach
PRESENILIN
CHRON 19
MUT FRIED
CHRON 13
FAM PRESENILINS
ALCOHOL IN THIS 21
PROTEIN
MANY
KINDREDS
FAM FAMILY
ONSET AD
21
APP GENE
AMYLOID PRECURSOR
β = PNET ABPEP
GPI #
SOLUBLE PATHOLOGY
SOLUBLE FORM
NL
SCH

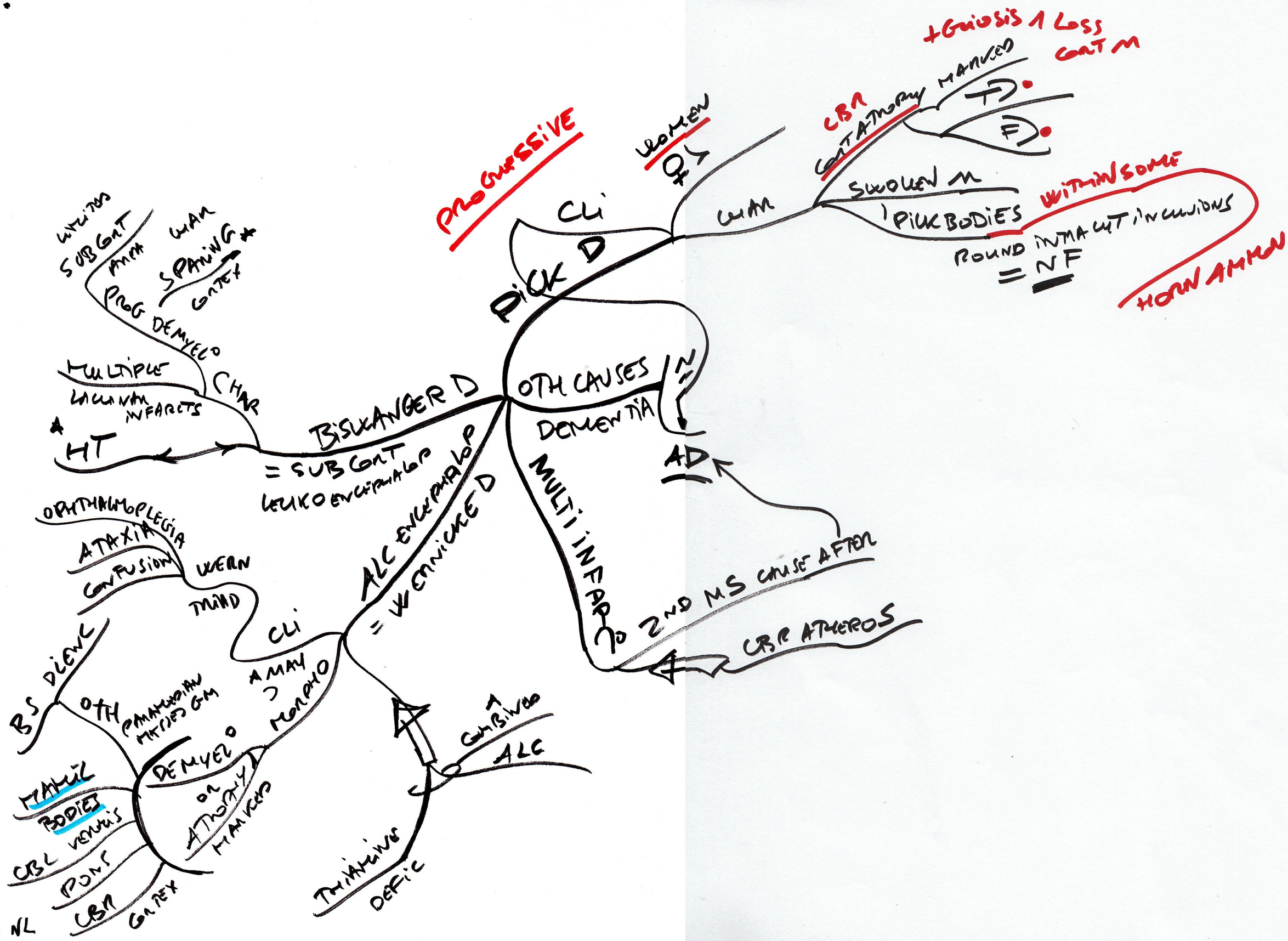
PROGRESSIVE
CLI
PICK D
WOMEN
CBA
CORTATHORY MANIFEST
+GLIOSIS + LOSS CORT N
SWOLLEN N
PICK BODIES
WITHIN SOME
ROUND INTRACYT INCLUSIONS
= NF
HORN AMMON
WAN
WITHOUT SUBCORT ANEM
WAN SPARING
CORTEX
PROG DEMYELO
CHAR
MULTIPLE LACUNAR INFARCTS
HT
BISWANGER D
= SUBCORT LEUKOENCEPHALOP
OTH CAUSES
DEMENTIA
N
AD
MULTI INFARCTS
2ND MS CAUSE AFTER
CBR ATHEROS
ALC ENCEPHALOP
= WERNICKE D
OPHTHALMOPLEGIA
ATAXIA
CONFUSION
WERN
THIRD
CLI
AMAY
MORPHO
BS DIENC
OTH
PARAVERMIAN MYELIN GM
DEMYEL
OR ATHORTY MANIFEST
TAU
BODIES
CBL VERMIS
PONS
CBR
CORTEX
NL
THIAMINE DEFIC
COMBINED
ALC

SCH

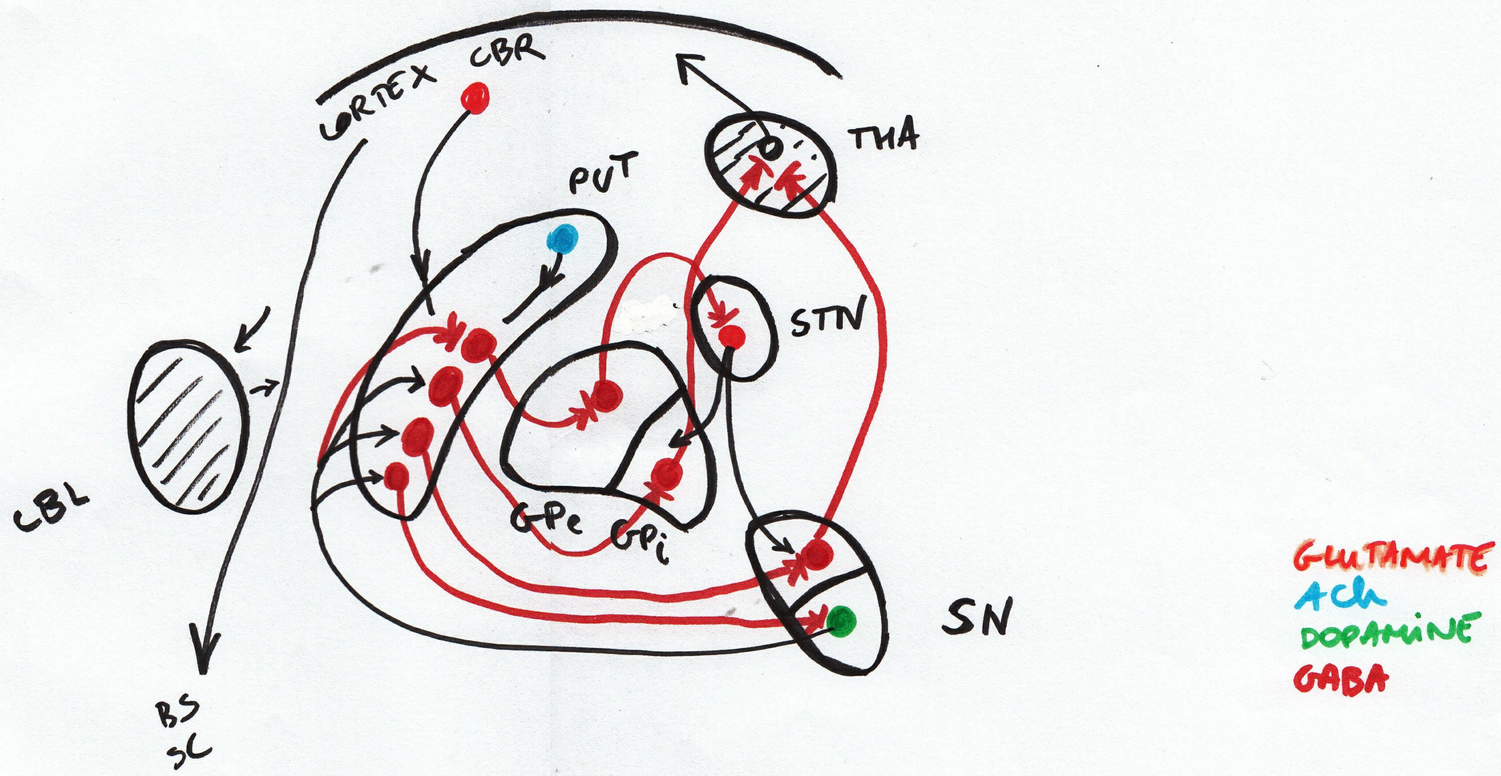

STRIATUM = PUT + CAUDATE NUCLEUS

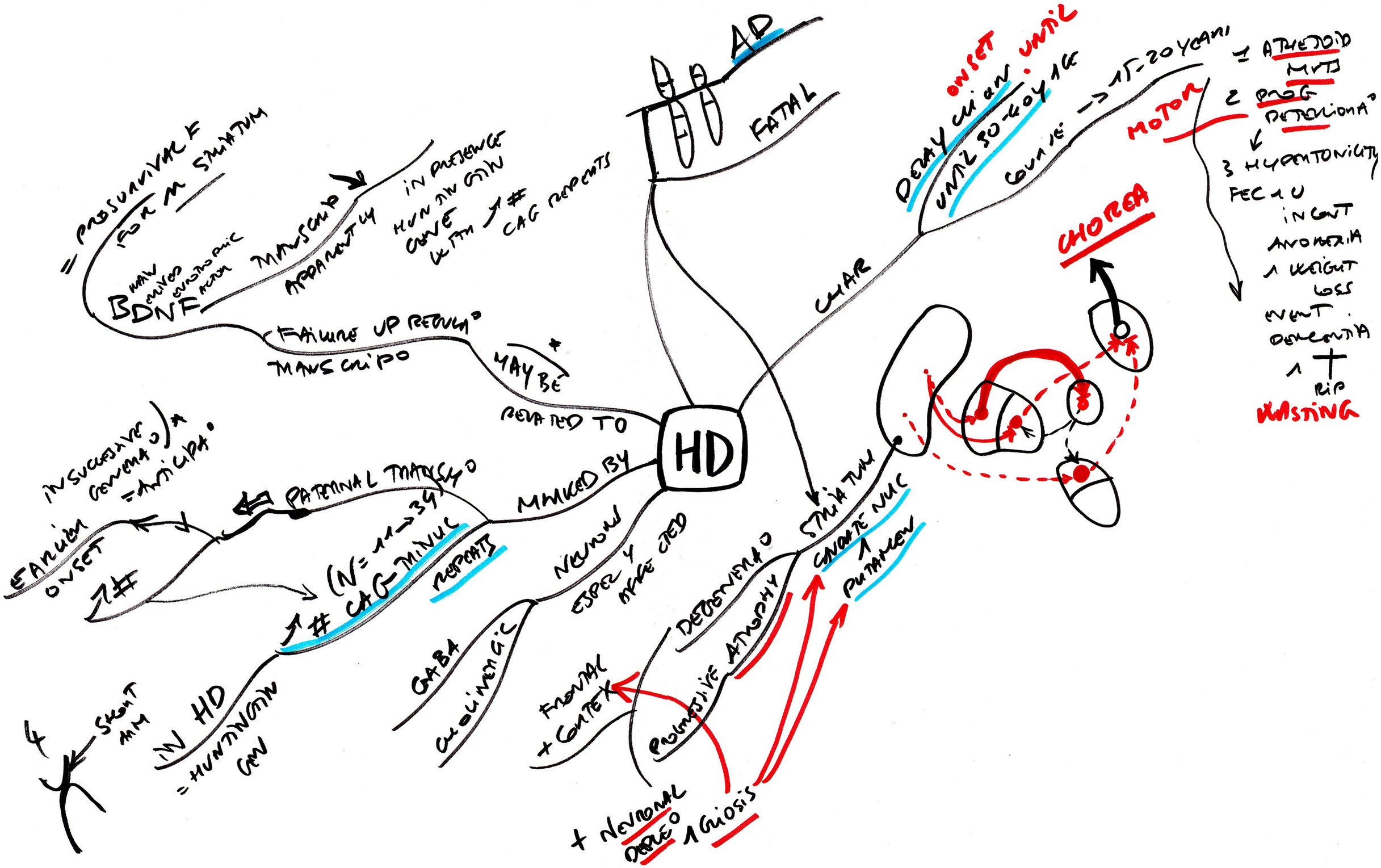
HD
AD
FATAL
ONSET
DEAY CLIAN
UNTIL
UNTIL 30-40 Y AGE
COURSE -> 15-20 YEARS
MOTOR
1 ATHETOID MVTS
2 PROG DETERIORATION
3 HYPERTONICITY
FEC + U
INCONT
ANOREXIA
↓ WEIGHT LOSS
EVENT. DEMENTIA
↑ RIP
WASTING
CHOREA
STRIATUM
CAUDATE NUC
↑ PUTAMEN
DEGENERATION
PROGRESSIVE ATROPHY
FRONTAL + CORTEX
+ NEURONAL DEPLE
↑ GLIOSIS
NEURONS ESPEC Y MEDIUM SIZED
GABA
GLUTAMERGIC
MARKED BY
PATERNAL TRANSMISSION
(N = 11 -> 39)
↑ # CAG MINUC REPEATS
EARLIER ONSET
↑ #
INSUCCESSIVE GENERATION = ANTICIPATION
IN HD
= HUNTINGTIN GENE
↑ SHORT ARM
RELATED TO
MAYBE
FAILURE UP REGULATION
TRANSCRIPTION
BDNF
MAIN NEURO ELECTROPHYSIOLOGIC ACTION
TRANSCRIP APPARENTLY
IN PRESENCE HUNTINGTIN GENE LEADS ↑ # CAG REPEATS
= PROSURVIVAL FOR M STRIATUM

NL

SCH

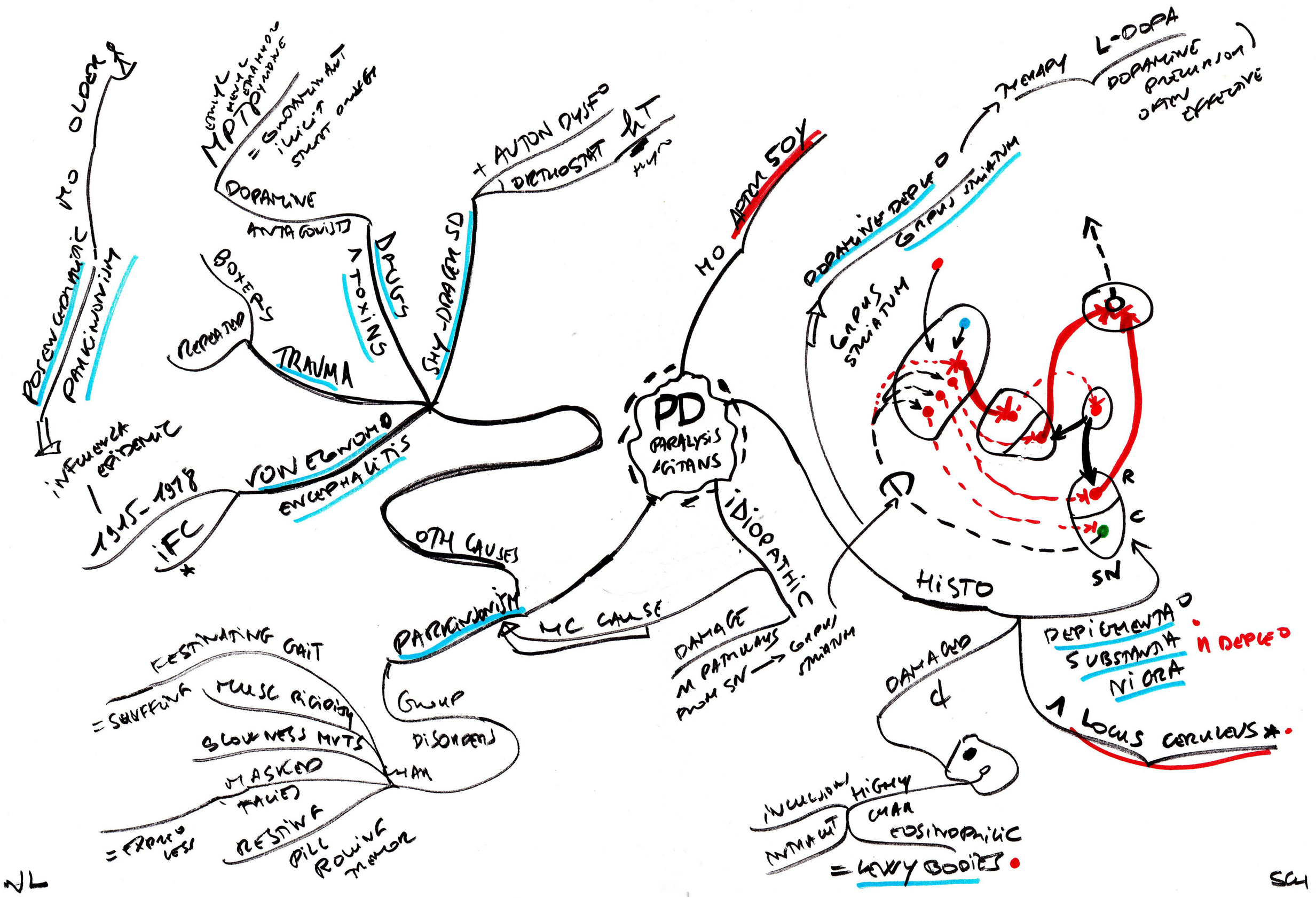
PD
PARALYSIS AGITANS
MO OLDER
POSTENCEPHALITIC
PARKINSONISM
INFLUENZA EPIDEMIC
1915-1918
IFC
VON ECONOMO ENCEPHALITIS
MPTP
= SYNTHETIC HEROIN
DOPAMINE ANTAGONISTS
BOXERS
REPEATED TRAUMA
TOXINS
DRUGS
SHY-DRAGER SD
+ AUTON DYSFO
ORTHOSTAT hT
HYPO
OTH CAUSES
PARKINSONISM
MC CAUSE
IDIOPATHIC
MO AFTER 50Y
DAMAGE IN PATHWAYS FROM SN → CAUDATE STRIATUM
DOPAMINE DEPLETED
CAUDATE STRIATUM
THERAPY L-DOPA
DOPAMINE PRECURSOR OFTEN EFFECTIVE
CAUDATE STRIATUM
D
R
C
SN
HISTO
DEPIGMENTATED SUBSTANTIA NIGRA
N DEPLETED
LOCUS CERULEUS
DAMAGED
INCLUSIONS IN NEURONS
HIGHLY CHAR EOSINOPHILIC
= LEWY BODIES
FESTINATING GAIT
= SHUFFLING
MUSC RIGIDITY
SLOWNESS MVTS
MASKED FACIES
= EXPRESSIONLESS
RESTING TREMOR
PILL ROLLING TREMOR
GROUP DISORDERS
MAM

NL

SCH

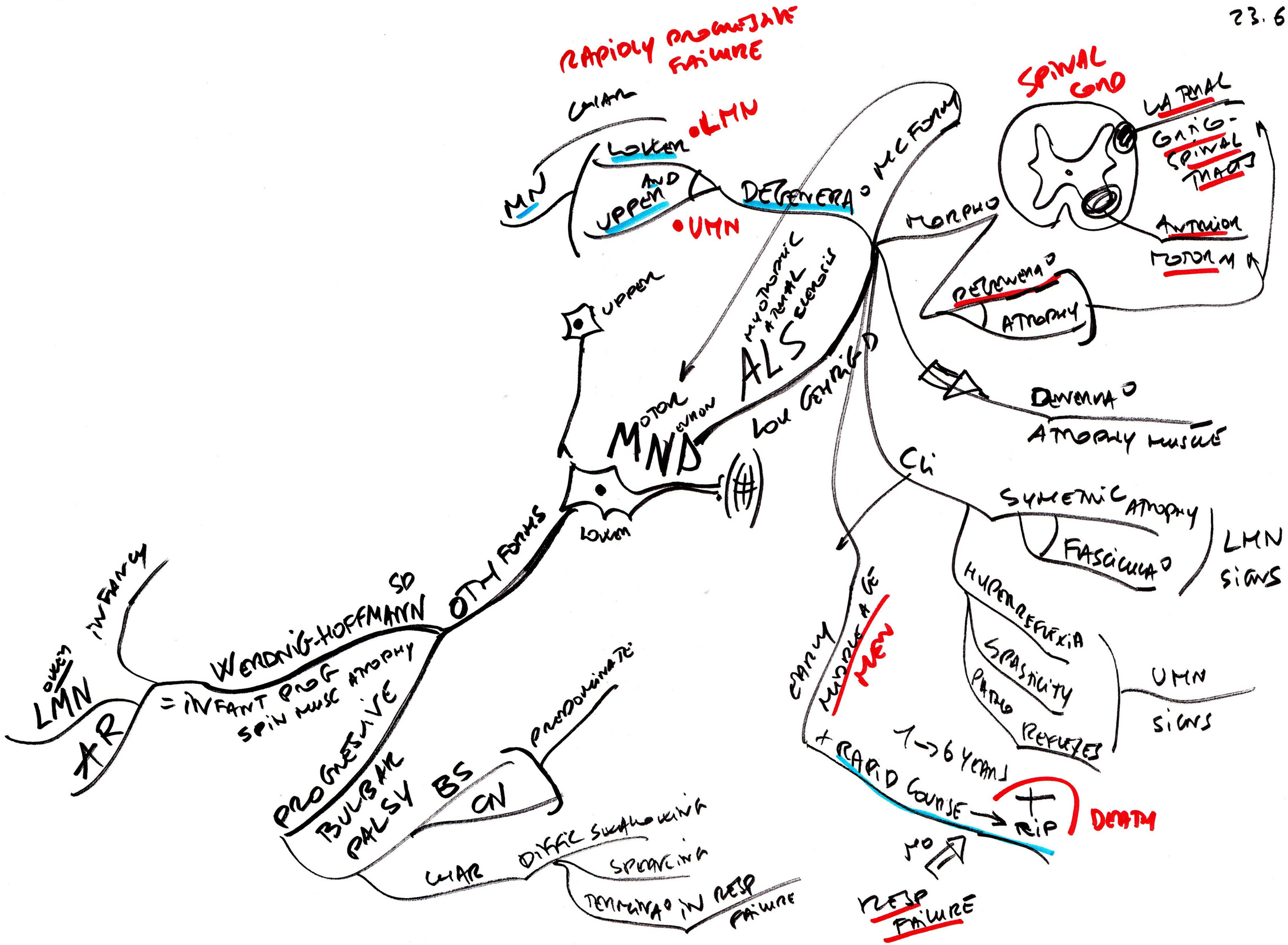
RAPIDLY PROGRESSIVE FAILURE
CHAR
MN
LOWER
• LMN
UPPER AND
• UMN
DEGENERA
• MC FORM
SPINAL CORD
LATERAL
CORTICO-SPINAL TRACTS
ANTERIOR
MOTOR N
MORPHO
DEGENERA
ATROPHY
DEGENERA
ATROPHY MUSCLE
UPPER
MOTOR NEURON
MND
MYOTROPHIC LATERAL SCLEROSIS
ALS
LOW GENERAL
LOWER
OTH FORMS
SD
WERDNIG-HOFFMANN
= INFANT PROG SPIN MUSC ATROPHY
INFANCY
LMN
AR
OWEN
PROGRESSIVE BULBAR PALSY
BS
CN
PREDOMINATE
CHAR
DIFFIC SWALLOWING
SPEAKING
DEGENERA IN RESP FAILURE
Chi
SYMETRIC ATROPHY
FASCICULAR
LMN SIGNS
HYPERREFLEXIA
SPASTICITY
PATHO REFLEXES
UMN SIGNS
CRAMP
MUSCLE AGE
MEN
+ RAPID COURSE
1 → 6 YEARS
+ RIP
DEATH
NO
RESP FAILURE

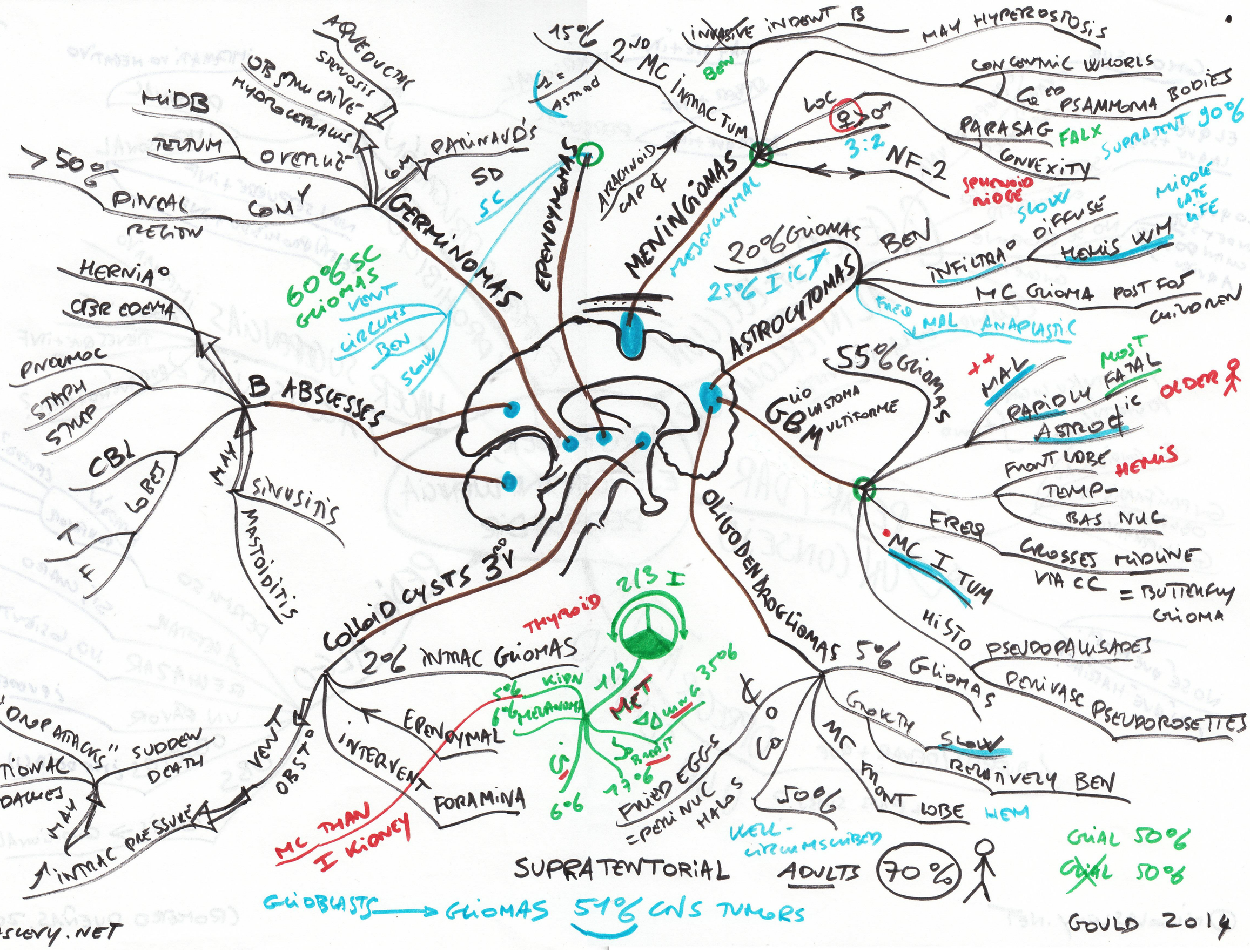
GERMINOMAS
>50%
PINEAL REGION
MIDB
TETRAD
OVERNUT
OBSTRUCTIVE HYDROCEPHALUS
AQUEDUCTAL STENOSIS
GM
PARINAUD'S
SD
SC
EPENDYMOMAS
ARACHNOID CYST
15% 2ND MC INTRACTUM
INVASIVE INDENT B
BEN
MAY HYPEROSTOSIS
CONCENTRIC WHORLS
GEO PSAMMOMA BODIES
LOC
♀>♂
3:2 NF-2
PARASAG FALX
CONVEXITY
SUPRATENT 90%
MENINGIOMAS
MESENCHYMAL
SPHENOID RIDGE
SLOW
MIDDLE LATE LIFE
20% GLIOMAS
25% ICT
BEN
INFILTRATE DIFFUSE
HEMIS WM
MC GLIOMA POST FOSS
CHILDHOOD
FREQ MAL ANAPLASTIC
ASTROCYTOMAS
60% SC GLIOMAS
VENT
CIRCUMS
BEN
SLOW
HERNIATE
CBR EDEMA
PNEUMOC
STAPH
STREP
B ABSCESSES
CBL
LOBES
T
F
MAY
SINUSITIS
MASTOIDITIS
COLLOID CYSTS 3RD V
55% GLIOMAS
++ MAL
MOST FATAL
RAPIDLY
ASTROCYTIC
OLDER
GLIOBLASTOMA MULTIFORME
FRONT LOBE
HEMIS
TEMP-
BAS NUC
FREQ
MC ITUM
GROSSES MIDLINE
VIA CC
= BUTTERFLY GLIOMA
OLIGODENDROGLIOMAS
5% GLIOMAS
HISTO PSEUDOPALISADES
PERIVASC PSEUDOROSETTES
GROWTH
SLOW
RELATIVELY BEN
MC FRONT LOBE
WHO
50%
CELL-LITE MYXOID
2% INTRAC GLIOMAS
THYROID
2/3 I
1/3
MET
Δ 3500
Δ RADIT
17%
FRIED EGGS
= PERI NUC HALOS
6%
5%
6% MELANOMA
KIDN
EPENDYMAL
INTERVENT FORAMINA
MC THAN I KIDNEY
VENT OBSTO
"ONSET ATTACKS"
SUDDEN DEATH
POSITIONAL HEADACHES
MAY
↑INTRAC PRESSURE
SUPRATENTORIAL ADULTS 70%
GLIAL 50%
~~GLIAL~~ 50%
GLIOBLASTS → GLIOMAS 51% CNS TUMORS
NICOLASCERY.NET
GOULD 2014

INFRATENT POST FOSSA CHILDREN 70% ♂

&

INFRASPINAL

NICOLASLEVY.NET

GOULD 2014.

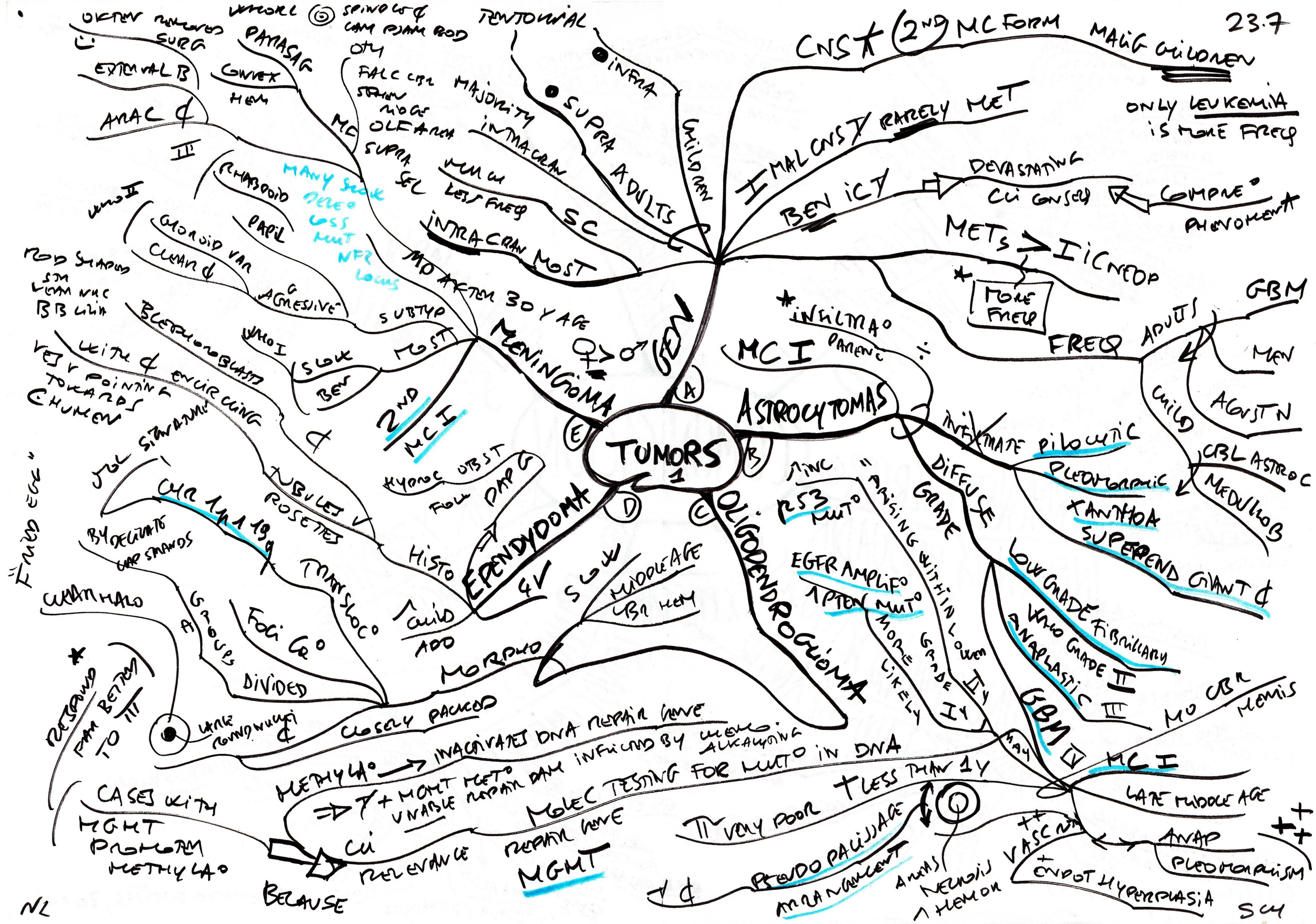
23.7
TUMORS 1
MENINGIOMA
CNS (2ND) MC FORM
MALIG CHILDREN
ONLY LEUKEMIA IS MORE FREQ
MALCNS RARELY MET
BEN ICT
DEVASTATING
CLI CONSEQ
COMPLE PHENOMENA
METS > ICNEOP
MORE FREQ
FREQ ADULTS
GBM
MEN
AGUST N
CHILD
CBL ASTROC
MEDULLOB
INFRA
SUPRA
ADULTS
CHILDREN
TENTORIAL
MAJORITY INTRACRAN
SUPRA
INTRACRAN MOST
SC
LESS FREQ
MP AFTER 30 YAGE
SUBTYP
MOST
SLOW
BEN
WHO I
2ND MC I
MC SUPRA
OLFACTORY
CONVEX
HEM
EXTERNAL B
ARAC
II
WHO II
CHORDOID
PAPIL
CLEAR
AGRESSIVE
BLEPHAROPLASTY
VEIN & ENVIRONING
VERY POINTING TOWARDS CHUMEN
JOL SIMANANC
ROD SHAPED SM LYMPHOC BB LIN
MANY SLOW GROW LESS MUT NFR LOCUS
ASTROCYTOMAS
MC I
INFILTRAO PARENC
INFILTRATE PILOCYTIC
PLEOMORPHIC XANTHOA
SUPERTEND GIANT
LOW GRADE FIBRILLARY
WHO GRADE II
ANAPLASTIC III
GBM IV
MC I
LATE MIDDLE AGE
ANAP PLEOMORPHISM
MO CBR
MENIS
DIFFUSE
GRADE
RISING WITHIN LOWER GRADE
MORE LIKELY
MAY
OLIGODENDROGLIOMA
1P/19q
LOSS
EGFR AMPLIFO
PTEN MUT
MIDDLE AGE
CBR HEM
SLOW
EPENDYDOMA
4V
CHILD ADO
HISTO
TUBULES
ROSETTES
TRANSLOCO
HYPOC OBST
FOLD PAPG
BY DELICATE CAP SPANDS
CHAN HALO
GROUPS
FOCI GO
DIVIDED
MORPHO
CLOSELY PACKED
LARGE ROUND NUCLI
RESPOND PAM BETTER TO III
CASES UCITY
MGMT PROMOTER METHYLAO
BECAUSE
CLI RELEVANCE
MOLEC TESTING FOR MUTO IN DNA
METHYLAO → INACTIVATES DNA REPAIR GENE
→ + MGMT MUTO VNABLE REPAIR DAM INFLICTED BY MEMO ALKALAMING
REPAIR GENE
MGMT
LESS THAN 1Y
VERY POOR
PSEUDOPALISADE
MANAGEMENT
ANIMS
NECROSIS
HEMOR
VASCN
ENDOT HYPERPLASIA
SCH
NL
FINDING

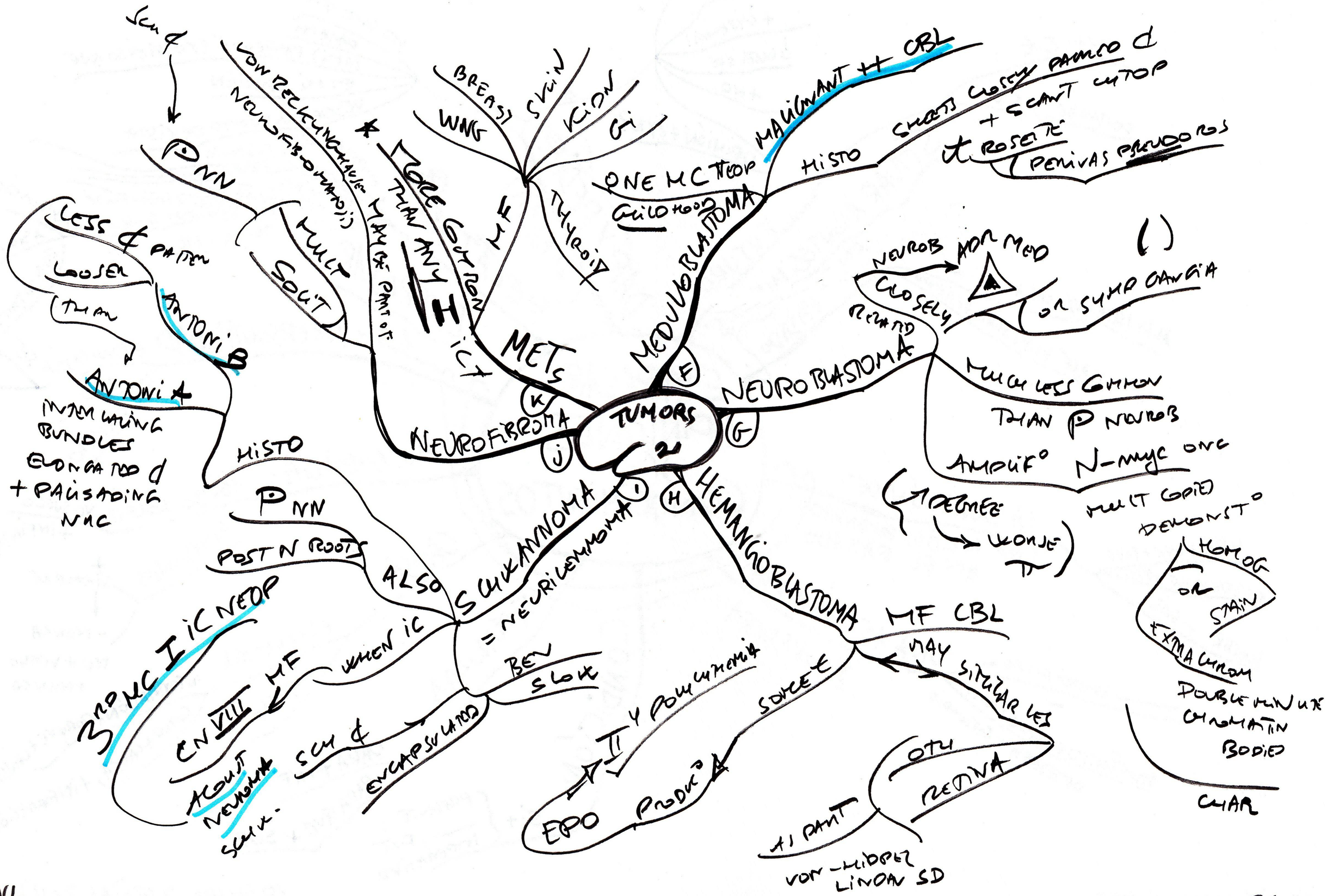
TUMORS
2
NEUROFIBROMA
MET
BREAST
SKIN
KIDN
GI
WNG
THYROID
MORE COMMON THAN ANY
ICT
MALIGNANT ++ CBL
ONE MC TROP
GUILOHOOD
MEDULLOBLASTOMA
HISTO
SHEETS CLOSELY PACKED
+ SCANT CYTOP
ROSETTE
PERIVAS PSEUDOROS
NEUROBLASTOMA
NEUROB ADR MED
CLOSELY
RELATED
OR SYMP GANGIA
MUCH LESS COMMON
THAN P NEUROB
AMPLIF° N-MYC ONC
MULT COPIES
DEGREE
UKONJE
DEMONST°
HOMOG
OR
STAIN
EXTRACHROM
DOUBLE MINUTE
CHROMATIN
BODIES
CHAR
HEMANGIOBLASTOMA
MF CBL
MAY
SIMILAR LES
OTH
RETINA
VON-HIPPEL
LINDAU SD
SCHWANNOMA
= NEURILEMMOMA
BEN
SLOW
SOLITE
ENCAPSULATED
WHEN IC
MF
CN VIII
ACOUST
NEUROMA
SCHW.
SCH
3RD MC I IC NEOP
LESS
PATTERN
LOOSER
THAN
ANTONI B
ANTONI A
INTERWEAVING
BUNDLES
ELONGATED
+ PALISADING
NUC
HISTO
P NN
POST N ROOT
ALSO
NF
NEUROFIBROMATOSIS
MALIGNANT PART OF
MULT
SOLIT
SCH
P NN
Y POLYCYTHEMIA
EPO
PRODUC
TI

NL

SCH

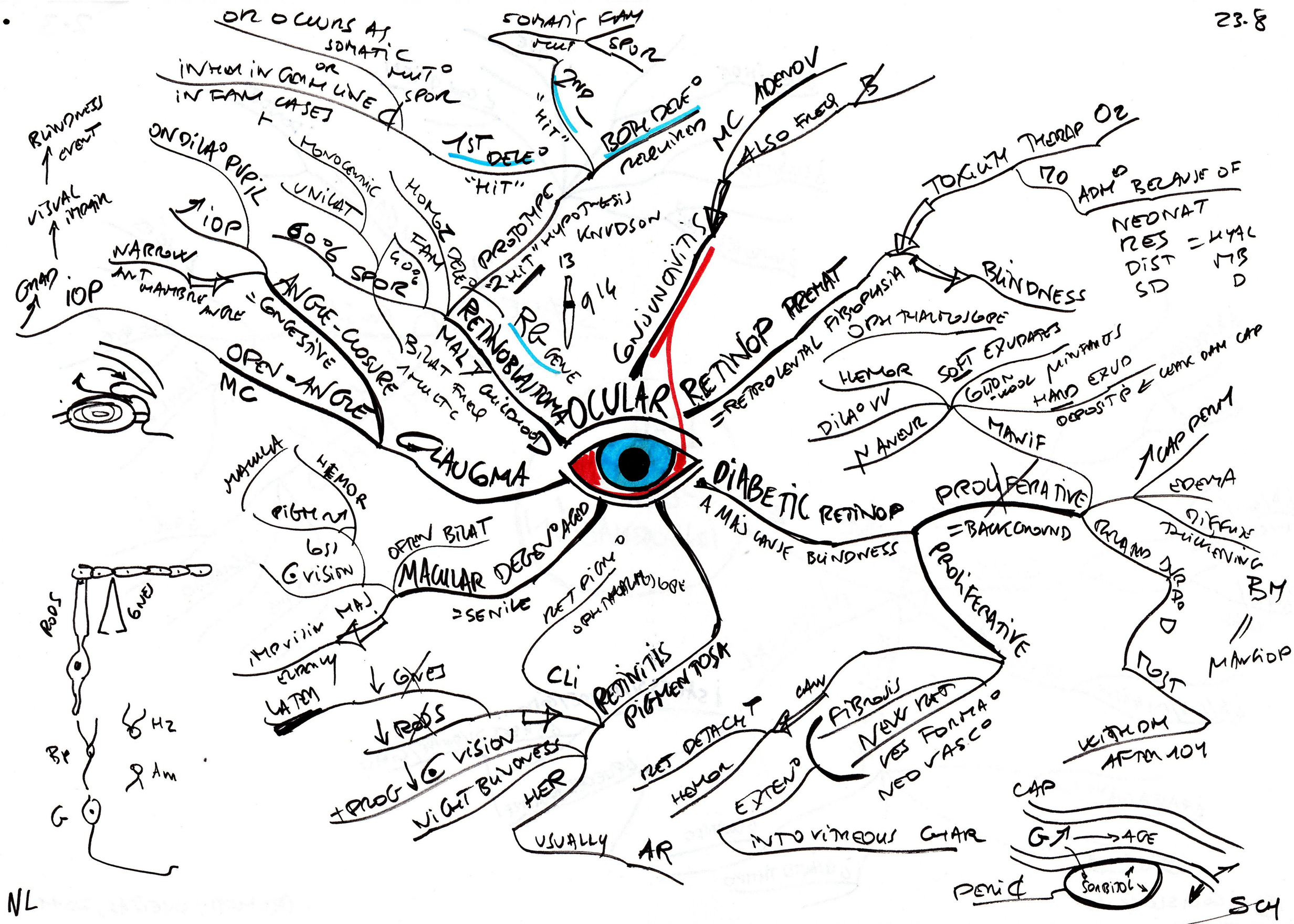
OCULAR
OR OCCURS AS SOMATIC MUT° OR INTRON IN GERM LINE
INFAM CASES
SOMATIC FAM
FAM
SPOR
2ND "HIT"
1ST DELE° "HIT"
BOTH DELE° RETINOB
MC ADENOV
ALSO FREQ B
TOXICITY THERAP O2
ADM° BECAUSE OF
NEONAT
RES = HYAL
DIST MB
SD D
BLINDNESS
RETROLENTAL FIBROPLASIA
OPHTHALMOSCOPE
RETINOP PREMAT
CONJUNCTIVITIS
RETINOBLASTOMA
PROTOTYPE
"2 HIT" HYPOTHESIS KNUDSON
13
9 14
RB GENE
MALT
BILAT FREQ
MONOCENTRIC
UNILAT
HOMOZ FAM DELE°
60% SPOR
40%
RUBINESS ↑ EVENT
VISUAL ↑ IMPAIR
ON DILAT° PUPIL
↑ IOP
NARROW ANT CHAMBER ANGLE
GRAD ↑ IOP
ANGLE-CLOSURE "CONGESTIVE"
OPEN-ANGLE
MC
GLAUCOMA
HEMOR
SOFT EXUDATES
COTTON-WOOL MINIMATS
HARD EXUD
DEPOSITS ← LEAK DAM CAP
DILAT° VV
↓ ANEUR
MANIF
DIABETIC RETINOP
A MAJ CAUSE BLINDNESS
PROLIFERATIVE
= BACKGROUND
PROLIFERATIVE
↑ CAP PERM
EDEMA
DIFFUSE THICKENING
BM
MAJOR
POST
VEITHOM AFTER 10Y
CAP
G ↑ → AGE
SORBITOL ↑
PERI ¢
SCH
MACULA
HEMOR
PIGM
↓ G VISION
OPTIC BILAT
MACULAR DEGEN° ARD
= SENILE
IMPV VISION MAJ
EURMY
LATER
↓ G VES
↓ RODS
+ PROG ↓ G VISION
NIGHT BLINDNESS
HER
USUALLY AR
RET PIGM°
OPHTHALMOSCOPE
CLI
RETINITIS PIGMENTOSA
RET DETACH
HEMOR
EXTEND°
CAN
FIBROUS
NEW RET VES FORMA°
NEOVASC°
INTRAVITREOUS CHAR
RODS
CONES
Hz
Am
BP
G
NL