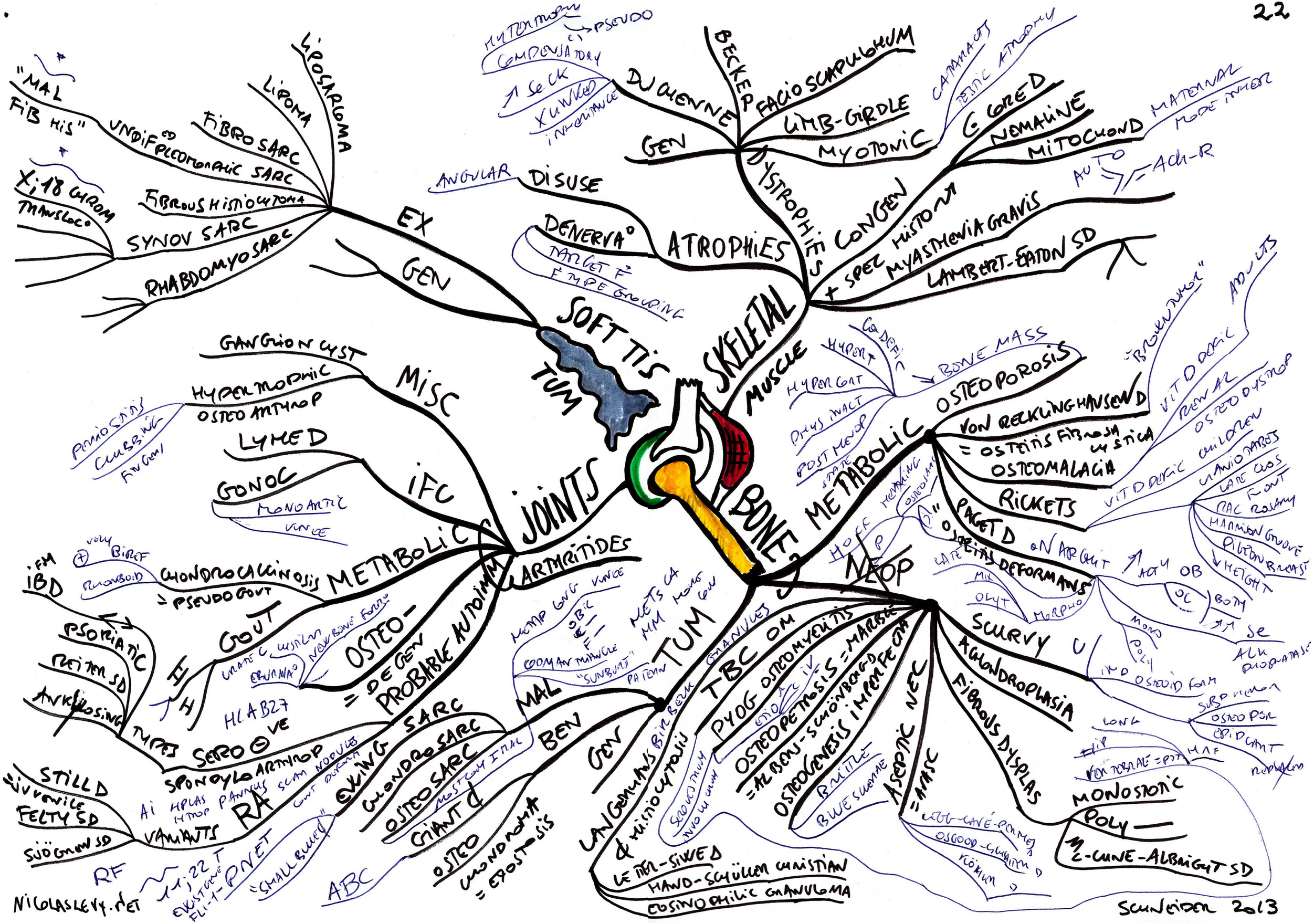
SKELETAL
MUSCLE
BONE
JOINTS
SOFT TIS
TUM
EX
GEN
LIPOSARCOMA
LIPOMA
FIBROSARC
UNDIFED PLEOMORPHIC SARC
FIBROUS HISTIOCYTOMA
SYNOV SARC
RHABDOMYOSARC
"MAL FIB HIS"
X;18 CHROM TRANSLOC°
ATROPHIES
DISUSE
ANGULAR
DENERVA°
TARGET F
F TYPE GROUPING
DUCHENNE
HYPERTROPHY
PSEUDO
COMPENSATORY
SECK
X LINKED INHERITANCE
BECKER
FACIOSCAPULOHUM
LIMB-GIRDLE
MYOTONIC
CATARACTS
TESTIC ATROPHY
CORED
NEMALINE
MITOCHOND
MATERNAL MODE INHER
DYSTROPHIES
CONGEN
+ SPEC HISTO
MYASTHENIA GRAVIS
LAMBERT-EATON SD
AUTO
ACH-R
MISC
GANGLION CYST
HYPERTROPHIC OSTEOARTHROP
PERIOSTITIS
CLUBBING
FINGERS
LYMED
GONOC
MONOARTIC
VINCE
IFC
METABOLIC
CHONDROCALCINOSIS = PSEUDOGOUT
VERY BIREF
RHOMBOID
GOUT
IBD
PSORIATIC
REITER SD
ANKYLOSING
TYPES
SERO ⊖ VE
HLAB27
SPONDYLOARTHROP
RA
AI
HPLAS
HTROP
PANNUS
SCAM NODULES
CONT DEFORM
VARIANTS
STILL D
JUVENILE
FELTY SD
SJÖGREN SD
RF
NICOLASLEVY.NET
11;22 T
EXISTENCE
FLI-1
PNET
"SMALL BLUE"
OSTEO-
= DEGEN
PROBABLE AUTOIMM
ARTHRITIDES
EWING SARC
CHONDROSARC
OSTEOSARC
MOST COMM IMAL
GIANT C
OSTEO
CHONDROMA = EXOSTOSIS
ABC
MAL
BEN
METAP LONG VINCE
OBIC
COOMAN TRIANGLE
"SUNBURST"
PATERN
METS CA
MM
MORE COM
TUM
GEN
LANGERMANS BIRBECK GRANULES
& HISTIOCYTOSIS
LETTER-SIWE D
HAND-SCHÜLLER CHRISTIAN
EOSINOPHILIC GRANULOMA
TBC OM
PYOG OSTEOMYELITIS
OSTEOPETROSIS = MARBLE
= ALBERS-SCHÖNBERG D
OSTEOGENESIS IMPERFECTA
BRITTLE
BLUE SCLERAE
ASEPTIC NEC
= AVASC
LEGG-CAVÉ-PERTHES D
OSGOOD-SCHLATTER D
KÖHLER D
FIBROUS DYSPLAS
ACHONDROPLASIA
SCURVY
C
IMP OSTEOID FORM
MONO
POLY
OSTEOPOR
EPIDCART
REPLACED
MONOSTOTIC
POLY
MC-CUNE-ALBRIGHT SD
NEOP
PAGET D
OSTEITIS DEFORMANS
ON ARCHIT
ACTY
OB
OC
BOTH
SE
ALK PHOSPHATASE
LATE
MIX
OLYT
MORPHO
HOCK
MEDALLING
OSTEOSARC
METABOLIC
OSTEOPOROSIS
VON RECKLINGHAUSEN D
= OSTEITIS FIBROSA CYSTICA
OSTEOMALACIA
RICKETS
VIT D DEFIC
CHILDREN
CRANIOTABES
LATE CLOS
FONT
RAC ROSARY
HARRISON GROOVE
PIGEON BREAST
HEIGHT
"BROWN TUMOR"
ADULTS
VIT D DEFIC
RENAL
OSTEODYSTROP
HYPERT
CO DEFIC
BONE MASS
HYPERCORT
PHYS INACT
POST MENOP
STATE
SCHNEIDER 2013

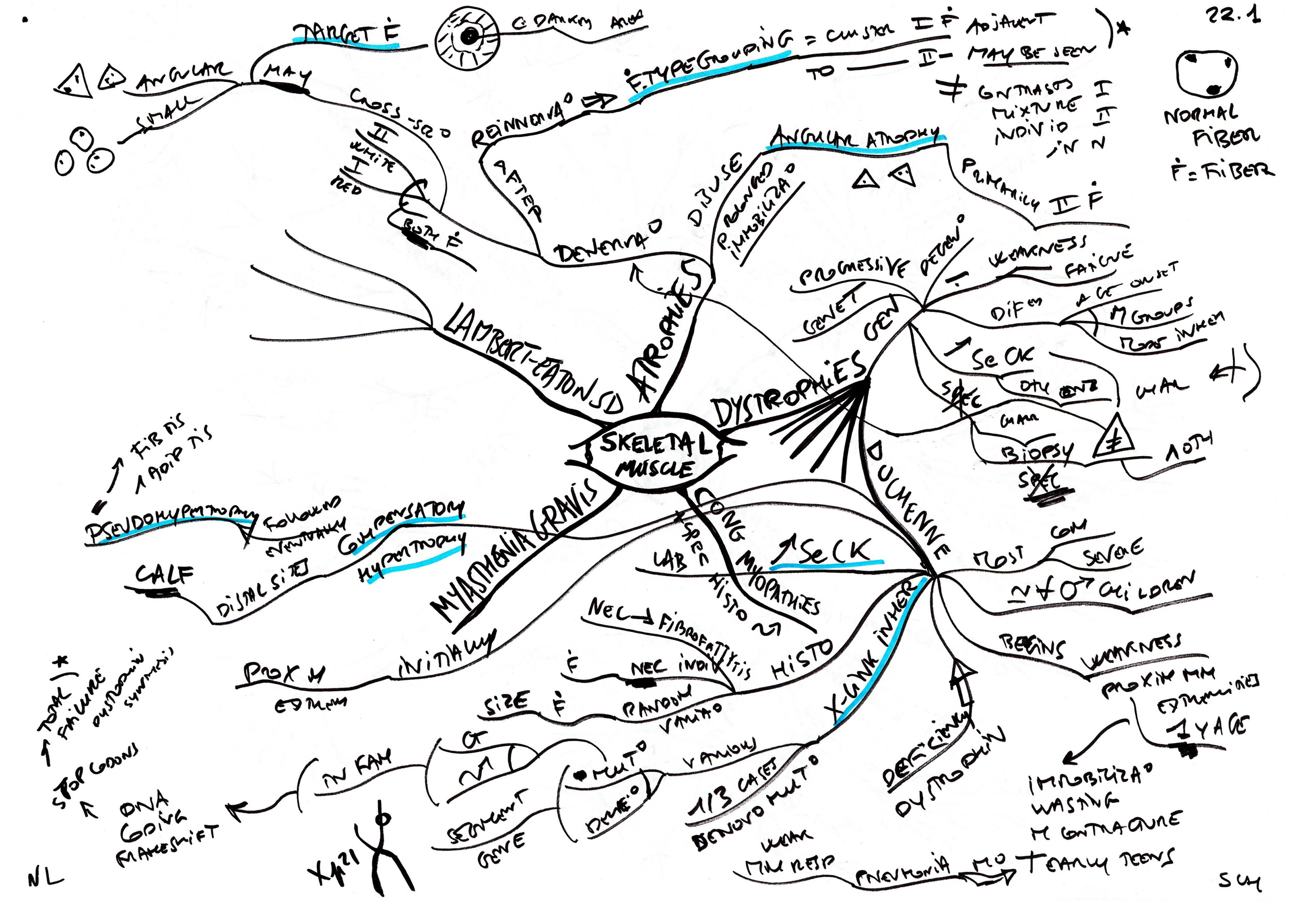
22.1
SKELETAL MUSCLE
LAMBERT-EATON SD
ATROPHIES
DYSTROPHIES
MYASTHENIA GRAVIS
CONG MYOPATHIES
DUCHENNE
X-LINK INHER
TARGET Ḟ
DARKEN AREA
ANGULAR
SMALL
MAY
CROSS-SEC°
II
WHITE
I
RED
BOTH Ḟ
REINNERVA°
AFTER
DENERVA°
Ḟ TYPE GROUPING = CLUSTER I Ḟ ADJACENT
TO II MAY BE SEEN
≠ CONTRASTS
MIXTURE I
INDIVID II
IN N
NORMAL FIBER
Ḟ = FIBER
ANGULAR ATROPHY
PRIMARILY II Ḟ
DISUSE
PROLONGED IMMOBILIZA°
PROGRESSIVE DEGEN°
GENET
GEN
WEAKNESS
FATIGUE
DIFEN
AGE ONSET
M GROUPS
MODE INHER
SeCK
OTH ENZ
CHAR
SPEC
CHAR
BIOPSY
SPEC
≠
NOTH
FIB TIS
ADIP TIS
PSEUDOHYPERTROPHY
FOLLOWED EVENTUALLY
COMPENSATORY
HYPERTROPHY
CALF
DISTAL SITES
LAB
SPEC
HISTO
SeCK
MOST
COM
SEVERE
CHILDREN
NEC → FIBROFATTYTIS
HISTO
PROX M
INITIALLY
EXTREM
Ḟ
NEC INDIV
SIZE Ḟ
RANDOM VARIA°
BEGINS
WEAKNESS
PROXIM MM
EXTREMITIES
1 YAGE
TOTAL FAILURE
DYSTROPHIN SYNTHESIS
STOP CODONS
DNA CODING FRAMESHIFT
IN FAM
CT
MUT°
DELE°
SEGMENT GENE
VARIOUS
1/3 CASES
DENOVO MUT°
DEFICIENCY
DYSTROPHIN
IMMOBILIZA°
WASTING
M CONTRACTURE
WEAK MM RESP
PNEUMONIA
MO
EARLY TEENS
NL
SCH

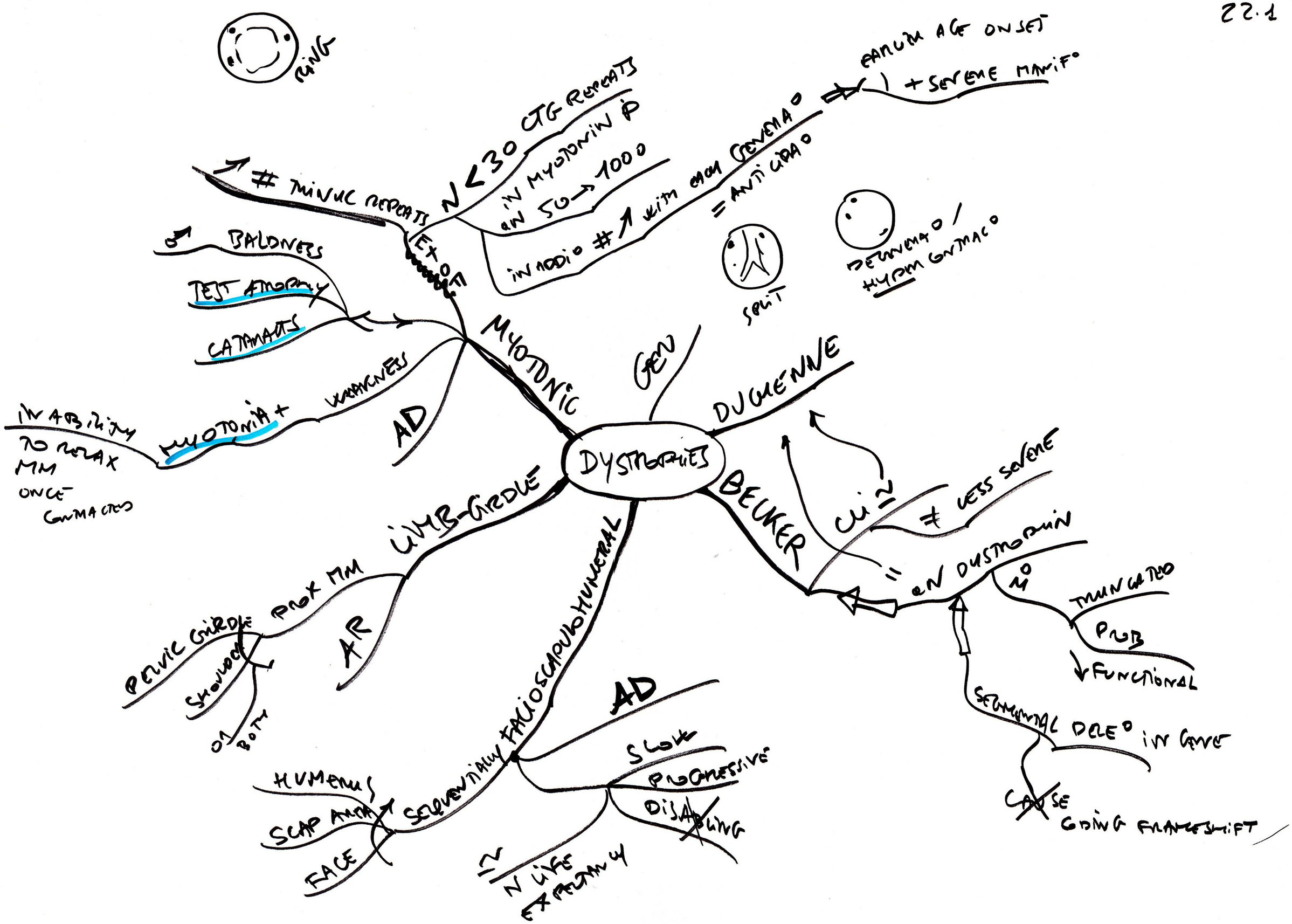
RING
MINUC REPEATS
N < 30 CTG REPEATS
IN MYOTONIN P
IN 50 → 1000
IN ADDIO # ↑ WITH EACH GENERA°
= ANTICIPA°
EARLIER AGE ONSET
+ SEVERE MANIF°
EXOF
BALDNESS
TEST ATROPHY
CATARACTS
SPLIT
DEGENERA° / HYPERCONTRAC°
MYOTONIC
GEN
DUCHENNE
AD
MYOTONIA +
WEAKNESS
INABILITY TO RELAX MM ONCE CONTRACTED
DYSTROPHIES
BECKER
CLI ≈
≠ LESS SEVERE
= ON DYSTROPHIN
M°
TRUNCATED
PROB
FUNCTIONAL
SEGMENTAL DELE° IN GENE
CAUSE CODING FRAMESHIFT
LIMB-GIRDLE
PROX MM
AR
PELVIC GIRDLE
SHOULDER
01 BOTH
SEQUENTIALLY FACIOSCAPULOHUMERAL
AD
SLOW
PROGRESSIVE
DISABLING
HUMERUS
SCAP AREA
FACE
≈ N LIFE EXPECTANCY

NMJ

AUTO ACH R

NL

SCM

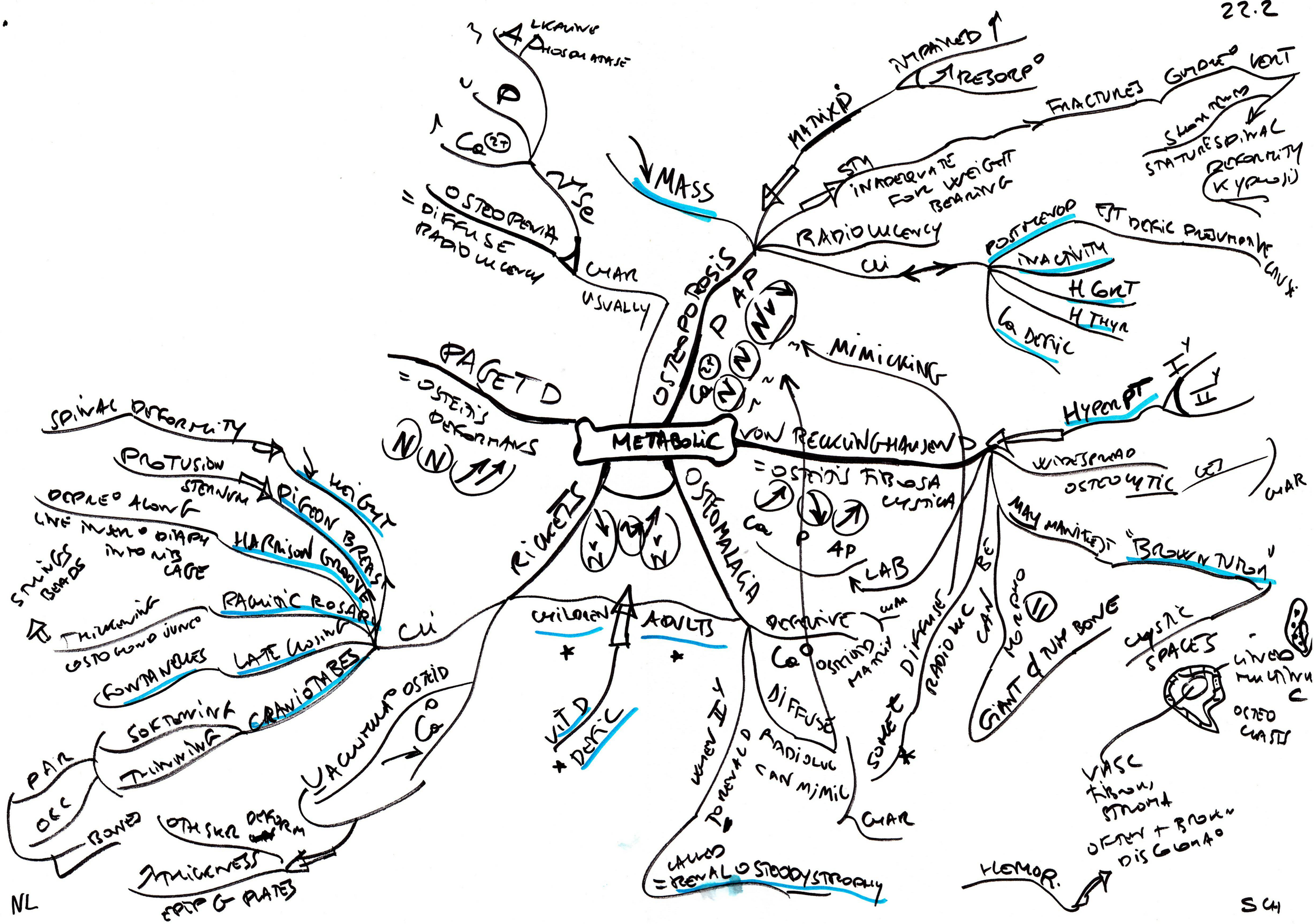
METABOLIC
OSTEOPOROSIS
MASS
MATRIX
IMPAIRED
RESORP
FRACTURES
GUMPRE
VERT
SHORTENED
STATURE
SPINAL DEFORMITY
KYPHOSIS
STM
INADEQUATE FOR WEIGHT BEARING
RADIOLUCENCY
CLI
POSTMENOP
EST DEFIC PRESUMPTIVE CAUSE
INACTIVITY
H CORT
H THYR
Ca DEFIC
MIMICKING
HYPERPT
WIDESPREAD
OSTEOLYTIC
CLI
CHAR
MAY MANIFEST
"BROWN TUMOR"
CYSTIC SPACES
LINED MULTINUC
OSTEO CLASTS
VASC FIBROUS STROMA
OFTEN + BROWN DISCOLORAO
HEMOR.
VON RECKLINGHAUSEN
= OSTEITIS FIBROSA CYSTICA
Ca
P
AP
LAB
OSTEOMALACIA
DEFECTIVE
CHAR
OSTEOID MATRIX
DIFFUSE
RADIOLUC
CAN MIMIC
CHAR
SOMET
DIFFUSE
RADIOLUC
CAN
BE
MORPHO
GIANT & TUM BONE
CALLED
= RENAL OSTEODYSTROPHY
WHEN II
TO RENAL D
RICKETS
CHILDREN
ADULTS
VIT D
DEFIC
OSTEOPENIA
= DIFFUSE RADIOLUCENCY
CHAR
USUALLY
PAGET D
= OSTEITIS DEFORMANS
SPINAL DEFORMITY
HEIGHT
PROTUSION
STERNUM
PIGEON BREAST
DEPRE ALONG
LINE INSER DIAPH INTO RIB CAGE
HARRISON GROOVE
STRINGS BEADS
RACHITIC ROSARY
THICKENING
COSTOCOND JUNC
LATE CLOSING
FONTANELLES
CRANIOTABES
SOFTENING
THINNING
PAR
OCC
BONES
VACUUMULATO OSTEID
Ca
OTH SKEL DEFORM
THICKNESS
EPIPG PLATES
NL
SCH

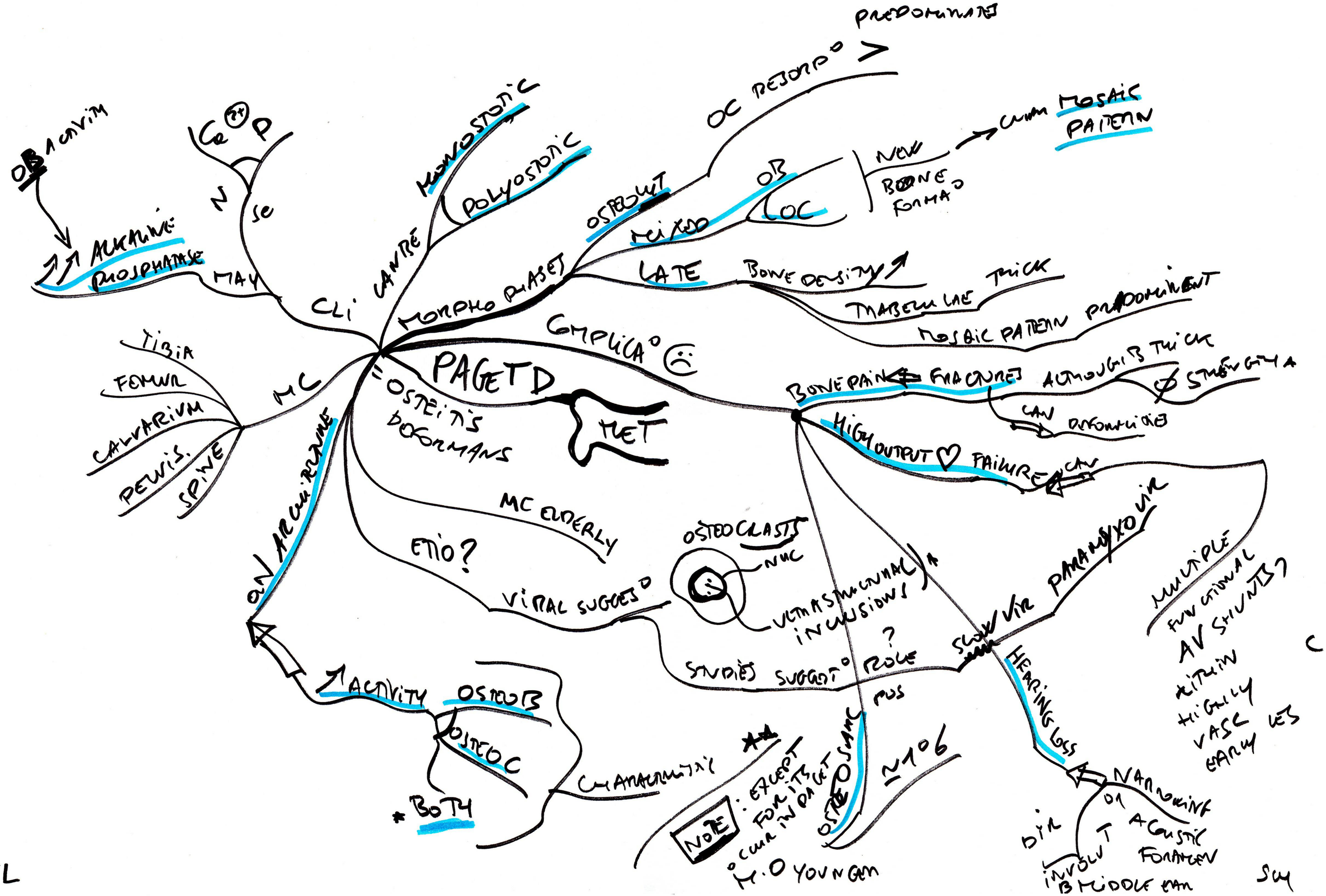
PAGET D
MET
OSTEITIS DEFORMANS
MORPHO PHASES
OSTEOLYT
MIXED
OB
OC
NEW BONE FORMAT°
CLIM MOSAIC PATTERN
OC RESORP° > PREDOMINATES
LATE
BONE DENSITY ↗
TRABECULAE THICK
MOSAIC PATTERN PREDOMINENT
COMPLICA° ☹
BONE PAIN ⇐ FRACTURES
ALTHOUGH B THICK
Ø STRENGTH A
CAN DEFORMITIES
HIGH OUTPUT ♡ FAILURE
CAN
MC ELDERLY
ETIO?
VIRAL SUGGES°
OSTEOCLASTS
NUC
ULTRASTRUCTURAL INCLUSIONS
STUDIES SUGGEST° ROLE ?
SLOW VIR
PARAMYXOVIR
MULTIPLE FUNCTIONAL AV SHUNTS?
LITHIN
HIGHLY
VASC
EARLY LES
HEARING LOSS
NARROWING
OR
ACOUSTIC FORAMEN
DIR
INVOLVT
B MIDDLE EAR
OSTEOSARC
POS
≈1°6
NOTE: EXCEPT FOR ITS OCCUR IN PAGET
M.O YOUNGER
CHARACTERISTIC
ACTIVITY
OSTEOB
OSTEOC
* BOTH
ON ARCHITECTURE
MC
TIBIA
FEMUR
CALVARIUM
PELVIS.
SPINE
CLI
LANBE
MONOSTOTIC
POLYOSTOTIC
Ca 2+
P
N
Se
MAY
OB ACTIVITY
ALKALINE PHOSPHATASE
NL
SM

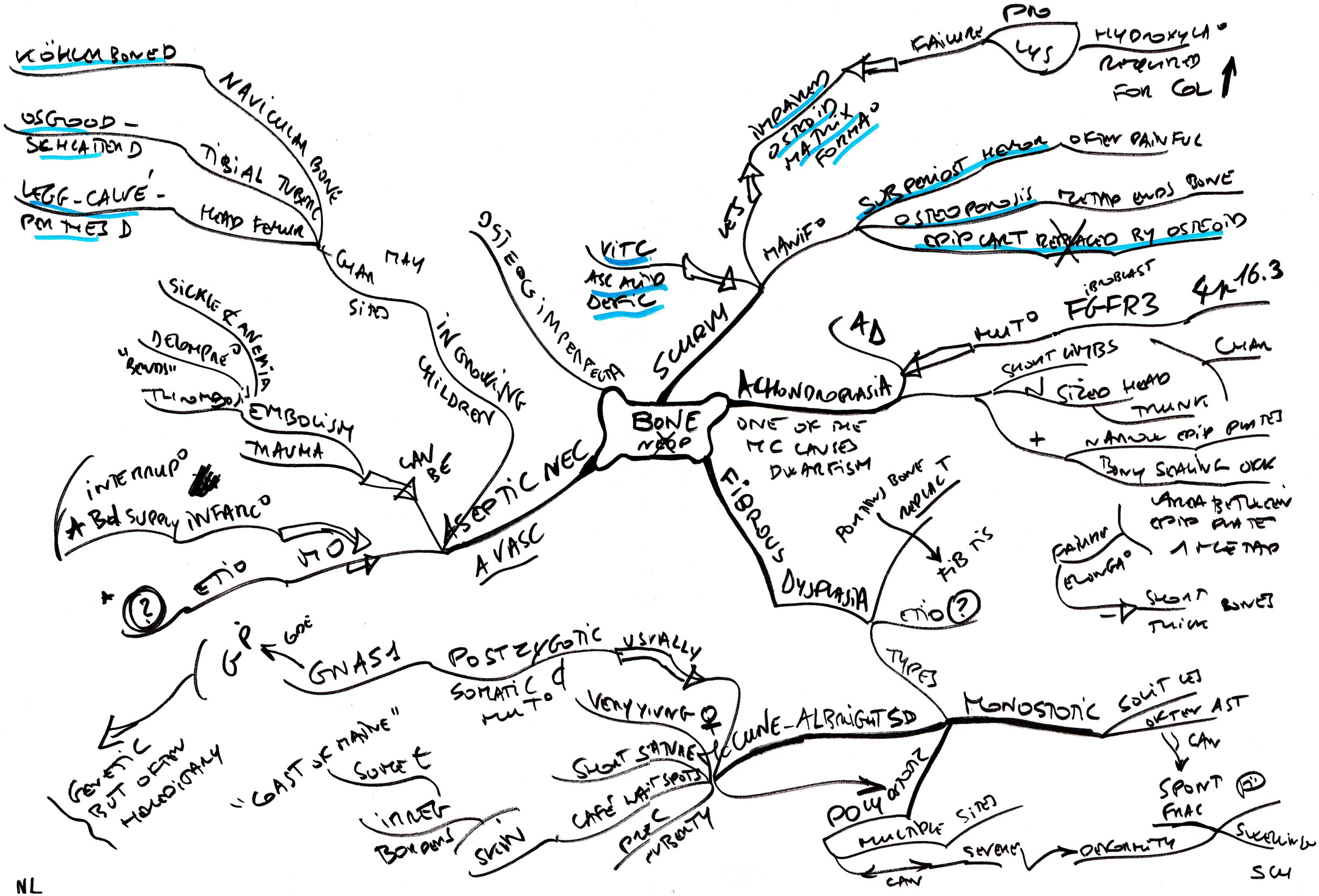
BONE
NEOP
ASEPTIC NEC
AVASC
KÖHLER BONED
NAVICULAR BONE
OSGOOD - SCHLATTER D
TIBIAL TUBERC
LEGG-CALVÉ - PERTHES D
HEAD FEMUR
CHAR
MAY
SITES
IN GROWING CHILDREN
SICKLE & ANEMIA
DELOMPRÉ
"BENDS"
THROMBOSIS
EMBOLISM
TRAUMA
CAN BE
INTERRUP
A Bd SUPPLY INFARC
ETIO
MO
?
OSTEOG IMPERFECTA
SCURVY
VITC
ASC ACID DEFIC
LES
IMPAIRED OSTEOID MATRIX FORMA
FAILURE
PRO
LYS
HYDROXYLA
REQUIRED FOR COL
MANIF
SUBPERIOST HEMOR
OFTEN PAINFUL
OSTEOPOROSIS
METAP ENDS BONE
EPIP CART REPLACED BY OSTEOID
ACHONDROPLASIA
AD
MUT
FGFR3
4p16.3
SHORT LIMBS
SIZED HEAD
TRUNK
CHAR
+
NARROW EPIP PLATES
BONY SEALING OCK
AREA BETWEEN EPIP PLATE & METAP
FAILURE ELONGA
SHORT THICK BONES
ONE OF THE MC CAUSES DWARFISM
FIBROUS DYSPLASIA
PORTIONS BONE REPLACT
FIB TIS
ETIO
?
TYPES
MONOSTOTIC
SOLIT LES
OFTEN AST
CAN
SPONT FRAC
SWELLING
SCH
POLYOSTOTIC
MULTIPLE SITES
SEVERE
CAN
DEFORMITY
MCCUNE-ALBRIGHT SD
VERY YOUNG ♀
SHORT STATURE
CAFÉ WAIT SPOTS
PREC PUBERTY
SKIN
IRREG BORDERS
SOME ♂
"COAST OF MAINE"
POSTZYGOTIC
SOMATIC ♂ MUT
USUALLY
GNAS1
GP
GDE
GENETIC BUT OFTEN HEREDITARY

NL

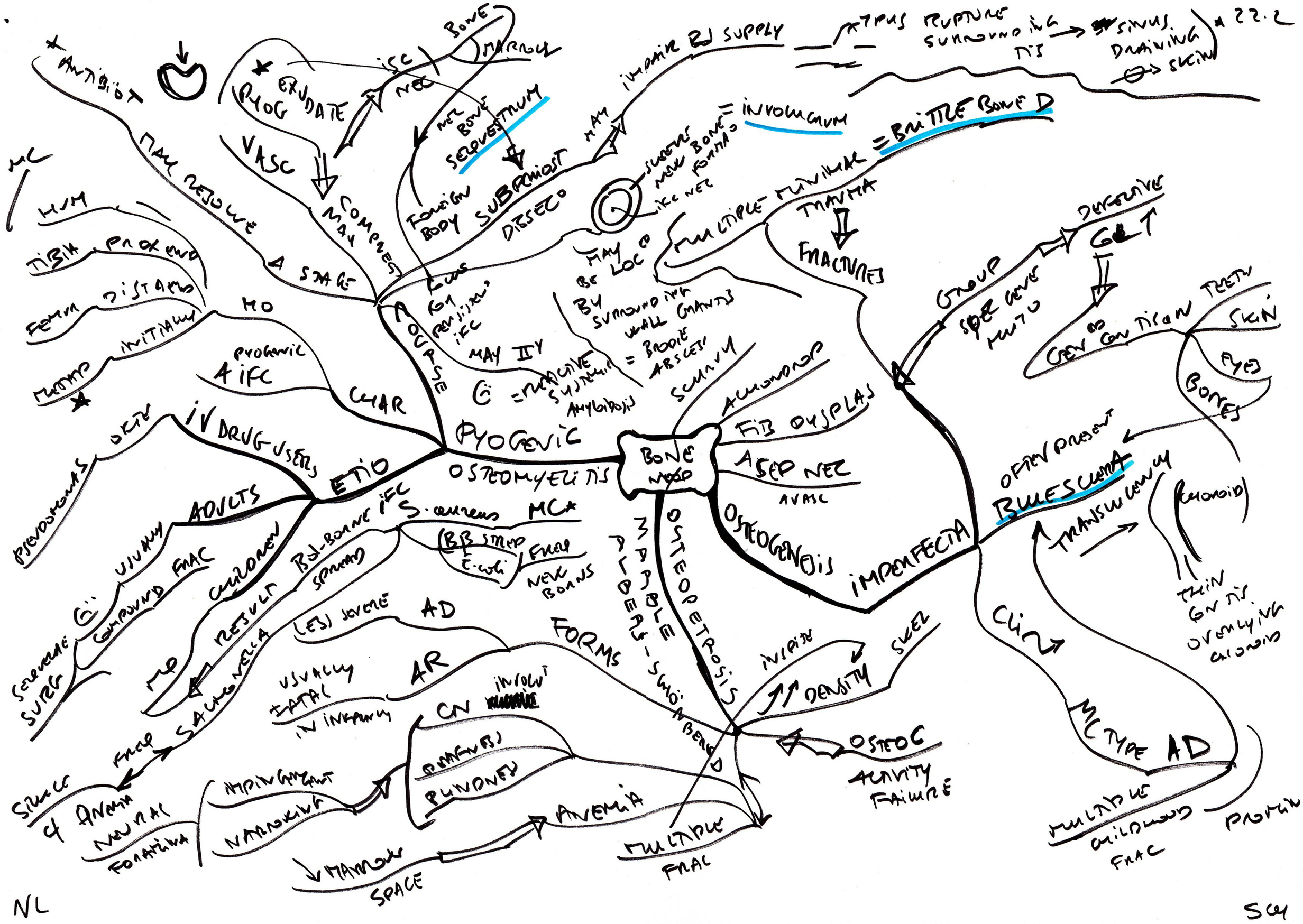

ANTIBIOT
MAY RESOLVE A STAGE
MC
HUM
TIBIA PROXEND
FEMUR DISTAEND
METAP INITIALLY
PYOGENIC
A IFC
CHAR
HO
PYOGENIC
OSTEOMYELITIS
ETIO
IV DRUG USERS
PSEUDOMONAS
OKTE
ADULTS
USUALLY
COMPOUND FRAC
SEQUELAE SURG
CHILDREN
MP
RESULT
SALMONELLA
BOL-BORNE IFC
SPREAD
S. aureus
MC
BB STREP
E. coli
FREQ
NEW BORNS
(ES) SEVERE
AD
FORMS
USUALLY FATAL
AR
IN INFANCY
CN
INVOLVT
DEAFNESS
BLINDNESS
SILICE
4 ANEMIA
NEURAL
FORAMINA
IMPINGEMENT
NARROWING
MARROW SPACE
ANEMIA
MULTIPLE FRAC
MARBLE
ALBERS-SCHÖNBERG
OSTEOPETROSIS
INSPITE
DENSITY
SKEL
OSTEOC
ACTIVITY FAILURE
BONE NEOP
SCURVY
ACHONDROP
FIB DYSPLAS
ASEP NEC
AVASC
OSTEOGENESIS
IMPERFECTA
BLUESCLERA
OFTEN PRESENT
TRANSLUCENCY
CHOROID
THIN CONTIS OVERLYING CHOROID
CLIN
MC TYPE AD
MULTIPLE CHILDHOOD FRAC
PROMIN
GROUP
SPEC GENE MUTO
DEFECTIVE
GLT
GEN ED CONTISON
TEETH
SKIN
EYES
BONES
MULTIPLE MINIMAL
TRAUMA
FRACTURES
= BRITTLE BONE D
= INVOLUCRUM
SLEEVE NEW BONE FORMAT
IFC NEC
MAY BE LOC ED BY SURROUNDING WALL GRANTS
= BRODIE ABSCESS
MAY IMPAIR BJ SUPPLY
SUBPERIOST
DISSECO
FOREIGN BODY
NEC BONE SEQUESTRUM
IFC NEC
BONE MARROW
EXUDATE
PYOG
VASC
COMPRESS MAY
ISC NEC
MAY IIY
= REACTIVE SYSTEMIC AMYLOIDOSIS
TYPUS RUPTURE SURROUNDING TIS
SINUS DRAINING
SKIN
22.2
NL
SCH

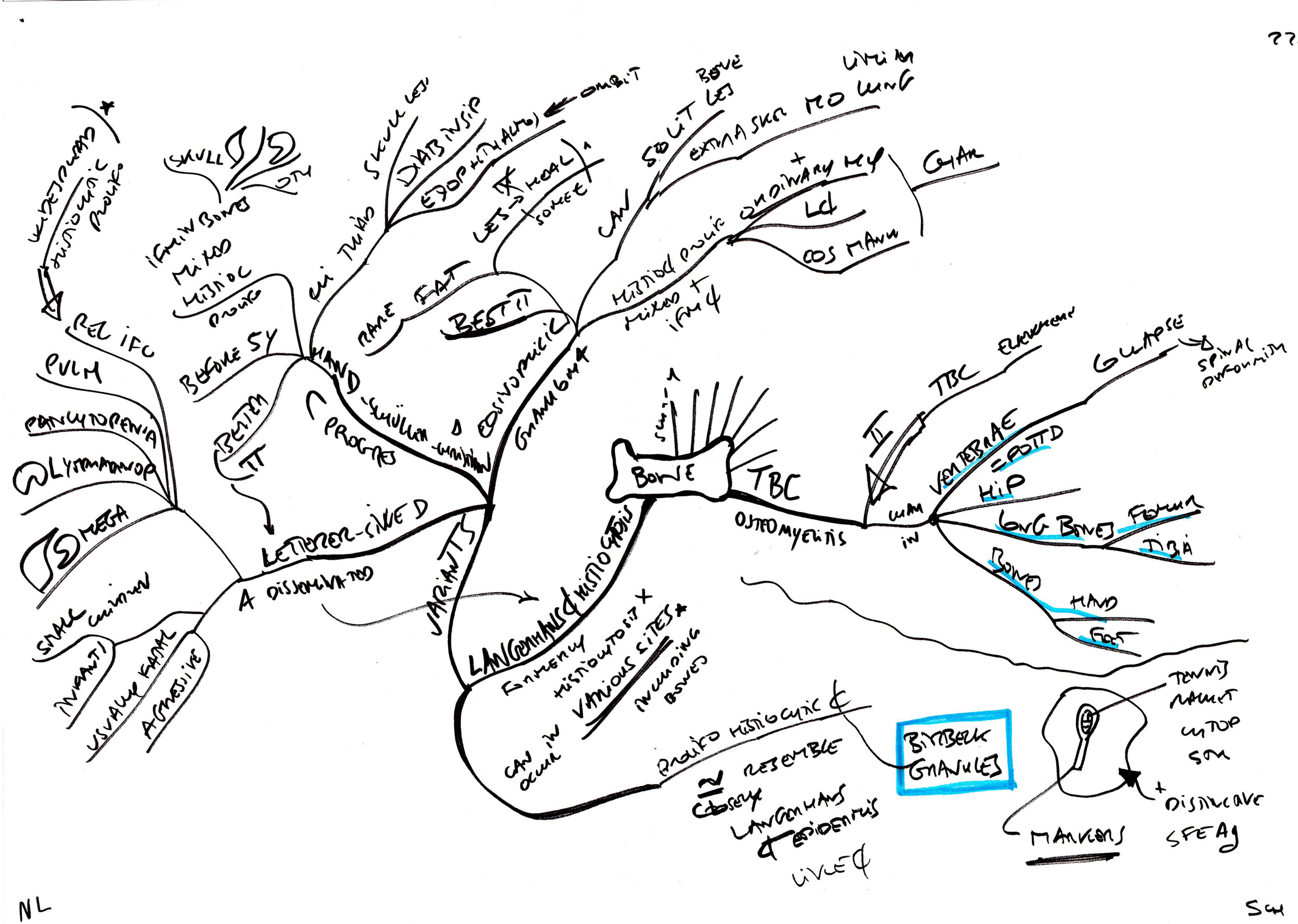

SKULL
OTH
IFMIN BONES
MIXED
HISTIOC
PROLIFO
REC IFC
PULM
PANCYTOPENIA
LYMPHADENOP
MEGA
SMALL CHILDREN
INFANTS
USUALLY FATAL
AGRESSIVE
BEFORE 5Y
BETTER
TT
LETTERER-SIWE D
A DISSEMINATED
HAND-SCHÜLLER-CHRISTIAN
PROGRES
CLI TRIAD
SKULL LES
DIAB INSIP
EXOPHTHALMOS
OMBIT
LES → HEAL
SOME E
RARE FAT
BEST TT
EOSINOPHILIC
GRANULOM
CAN
SOLIT LES
BONE
EXTRASKER MO LUNG
LIMIN
HISTIOC PROLIF
MIXED + IFM
ORDINARY MY
LC
COS MANU
CHAR
VARIANTS
LANGERHANS HISTIOCYTOSIS
FORMERLY HISTIOCYTOSIS X
VARIOUS SITES
INCLUDING BONES
CAN OCCUR IN
PROLIFO HISTIOCYTIC
RESEMBLE
CLOSELY
LANGERHANS
EPIDERMIS
LIVE
BIRBECK GRANULES
BONE
TBC
OSTEOMYELITIS
II
TBC
ELEKHERN
COLLAPSE
SPINAL DEFORMITY
VERTEBRAE
= POTTD
HIP
LONG BONES
FEMUR
TIBIA
BONES
HAND
FEET
TENNIS RACKET
CYTOP
STR
+ DISTINCTIVE
SFE Ag
MARKERS

BONE TUMORS

BEN

- ABC
  - EPIP END LONG
  - > 50% AROUND KNEE
  - LOWER END FEM > UPPER END TIB
  - LOC = AGGRESSIVE OSTEOLYTIC RECURR COMMON
  - DIA METAPHYSIS EPI
  - LONG LOWER END FEMUR / UPPER END TIBIA / FAVORITE LOC
  - NONOSSIFYING FIBROMA
  - "SOAP BUBBLE" RADIO
  - ABC ONE YST
  - II Y
  - MAY
  - BEN PROCESS ↓ SOLA O OR ↔ OTH TUM
  - FOR MAG
  - SOMEWHAT ♀ > ♂
  - 20-60 Y
  - SURG CURE I° OCCULT TUM
  - FOLLOWED
  - DVPT OSTEOSARC ?
  - RESPONDED WELL SW
  - Y 13
- HAMARTOMA
  - MAYBE
  - ♂ < 25 Y
  - CAP CART PROJECTING FROM SFE
  - CART-CAPPED SUBARTICULAR BONY PROJECT FROM GIANT SFE
- OSTEOCHONDROMA
  - MC BEN
  - EXOSTOSIS
  - POST FUSE
  - ENCHONDROMA
    - IN HAND
    - FIB STROMA
    - MULTIPLE GIANT ¢
    - IN LONG TUB
    - SPINDLE
    - MONOSTOTIC OVAL
    - MORE HER VARIANT MULTIPLES
    - MULT FAM OSTEOCHONDROMATOSIS
  - CHONDROSARC
    - RARE → PEAL + FUSE
    - RARE
- OSTEOMA
  - OSTEOID OSTEOMA
    - INTRAMED / HAMMY FEETS / SPINAL AGE SCOLIOSIS
    - DENSE ♂ MATURE
    - OSTEOMYELITIS / NEAR END DIAP FEM TIB ♂ < 25
    - SKULL + FACIAL OFTEN PROTRUDES INTO PARANAS SIN ♂
    - WITHIN MEDULLA
  - OSTEOBLASTOMA

BONE TUMORS

- FIBROUS DYSPLASIA
  - MONO
  - POLY
  - JUVENILE
  - LONG
  - ♂ < 25
  - PROX FEMUR TIB
  - AROUND KNEE
  - NOT DIS PROX FEM
  - PREFERRED SITES
  - USUALLY ENDOST
  - OSTEOID OSTEOMA ++
  - NOT OBVIOUS
  - VARIANTS
    - OSTEOBLASTIC
    - CHONDROBLASTIC
    - CART MATRIX
    - MAY RESEMBLE SCLEROSING BONY DIS
    - VIRTUALLY ALWAYS SEEN IN PEDIAT
    - MM = MULTIPLE MYELOMA SCH
    - VITAL CART-FORMING
    - CHILDREN INVARIABLY
    - REPRESENT RATHER THAN GROWTH
    - HISTO
    - FIBROBLASTIC
    - MAY EASILY MISDIAGNOSE FOR MALIGN PROCESS
    - A VICE VERSA
- OSTEOSARC
  - MC I Y MAL
  - ♂ 10-20 Y
  - METS GA MM
  - MORE COMMON THAN I Y MAL
  - PREDISPF
    - PAGET'D
    - FIBROUS DYSPLASIA
    - CHONDROMA
    - OSTEOCHONDROMA
    - IR
    - BONE INFARCTS
    - FAM RETINOBLASTOMA
  - LIFTING PERIOST BY EXPAND TUM
    - 2X → 3X
    - ALK@PHOS
    - CLI
    - OCCAS FNAC
    - PAIN SUGGESTIVE
    - SPICULATED "SUNBURST" PAT G
    - ARTOM RATIO
    - CODMAN TRIANGLE
    - GIAN RADIO
    - SPIEGEL LYEN LUNGS
    - MEMAT
    - SPRAD
    - EARLY
- EWINGSARC MAL

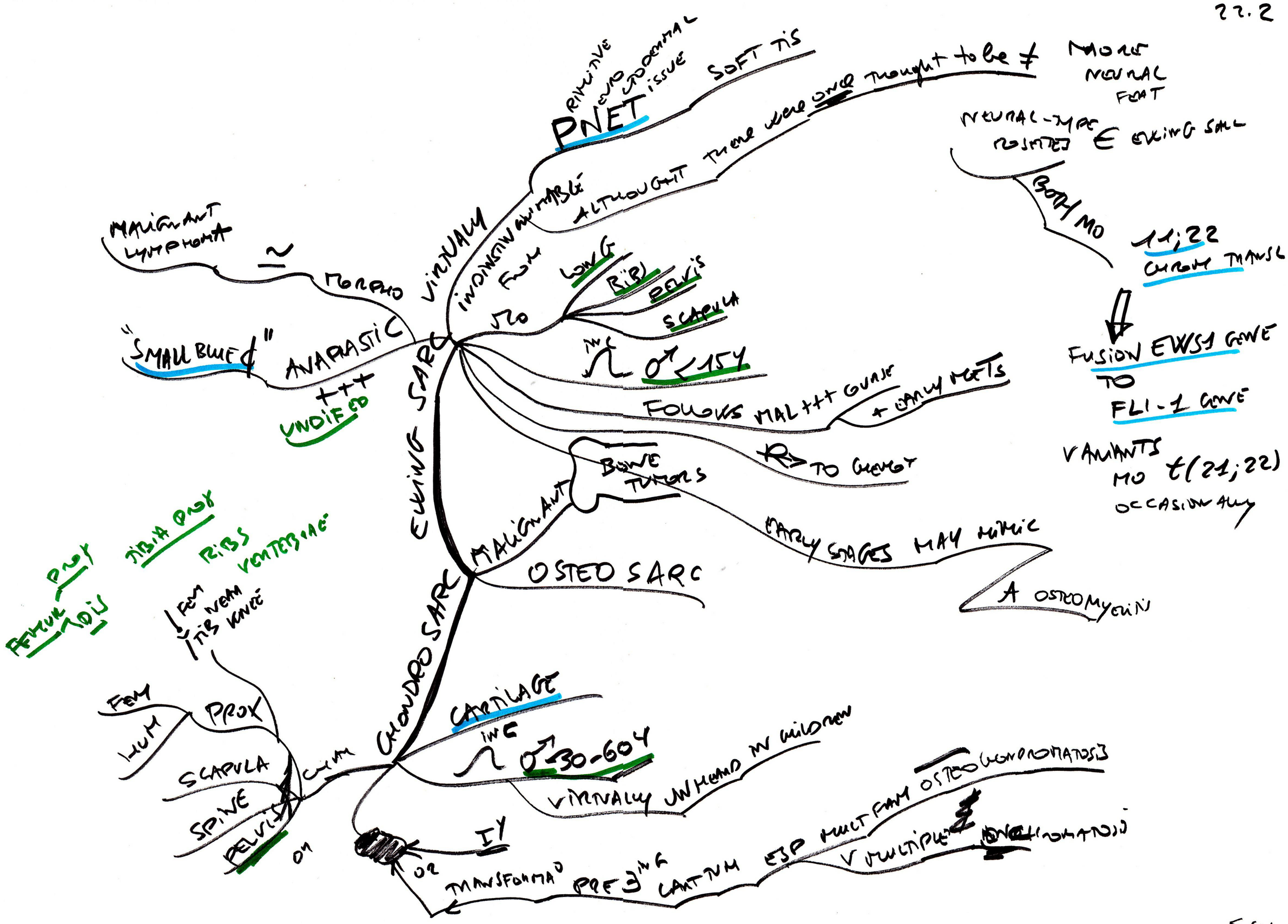
PNET
PRIMITIVE
EURO
CTODERMAL
ISSUE
SOFT TIS
ALTHOUGHT THERE WERE ONCE THOUGHT TO BE ≠
MORE NEURAL FEAT
NEURAL-TYPE ROSETTES ∈ EWING SALL
BOTH MO
11;22
CHROM TRANSL
FUSION EWS1 GENE TO FLI-1 GENE
VARIANTS MO t(21;22) OCCASIONALLY
VIRTUALLY INDISTINGUISHABLE FROM
MALIGNANT LYMPHOMA
≃
MORPHO
"SMALL BLUE ¢"
ANAPLASTIC
+++
UNDIFED
MO
LONG
RIBS
PELVIS
SCAPULA
INC
♂ < 15Y
FOLLOWS MAL +++ COURSE
+ EARLY METS
R> TO CHEMOT
EWING SARC
BONE TUMORS
MALIGNANT
OSTEO SARC
EARLY STAGES MAY MIMIC
A OSTEOMYELITIS
PROX
TIBIA PROX
RIBS
VERTEBRAE
FEMUR
DIS
FEM
TIB
NEAR KNEE
CHONDRO SARC
CARTILAGE
INC
♂ 30-60Y
VIRTUALLY UNHEARD IN CHILDREN
FEM
HUM
PROX
SCAPULA
SPINE
PELVIS
CHAM
ON
IY
OR
TRANSFORMAO
PRE 3ING
CART TUM
ESP MULT FAM OSTEOCHONDROMATOSIS
V MULTIPLE
ENCHROMATOSIS

22.3

CYSTS
NO

SUBCHOND
BONE

OFTEN ANT CART

GRAN°TIS

EVENTUATE INTO NUMEROUS FIBRO LIKE KILLI

= PANNUS

SYNOV LINING

HYPERPLAS 1

THICKN

DEFINITIVE IRM LIC TENO BURSAE

SCARRING CONTRACTURE

SUBCUT + R NODULES

1/3 PATIENTS

ENTIR

GENET

INTERPLAY +

AUTOIMM

LIKELY

SYNOVITIS

20-50Y O♂/♀

SYNOV

Ci

PROGRE°

IFMY

INFILTRATE

AI REAC°

EARLY RA

EDEMA

+

DEFORMITY

BONE CART

PG

MORPHO

Ci COURSE

RA

VARIANTS

SE

RF HUMANIZED

USEFUL △

9/11 Ig M

M

= ANTI IgG FC SPECIFICITY

OFTEN ASSOC BY

ANOTHER MARKERS

RELENT 9/13 GREMY

ANTI-CCP

HIGH SPECIFIC

CHART++ SPECIFIC ★

⊕ve 70%

★EARLY RA

MO HLA-DR4 ⊕ve

EPISODIC

EXTRA ARTIC

PULM

NEURO

JOINT INVOLV

POLYART

SYMMETRIC

INTENSITY

MORNING STIFFNESS

FATIGUE MALAISE

ANOREXIA WEIGHT↓

FEV MYALGIA

SWELLING JOINTS

PROX INTERPHAL METACARPO PHAL

ULNAR DEVIA FINGERS

KNEES FEET HANDS

FREQ

SYNOVITIS LIGAMENTS

MINIMAL RADIAL DEVIA°

MAY OCCUR

WRIST

PERIC

PLEUR

ANEMIC CD

EXCESS

VASCULITIS

LYMPHOADENOP

SJÖGREN'S

FELTY SD

SPLENO +RA

NEUTROPENIA

RA

OMEGA

STILL D = JUVENILE

VACCINATIONS PREVENTED BY

OMEGA

GEN LYMPHADENOP

FEVER

ONSET ★

PROB AUTOIMM

NEGATIVE

SERONEGATIVE

= SPONDYLOARTHROPATHIES

GENET GMP YOUNG ♂

CHAR

ØRF

SACROILIITIS

PARTNERS

INC +++

HLA B27

ANKYLOSING SPONDYLITIS

ASYMETRIC

SACRO-ILIAC JOINT

SPINE

98%

STIFFENING

CAN

ANT is CONJUNC IS URETHRITIS

IFC (INTES)

WOMEN

REITER SD

10% PSORIATIC + IBD

TYP

PART is

ANK SPONDY

CROHN UC

IBD OVER

BOWEL FUSION = ANKYLOSIS

NL

SCH

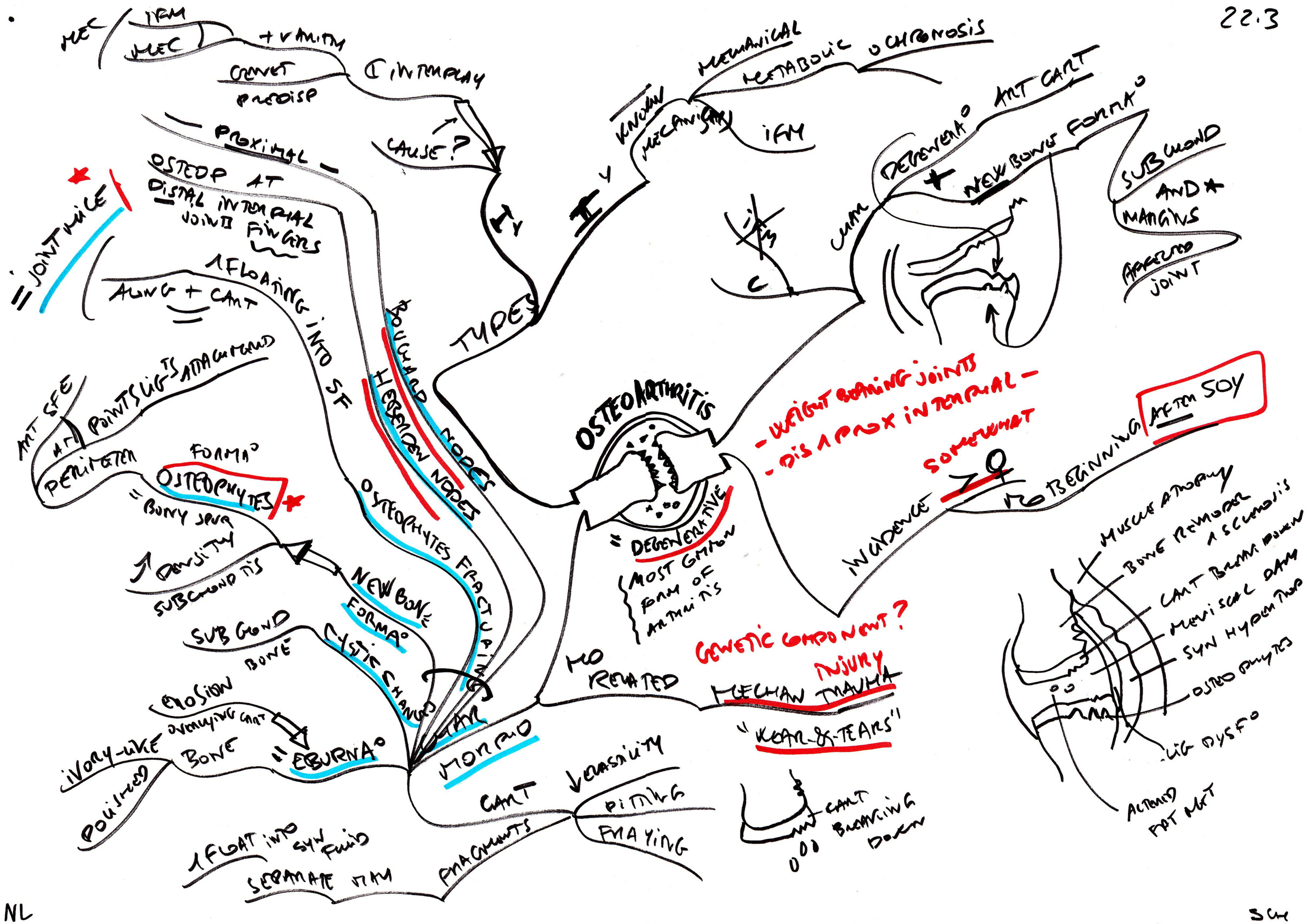
MEC
IFM
MEC
+ VARIETY
GENET
PREDISP
INTERPLAY
CAUSE?
PROXIMAL
OSTEOP AT
DISTAL INTERPHAL
JOINTS FINGERS
= JOINT MICE
FLOATING INTO SF
ALONG + CART
BOUCHARD NODES
HEBERDEN NODES
TYPES
I Y
II Y
KNOWN
MECHANICAL
METABOLIC
OCHRONOSIS
MECHANICAL
IFM
IFM
C
CHAR
DEGENERA°
ART CART
NEW BONE FORMA°
SUBCHOND
AND
MARGINS
AFFECTED
JOINT
OSTEOARTHRITIS
= DEGENERATIVE
MOST COMMON
FORM OF
ARTHRITIS
- WEIGHT BEARING JOINTS
- DIS 1 PROX INTERPHAL -
SOMEWHAT
INCIDENCE
MO BEGINNING
AFTER SOY
MUSCLE ATROPHY
BONE REMODEL
1 SCLEROSIS
CART BREAKDOWN
MENISCAL DAM
SYN HYPERTROP
OSTEOPHYTES
LIG DYSF°
ALTERED
FAT MET
GENETIC COMPONENT?
INJURY
MECHAN TRAUMA
"WEAR-&-TEARS"
MO
RELATED
CART
BREAKING
DOWN
ART SFE
AT
POINTS LIG'TS ATTACHMENT
PERIMETER
FORMA°
OSTEOPHYTES
= BONY SPUR
DENSITY
SUBCHONDTIS
NEW BONE
FORMA°
OSTEOPHYTES FRACTURING
SUB CHOND
BONE
CYSTIC CHANGES
EROSION
OVERLYING CART
IVORY-LIKE
BONE
= EBURNA°
POLISHED
CHAR
MORPHO
CART
ELASTICITY
PITTING
FRAYING
FRAGMENTS
FLOAT INTO SYN FLUID
SEPARATE MAY

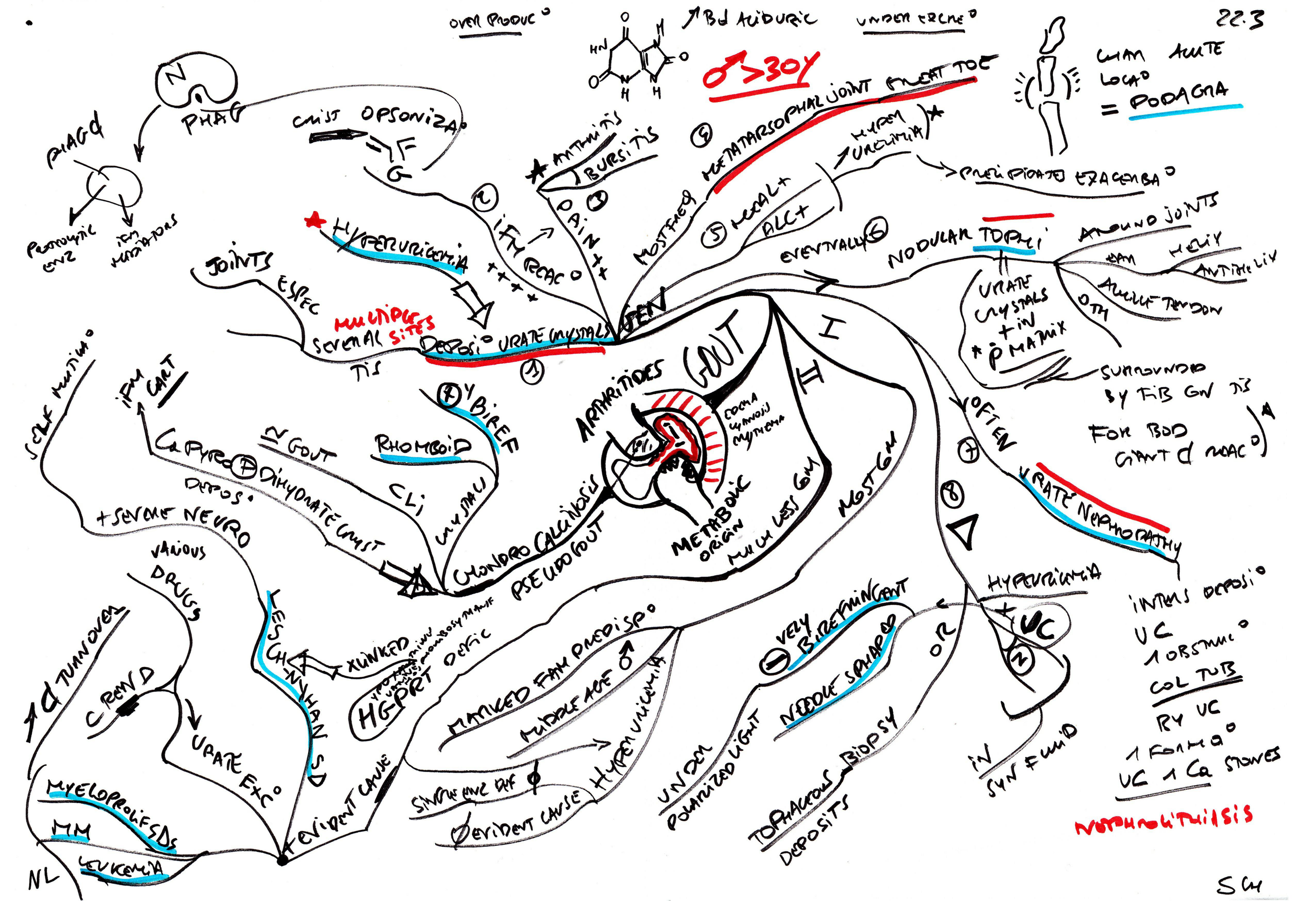
22.3
OVER PRODUC°
↗ Bd ACIDURIC
UNDER EXCRE°
♂ > 30Y
CHAR ACUTE LOCA°
= PODAGRA
PHAG
PHAG ¢
PROTEOLYTIC ENZ
IFM MEDIATORS
CRIST OPSONIZA°
F
G
ARTHRITIS
BURSITIS
PAIN ++
IFM REAC°
HYPERURICEMIA
MOST FREQ
METATARSOPHAL JOINT
GREAT TOE
HYPER URICEMIA
PRECIPITATES EXACERBA°
MEAL +
ALC +
EVENTUALLY
NODULAR TOPHI
AROUND JOINTS
EAR
HELIX
ANTIHELIX
ACHILLE TENDON
OTH
URATE CRYSTALS + IN * P MATRIX
SURROUNDED BY FIB GN TIS
FOR BOD GIANT ¢ REAC°
JOINTS
ESPEC
MULTIPLE SITES
SEVERAL TIS
DEPOSI° URATE CRYSTALS
SEN
GOUT
ARTHRITIDES
EDEMA CYANOSIS ERYTHEMA
METABOLIC ORIGIN
MUCH LESS COM
MOST COM
I
II
OFTEN
URATE NEPHROPATHY
INTERS DEPOSI°
UC
1 OBSTRUC°
COL TUB
BY UC
1 FORMA°
UC 1 Ca STONES
NEPHROLITHIASIS
HYPERURICEMIA
UC
IN SYN FLUID
OR
VELY BIREFRINGENT
NEEDLE SHAPED
TOPHACEOUS BIOPSY DEPOSITS
UNDER POLARIZED LIGHT
MARKED FAM PREDISP°
MIDDLE AGE ♂
HYPERURICEMIA
SINGLE ENZ DEF ∅
∅ EVIDENT CAUSE
EVIDENT CAUSE
HGPRT DEFIC
XLINKED
LESCH-NYHAN SD
VARIOUS DRUGS
CREND
URATE EXC°
MYELOPROLIF SDs
MM
LEUKEMIA
NL
SELF MUTILA°
IFM CART
CAPYRO DIHYDRATE CRYST
DEPOS°
+ SEVERE NEURO
GOUT
RHOMBOID
CLI
CRYSTALS
BIREF
CHONDRO CALCINOSIS
PSEUDOGOUT
SCH

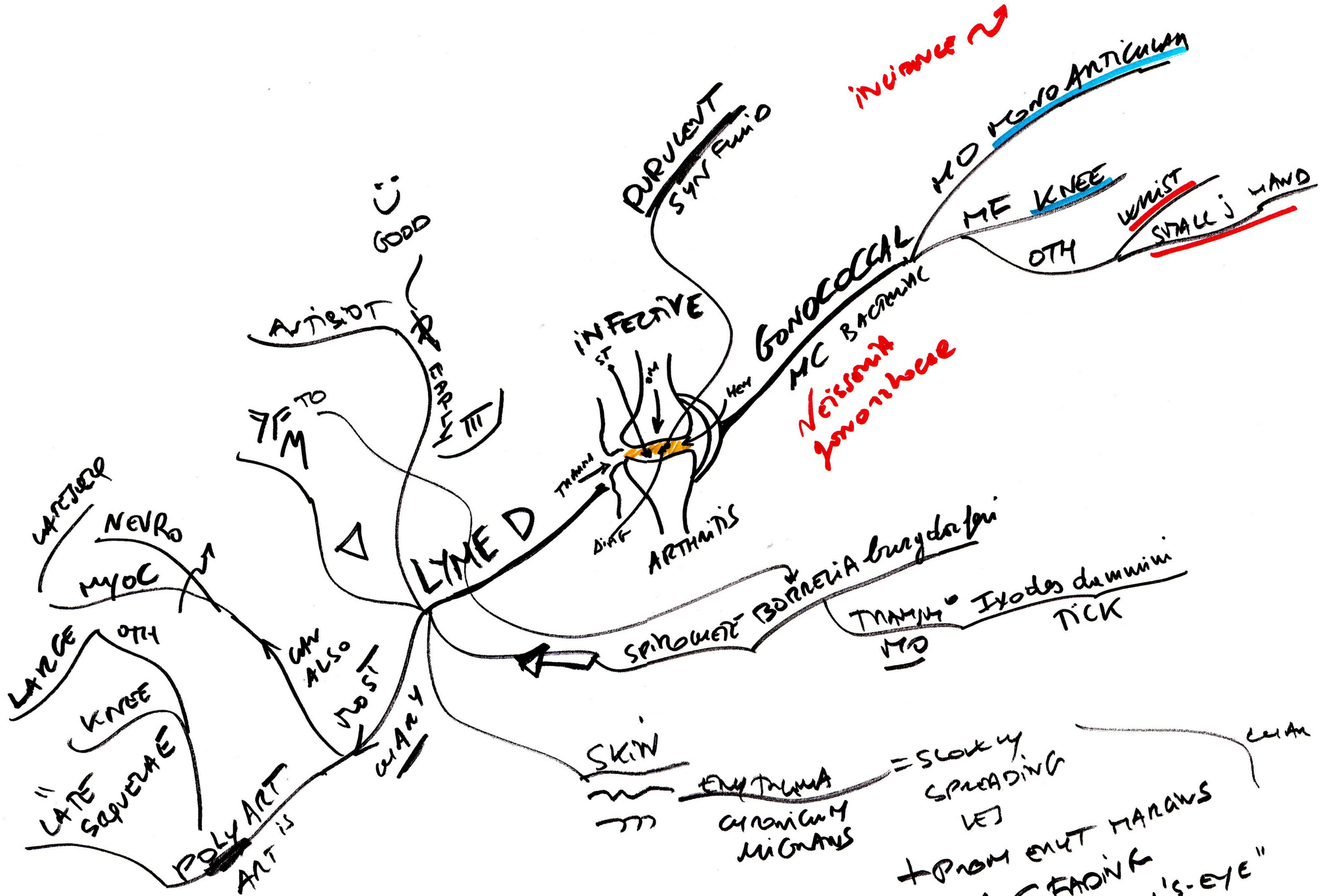

INCIDENCE
PURULENT
SYN FLUID
MO MONO ARTICULAR
MF KNEE
OTH
WRIST
SMALL J HAND
GONOCOCCAL
MC BACTERIAL
Neisseria gonorrhoeae
INFECTIVE
ST
OM
HEM
THAMM
DIAG
ARTHRITIS
GOOD
ANTIBIOT
EARLY
III
TO
M
LYME D
LATE SEQ
NEVRO
MYOC
LARGE
OTH
KNEE
"LATE SEQUELAE
CAN ALSO
MOST
MARY
POLY ART
ART IS
SPIROCHETE BORRELIA burgdorferi
TRAMM
MO
Ixodes dammini
TICK
SKIN
ERYTHEMA
CHRONICUM MIGRANS
= SLOWLY SPREADING LES
+ PROM ERYT MARGINS
1 G FADING
"BULL'S-EYE"
CHAR

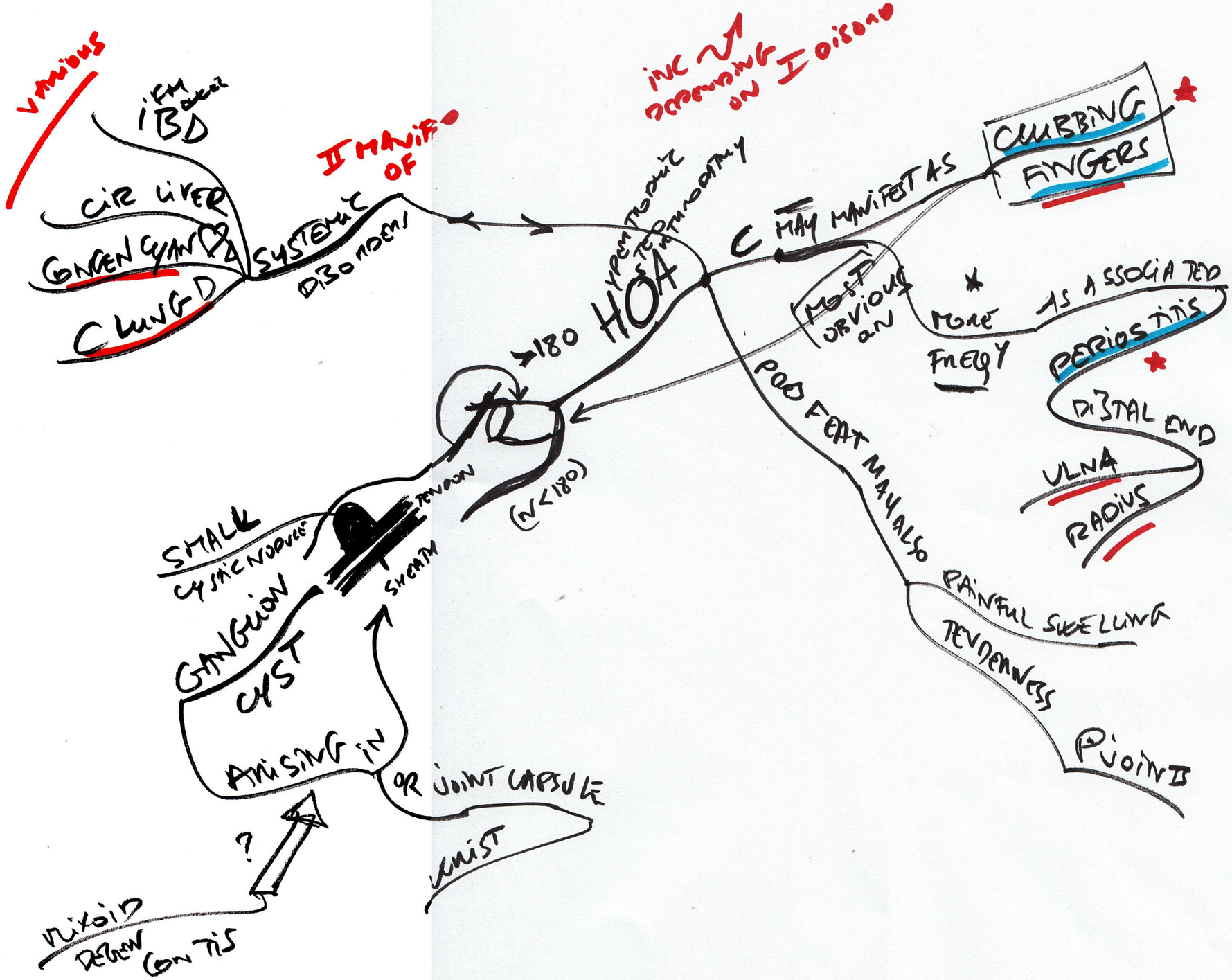
VARIOUS
IBD
CIR LIVER
CONGEN CYAN
CLUNG D
SYSTEMIC DISORDERS
II MANIFO OF
INC DEPENDING ON I DISORD
HOA
>180
(N<180)
C MAY MANIFEST AS
CLUBBING FINGERS
MOST OBVIOUS ON
MORE FREQY
AS ASSOCIATED
PERIOSTITIS
DISTAL END
ULNA
RADIUS
POD FEAT MAY ALSO
PAINFUL SWELLING
TENDERNESS
P JOINTS
SMALL
CYSTIC NODULE
TENDON
SHEATH
GANGLION
CYST
ARISING IN
OR JOINT CAPSULE
CHRIST
?
MIXOID
DEGEN CONTIS

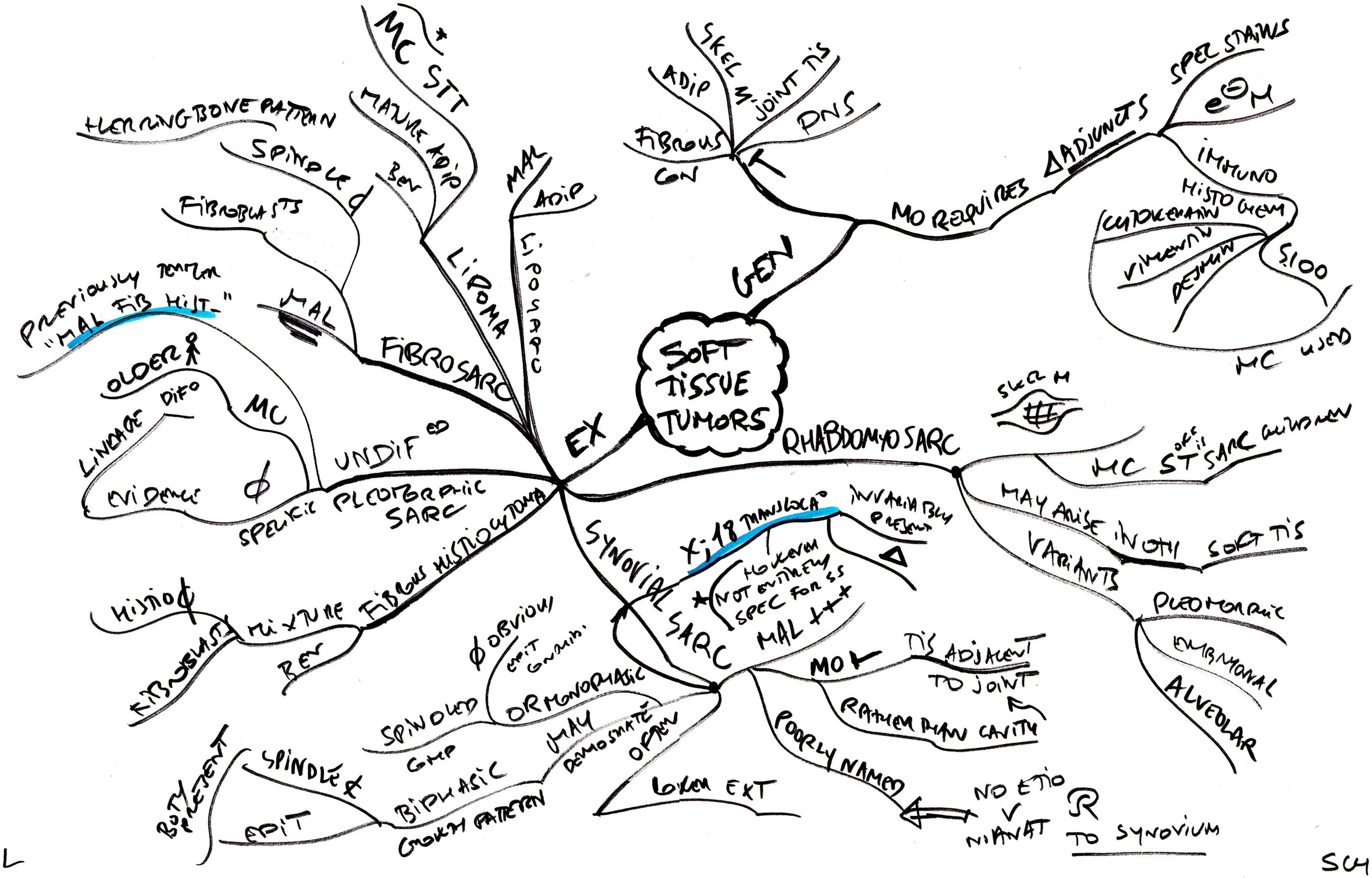
SOFT TISSUE TUMORS
GEN
EX
MO REQUIRES ΔADJUNCTS
SPEC STAINS
e⊖M
IMMUNO
HISTOCHEM
CYTOKERATIN
VIMENTIN
DESMIN
S100
MC USED
FIBROUS CON
ADIP
SKEL M
JOINT TIS
PNS
RHABDOMYOSARC
SKEL M
MC ST OFF IS SARC CHILDREN
MAY ARISE IN OTH SOFT TIS
VARIANTS
PLEOMORPHIC
EMBRYONAL
ALVEOLAR
SYNOVIAL SARC
X;18 TRANSLOCA°
INVARIABLY PRESENT
Δ
HOWEVER NOT ENTIRELY SPEC FOR SS
MAL +++
MO
TIS ADJACENT TO JOINT
RATHER THAN CAVITY
POORLY NAMED
NO ETIO
V
NIANAT
R
TO SYNOVIUM
LOKER EXT
MAY DEMOSTRATE
OFTEN
BIPHASIC
GROWTH PATTERN
SPINDLE
EPIT
BOTY PRESENT
SPINDLED
GMP
OR MONOPHASIC
ϕ OBVIOUS
EPIT
GNMIN
FIBROUS HISTIOCYTOMA
BEN
MIXTURE
FIBROBLASTS
HISTIO ϕ
FIBROSARC
MAL
PREVIOUSLY TERMED "MAL FIB HIST."
UNDIF^ED
PLEOMORPHIC SARC
SPECIFIC
ϕ
EVIDENCE
LINEAGE
DIFO
OLDER
MC
FIBROBLASTS
SPINDLE ϕ
HERRINGBONE PATTERN
LIPOMA
BEN
MATURE ADIP
MC STT
MAL
ADIP
LIPOSARC

NL

SCH