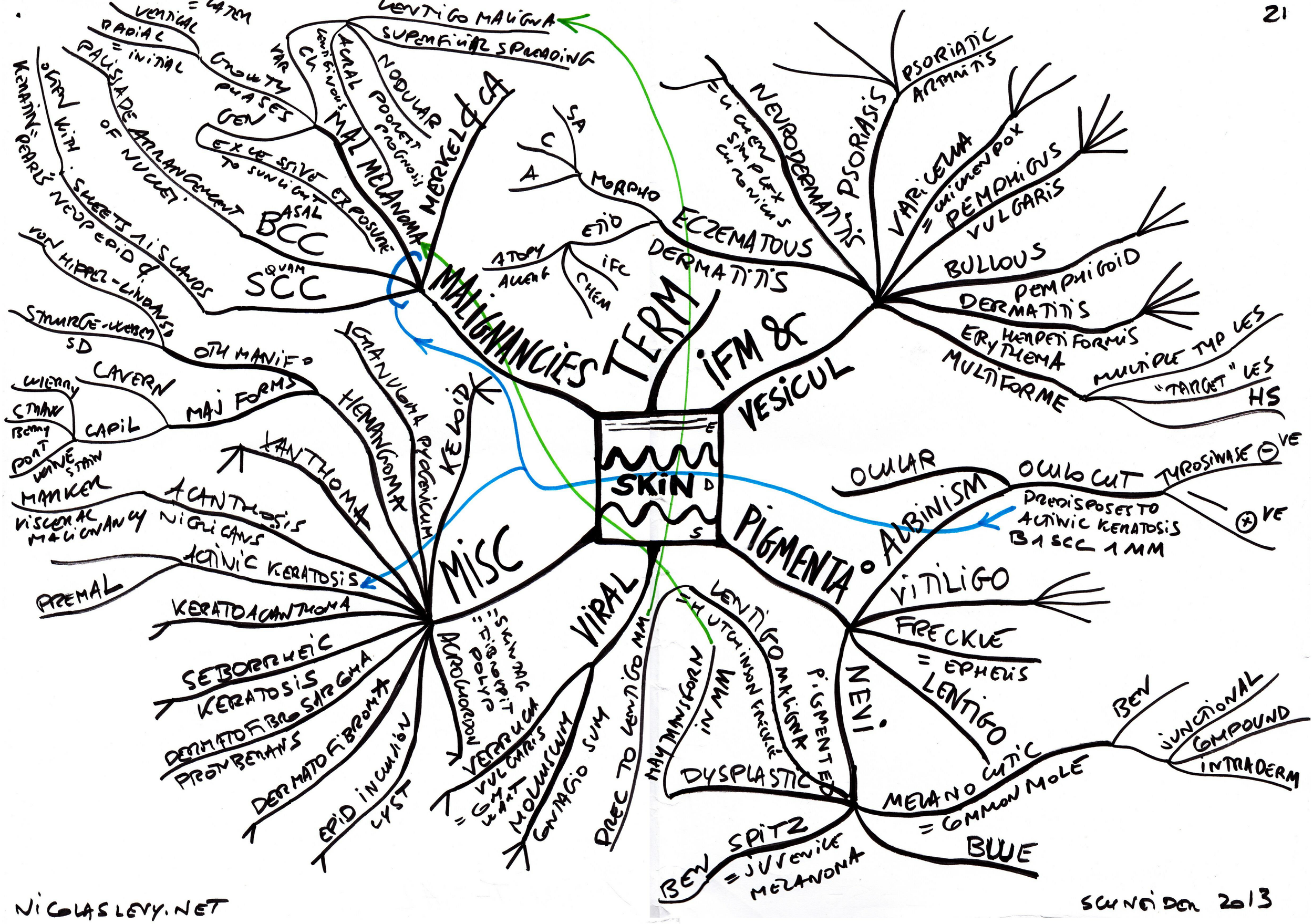
SKIN
MALIGNANCIES
TERM
MAL MELANOMA
MERKEL CA
LENTIGO MALIGNA
SUPERFICIAL SPREADING
NODULAR
ACRAL
VERTICAL = LATER
RADIAL = INITIAL
GROWTH PHASES
PALISADE ARRANGEMENT OF NUCLEI
SKIN WITH KERATIN PEARLS
SHEETS AISLANDS
EXCESSIVE EXPOSURE TO SUNLIGHT
BASAL BCC
SQUAM SCC
VON HIPPEL-LINDAU'S
NEUROFIBROMATOSIS
STURGE-WEBER SD
OTH MANIFO
CAVERN
MAJ FORMS
CAPIL
MANKER
VISCERAL MALIGNANCY
ACANTHOSIS NIGRICANS
ACTINIC KERATOSIS
PREMAL
KERATOACANTHOMA
SEBORRHEIC KERATOSIS
DERMATOFIBROSARCOMA PROTUBERANS
DERMATOFIBROMA
EPID INCLUSION CYST
XANTHOMA
HEMANGIOMA
LYMPHANGIOMA
PYOGENICUM
KELOID
MISC
ACROCHORDON
"SKIN TAG"
"TIBERIAN DOLYD"
VERRUCA VULGARIS = GMT WART
MOLLUSCUM CONTAGIOSUM
VIRAL
PREC TO LENTIGO MM
LENTIGO MALIGNA
HUTCHINSON FREKKLE
MALIGNANT IN MM
DYSPLASTIC
PIGMENTED
NEVI
PIGMENTA
ALBINISM
OCULAR
OCULOCUT
TYROSINASE ⊖ VE
⊕ VE
PREDISPOSES TO ACTINIC KERATOSIS
BASCC 1 MM
VITILIGO
FRECKLE = EPHELIS
LENTIGO
BEN
JUNCTIONAL
COMPOUND
INTRADERM
MELANOCUTIC = COMMON MOLE
BLUE
BEN SPITZ = JUVENILE MELANOMA
ECZEMATOUS DERMATITIS
ATOPY
ALLERG
ETIO
IFC
CHEM
MORPHO
A
C
SA
FUNGAL SIMPLEX CHRONICUS
NEURODERMATITIS
PSORIASIS
PSORIATIC ARTHRITIS
VARICELLA = CHICKENPOX
PEMPHIGUS VULGARIS
BULLOUS PEMPHIGOID
DERMATITIS HERPETIFORMIS
ERYTHEMA MULTIFORME
MULTIPLE TYPES
"TARGET" LES
HS
IFM & VESICUL
NICOLASLEVY.NET
SCHNEIDER 2013

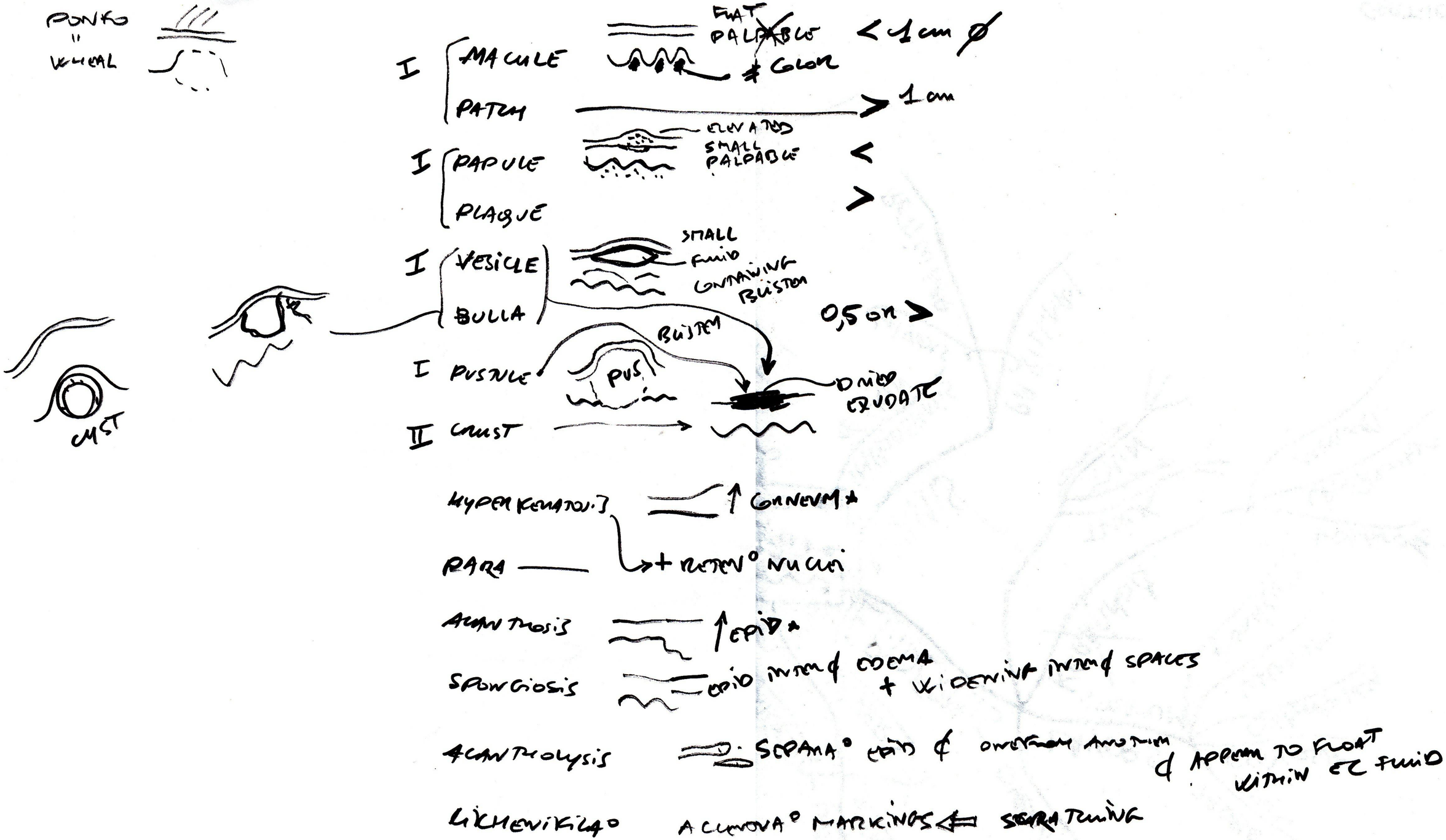
PONTO
"
VERTICAL
I
MACULE
FLAT
PALPABLE
< 1 cm ∅
≠ COLOR
PATCH
> 1 cm
I
PAPULE
ELEVATED
SMALL
PALPABLE
<
PLAQUE
>
I
VESICLE
BULLA
SMALL
FLUID
CONTAINING
BLISTER
0,5 cm >
BLISTER
I
PUSTULE
PUS
DRIED
EXUDATE
II
CRUST
CRUST
HYPERKERATOSIS
↑ CORNEUM
RARA
+ RETENT° NUCLEI
ACANTHOSIS
↑ EPID
SPONGIOSIS
EPID INTERC EDEMA
+ WIDENING INTERC SPACES
ACANTHOLYSIS
SEPARAT° EPID C OVERLYING ANATOMY
C APPEAR TO FLOAT
WITHIN EC FLUID
LICHENIFICAT°
ACCENTUAT° MARKINGS ⇐ SCRATCHING

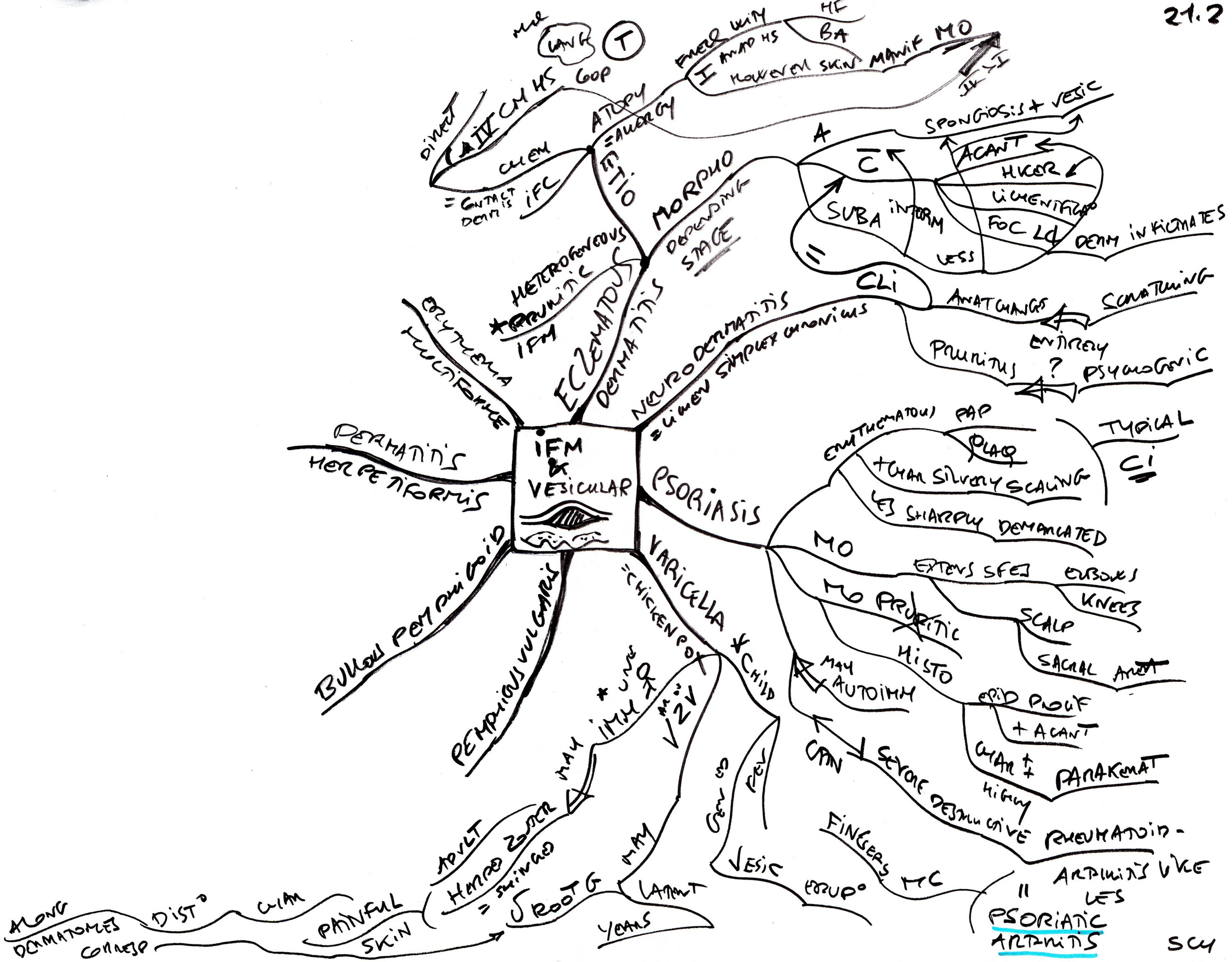
ECZEMATOUS DERMATITIS
ATOPY = ALLERGY
ETIO.
MORPHO DEPENDING STAGE
HETEROGENEOUS
PRURITIC
IFM
ERYTHEMA MULTIFORME
NEURODERMATITIS = LICHEN SIMPLEX CHRONICUS
IFM & VESICULAR
DERMATITIS HERPETIFORMIS
BULLOUS PEMPHIGOID
PEMPHIGUS VULGARIS
PSORIASIS
VARICELLA = CHICKENPOX
CHILD
ADULT
HERPES ZOSTER = SHINGLES
ROOT G
PAINFUL SKIN
ALONG DERMATOMES
DIST°
CHAR
LATENT
YEARS
MAY
VESIC
ERUPT°
FINGERS
MC
CAN
SEVERE DESTRUCTIVE RHEUMATOID-ARTHRITIS LIKE
PSORIATIC ARTHRITIS
TYPICAL
CI
EXTENS SFCE
ELBOWS
KNEES
SCALP
SACRAL AREA
MO PRURITIC
HISTO
MAY AUTOIMM
EPID PROLIF
+ ACANT
CHAR + HIGHLY
PARAKERAT
SPONGIOSIS + VESIC
ACANT
HYPER
LICHENIFICATION
FOC LL
DERM INFILTRATES
SUBA INFORM
LESS
CLI
ANAT CHANGES
SCRATCHING
PRURITUS
ENTIRELY ?
PSYCHOGENIC
EMPTHEMATOUS PAP
PLAQ
+ CHAR SILVERY SCALING
LES SHARPLY DEMARCATED
MO
EXTENS SFCE
ELBOWS
KNEES
SCALP
SACRAL AREA
MO PRURITIC
HISTO
MAY AUTOIMM
EPID PROLIF
+ ACANT
CHAR + HIGHLY
PARAKERAT
SEVERE DESTRUCTIVE RHEUMATOID-ARTHRITIS LIKE
PSORIATIC ARTHRITIS
NL
SCM

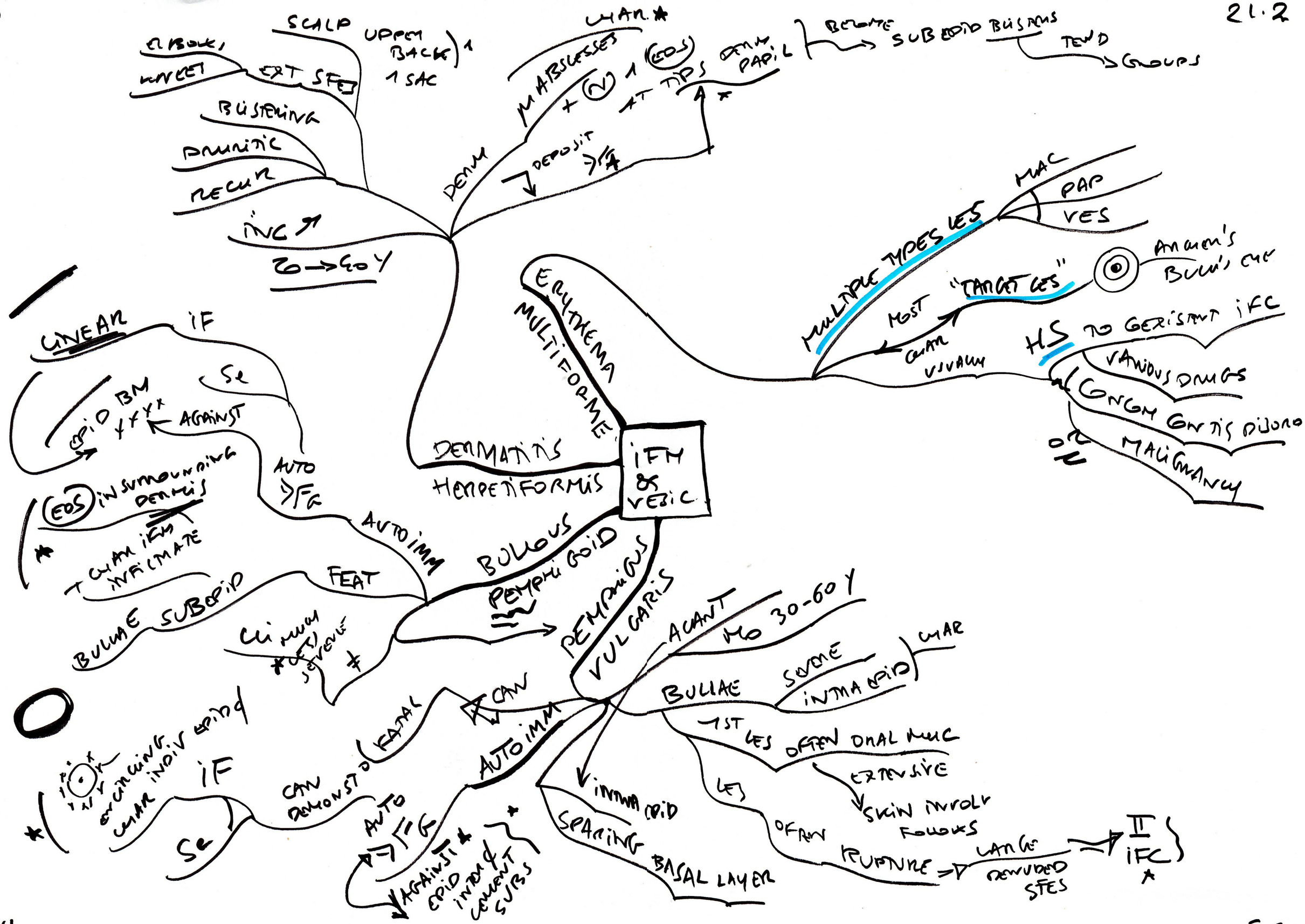
SCALP
UPPER BACK
1 SAC
ELBOW, KNEE
EXT SFS
BLISTERING
PRURITIC
RECUR
INC
20 → 60 Y
DERM
MARBLESSES
+ (N)
1 (EOS)
AT TIPS
DERM PAPIL
BECOME
SUBEPID BULLAE
TEND
GROUPS
DEPOSIT
MULTIPLE TYPES LES
MAC
PAP
VES
MOST
"TARGET LES"
ANAGEN'S BULB'S CHC
CHAR VISUALLY
HS
TO GERISTANT IFC
VARIOUS DRUGS
GONGM GRAFTS DISORD
OR
MALIGNANCY
ERYTHEMA MULTIFORME
DERMATITIS HERPETIFORMIS
IFM & VESIC
LINEAR
IF
SE
EPID BM
AGAINST
AUTO IFG
(EOS) IN SURROUNDING DERMIS
CHAR IFM INFILTRATE
AUTOIMM
BULLOUS
PEMPHIGOID
FEAT
BULLAE SUBEPID
CLINICAL
SEVERE
PEMPHIGUS VULGARIS
ACANT
MO 30-60 Y
BULLAE
SEVERE
INTRAEPID
CHAR
CAN
AUTOIMM
FATAL
CAN DEMONST
IF
SE
CHAR INDIV EPID
AUTO IFG
AGAINST EPID INTER CEMENT SUBS
INTRAEPID
SPACING
BASAL LAYER
1ST LES
OFTEN ORAL MUC
EXTENSIVE
SKIN INVOLV FOLLOWS
LES
OFTEN
RUPTURE
LARGE REVEALED SFES
II IFC
NL
SCH

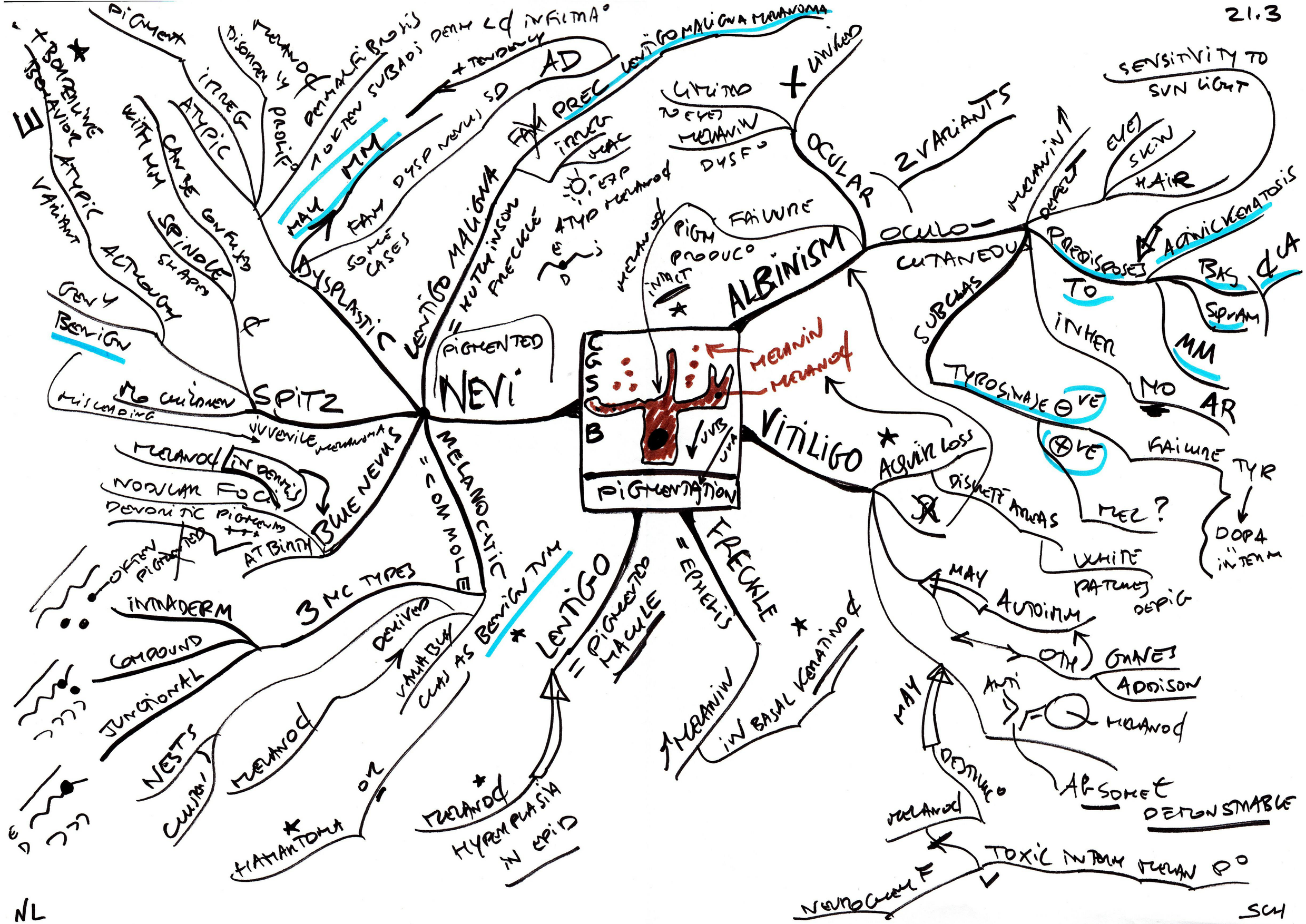
PIGMENTED NEVI
SPITZ
BENIGN
ATYPIC VARIANT
ACTINOUS
SPINDLE SHAPED
CAN BE CONFUSED WITH MM
ATYPIC
INNEG
PIGMENT
DYSPLASTIC
MAY ↑ MM
FAM DYSP NEVUS SD
SOME CASES
AD
FAM PREC
VENTIGO MALIGNA = HUTCHINSON FRECKLE
ATYP MELANOCYTES
MELANOCYTES
PIGM PRODUCO
FAILURE
ALBINISM
OCULAR
2 VARIANTS
OCULO-CUTANEOUS
SUBGROUPS
PREDISPOSES TO
ACTINIC KERATOSIS
BAS & CA
SQUAM
MM
INHER
NO AR
TYROSINASE ⊖ VE
⊕ VE
FAILURE TYR
DOPA INTERM
MEL ?
SENSITIVITY TO SUN LIGHT
EYES
SKIN
HAIR
MELANIN ↑
DEFECT
VITILIGO
ACQUIR LOSS
DISCRETE AREAS
WHITE PATCHES
DEPIG
MAY
AUTOIMM
OTH
GRAVES
ADDISON
ANTI
MELANOCYTE
ABSENCE
DETERMINABLE
MAY
DESTROYED
MELANOCYTES
TOXIC INTERM MELAN PO
NEUROGENIC
CGS
B
MELANIN
MELANOCYTES
UVB
UVA
PIGMENTATION
FRECKLE = EPHELIS
↑ MELANIN IN BASAL KERATINOCYTES
LENTIGO = PIGMENTED MACULE
MELANOCYTE HYPERPLASIA IN EPID
HAMANTOMA
NEVUS
BLUE NEVUS
MELANOCYTIC NEVUS
COM MOL
3 MC TYPES
JUNCTIONAL
COMPOUND
INTRADERM
NESTS
CULTURE
MELANOCYTES
DERIVED VARIABLY CLASS AS BENIGN TUM
MELANOCYTIC FOCI
DEVONIC PIGMENT
AT BIRTH
OFTEN PIGMENTED
MISLEADING
JUVENILE MELANOMA
NO CHANGE
MELANOCYTES
PIGMENTED
MALIGNANT MELANOMA
SUBAD DERM
INFILTRATES
TENDENCY
MELANOCYTES
PROLIFS
PIGMENT
ISOMORPHIC BEHAVIOR
BORDERLINE
LENTIGO MALIGNA
UNILAT
GRADUAL TO EYES
MELANIN
DYSF
NL
SCH

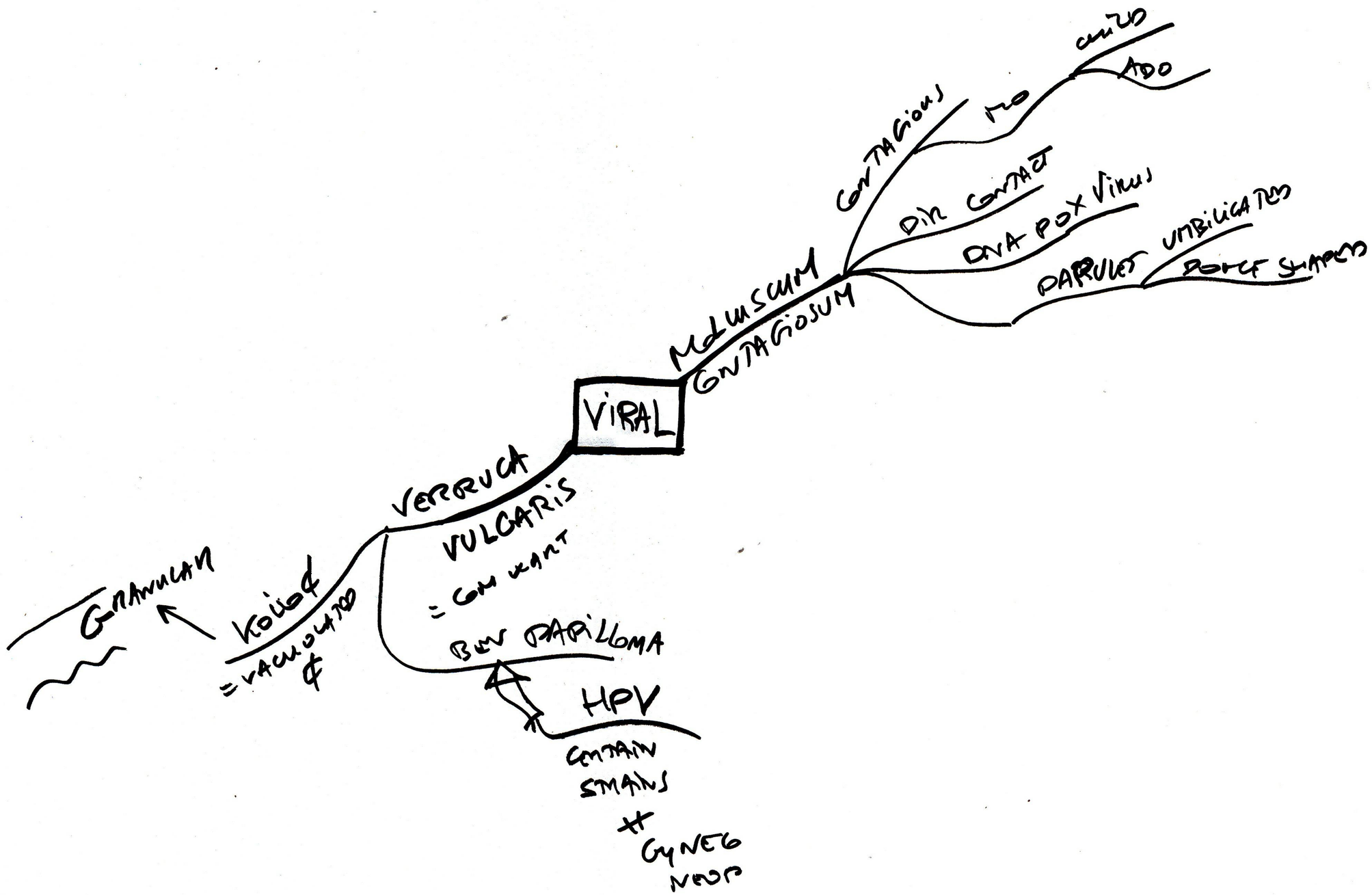
VIRAL
MOLUSCUM CONTAGIOSUM
CONTAGIOUS
PRO
CHILD
ADO
DIR CONTACT
DNA POX VIRUS
PARULIS
UMBILICATED
DOME SHAPED
VERRUCA VULGARIS
= COM WART
BEN PAPILLOMA
HPV
CONTAIN STRAINS
+ GYNEC NEOP
KOILOCYTOSIS
= VACUOLATED
GRANULAR

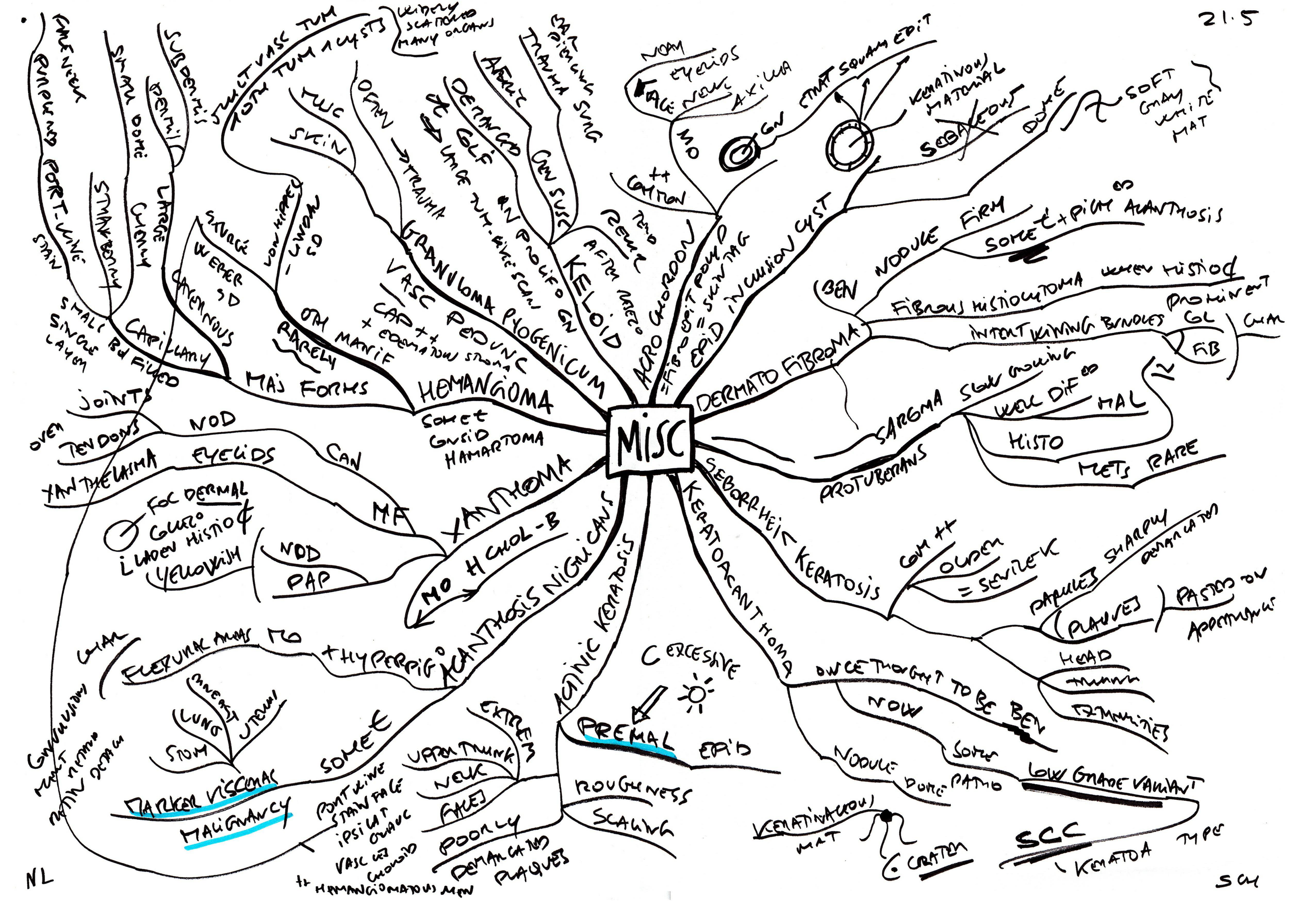
MISC
ACROCHORDON
FIBROEPIT POLYP
SKIN TAG
EPID INCLUSION CYST
DERMATOFIBROMA
BEN NODULE
FIRM
SOFT
SOFT GRAY WHITE MAT
DOME
SEBACEOUS
KERATINOUS MATERIAL
SQUAMY EPIT
GN
MO
KALE NEVI
AXILLA
EYELIDS
NOAM
++ COMPLICATION
ACTIN KERATOSIS
SEBORRHEIC KERATOSIS
PROTUBERANS
SARCOMA
HISTO
MALIGNANCY
MALIGNANCY
PREMAL
EPID
ROUGHNESS
SCALING
KERATOACANTHOMA
NODULE
DOME
PATHO
LOW GRADE VARIANT
SCC
KERATOA
TYPE
CRATER
KERATINACEOUS MAT
XANTHOMA
MO
HCHOL-B
NOD
PAP
FOC DERMAL
GLIO
LANGER HISTIO
YELLOWISH
XANTHELASMA
TENDONS
JOINTS
MAJ FORMS
HEMANGIOMA
GRANULOMA PYOGENICUM
VASC PROLIF
CAP ++
+ EDEMATOUS STROMA
KELOID
ACNE
ACNE
ACTINIC KERATOSIS
PRECAL
EPID
EXCESSIVE
SOLAR
SOLAR DOME
SUBDENTIS
PENTIL
LARGE CHEMY
CAPILLARY
CAVERNOUS
SINGLE LAYER
SMALL BLD FILLED
STRAW
WERNER SD
VON HIPPEL LINDAU SD
OTH MANIF
RARELY
SOLITARY
SOLITARY
SOLITAR

21.6

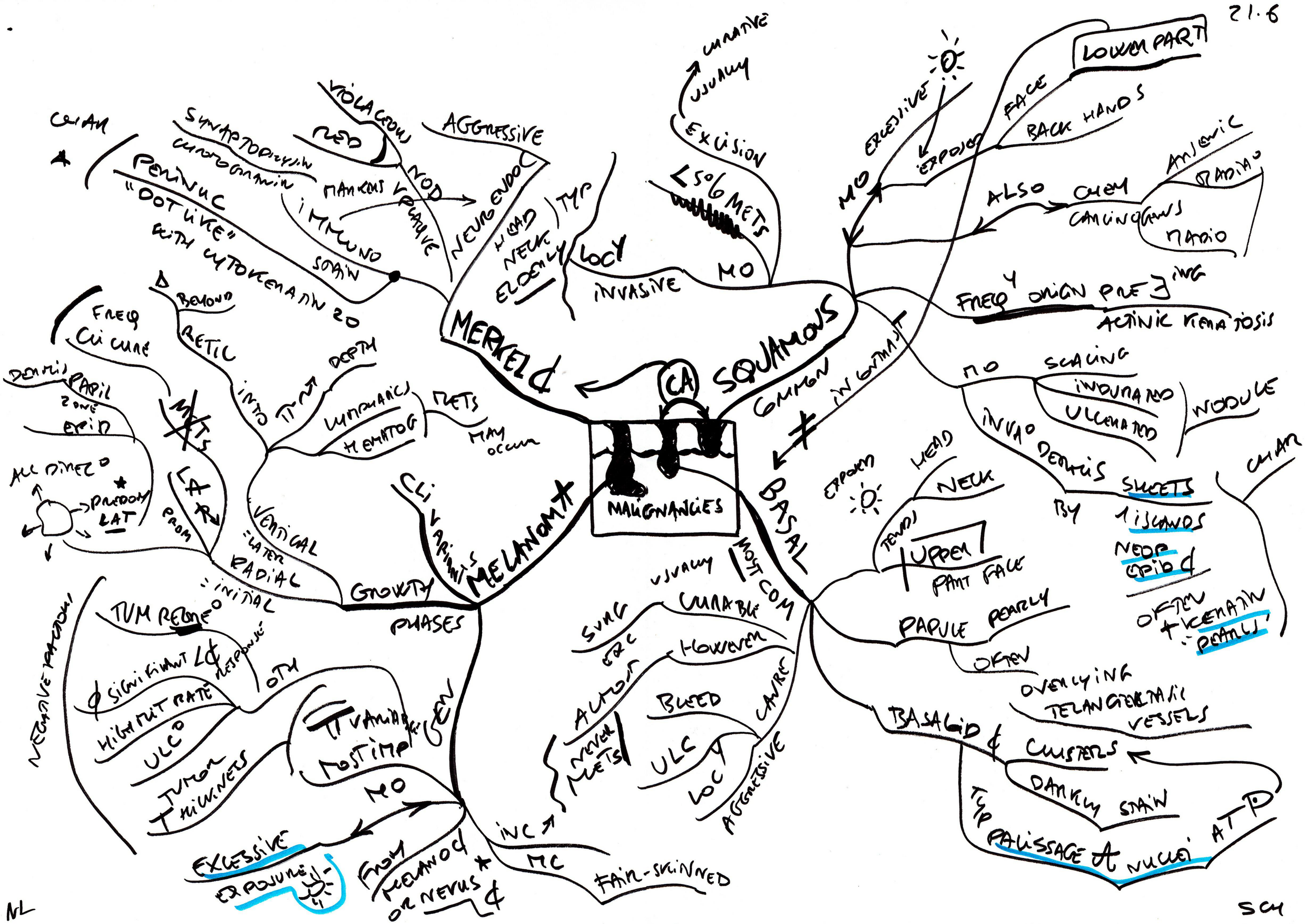
MERKEL
CA SQUAMOUS
MALIGNANCIES
MELANOMA
BASAL
CLIN VARIANTS
GROWTH PHASES
VERTICAL
RADIAL
INITIAL
LATER
FROM
ALL DIRECT
PREDOM LAT
ZONE
EPID
DENTIS
PAPIL
FREQ CLINIC
BEYOND
RETIC
INTO
DEPTH
LYMPHANGIO
HEMATOG
MAY OCCUR
METS
NEGATIVE PROGNOSIS
TUM REGRESS
SIGNIFICANT LC RESPONSE
HIGHEST RATE
ULC
TUMOR THICKNESS
OTH
TRANSLOCATION
MOST IMP
NO
EXCESSIVE
EXPOSURE
FROM MELANOCYTIC NEVUS
INC
MC
FAIR-SKINNED
SUNG ETC
AUTOS
NEVER METS
USUALLY
CURABLE
HOWEVER
BLEED
ULC
LOC
CANCER
AGGRESSIVE
MOST COM
EXCISION
<50 METS
MO
LOCALLY
INVASIVE
HEAD
NECK
TYP
NEUROENDOC
AGGRESSIVE
VIOLACEOUS
RED
NOD
MANKOS
IMMUNO
SUPPR
SYNAPTOPHYSIN
CHROMOGRANIN
PERINUC
"DOT LIKE" WITH CYTOKERATIN 20
CHAN
USUALLY
CURATIVE
EXCESSIVE
EXPOSURE
FACE
BACK HANDS
LOWER PART
ALSO
CHEM CARCINOGENS
ARSENIC
RADIATION
MARIO
FREQ ORIGIN PRECEDING
ACTINIC KERATOSIS
NO SCALING
INDURATED
ULCERATED
NODULE
INVADES DERMIS
SHEETS
ISLANDS
NEOPLASTIC
OFTEN ULCERATED
PEARLY
CHAN
BY
HEAD
NECK
TEND
UPPER PART FACE
PAPULE
PEARLY
OFTEN
OVERLYING TELANGIECTATIC VESSELS
BASALOID
CLUSTERS
DARKLY STAIN
TYP PALISSADE
NUCLEI
ATP
NL
SCM

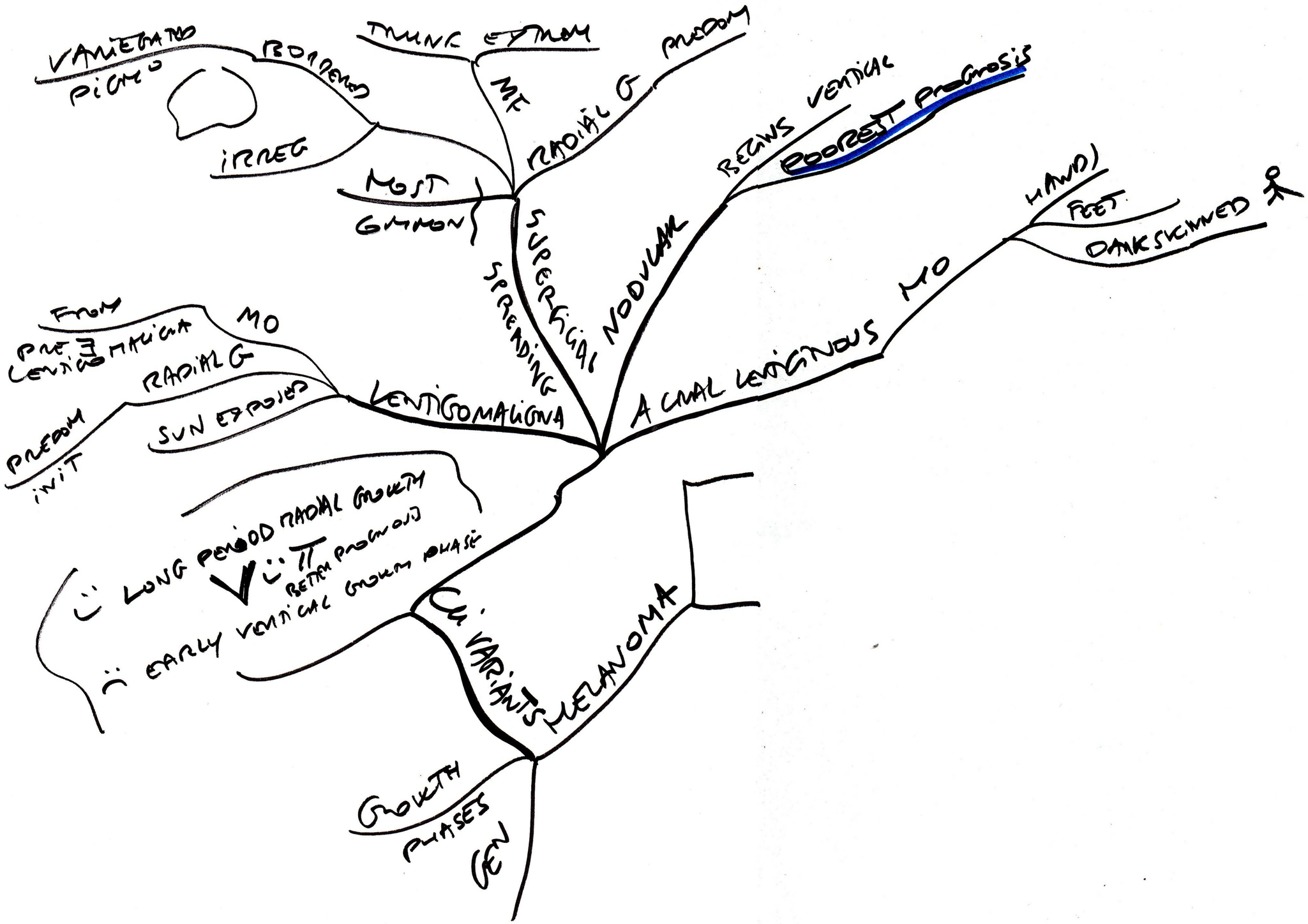
VARIEGATED
PIGMT
BORDERED
IRREG
TRUNK EXTRUDY
MT
RADIAL G
PREDOM
MOST
GMMON
SUPERFICIAL SPREADING
NODULAR
BEGINS VERTICAL
POORLY PROGNOSIS
HANDS
FEET
DARKSKINNED
ACRAL LENTIGINOUS MO
FROM
PRE ∃ LENTIGO MALIGNA
MO
RADIAL G
SUN EXPOSED
PREDOM
INIT
LENTIGOMALIGNA
LONG PERIOD RADIAL GROWTH
INIT
BETTER PROGNOSIS
EARLY VERTICAL GROWTH PHASE
CU. VARIANTS MELANOMA
GROWTH PHASES
GEN