(13%) MISCELLANOUS BENIGN
(80%) NO DISEASE
ADENOMA NIPPLE
PHYLLODES
CARCINOMA (10%)
TYPES
DCIS
INVAS DUCTAL
INVAS LOBULAR
MEDULLARY
MUCINOUS
COLLOID
LOBIS
PAGET D
INFLAMMATORY
PERICANALICULAR
FIBRO ADENOMA (7%)
INTRACANALICULAR
TUMORS
BREAST (7) FEMALE
MORPHO
FIBROCYSTIC (40%)
CHORIOAMNIONITIS
POSTPARTUM ANTIBIT NEC
SHEEHAN SD
AF EMBOLISM
HYDATIDIFORM MOLE
CHORIO CA
GEST TROPHOBLASTIC
OTH PERIPARTAL COMPLIC
ECLAMPSIA
PREECLAMPSIA
TOXEMIA
GENUINE
PARTIAL
(6) PREGNANCY
PREVIA
ACCRETA
ABRUPTIO
ECTOPIC
PLACENTA
ATTACHMENT
CHORIO CA
IMMAT
MATURE
MODERNAL
TERATOMAS
THECOMA-FIBROMA
GRANULOSA
SERTOLI-LEYDIG
ANDROBLASTOMA
ARRHENO B
KRUKENBERG
ENDOD SINUS
YOLK SAC
DYSGERMINOMA
OVARIAN SEXCORD
STROMAL
GERM & (1/4)
METS (5%)
TUMORS
OVARIES (5)
BRENNER
CLEAR CA
ENDOMETRIOID
ADENO CAS
MUCINOUS
SFE EPIT (3/4)
SEROUS
CYSTADENOMA
BORDERLINE
CYSTADENO CA
POLYCYSTIC
STEIN-LEVENTHAL SD
CHOCOLATE
CYSTS
FOLLICULAR
CORPUS
LUTEUM
THECA-LUTEIN
MISC
BARTHOLIN CYST
LICHEN SCLEROSUS
CANDIDIASIS
TRICHOMONIASIS
BAC
VAG GARDN
TOXIC
SHOCK SD
GONOR
CHLAMYD
HSV
SYPHILIS
CHANCROID
GRANULOMA INGUINALE
IFC
NEOP
VULVA
VAGINA (1)
NEOP
SCC
CLEAR CELL ADENOCA
SARCOMA BOTRYOIDES
EROSION
CERVICITIS
POLYPS
UTERUS
CERVIX (2)
NEOP
DYSPLASIA
INVASIVE CA
SCC
ROLE HPV 16 18 31 33
CORPUS (3)
ENDOMETRITIS
A
C SPECIFIC
GRANULOMATOUS
ENDOMETRIOSIS
ADENOMYOSIS
ENDOM HYPERPLAS
ENDOM POLYP
LEIOMYOMA
FIBROID
LEIOMYOSARC
ENDOM STROMAL
MALIGNANCIES
ENDOM CA
TYPES
I
II
FALLOPIAN TUBES (4)
NEOP
HEMATOSALPINX
SALPINGITIS
ADENOMATOID
ADENOCA
PAPILLARY
ADENOMA
HPV 6 11 13
CONDYLOMA ACUMINATUM
SCC
PAGET D
VULVA
MALIG
MELANOMA
NEOPLASIA
NICOLASLEVY.NET
SCHNEIDER 2013

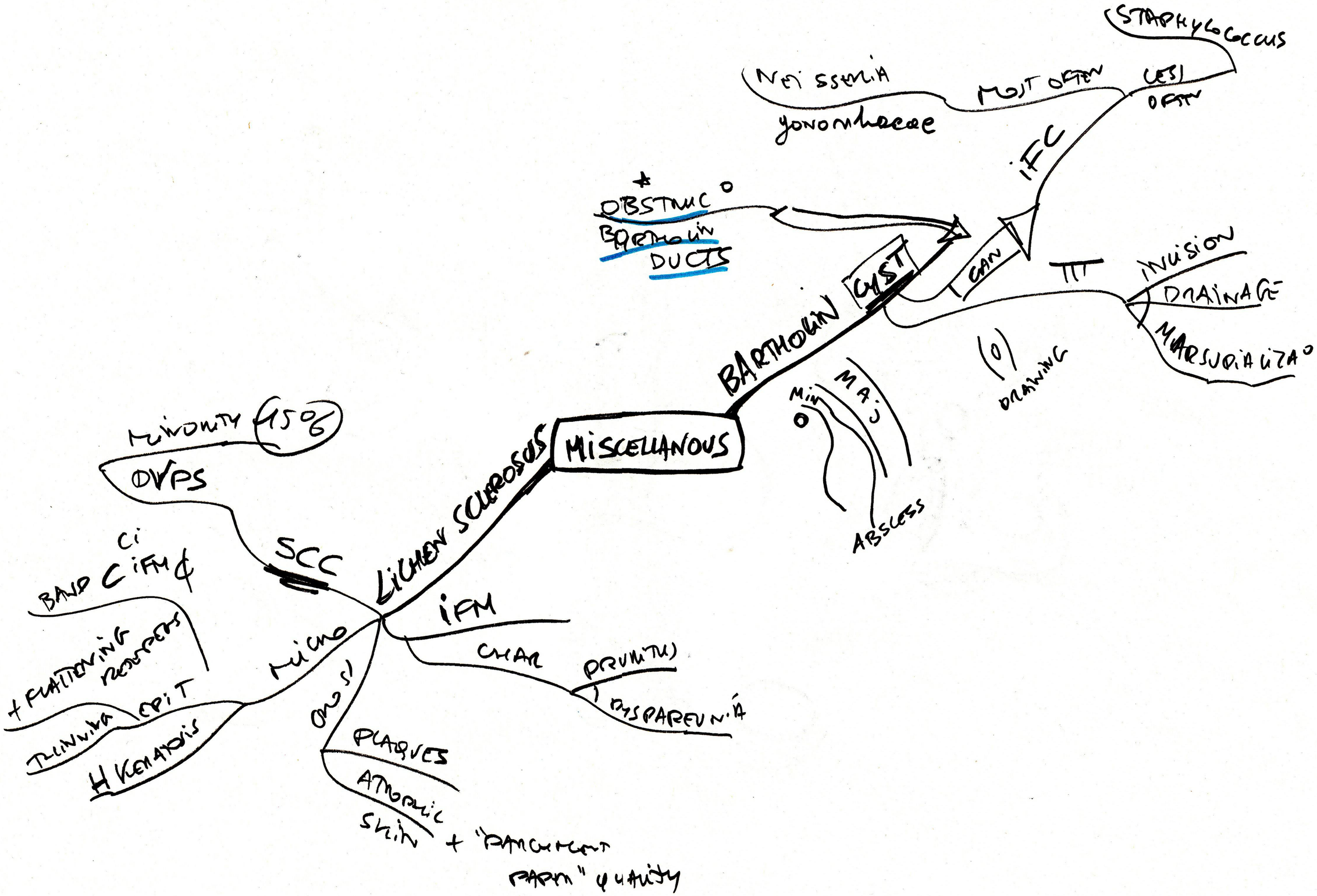
MISCELLANOUS
BARTHOLIN CYST
OBSTRUCTION
BARTHOLIN DUCTS
GAN
IFC
NEISSERIA gonorrhoeae
MOST OFTEN
LESS OFTEN
STAPHYLOCOCCUS
INCISION
DRAINAGE
MARSUPIALIZATION
(0) DRAWING
MIN
MAJ
ABSCESS
LICHEN SCLEROSUS
SCC
MINORITY (15%)
DVPS
BAND CIFM
+ FLATTENING RIDGES
TRINNINA
EPIT
HYPERKERATOSIS
MICRO
IFM
CHAR
PRURITUS
DYSPAREUNIA
ONS!
PLAQUES
ATROPHIC SKIN
+ "PARCHMENT PAPER" QUALITY

NL

SCH

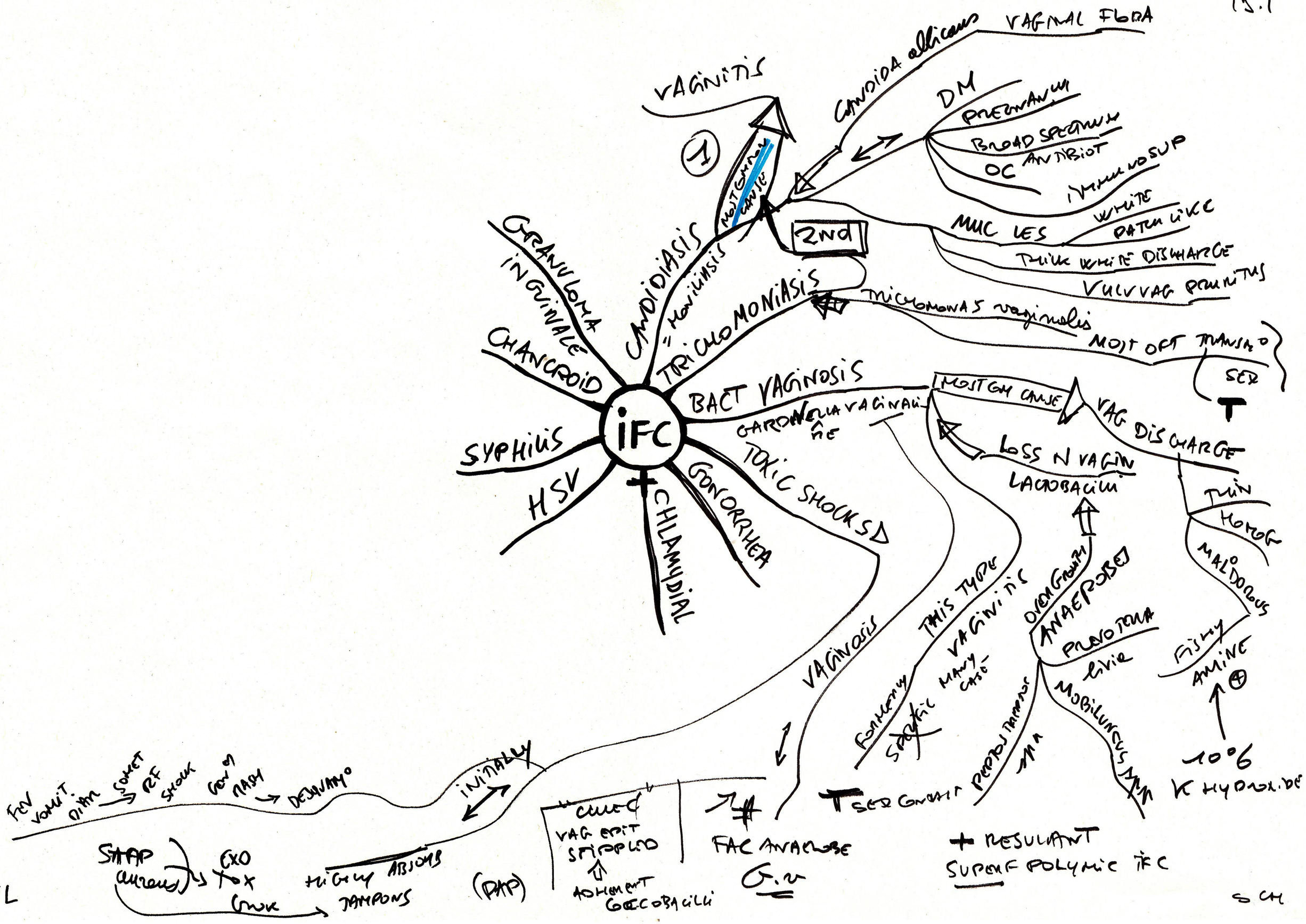
VAGINAL FLORA
VAGINITIS
CANDIDA albicans
DM
PREGNANCY
BROAD SPECTRUM ANTIBIOT
OC
IMMUNOSUP
1
MOST COMMON CAUSE
2nd
MUC LES
WHITE PATCH LIKE
THICK WHITE DISCHARGE
VULVAG PRURITUS
CANDIDIASIS
" NONINFECTIVE
TRICHOMONIASIS
TRICHOMONAS vaginalis
MOST OFT TRANSMD SEX
T
GRANULOMA INGUINALE
CHANCROID
BACT VAGINOSIS
GARDNERELLA VAGINALIS
MOST COM CAUSE
VAG DISCHARGE
LOSS N VAGIN
LACTOBACILLI
THIN
HOMOG
MALODOROUS
FISHY AMINE
+
10%
KOH
ANAEROBES
OVERGROWTH
PREVOTELLA
Bivia
MOBILUNCUS
MN
PEPTOSTREPTOCOCCUS
MN
THIS TYPE VAGINITIS
formerly
STATIC
MANY CASE
VAGINOSIS
IFC
SYPHILIS
HSV
CHLAMYDIAL
GONORRHEA
TOXIC SHOCK SD
+
SEE GONORR
+ RESULTANT SUPERIMPOSED IFC
FAC ANAEROBE
G.V
INITIALLY
CMC
VAG EPIT STIPPLED
ADHERENT GERCOBACILLI
(PAP)
HIGHLY ABSORB TAMPONS
STAP aureus
EXO
TOX
CNOK
FEV
VOMIT
DIAR
SOMET
RF
SHOCK
GOV
RASH
DESQUAMO
NL
SCH

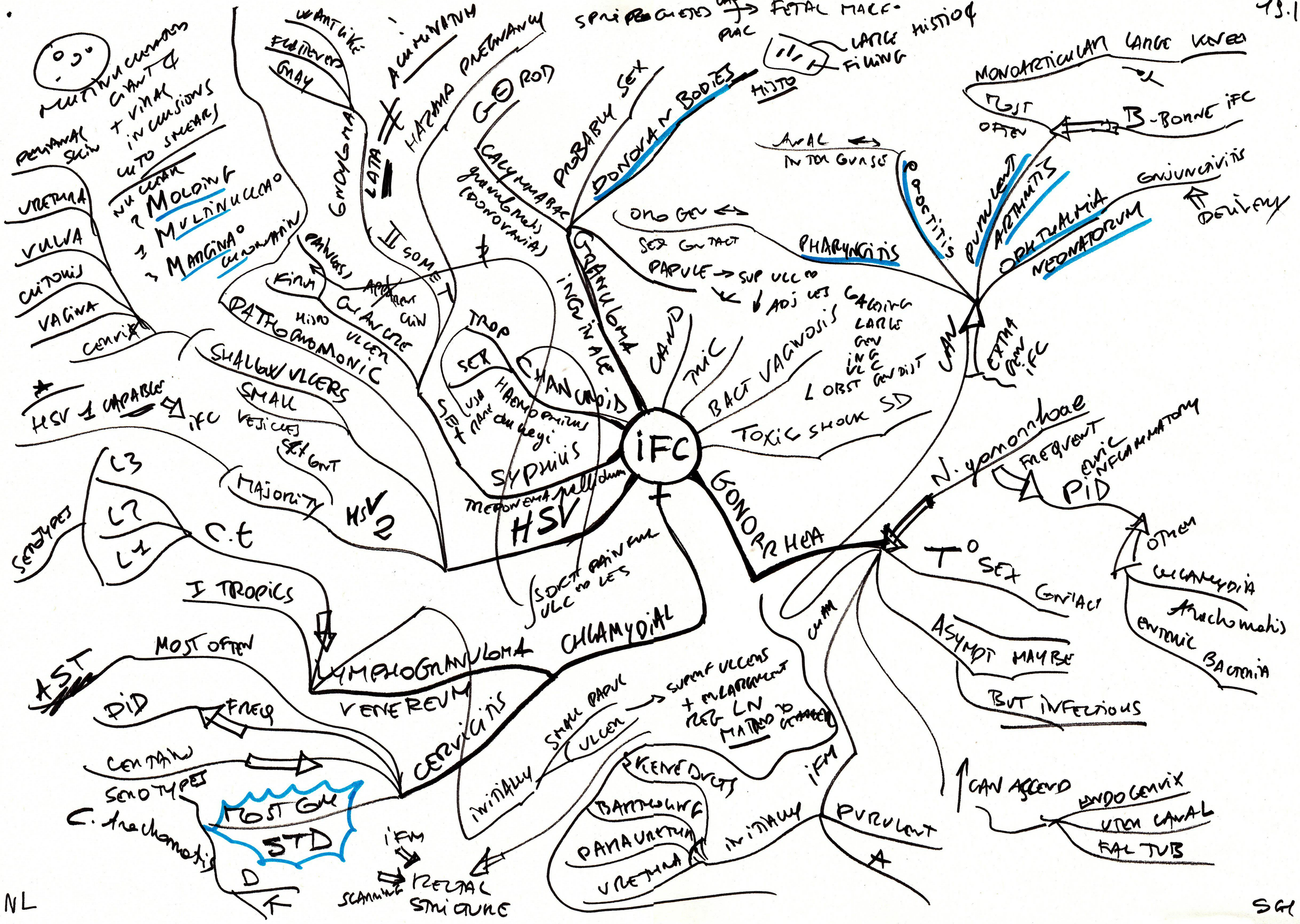
IFC
GONORRHEA
HSV
CHANCROID
SYPHILIS
LYMPHOGRANULOMA VENEREUM
CHLAMYDIAL CERVICITIS
PID
STD
NL
SGL
PELVIC SKIN
URETHRA
VULVA
CLITORIS
VAGINA
CERVIX
NUCLEAR MOLDING
MULTINUCLEATED
MARGINATION
GIANT + VIRAL INCLUSIONS
CUTO SMEARS
HSV 1 CAPABLE
IFC
SHALLOW ULCERS
SMALL VESICLES
SEXT CONT
MAJORITY
HSV 2
L3
L2
L1
C.t
SEROTYPES
I TROPICS
MOST OFTEN
AST
PID
FREQ
CERTAIN SEROTYPES
C. trachomatis
MOST COMMON STD
D
K
GRANULOMA
LATA
HAZMA PREGNANCY
FUNDUS
GRAY
ACUMINATUM
GRANULOMA INGUINALE
(DONOVANIA)
CALYMMATOBACTERIUM GRANULOMATIS
PROBABLY SEX
DONOVAN BODIES
HISTO
LARGE HISTIOCYTES
FILLING
FETAL MACROPHAGES
ORAL GEN
SEX CONTACT
PAPULE → SUP ULCER
ADJ LES
PHARYNGITIS
ANAL
INTERGLUTEAL
PROCTITIS
PURULENT
ARTHRITIS
ORPHTHALMIA NEONATORUM
CONJUNCTIVITIS
DELIVERY
MONOARTICULAR LARGE JOINTS
MOST OFTEN
B-BORNE IFC
EXTRA GEN IFC
CAND
TRIC
BACT VAGINOSIS
LARGE GRAMNEG VLC
LOBST GRANDIST
TOXIC SHOCK SD
CAND
TROP
SEX
SYPHILIS
HAEMOPHILUS DUCREYI
MEROWEMA pellidum
SEXT PAINFUL ULCERS
N. gonorrhoae
FREQUENT
PID
CHRONIC INFLAMMATORY
OTHER
CHLAMYDIA
Trachomatis
ENTERIC BACTERIA
T0 SEX CONTACT
ASYMPT MAYBE
BUT INFECTIOUS
UTI
SMALL PAPUL
ULCER
INITIALLY
SUPERF ULCERS + ENLARGEMENT REG LN
MATRIX TO CHANCRE
KERNEDYCTS
BARTHOLINE
PARAURETHRA
URETHRA
INITIALLY
IFM
PURULENT
A
CAN ASCEND
ENDOCERVIX
UTER CANAL
FAL TUB
IFM
SCANNING
RECTAL SMIGURE

NEOPLASMS

CERVIX

- UTILITY HPV TESTING? [EXCEPT ↔ ⊕ VS PAP]
- VIRUS ⊖ VS → RISK DVPT CANCER LOW
- HPV SO COMMON ⇒ ⊕ VS → MANY BIOPSIES + TESTS
- UNNECESSARY

VULVA

- VULVOVAG
  - PERIANAL
  - CERVIX SOMETIMES
- HPV
  - HSV
  - 6, 11
  - FROM LOW RISK
  - MOST OFTEN MULTIPLE
  - SEX CONTACT
  - MULTIPLE
  - CLI
  - HISTO
  - PERINUC HALOES
  - KOILOCYTES
  - OR EXPANDED EPIT + PERINUC CLEARING
- CONDYLOMA ACUMINATUM
  - VARI
  - NEGEL
- SCC
  - BEN
  - MOST CGM
  - QUAMOUS CELL CARCINOMA
  - MAL
- PAPILLOMA
  - MULTIPLE
- PAPILLARY
  - BLEED AND ULCERATE
  - MAY
  - LABIAL
  - NODULE
  - FROM
  - SIMPLE
  - EXCIS
  - APOC SWEAT GLANDS
  - MOST COM BEN
- HIDRADENOMA
- PAGET D
  - INCASES ASSOCIATED WITH HPV
  - LICHEN SCLEROSUS
  - MAY BE PRECEDED BY
  - DYSPLASTIC PROCESSING
  - ATYPICAL HYPERPLASTIC DYSTROPHY
  - PREMALIG CHANGES
  - GRADED VULVAR INTRAEPIT NEOP
  - VIN 1 THROUGH 3
  - = WELL DIFFERENTIATED "VIN"
  - HPV 16, 18, 31 OR 33
  - SAME STRAINS
- SIMILAR BREAST
  - SOMETIMES
  - UNDERLYING ADENOCA APOC SWEAT GLANDS
  - OFTEN
  - PAPILLOMATOUS
  - ELSEWHERE
  - OTHER STRAINS
- MELANOMA
- 10% MALIG MELANOMA

VAGINA

- "BRUNCH GRAPES"
  - MULTIPLE → PROJECTING INTO VAGINA OFTEN PROTRUDING FROM VULVA
  - POLYPOID
  - MASSES
  - < 5 Y AGE
- SARCOMA BOTRYOIDES
  - EMBRYONAL RARE
  - RHABDOMYOSARCOMA VARIANT
- CLEAR CELL ADENOCA
  - RARE
  - MALIGNANT
  - MUCOSAL GLANDS UNDER EPIT = PRECURSOR ?
  - MALIGNANT OCCUR REMOTE
  - PREMALIG
  - CERVIX AND VAGINA
  - INCIDENCE
  - DAUGHTERS WOMEN TAKE DES DURING PREGNANCY
  - PEAK INCIDENCE 1 YOUNG
- SCC
  - MOST OFTEN
  - EXTENS SCC CERVIX
  - VAGINA INFREQUENTLY PRIMARY SITE
  - UNGERTAIN LOCO FOR I SCC

NL IN VTRO

SCH

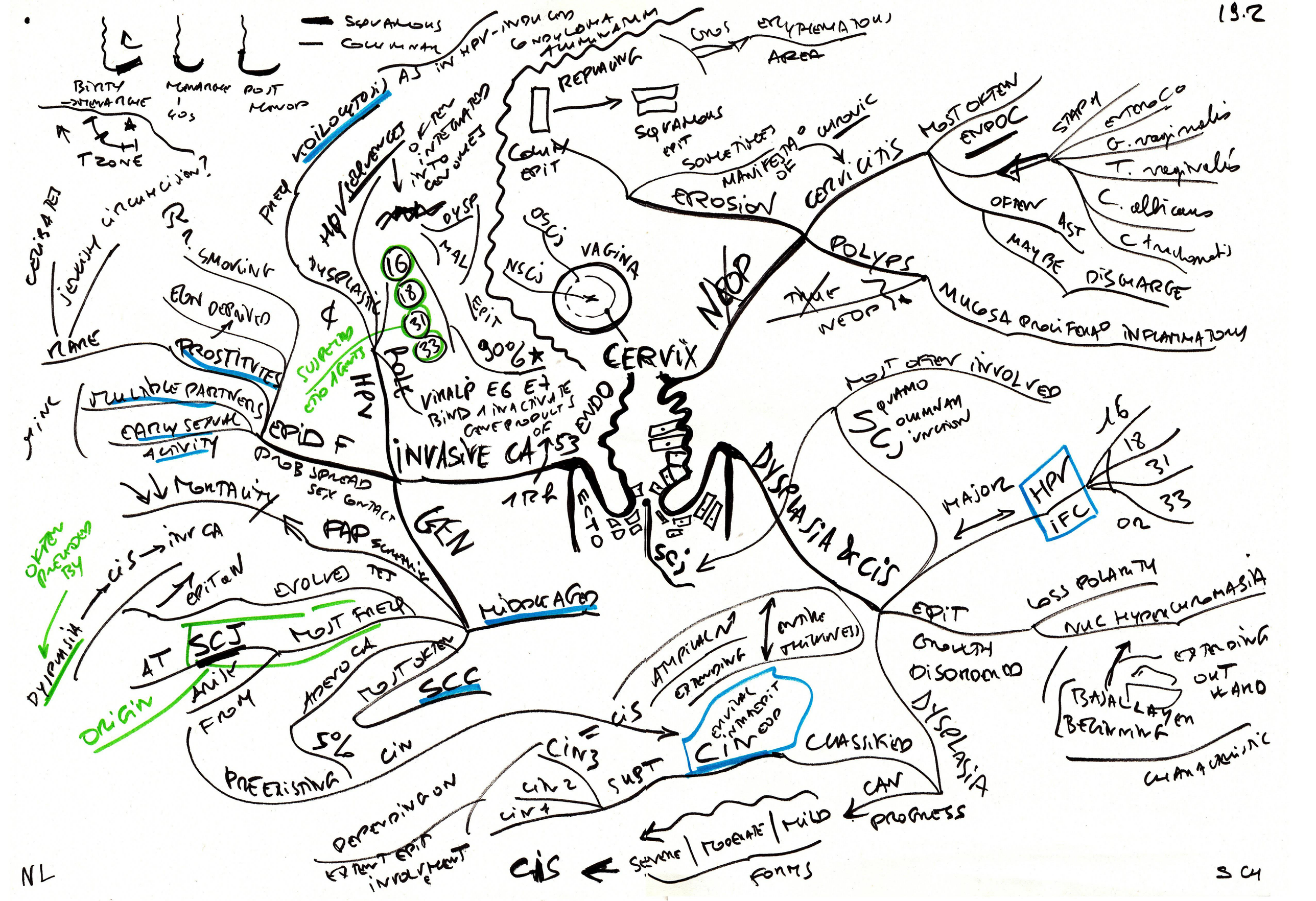
SQUAMOUS
COLUMNAR
BIRTH
MENARCHE
POST MENOP
T ZONE
CERVICITIS
MOST OFTEN
ENPOC
STAPH
ENTEROCO
G. vaginalis
T. vaginalis
C. albicans
C trachomatis
OFTEN
ASYMP
MAYBE
DISCHARGE
EROSION
SOMETIMES MANIFESTATION OF
CHRONIC
REPLACING
SQUAMOUS EPIT
COLUMN EPIT
CERVIX
VAGINA
OSCJ
NSCJ
NEOP
POLYPS
MUCOSA PROLIFERATION INFLAMMATORY
TYPE
NEOP
AS IN HPV-INDUCED CONDYLOMA ACUMINATUM
CONS ERYTHEMATOUS AREA
HPV/SELDOM
PREV KOILOCYTOSIS
OFTEN INTEGRATED INTO CHROMES
DYSP
MAL
EPIT
90%
16
18
31
33
DYSPLASTIC
SUSPECTED ETIOLOGY
HPV
POLY
VIRAL E6 E7 BIND & INACTIVATE GENE PRODUCTS OF
ENDO
INVASIVE CA
53
1%
ECTO
SCJ
DYSPLASIA & CIS
MOST OFTEN INVOLVED
SQUAMO COLUMNAR JUNCTION
16
18
31
33
02
MAJOR
HPV
IFC
LOSS POLARITY
NUC HYPERCHROMASIA
EPIT
GROWTH DISORDERED
DYSPLASIA
BASAL LAYER BEGINNING
EXTENDING OUT HERE
CHAMAELEONIC
CAN PROGRESS
CLASSIFIED
CIN
ENTIRE EPITHELIUM
CIS
ATYPICAL
EXTENDING
ENTIRE THICKNESS
CIN3
CIN2
CIN1
SUPT
CIS
SEVERE | MODERATE | MILD
FORMS
DEPENDING ON
EXTENT EPIT INVOLVEMENT
PREEXISTING
CIN
50%
APPROCA
MOST OFTEN
SCC
FROM
ANIM
ORIGIN
AT
SCJ
MOST FREQ
EVOLVED TEST
EPITHEL
CIS → INV CA
DYSPLASIA
OFTEN PRECEDED BY
MORTALITY
PAP SCREENING
PROB SPREAD SEX CONTACT
GEN
MIDDLE AGED
INVASIVE CA
FIRST SEXUAL ACTIVITY
VULNERABLE PARTNERS
MULTIPLE
CERVICITIS
JEWISH CIRCUMCISION?
R
SMOKING
EGW DEPRIVED
PROSTITUTES
RARE
NL
SCH

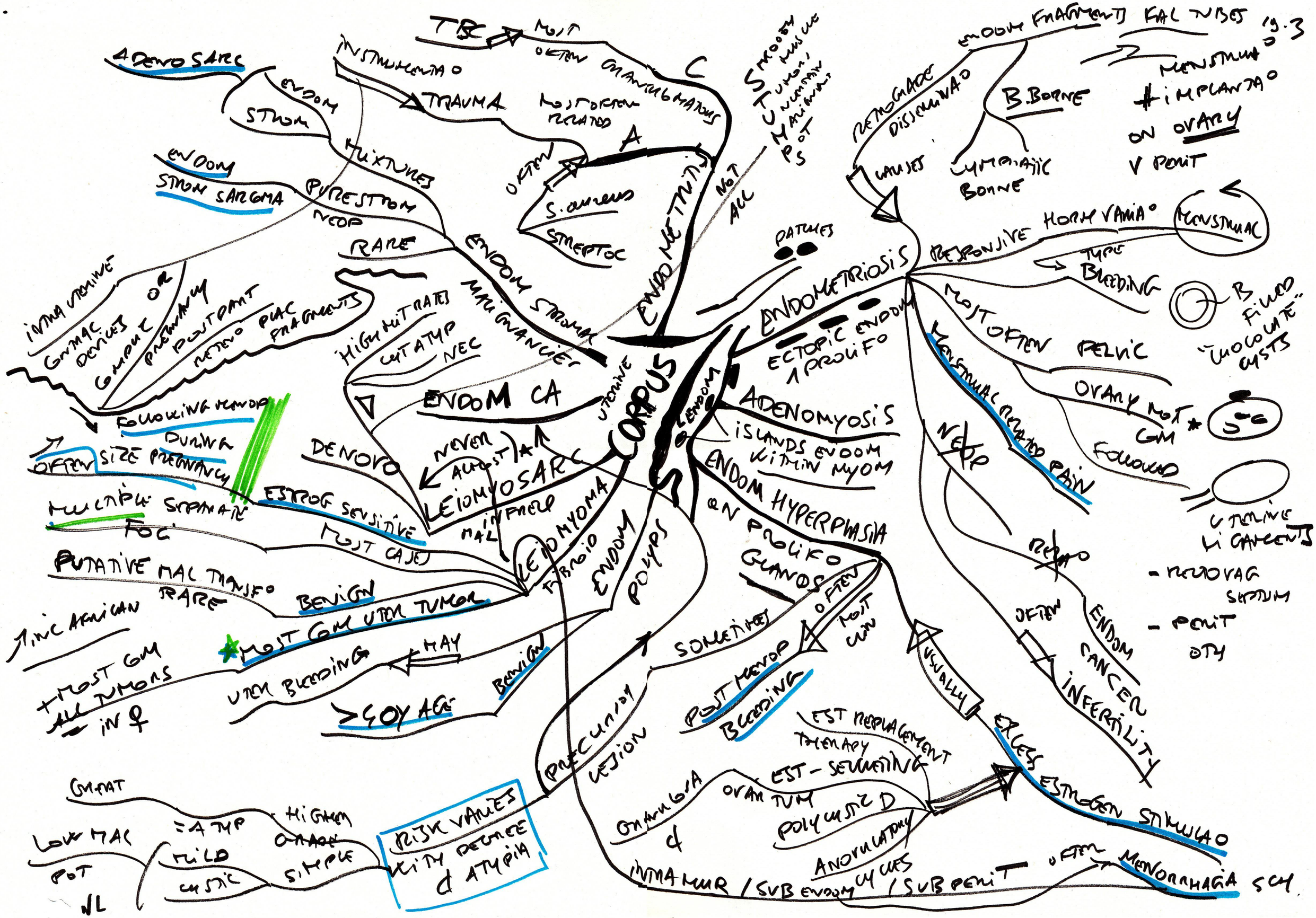
TB
MOST OFTEN GRANULOMATOUS
INSTRUMENTATION
TRAUMA
MOST OFTEN RELATED
ADENOSARC
ENDOM STROM
MIXTURES
ENDOM STROM SARCOMA
PURESTROM
NEOP
RARE
ENDOM STROMAL MALIGNANCIES
OFTEN
S. aureus
STREPTOC
ENDOMETRITIS
NOT ALL
STROOM MUSCLE URINARY NUMBER ANIMALS POT
C
A
INTRAUTERINE
GYNAC DEVICES OR
GYNAC
PNEUMATIC
POSTPART
METRO PLAC FRAGMENTS
HIGH NITRATES
CATATYP
NEC
ENDOM CA
FOLLOWING VENOUS
DURING
OFTEN SIZE PREGNANCY
DENOVO
NEVER ALMOST
LEIOMYOSARC
MALIGNANT
MULTIPLE SEPARATE FOCI
ESTROG SENSITIVE
MOST CASES
LEIOMYOMA
FIBROID
ENDOM POLYPS
PUTATIVE MAL TRANSFO
RARE
BENIGN
UTER TUMOR
MOST GYN
MAY
UTER BLEEDING
BENIGN
>60 YAGE
INC AFRICAN
MOST GYN ALL TUMORS IN ♀
GYNAT
LOW MAL POT
NL
=ATYP
MILD CYSTIC
HIGHER GRADE SIMPLE
RISK VALUES WITH DEGREE of ATYPIA
PRECURSOR LESION
SOMETIMES
OFTEN MOST CUR
POST MENOP BLEEDING
EST REPLACEMENT THERAPY
EST-SECRETING
OVAR TUM
POLYCYSTIC D
ANOVULATORY CYCLES
GRANULOSA
INTRAMUR / SUB ENDOM / SUB PERIT
OFTEN
MENORRHAGIA SCH
USUALLY
EXCESS ESTROGEN STIMULATO
ENDOM CANCER
INFERTILITY
OFTEN
PATCHES
ENDOMETRIOSIS
RESPONSIVE
HORMONAL
MENSTRUAL
TYPE BLEEDING
MOST OFTEN PELVIC
OVARY MOST COM
FOLLOWED
B FILLED "CHOCOLATE" CYSTS
MENSTRUAL PAIN
NEOP
ENDOM ADENOMYOSIS
ISLANDS ENDOM WITHIN MYOM
ENDOM HYPERPLASIA
ON PROLIFO GLANDS
RETROGRADE DISSEMINATION
CAUSES
B. BORNE
LYMPHATIC BORNE
ENDOM FRAGMENTS FAL TUBES
MENSTRUAL IMPLANTATION
ON OVARY
V POINT
UTERINE LIGAMENTS
- RECTOVAG SEPTUM
- PERIT CDS
NEOP
RETRO
19.3

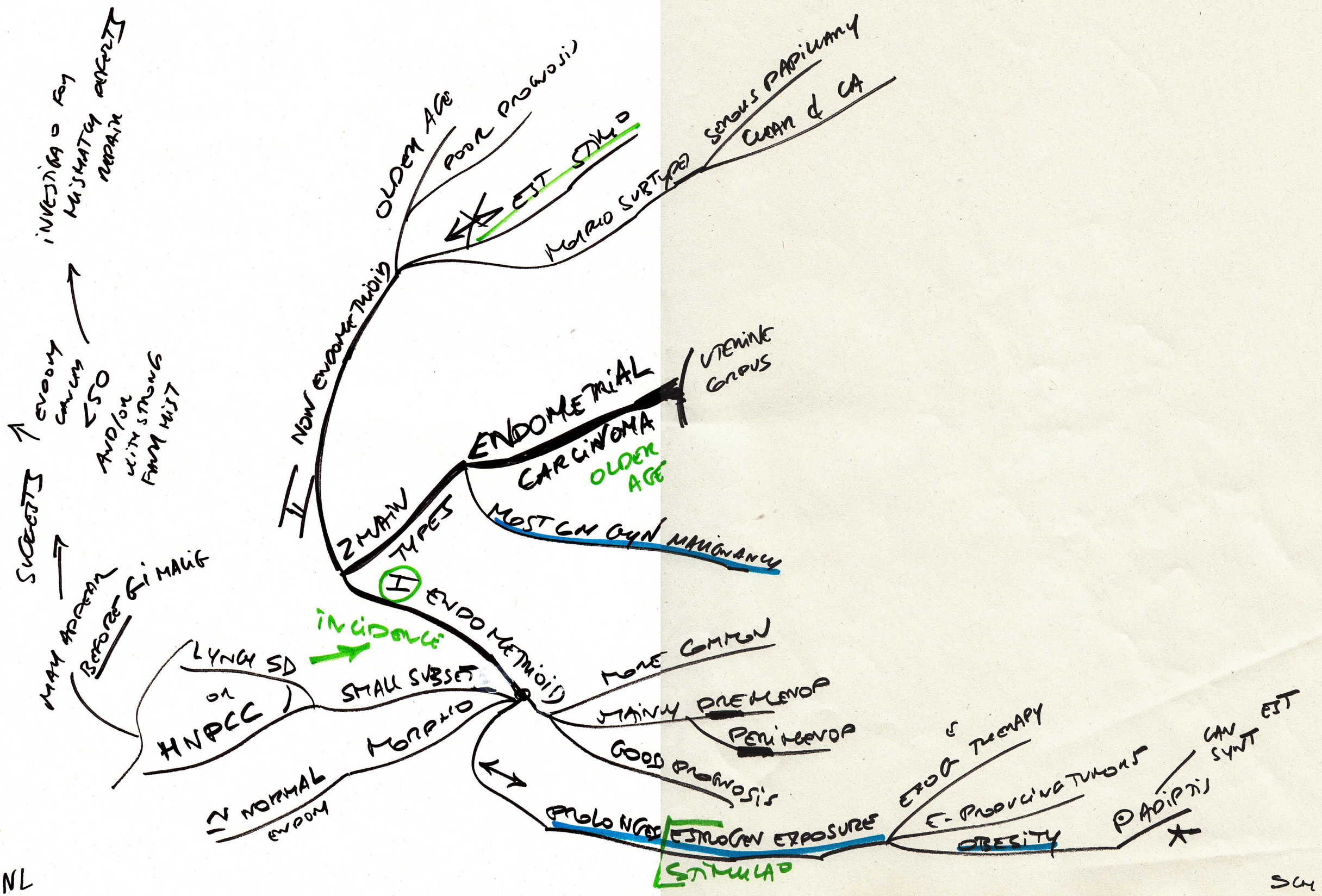
INVESTIGATION FOR MISMATCH REPAIR
SUGGESTS
↑ ENDOM CANCER <50 AND/OR WITH STRONG FAM HIST
MAY APPEAR BEFORE GI MALIG
LYNCH SD OR HNPCC
INCIDENCE
SMALL SUBSET
MORPHO
~ NORMAL ENDOM
NOW ENDOMETRIOID
OLDER AGE
POOR PROGNOSIS
EST STIM
MORIO SUBTYPES
SEROUS PAPILLARY
CLEAR CA
2 MAIN TYPES
I
II
ENDOMETRIAL CARCINOMA
UTERINE GROUS
OLDER AGE
MOST CM GYN MALIGNANCY
ENDOMETRIOID
MORE COMMON
MAINLY PREMENOP
PERIMENOP
GOOD PROGNOSIS
PROLONGED ESTROGEN EXPOSURE
STIMULATED
ESTROG THERAPY
E-PRODUCING TUMORS
OBESITY
PADIPATIS
CAN SYNT EST
NL
SCM

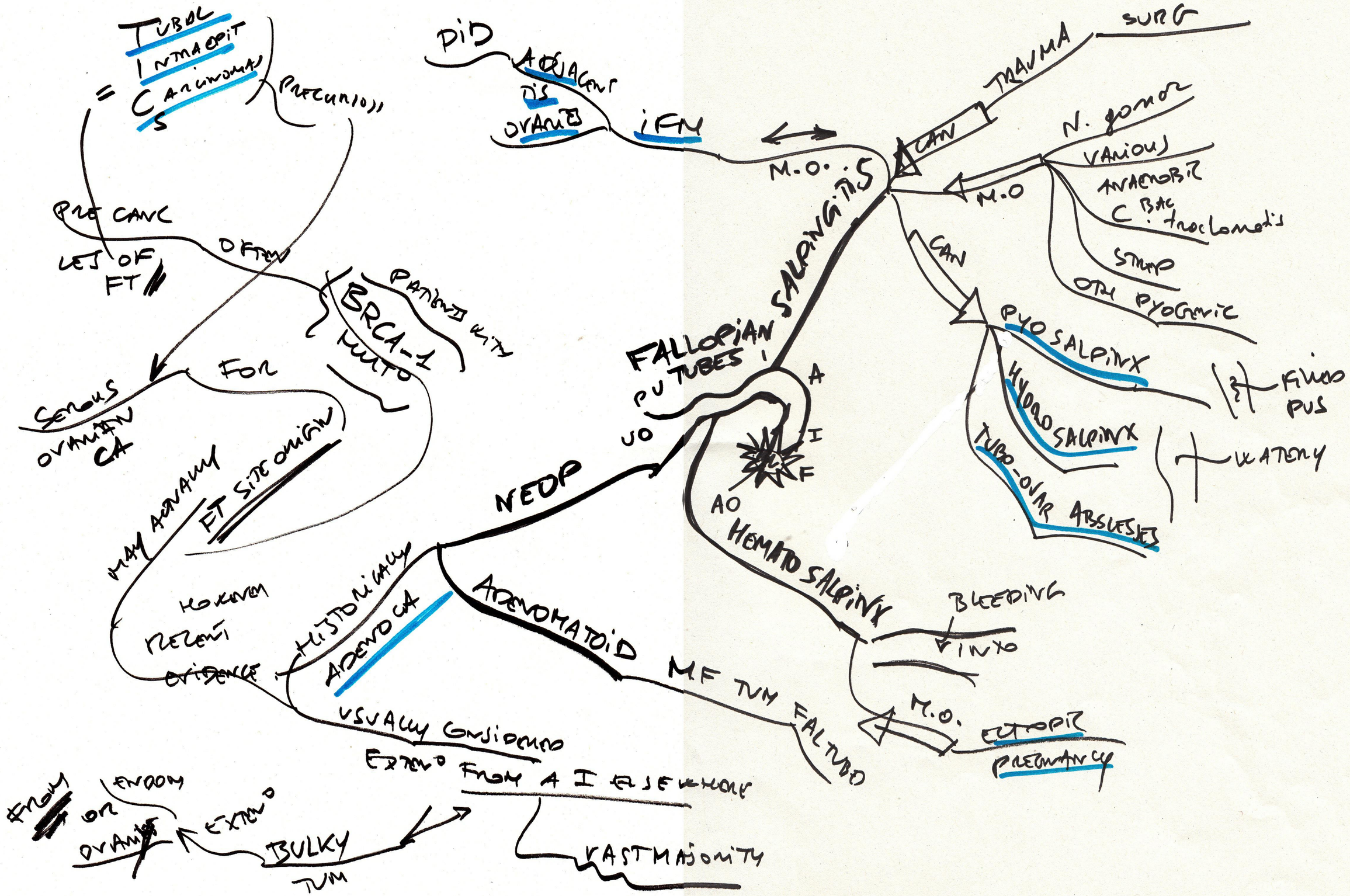
TUBAL INTRAEPIT CARCINOMAS
= CS
PRECURSORS
PID
ADJACENT DIS
OVARIES
IFN
TRAUMA
SURG
N. gonor
VARIOUS
ANAEROBIC
C. trachomatis
STREP
OTH PYOGENIC
M.O.
CAN
M.O
CAN
PRE CANC
LES OF FT
OFTEN
BRCA-1 MUTO
PATIENTS WITH
FOR
SEROUS OVARIAN CA
FALLOPIAN TUBES
SALPINGITIS
PYO SALPINX
HYDRO SALPINX
TUBO-OVAR ABSCESSES
FILMS PUS
+ HEATERY
A
I
F
AO
UO
NEOP
MAY ARISE
FT SITE ORIGIN
HOWEVER
RECENT EVIDENCE
HISTORICALLY
ADENO CA
ADENOMATOID
HEMATO SALPINX
BLEEDING
VINO
M.O.
ECTOPIC PREGNANCY
MF TUM FALTUBO
USUALLY CONSIDERED
EXTENS FROM A I ELSEWHERE
VAST MAJORITY
FROM OR OVARY
ENDOM
EXTENS
BULKY TUM

NL

SCH

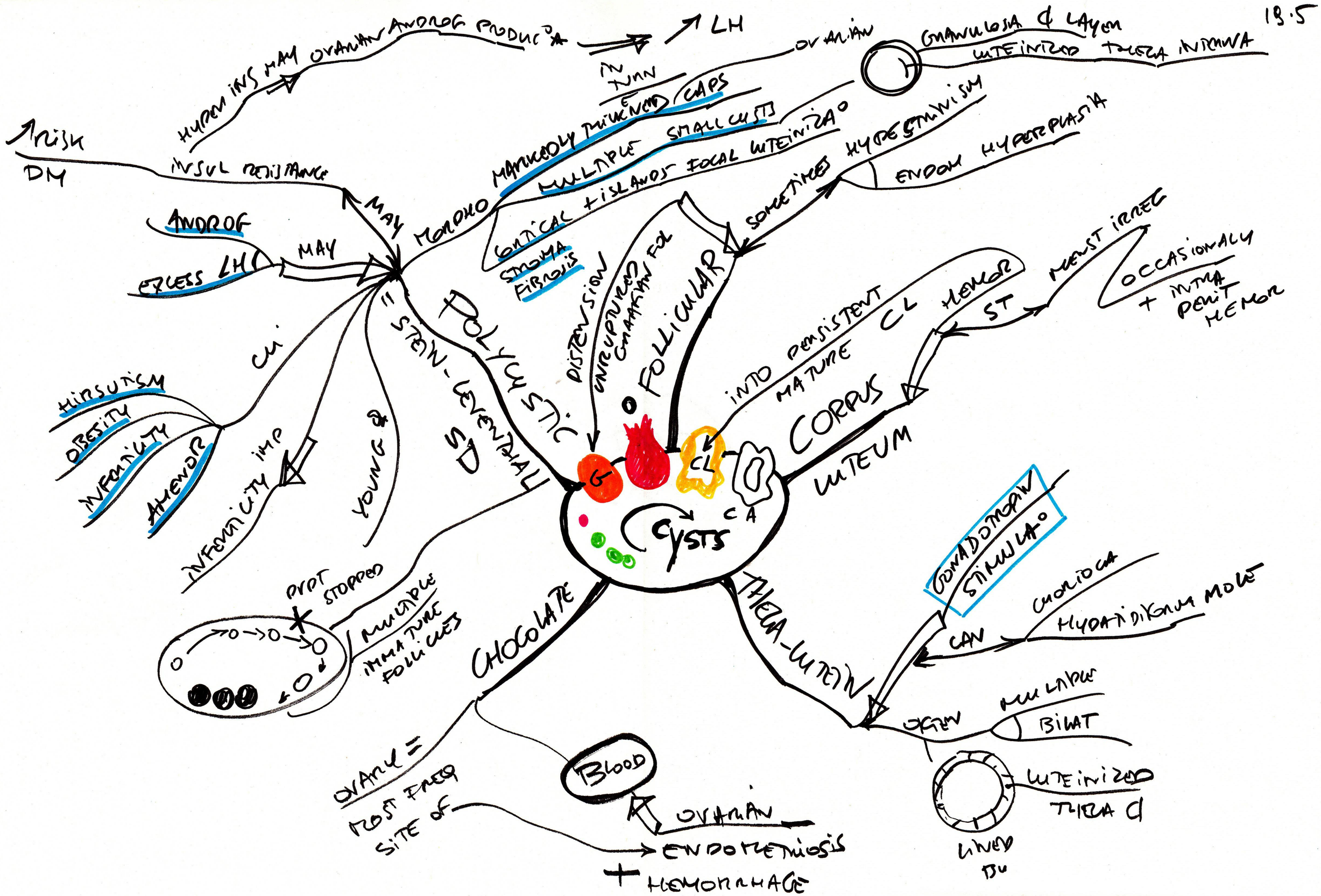
↑ risk DM
hyperins may ovarian androg production
↑ LH
in turn
ovarian androg
insul resistance
may
androg
excess LH
may
hirsutism
obesity
infertility
amenor
infertility
imp
cui
young ♀
Stein-Leventhal SD
Polycystic ovarian
Follicular
distension
unruptured graafian fol
markedly thickened caps
multiple small cysts
cortical islands focal luteinization
stroma fibrosis
sometimes hyperestrinism
endom hyperplasia
granulosa & layer
luteinized theca interna
menst irreg
occasionally + intra menor
st menor
into persistent mature CL
corpus luteum
Cysts
G
CL
CA
gonadotropin stimulation
chorioca
hydatidiform mole
can
theca-lutein
ovary
multiple
bilat
luteinized theca cl
lined by
chocolate
prot stopped
multiple immature follicles
ovary = most freq site of
Blood
ovarian
endometriosis
+ hemorrhage

NL

SCH

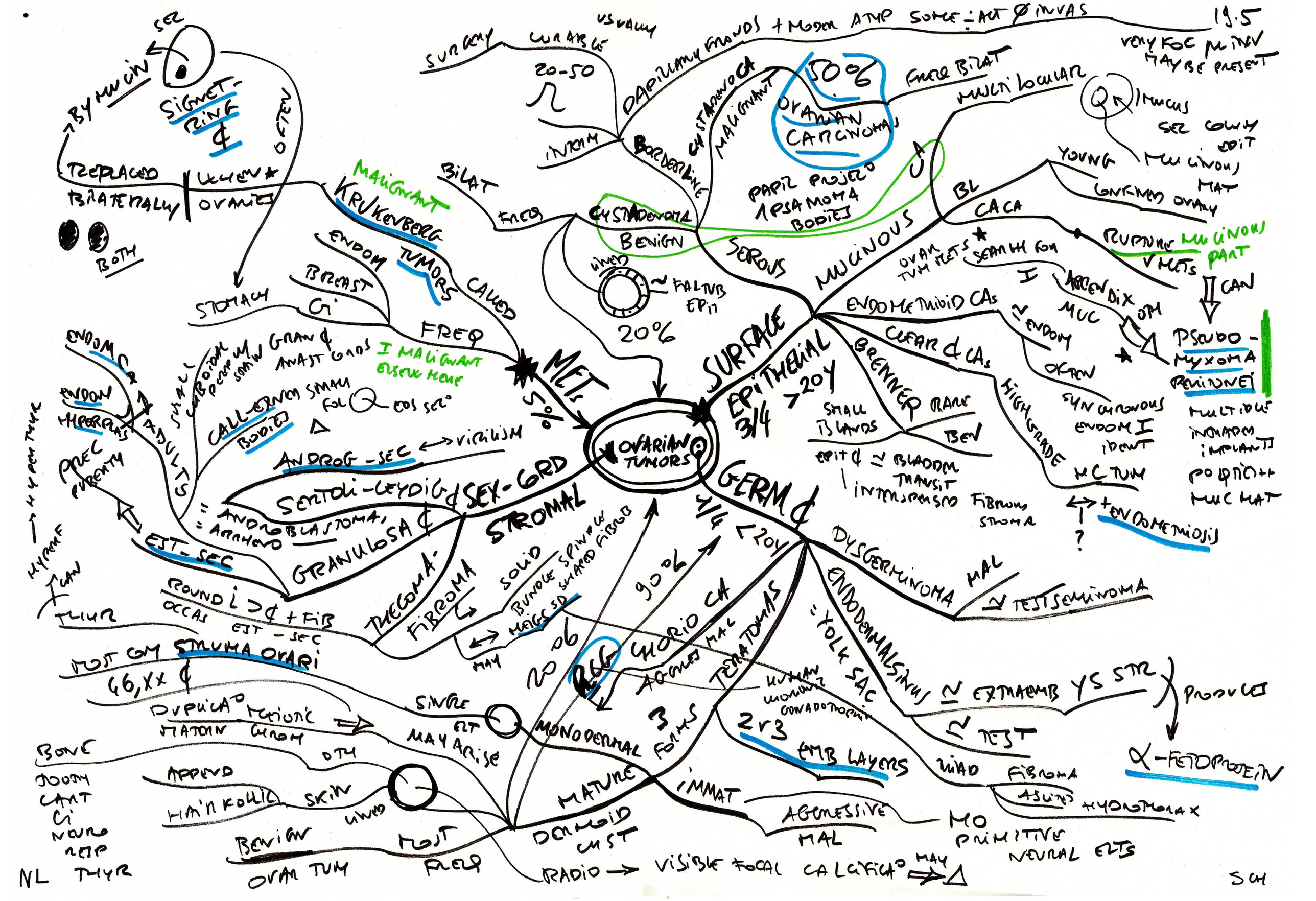
19.5
OVARIAN TUMORS
METS 5%
SURFACE EPITHELIAL 3/4 >20Y
GERM ¢ 1/4 <20Y
SEX-CORD STROMAL
SIGNET-RING ¢
REPLACED BILATERALLY
UNILAT OVARIES
BOTH
KRUKENBERG TUMORS
MALIGNANT
CAUSED
STOMACH
BREAST
GI
ENDOM
FREQ
BILAT
CYSTADENOMA
BENIGN
SEROUS
MUCINOUS
PAPILLARY GLANDS + MORE ATYP SOME ÷ ACT Ø INVAS
SURGERY
CURABLE
USUALLY
20-50
INVASIV
BORDERLINE
CYSTADENOCA
MALIGNANT
50%
OVARIAN CARCINOMA
FREQ BILAT
MULTILOCULAR
PAPIL PROJECS
PSAMMOMA BODIES
VERY ROE MUCINV MAYBE PRESENT
MUCINOUS SEC COLONY EPIT
MUCINOUS MAT
YOUNG
GENERAL OVARY
BL
CACA
RUPTURE MUCINOUS PART
OVAR TUM METS
SEARCH FOR
APPENDIX
MUC
OM
CAN
PSEUDO-MYXOMA PERITONEI
MULTIPLE INTRAPER IMPLANTS
POORLY DIFF MUC MAT
ENDOMETRIOID CAs
CLEAR ¢ CAs
BRENNER RARE
BEN
SMALL ISLANDS
EPIT ¢ ≃ BLADDER TRANSIT
INTERSPERSED
FIBROUS STROMA
HIGH GRADE
SYNCHRONOUS ENDOM I IDENT
MC TUM
+ ENDOMETRIOSIS
?
ENDOM CA
ENDOM HYPERPLAS
ADULTS
PREC PARENTS
SMALL CARBOHYDRATE SOLID
GRAN ¢ ANAST GLANDS
I MALIGNANT USUAL HERE
CALLEXNER SMALL FOL BODIES
EOS SEC
ANDROG-SEC ↔ VIRILISM
SERTOLI-LEYDIG ¢
= ANDROBLASTOMA, = ARRHENO
GRANULOSA ¢
EST-SEC
THECOMA-FIBROMA
SOLID
BUNDLE SPINDLE
MAGG SD SHARED FIBROB
MAY
ROUND i ⊃ ¢ + FIB
OCCAS EST-SEC
THYR
HYPERP
CAN
MOST COM STRUMA OVARI
46,XX ¢
DUPLICATE HAPLOID MATERN CHROM
SINGLE ELT MAY ARISE
BONE
BODY
CART
GI
NEURO
RESP
NL THYR
APPEND
HAIR FOLLIC
SKIN
UNIL
BENIGN
MOST
OVAR TUM
FREQ
90%
RARE CHORIO CA
AGRES MAL
TERATOMAS
MONODERMAL
3 FORMS
MATURE
DERMOID CYST
RADIO → VISIBLE FOCAL CALCIFICATION MAY ⇒ △
IMMAT
AGGRESSIVE MAL
MO PRIMITIVE NEURAL ELTS
HUMAN CHORIONIC GONADOTROPIN
2r3 EMB LAYERS
ENDODERMALSINUS ≃ EXTRAEMB YS STR
≃ TEST
YOLK SAC
PRODUCES
α-FETOPROTEIN
MIXED FIBROMA
ASSOC HYDROTHORAX
SCH

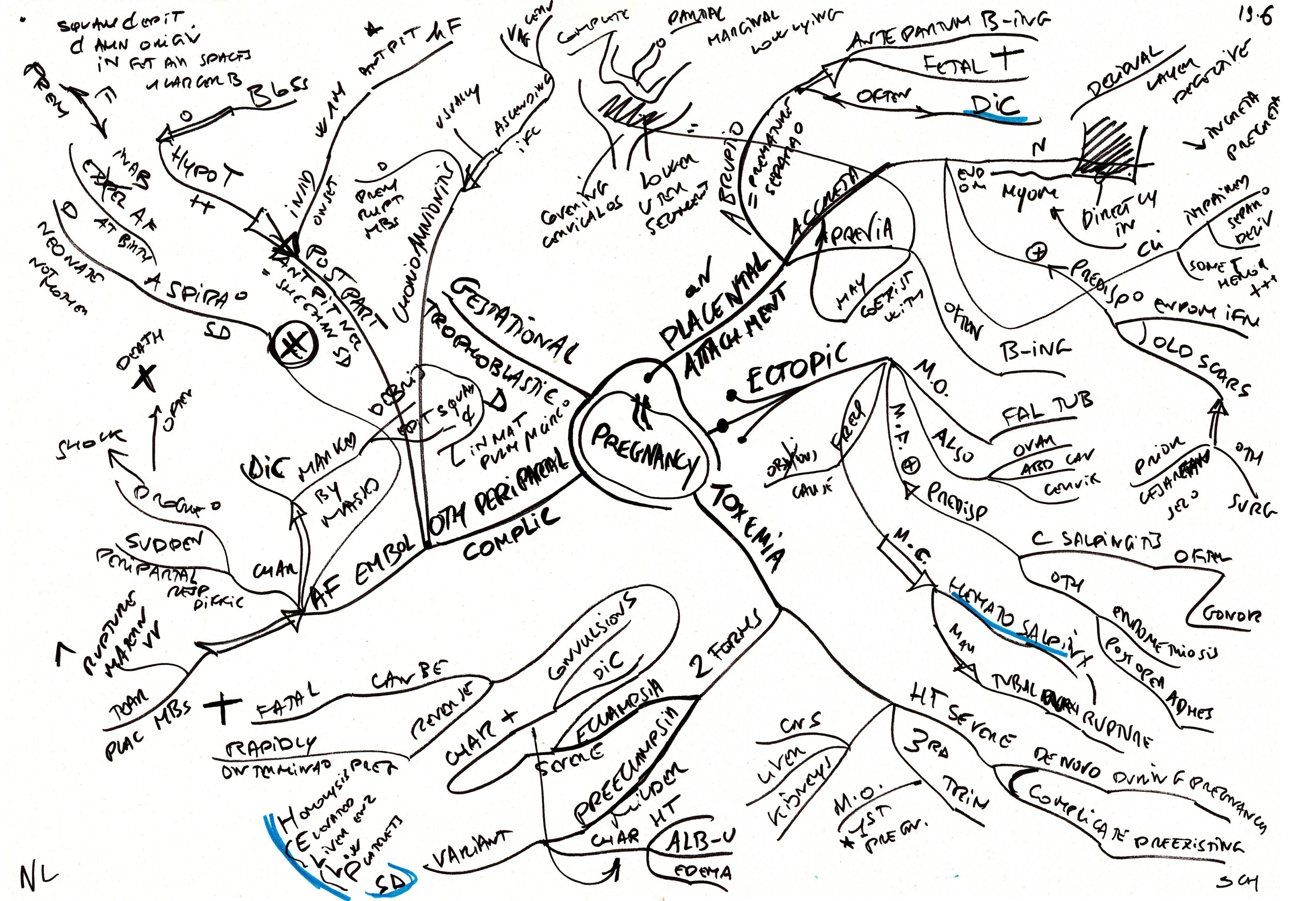
19.6
PREGNANCY
GESTATIONAL
TROPHOBLASTIC
PLACENTAL ATTACHMENT
ECTOPIC
TOXEMIA
ACCRETA
PREVIA
ANTEPARTUM B-ING
FETAL
DIC
DECIDUAL
LAYER
INCRETA
PRECRETA
MYOM
DIRECTLY IN
CU
IMPLANTATION
SEPAR
DECID
SOME
HEMOR
PREDISPO
ENDOM IFN
OLD SCARS
OTHER B-ING
MAY COEXIST WITH
FAL TUB
OVAR
ABD CAV
CONVIX
PRIOR
SURG
M.O.
ALSO
PREDISP
C SALPINGITIS
OTH
GONOR
PYOSALPINX
PYOMETRIOSIS
POST OPER ADHES
HEMATO SALPINX
MAY
TUBAL
RUPTURE
HT SEVERE
DE NOVO
DURING PREGNANCY
COMPLICATE PREEXISTING
3RD TRIM
CNS
LIVER
KIDNEYS
M.O.
1ST PREGN.
SCH
2 FORMS
CONVULSIONS
DIC
ECLAMPSIA
SEVERE
PREECLAMPSIA
CHAR HT
ALB-U
EDEMA
CHAR +
REVERSE
CAN BE
FATAL
RAPIDLY
OVERTERMINATED
VARIANT
HELLP
SD
PLAC MBS
TOXAM
RUPTURE
MARGIN VV
SUDDEN
PERIPARTAL
RESP
DIC
CHAR
AF EMBOL
OTH PERIPARTAL
COMPLIC
DIC MANIFS
BY MASSIV
SHOCK
OPER
DEATH
SD
POST PART
ANTPIT NEC
SHEEHAN SD
NEONATE
NORMOTHER
ATBIRTH
ASPIRATION
SD
INVAD
ONSET
PREM RUPT MBS
CHORIOAMNIONITIS
USUALLY
ASCENDING
IFC
COVERING CERVICALOS
LOWER UTER SEGMENT
COMPLETE
PARTIAL
MARGINAL
LOW LYING
ABRUPTIO
PREMATURE SEPARATION
PREM
INAB
EXTER AF
BLOSS
HYPOT
WAM
ANTPIT AF
SQUAM CARCIT
OF ANN ORIGIN
IN FUT ANN SPACES
VARICOSIS
NL

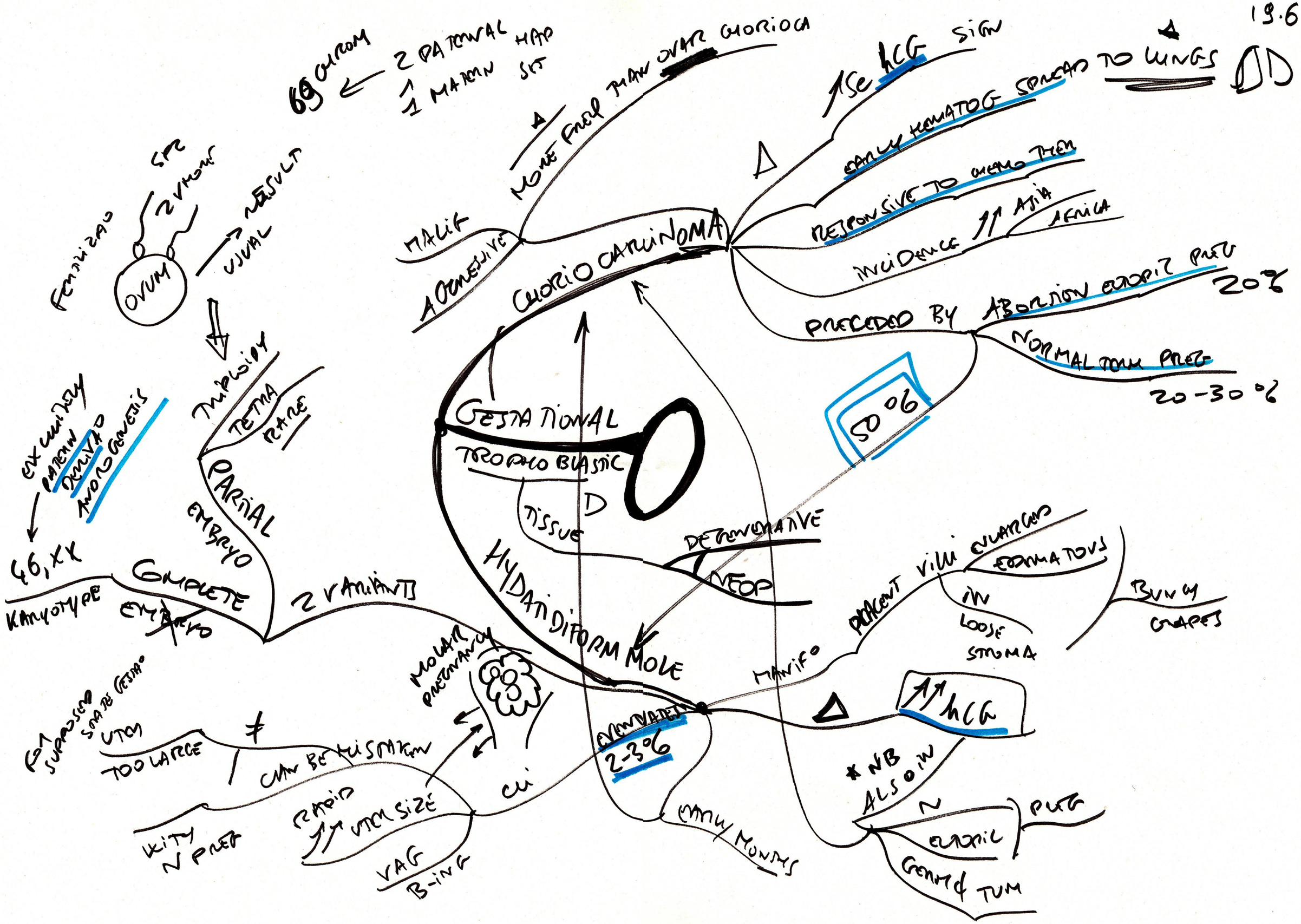
69 CHROM
2 PATERNAL
1 MATERN
HAP SET
MALIG
A GENESIS
MOLE PREG MAY OVAR CHORIOCA
CHORIOCARCINOMA
↑↑ hCG SIGN
EARLY HEMATOG SPREAD TO LUNGS
RESPONSIVE TO CHEMO THEN
INCIDENCE ↑↑ ASIA
AFRICA
PRECEDED BY ABORTION ECTOPIC PREG
20%
NORMAL TERM PREG
20-30%
50%
GESTATIONAL
TROPHOBLASTIC
TISSUE
DETERMINATIVE
NEOP
HYDATIDIFORM MOLE
FERTILIZED
SPERM
2 VARIANT
OVUM
RESULT
USUAL
TRIPLOIDY
TETRA
PARTIAL
EMBRYO
EX UNIPARENTAL
PATERN
DERIVED
MONOGENESIS
46, XX
KARYOTYPE
COMPLETE
EMBRYO
2 VARIANTS
MOLAR PRETERMANCY
CU
CAN BE REMOVED
TOO LARGE
UTER
RAPID
↑↑ UTER SIZE
VAG B-ING
VITY
N PREG
PRESENT
VILLI
EDEMATOUS
IN LOOSE STROMA
BUNCH GRAPES
MANIFO
↑↑ hCG
* NB ALSO IN
N
ECTOPIC
PREG
GENITAL TUM
CRANIAL MONTHS
2-3%

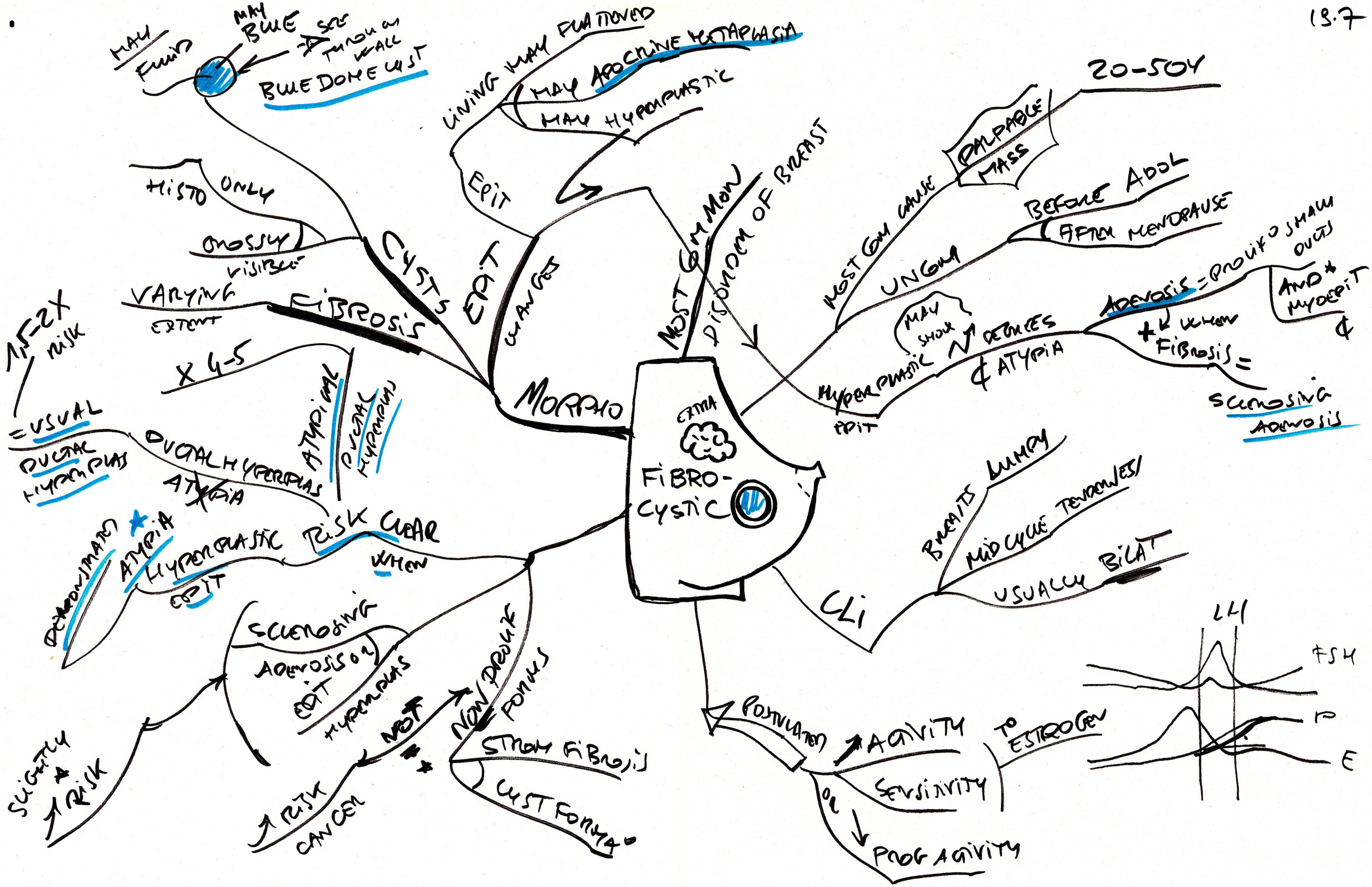
MAY FLUID
MAY BLUE
SEE THROUGH WALL
BLUE DOME CYST
LINING MAY FLATTENED
MAY APOCRINE METAPLASIA
MAY HYPERPLASTIC
EPIT
CYSTS
HISTO ONLY
GROSSLY VISIBLE
FIBROSIS
VARYING EXTENT
X 4-5
1.5-2X RISK
= USUAL
DUCTAL HYPERPLAS
DUCTAL HYPERPLAS
ATYPIA
ATYPICAL
DUCTAL HYPERPLAS
DEMONSTRATED ATYPIA
HYPERPLASTIC EPIT
RISK CLEAR WHEN
EPIT
MORPHO
EPIT CHANGES
MOST COMMON DISORDER OF BREAST
EXTRA
FIBRO-CYSTIC
MOST COM CAUSE
PALPABLE MASS
20-50Y
UNCOMM
BEFORE ADOL
AFTER MENOPAUSE
HYPERPLASTIC EPIT
MAY SHOW DEGREES OF ATYPIA
ADENOSIS = PROLIFERATION OF SMALL DUCTS
AND MYOEPIT
+ WHEN FIBROSIS =
SCLEROSING ADENOSIS
CLI
BREAST LUMPY
MID CYCLE TENDERNESS
USUALLY BILAT
SCLEROSING ADENOSIS OR EPIT HYPERPLAS
SLIGHTLY ↑ RISK
↑ RISK CANCER
NOT
NON PROLIF FORMS
STROMA FIBROSIS
CYST FORMATION
POSITIVE ↑ ACTIVITY
SENSITIVITY
TO ESTROGEN
OR ↓ PROG ACTIVITY
LH
FSH
P
E

NL

SCH

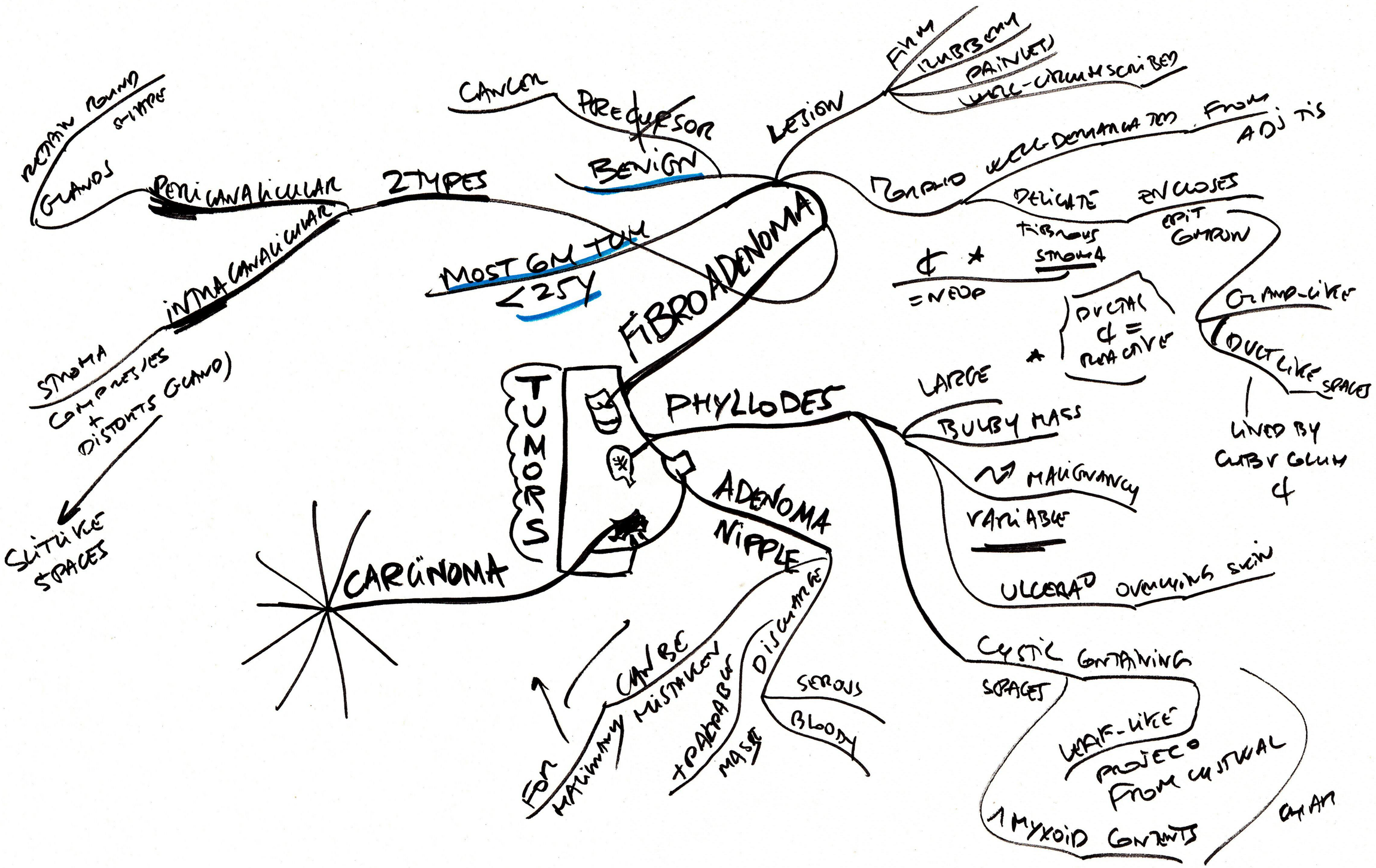
FIBROADENOMA
2 TYPES
PERICANALICULAR
INTRACANALICULAR
GLANDS
RETAIN ROUND SHAPE
STROMA COMPRESSES + DISTORTS GLAND
SLITLIKE SPACES
MOST COMMON TUMOR <25Y
BENIGN
PRECURSOR
CANCER
LESION
FIRM
RUBBERY
PAINLESS
WELL-CIRCUMSCRIBED
BORDER WELL-DEMARCATED FROM ADJ TIS
DELICATE FIBROUS STROMA
ENCLOSES EPIT GROWTH
GRAND-LIKE
DUCT-LIKE SPACES
LINED BY CUBOIDAL CELLS
DUCTAL CA = PREA CANCER
CA = NEOP
TUMORS
PHYLLODES
LARGE BULBY MASS
MALIGNANCY VARIABLE
ULCERATED OVERLYING SKIN
CYSTIC CONTAINING SPACES
LEAF-LIKE PROJECTIONS FROM CYSTICAL CHAMB
MYXOID CONTENTS
ADENOMA NIPPLE
DISCHARGE
SEROUS
BLOODY
TRACTABLE MASS
CAN BE MISTAKEN FOR MALIGNANCY
CARCINOMA

NL

SCM

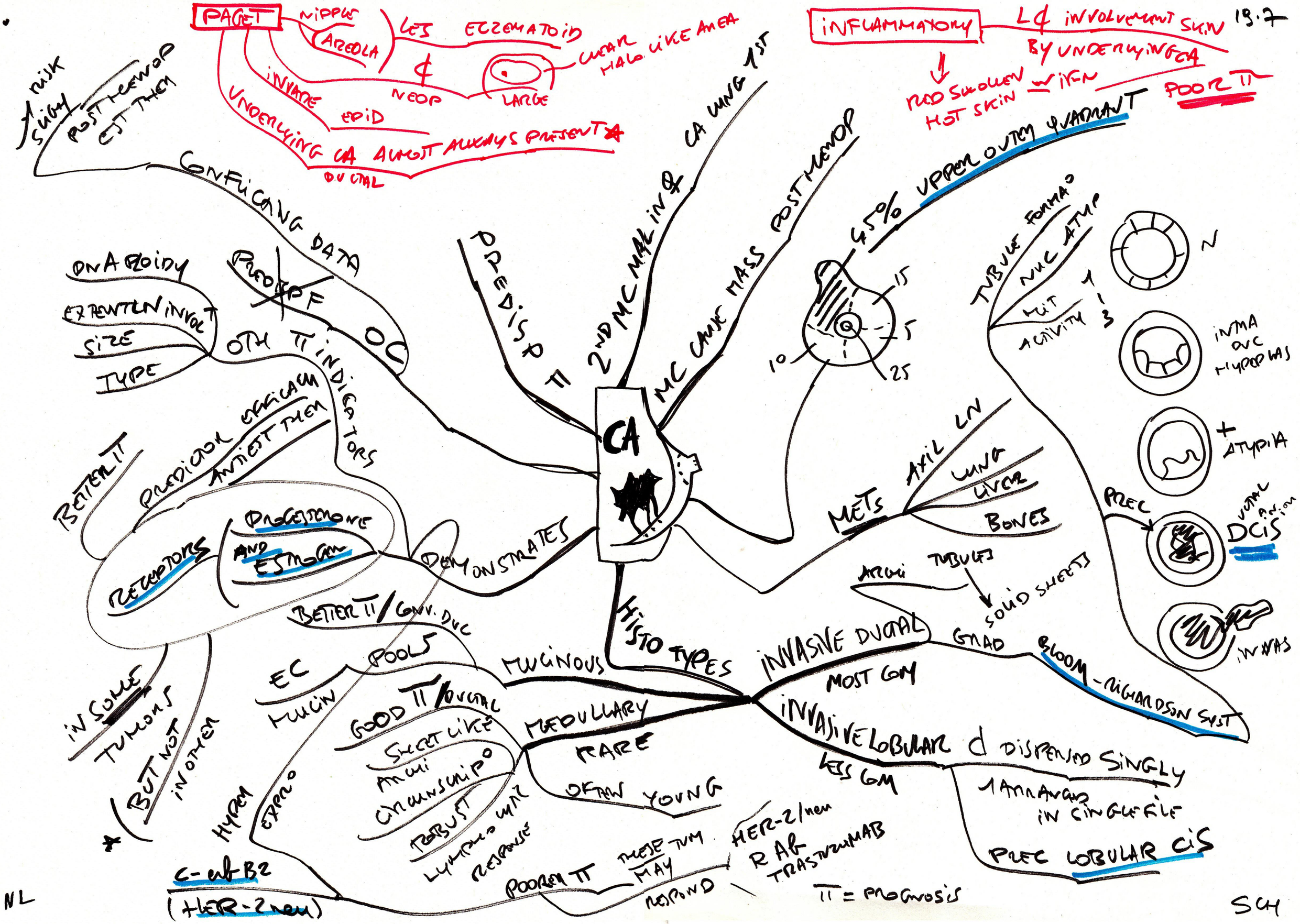
CA
PAGET
NIPPLE
AREOLA
LES ECZEMATOID
CLEAR HALO LIKE AREA
LARGE
NEOP
INVADE
EPID
UNDERLYING CA ALMOST ALWAYS PRESENT
DUCTAL
INFLAMMATORY
L/C INVOLVEMENT SKIN
BY UNDERLYING CA
RED SWOLLEN HOT SKIN
IFN
POOR TT
19.7
RISK
SKIN
POST MENOP
EST THEN
CONFLICTING DATA
OC
DNA PLOIDY
PROGRF
EXTENT LN INVOL
SIZE
TYPE
OTH TT INDICATORS
PREDISP TT
2ND MC MAL IN CA UNIG 1ST
MC CAUSE MASS POST MENOP
45% UPPER OUTER QUADRANT
15
5
10
25
TUBULE FORMAT
NUC ATYP
MIT ACTIVITY
1
3
N
INTRA DUC HYPERPLAS
+ ATYPIA
PREC
DUCTAL CARCINOMA DCIS
INVAS
METS
AXIL LN
LUNG
LIVER
BONES
BETTER TT
PREDICTOR ERRICAM
ANTIEST THEN
RECEPTORS
PROGESTERONE AND ESTROGEN
DEMONSTRATES
BETTER TT / GRV. DUC
IN SOME TUMORS
BUT NOT IN OTHER
EC
MUCIN
POOLS
MUCINOUS
HISTO TYPES
INVASIVE DUCTAL
MOST COM
ARCHI
TUBULES
SOLID SHEETS
GRAD
BLOOM-RICHARDSON SYST
GOOD TT / DUCTAL
SHEET LIKE ARCHI
CIRCUMSCRIPTO
TERBUST
LYMPHOCYTE RESPONSE
MEDULLARY
RARE
OFTEN YOUNG
INVASIVE LOBULAR
LESS COM
DISPERSED SINGLY
1 ARRANGED IN SINGLE FILE
PREC LOBULAR CIS
HYPER
EXPRO
C-erbB2
(HER-2 neu)
POOR TT
THERE TUM MAY RESPOND
HER-2/neu
RAR
TRASTUZUMAB
TT = PROGNOSIS
NL
SCH

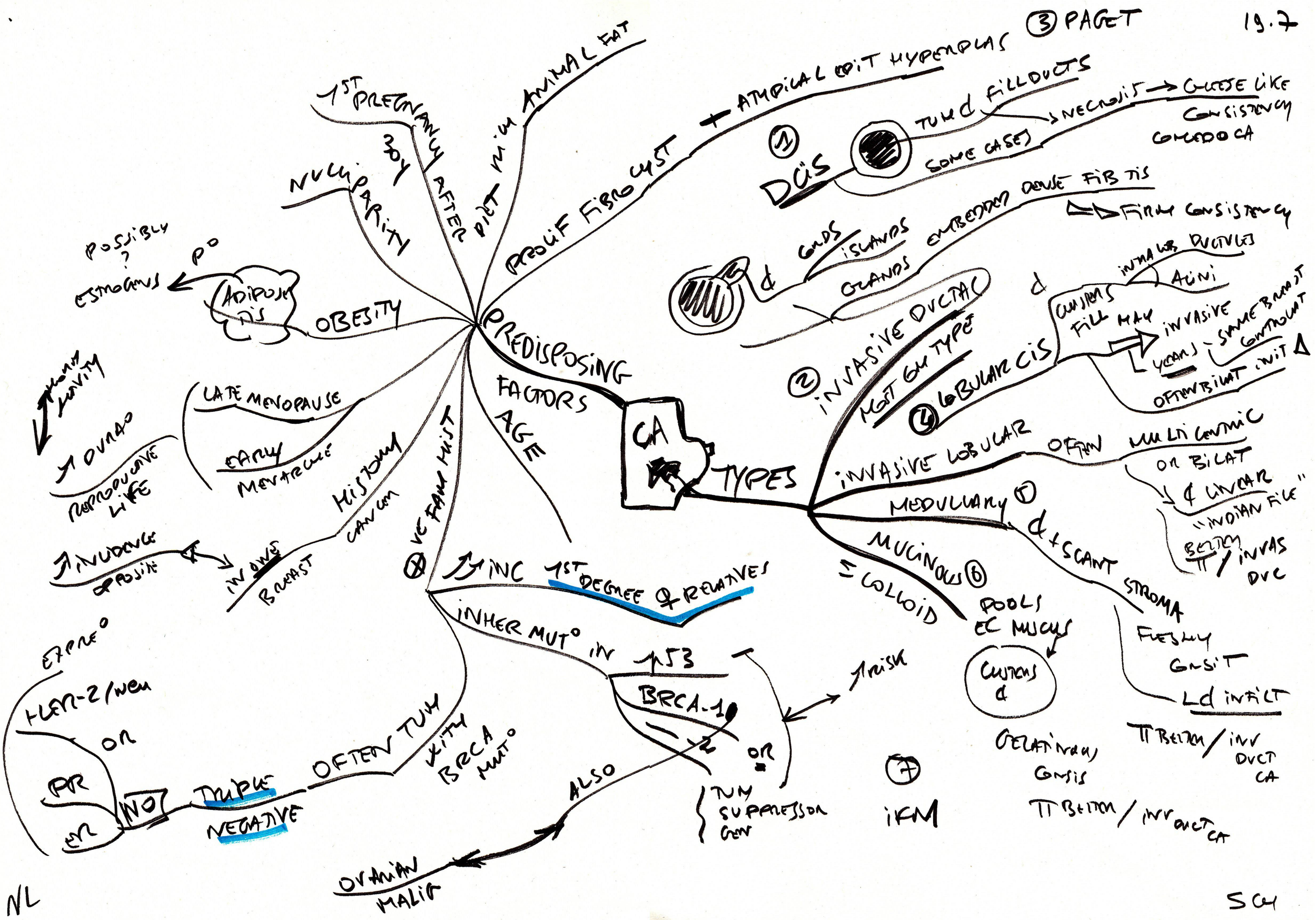
CA
TYPES
PREDISPOSING FACTORS
AGE
↑ INC 1ST DEGREE & RELATIVES
INHER MUT° IN ↑53
BRCA-1
-2
OR
↑risk
TUM SUPPRESSOR GEN
ALSO
OVARIAN MALIG
⊗ VE FAM HIST
HISTORY CANCER
INV OVE BREAST
↑ INVASIVE & POSITIVE
EXPRE°
HER-2/NEU
OR
PR
ER
NO
TRIPLE NEGATIVE
OFTEN TUM WITH BRCA MUT°
LATE MENOPAUSE
EARLY MENARCHE
↑ OVAR° REPRODUCTIVE LIFE
↑ HORMONAL ACTIVITY
OBESITY
ADIPOSE TIS
POSSIBLY ? PO
ESTROGENS
NULLIPARITY
3 OR
1ST PREGNANCY AFTER 18
HIGH ANIMAL FAT DIET
PROLIF FIBROCYST + ATYPICAL EPIT HYPERPLAS
③ PAGET
① DCIS
TUM & FILL DUCTS
SOME CASES → NECROSIS → CHEESE LIKE CONSISTENCY COMEDO CA
& GLDS
ISLANDS
GLANDS EMBEDDED DENSE FIB TIS
FIRM CONSISTENCY
② INVASIVE DUCTAL MOST COM TYPE
& CONTAINS FILL MAY INVASIVE
INTRALOB DUCTULES
ACINI
④ LOBULAR CIS
YEARS - SAME BREAST CONTROLAT
OFTEN BILAT INVIT
INVASIVE LOBULAR
OFTEN MULTICENTRIC OR BILAT
& LINEAR "INDIAN FILE"
BETTER TT / INVAS DUC
MEDULLARY ⑤
& + SCANT STROMA
MUCINOUS ⑥
= COLLOID
POOLS EC MUCUS
CONTAINS &
GELATINOUS CONSIS
TT BETTER / INV DUCT CA
FLESHY CONSIT
LYMPH INFILT
TT BETTER / INV DUCT CA
⑦ IFM

NL

SCH