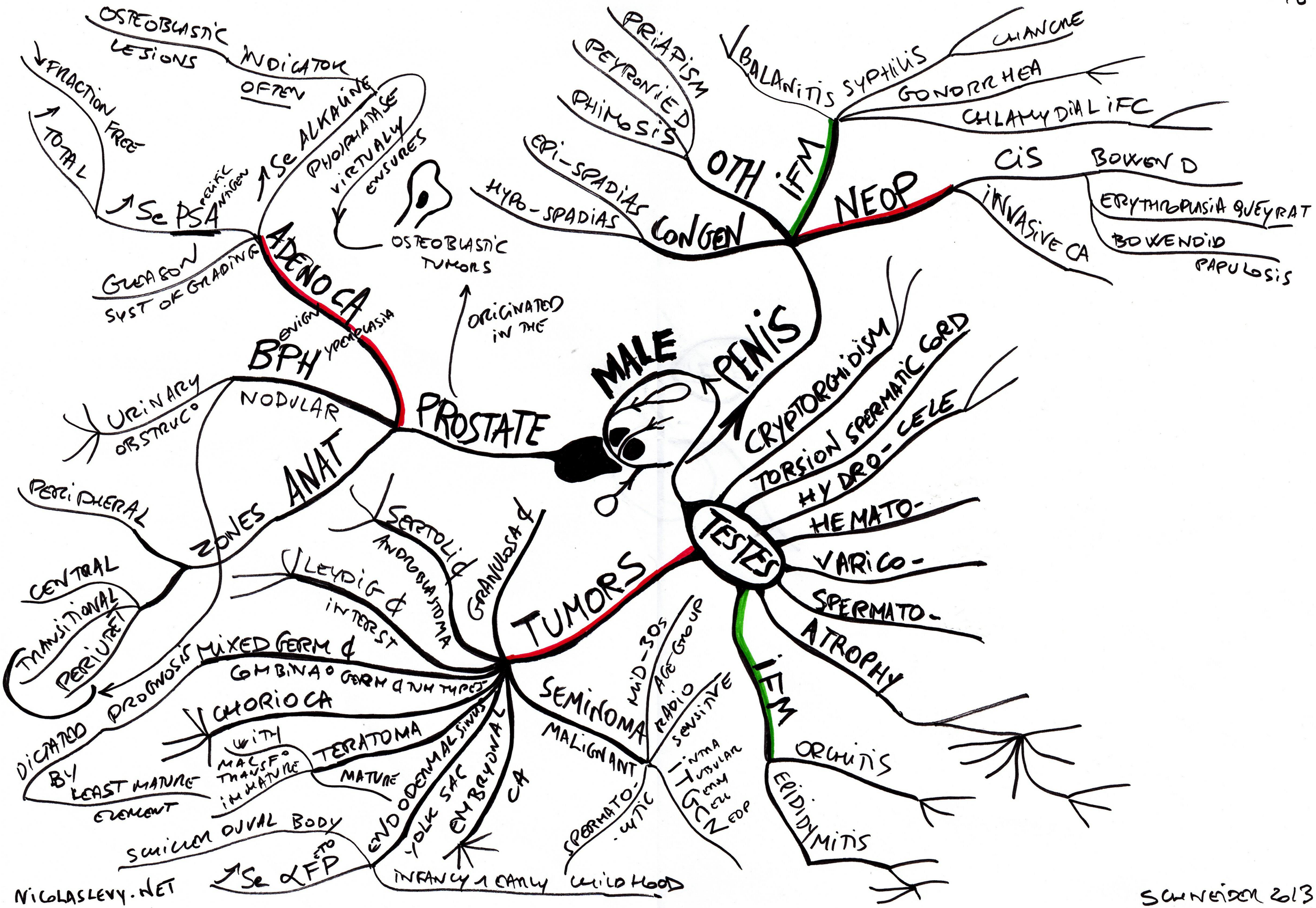
MALE
PENIS
OTH
IFM
PRIAPISM
PEYRONIE'D
PHIMOSIS
BALANITIS
SYPHILIS
CHANCRE
GONORRHEA
CHLAMYDIAL IFC
Ccongen
HYPO-SPADIAS
EPI-SPADIAS
NEOP
CIS
BOWEN'D
INVASIVE CA
ERYTHROPLASIA QUEYRAT
BOWENOID PAPULOSIS
PROSTATE
ORIGINATED IN THE
OSTEOBLASTIC TUMORS
ADENO CA
PSA specific antigen
Se PSA
Se ALKALINE PHOSPHATASE
VIRTUALLY ENSURES
OSTEOBLASTIC LESIONS
INDICATOR OFTEN
FRACTION FREE
TOTAL
GLEASON
SYST OF GRADING
BPH benign hyperplasia
NODULAR
URINARY OBSTRUC°
ANAT
ZONES
PERIPHERAL
CENTRAL
TRANSITIONAL
PERIURET
PROGNOSIS
DICTATED BY LEAST MATURE ELEMENT
TUMORS
SERTOLI & ANDROBLASTOMA
LEYDIG & INTERST
GRANULOSA &
MIXED GERM & COMBINA° GERM & NON TYPES
CHORIO CA
WITH MALIGN TRANSFO IMMATURE
TERATOMA
MATURE
ENDODERMAL SINUS
YOLK SAC
EMBRYONAL CA
INFANCY & EARLY CHILDHOOD
Se αFP ETO
SCHILLER DUVAL BODY
SEMINOMA
MAL-30S
AGE GROUP
RADIO SENSITIVE
MALIGNANT
SPERMATO-CYTIC
TGCN
INTRA TUBULAR GERM CELL NEOP
TESTES
HEMATO-
VARICO-
SPERMATO-
ATROPHY
IFM
ORCHITIS
EPIDIDYMITIS
CRYPTORCHIDISM
TORSION SPERMATIC CORD
HYDRO-CELE

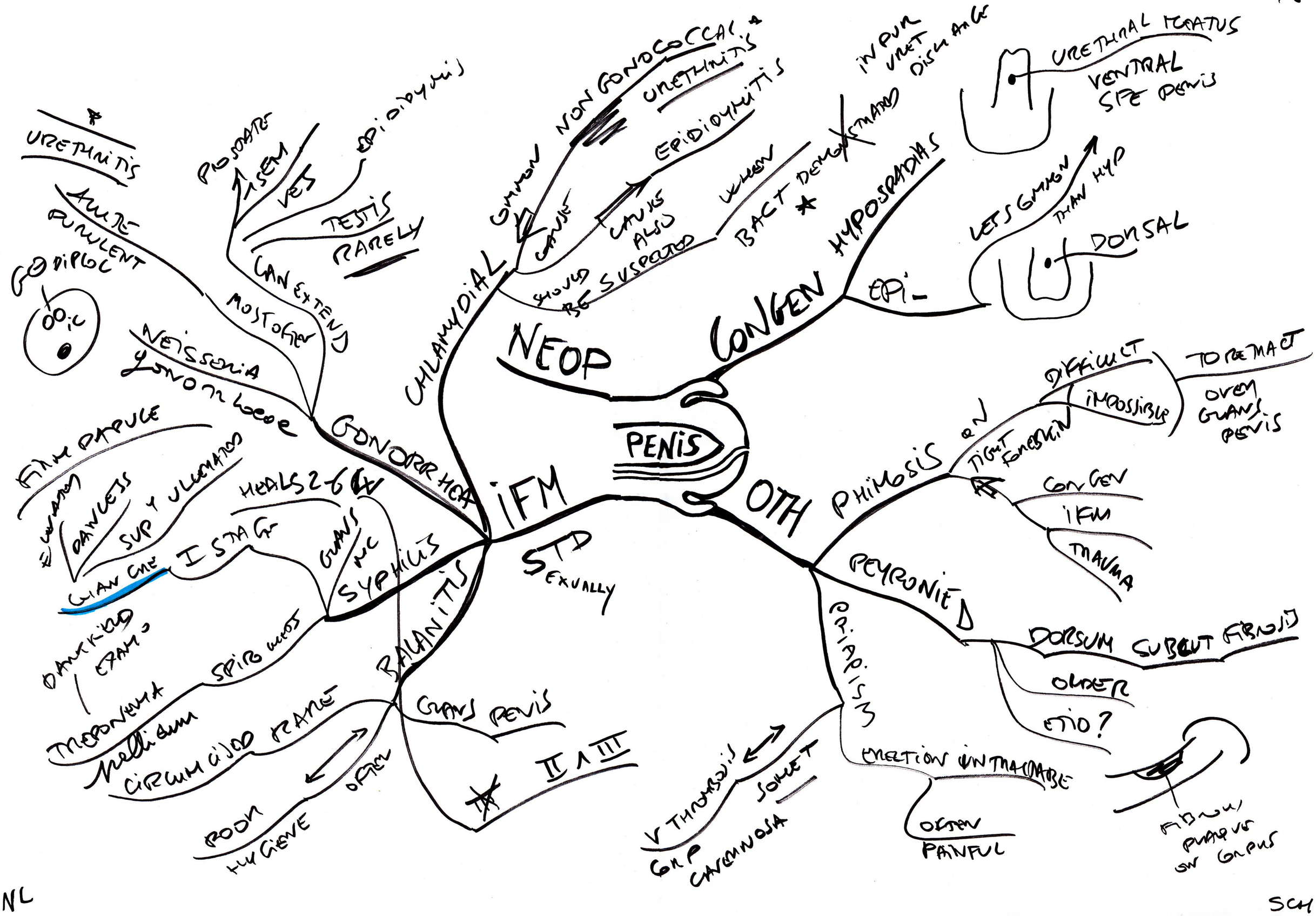
PENIS
NEOP
CONGEN
IFM
OTH
GONORRHOEA
URETHRITIS
ACUTE PURULENT
GO DIPLOC
OOIC
NEISSERIA GONORRHOEAE
MOST OFTEN
CAN EXTEND
PROSTATE
ASEM
VES
EPIDIDYMIS
TESTIS RARELY
CHLAMYDIAL
COMMON CAUSE
SHOULD BE SUSPECTED
NON GONOCOCCAL URETHRITIS
EPIDIDYMITIS
CAUSES ALSO
WOMEN
BACT DEMONSTRATED
IN PUR URET DISCHARGE
HYPOSPADIAS
EPI-
URETHRAL MEATUS
VENTRAL SPE PENIS
LETS GO MORE THAN HYP
DORSAL
FILM PAPULE
EVERYWHERE
PAINLESS
SUP Y ULCERATION
HEALS 2-6 W
GIANT CHE
I STAGE
GUANS NC
SYPHILIS
DARKFIELD EXAM
TREPONEMA PALLIDUM
SPIROCHETE
BALANITIS
CIRCUMCISED PENILE
POOR HYGIENE
OFTEN
GUANS PENIS
II & III
STD
SEXUALLY
PHIMOSIS
DIFFICULT
IMPOSSIBLE
TO RETRACT
OVER GLANS PENIS
ON TIGHT FORESKIN
CONGEN
IFM
TRAUMA
PEYRONIE'S
PRIAPISM
DORSUM SUBCUT FIBROSIS
OLDER
ETIO?
ERECTION INTRACTABLE
OFTEN PAINFUL
FIBROUS PLAQUE ON GLANS
V THROMBOSIS
GRP CAVERNOSA
SOMET

NL

SCH

NEOPLASMS PENIS

INVASIVE CARCINOMA

- HPV ↔ OFTEN *
  - 16
  - 18
  - 31
  - 33
- PREDISP F
  - POOR PERSONAL HYGIENE
- INCIDENCE ↑
  - C AMERICA
  - AFRICA
  - FAR EAST
- RARE IN CIRCUMCISED
- MOST FREQ SCC (QUAMOUS)

CIS (ARCINOMA IN SITU)

- UNCIRCUMCISED MOST CM
- RELATED TO
  - SQUAMS
  - ACCUMULATION AND "SMEGMA" DEBRIS IGM
  - IFC
    - HPV
      - HIGH RISK
      - 16
      - 18
      - IV
- ÷ HISTORICALLY
  - FULL THICKNESS ATYPIA SQUAMS OPIT
  - PLAQUE
    - SINGLE
      - DEMARCATED CHAMPLY
      - ERYTHEMATOUS OR GRAYISH
    - MOST OFTEN
      - SHAFT PENIS
      - SCROTUM
    - BOWEN'S D
    - ERYTHROPLASIA QUEYRAT
    - BOWENOID PAPULOSIS
  - PLAQUES SINGLE (OR MULTIPLE)
    - NO GLANS
    - PREPUCE
  - LESIONS MULTIPLE
    - VERRUCOID = WART LIKE
    - ~ CONDYLOMA
    - RESEMB ACUMINATUM
  - * YOUNG ADULT AGE GROUP MEAN

NL

SCH

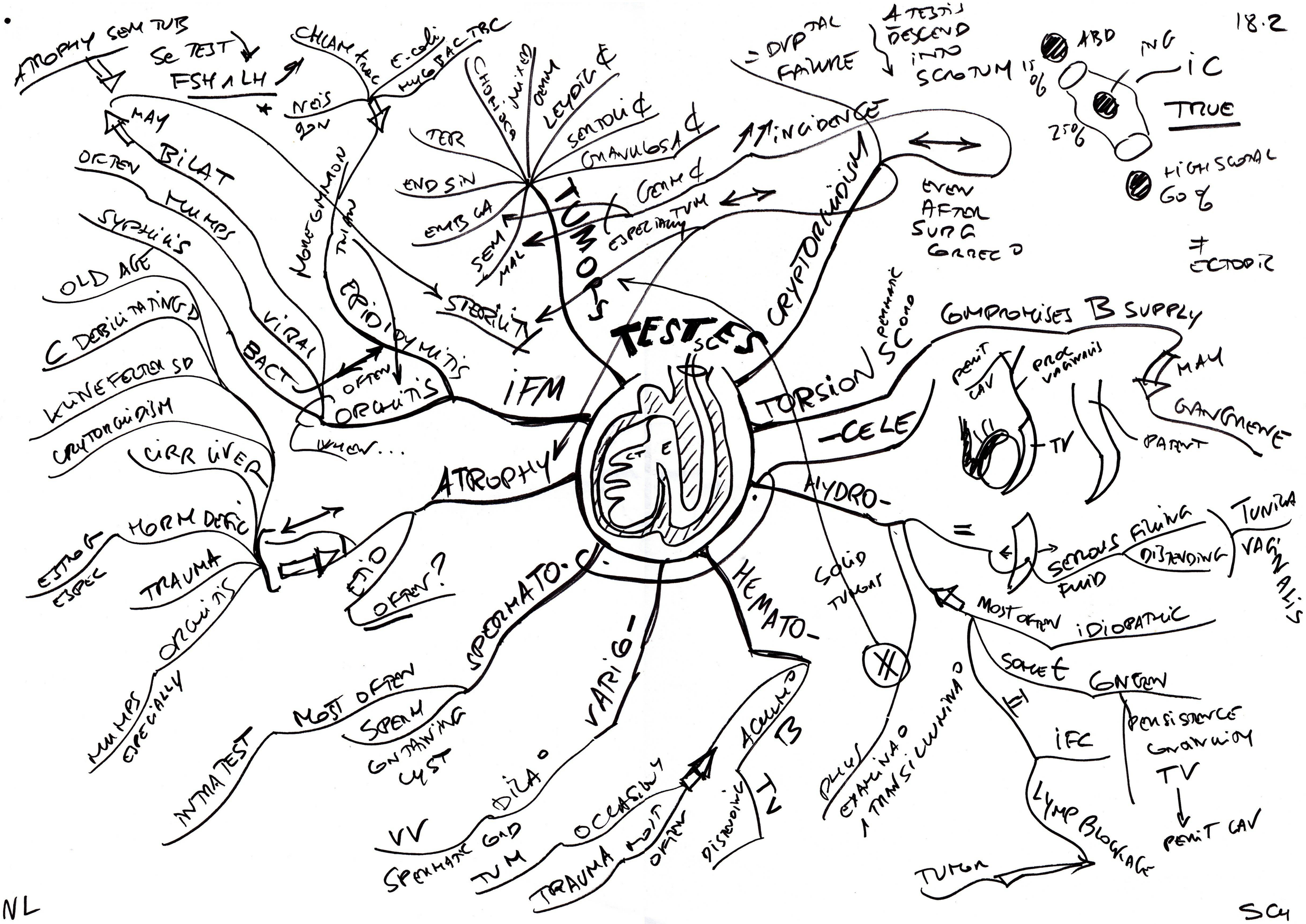
TESTES
ATROPHY SEM TUB
Se TEST
FSH & LH
CHLAM trac
E. coli
HYGBACTRC
MAY
BILAT
OFTEN
MUMPS
SYPHILIS
OLD AGE
C DEBILITATING D
KLINEFELTER SD
CRYPTORCHIDISM
CIRR LIVER
VIRAL
BACT
MONONYMON
TRIAD
EPIDIDYMITIS
OFTEN
ORCHITIS
KNOW...
iFM
ATROPHY
HORMONAL
ESTROG ESPEC
TRAUMA
ORCHITIS
MUMPS ESPECIALLY
ETIO
OFTEN?
INTRA TEST
MOST OFTEN
SPERM GRANULOMA CYST
SPERMATO-C
VV
DILA
SPERMATIC CORD TUM
VARIC-
OCCASIONALY
TRAUMA MOST OFTEN
HEMATO-
ACUTE
B
DISTENDING
TV
STERILITY
TUMORS
SEM
MAL
ESPECIALLY
TER
END SIN
EMB CA
CHORIOCA
JUVENILE
GERM
LEYDIG C
SERTOLI C
GRANULOSA C
GERM C
INCIDENCE
↑↑
= DYSPTAL FAILURE
4 TESTIS DESCEND INTO SCROTUM 15%
ABD
ING
IC
TRUE
25%
HIGH SCROTAL
60%
≠ ECTOPIC
EVEN AFTER SURG CORRECTD
CRYPTORCHIDISM
PERMANENT SCOND
COMPROMISES B SUPPLY
TORSION
-CELE
PENIT CAV
PROC VAGINALIS
TV
PATENT
MAY
GANGRENE
HYDRO-
SERROUS FLUID
FILLING
DISTENDING
TUNICA VAGINALIS
MOST OFTEN
IDIOPATHIC
SOLID TUMOR
PLUS EXAMINATION TRANSILLUMINATION
SCROTUM
GRAVITY
PERSISTENCE
GRAVITY
TV
PENIT CAV
iFC
LYMP BLOCKAGE
TUMOR

NL

SCH

TESTICULAR TUMORS
SEMINOMA
35
MID 30s AGE GROUP
INC
ENLARGEMENT
PAINLESS
↑ Se hCG
SAME ↔ CHORIOCA
OTM
TESTES
SOME ↑
VERY RADIOSENSITIVE
CAN OFTEN BE CURED
EVEN WHEN METS TO ABD LN
RARE
OLDER
PROGNOSIS EXCELLENT
MOST COM
ANALOG DYSGERMINOMA
OVARY
FAR LESS COMMON THAN IN OVARY
CONTEMPART
SPERMATOCYTIC
UNRELATED TO UNDESCENDED
≃ OVARY
PLEOMORPHIC
ITGCN
MAY BE PRESENT
OFTEN METS AT PRESENTATION
hCG ↑ OFTEN
PROGNOSIS
SOMEWHAT YOUNGER AGE INDEX CASE THAN SEMINOMA
GRANULOSA
GERM 90%
STROMAL SEX-CORD
MALIGNANT
EMBRYONAL CA
MALIGNANT
MUCH TRANSLOCATION
2nd MOST FREQ COMM
PRECURSOR LES
OFTEN INCIDENTAL IN BACKGROUND TUBULES
3 DISTINCT CELL TYPES
INTRA TUBULAR GERM CELL NEOPLASIA
NO
PAUCITY
ENDOC MANIFS
USUALLY BEN
SERTOLI
ANDROBLASTOMA
ENDODERMAL SINUS
≃ OVARY
PURE FORM
EXCLUSIVELY
INFANCY
ADULT FREQ
CAN ALSO CHILDHOOD
YOLK SAC MALIGNANT
EMB LAYERS
2 OR MORE
↑ Se αFP
MOST
HCC
CHAS SCHILLER DUVAL BODY
MC TUM IN THIS AGE GROUP
MIXED
GLOMERULOID
ITGCN
MAY BE
CANT ISLANDS
CILIAT EPIT
LIVER
NEUROGLIA
EMB CUT
OR SMALL ROUND SCM
TERATOMA
MOST FREQ MALIGNANT
MULTI TIS TYP
UNLIKE IN ♀
MATURE
IMMATURE
ALMOST ALWAYS MAL
WITH MALIGNANT TRANSFORMAD
ONE OF THE TIS
SCC
epidermoid CARCIN
OFTEN PRIMIT NEURAL e OFTEN MAL
CHORIOCA
MAL GERM
≃ OVARY
2-3 DECADES
↑ Se hCG
CAN OCCUR AS AN ELT OF OTHER GERM CELL TUM
CHORIOSEMINOMA
MIXED GERM CELL TUMS
MORE THAN ONE HISTO TYPE MIXES OF
COMBINA
PROGNOSIS DICTATED BY LEAST MATURE ELEMENT
LEYDIG CELL
PRECOC PUBERTY
Gynaecomastia
INTERST
SOME ↑ ANDROGEN PRODUCING
OFTEN MUST OCC BEN
INTRA CYTOP BRIDGE CRYSTALS
≃ SERT CEL OVARY
CS
EST
(BOTH AND)
GYNAECOMASTIA ADULTS
FIBROUS SEPTA SEPARATE NESTS
+ PROMINENT NUCLEOLI
CENTRALLY LOCATED NUCLEI
LARGE ¢ INFILTRATE
¢ BORDERS INDISTINCT
+ PROM IN LYMPHOID RESPONSE
CYTO
SYNCYTIOTROPHOBLASTS
¢ ≃
PLACENTA
NL

	P	T	C
FOCAL ATROPHY	++	+	
AI			
CI	+	+	
BPH		++	
HIGH GRADE PIN	+		
CA	+		

WATCHING

PROSTATE

ANAT

SHAPE

SIZE

CHESTNUT

SURROUNDS URETHRA

BASE BLADDER

4 GROUPINGS GLANDS

ZONES

(A) CENTRAL

B FIBROMUSC

(C) TRANSITIONAL

(D) PERIPHERAL

E PERIURETHRAL

ZONES

PERIURETHRAL (ANT)

TRANSITIONAL (MID)

CENTRAL (LAT)

BPH

PERIPHERAL ZONE OF GLANDS

DRAINING INTO DUCTS

ENTERING URETHRAL SINUS CLOSE TO VERUMONTANUM (POST)

CA

EJACULATORY DUCT

ADENO CA

COMMON ++

NEW THAP!

HYDRO URETER

NEPHROSIS

BANG

ENLARGED BLADDER

MUSC TRABECULATE

CONGENITAL

NODULAR BPH

OLDER

UNIVERSAL

MOST FREQ CAUSE UT OBSTRUCTION

NO REL° WITH CANCER

CAN COEXIST

DIRECT ACTION DHT

ALSO CAUSED BY

5α-REDUCTASE TYPE 2

APPLICATION TTT

T

PROMOTE EXPRESS FOR DHT

AGE RELATED ↑ ESTROGENS

URIN OBST°

MUS HYPERTROPHY BLADDER

DISTEND

UT IFC

HESITANCY

DYSURIA

INCOMPLETE BLADDER EMPTYING

FREQUENCY

MOST COMM

COMPRESSED URETHRA

SIDE TO SITE NODULAR

VERTICAL SLIT

GROSS

HYPERPLASIA

RUBBERY

FIBROMUSC

STROMAL GLANDULAR ELEMENT

WHITE BODY

MICROSCOPIC

TRANSIT

PERIURETHRAL

INVOLVE GROUPAGE GLANDS

NL

SCH

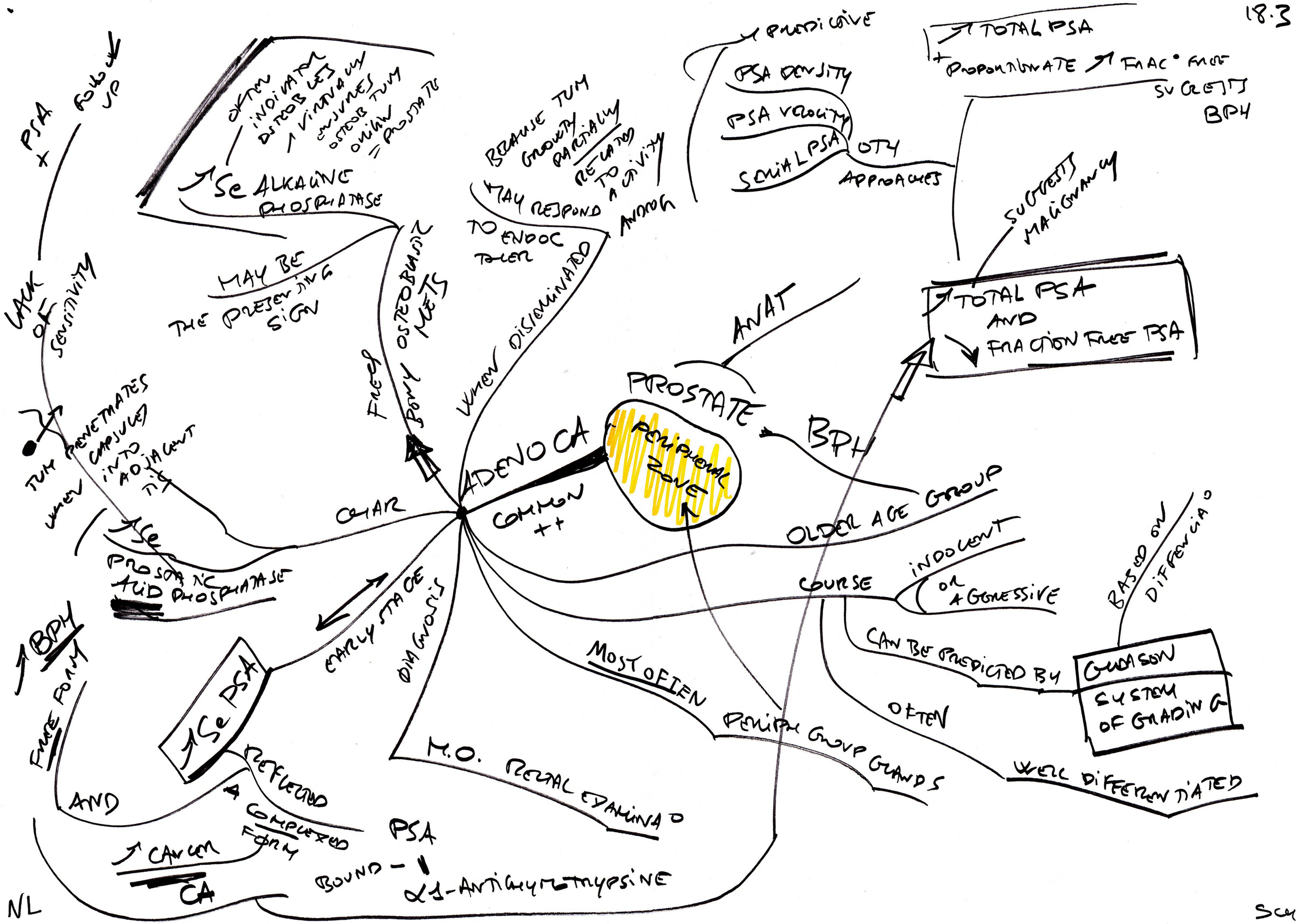
PSA + FOLLOW UP
LACK OF SENSITIVITY
OFTEN INDICATES DISEASE LESS AGGRESSIVE THAN OSTEOBLASTIC ONLY = PROSTATE
↑ Se ALKALINE PHOSPHATASE
MAY BE THE PRESERVING SIGN
BECAUSE TUM GROWTH PARTIALLY RELATED TO ACTIVITY
MAY RESPOND TO ENDOC THER
ANDROG
PREDICTIVE
PSA DENSITY
PSA VELOCITY
SERIAL PSA
OTH APPROACHES
↑ TOTAL PSA
+ PROPORTIONATE ↑ FRAC • FREE
SUGGESTS BPH
SUGGESTS MALIGNANCY
TOTAL PSA AND FRACTION FREE PSA
ANAT
PROSTATE
BPH
FREQ BONY OSTEOBLASTIC METS
WHEN DISEMINATED
ADENO CA
PERIPHERAL ZONE
COMMON ++
TUM PENETRATES CAPSULE INTO ADJACENT TIS
WHEN
CHAR
OLDER AGE GROUP
↑ Se PROSTATIC ACID PHOSPHATASE
COURSE
INDOLENT OR AGGRESSIVE
BASED ON DIFFERENTIATION
CAN BE PREDICTED BY
GLEASON SYSTEM OF GRADING
EARLY STAGE DIAGNOSIS
MOST OFTEN PERIPH GROWP GLANDS
OFTEN
WELL DIFFERENTIATED
↑ BPH
FREE FORM
↑ Se PSA
REFLECTED
AND
COMPLEXED FORM
M.O. RECTAL EXAMINATION
↑ CANCER
CA
PSA BOUND - α1-ANTICHYMOTRYPSINE
NL
SCM