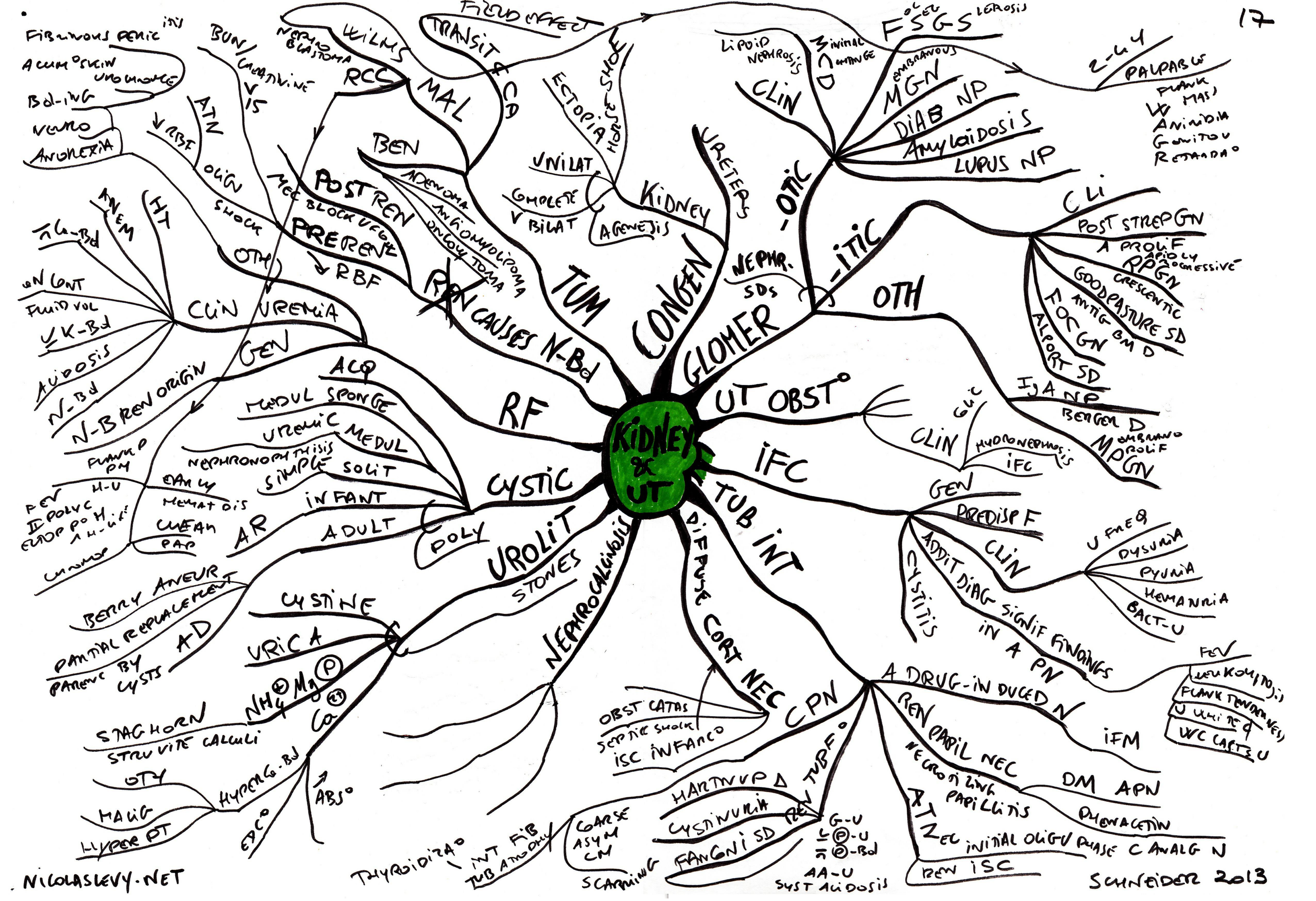
KIDNEY & UT
TUM
WILMS
NEPHROBLASTOMA
RCC
TRANSIT CD
MAL
BEN
ADENOMA
ANGIOMYOLIPOMA
ONCOCYTOMA
CONGEN
FIELD EFFECT
ECTOPIA
HORSESHOE
UNILAT
COMPLETE
BILAT
AGENESIS
KIDNEY
URETERS
GLOMER
MCD
MINIMAL CHANGE
LIPOID NEPHROSIS
CLIN
FSGS
FOCAL SEG GLOMERULOSIS
MGN
EMBRANOUS
DIAB NP
AMYLOIDOSIS
LUPUS NP
2-4 W
PALPABLE FLANK MASS
ANURIA
GROWTH RETARDATION
-OTIC
-ITIC
NEPHR. SDs
OTH
CLI
POST STREP GN
A PROLIF
RPGN
RAPIDLY PROGRESSIVE
CRESCENTIC
GOODPASTURE SD
ANTI GBM D
ANTI GBM
ALPORT SD
IgA NP
BERGER D
MPGN
MEMBRANO PROLIF
CLIN
GUC
HYDRONEPHROSIS
IFC
GEN
PREDISP F
CLIN
U FREQ
DYSURIA
PYURIA
HEMATURIA
BACT-U
CYSTITIS
ADDIT DIAG SIGNIF FINDINGS IN A PN
A DRUG-INDUCED N
FEV
LEUKOCYTOSIS
FLANK TENDERNESS
U URGENCY
WC CASTS U
IFM
REN PAPIL NEC
NECROTIZING PAPILLITIS
DM APN
PHENACETIN
RTZ EC
INITIAL OLIGU PHASE C ANALG N
REN ISC
TUB INT
IFC
UT OBST
RF
ACQ
MEDUL SPONGE
UREMIC MEDUL
NEPHRONOPHTHISIS
SIMPLE
SOLIT
CYSTIC
INFANT
ADULT
POLY
AR
FAMILY
MEMAT DIS
CLEAN
PAP
PKD
H-U
ADPKD
ADULT
CLIN
BERRY ANEUR
PARTIAL REPLACEMENT
PATIENT BY CYSTS
AD
UROLIT
STONES
NEPHROCALCINOSIS
CYSTINE
URIC A
NH4 Mg P
Ca
STAGHORN
STRUVITE CALCULI
HYPERCa. BJ
OTY
HALG
HYPER PT
EAC
ABS
THYROIDIZA
INT FIB
TUB ATROPHY
COARSE ASYM CM
SCARRING
DIFFUSE CORT NEC
OBST CATAS
SEPTIC SHOCK
ISC INFANCY
CPN
HARTNUP
CYSTINURIA
FANCONI SD
TUBF
G-U
P-U
P-Bd
AA-U
SYST ACIDOSIS
FIBROUS PENIS
ACUMOSKIN UNCHANGE
BD-ING
VOMIT
ANOREXIA
BUN/CREATININE
V IS
ATN
RBF
OLIG
SHOCK
OTH
MEC BLOCK URGT
POST REN
PRE REN
RBF
REN CAUSES N-Bd
ANEM
HT
Ca-Bd
ON CONT
FLUID VOL
K-Bd
AUDOSIS
N-Bd
N-B REN ORIGIN
CLIN
UREMIA
GEN
FLANK P
PM
PKD
H-U
ADPKD
ADULT
CLIN
NICOLASLEVY.NET
SCHNEIDER 2013

POTTER SEQUENCE

DEFORMED EXTREMITIES

HYPOPLASTIC LUNG

MULTIPLE FETAL AN

* CAUSE

OTH RESULTING CONDITIONS

PROX SYS FAILS TO EXCRETE FLUID SWALLOWED BY FETUS

OLIGOHYDRAMNIOS

= ↓ AF

WITH LIFE

COMPATIBLE

RARE

NB HYPER AMNIOS

↑ AF

DUOD ATRESIA

OR ↑ ↓

TYPE TRACHEO ESOP FISTULA

BLIND POUCH UPPER

LOWER

TRAC

COMPLETE BILAT

AGENESIS

UNILAT

KIDNEY

HORSESHOE

ECTOPIA

ON LOC

FALSE PELVIS

MUCH MORE COMMON THAN

ONE MISSING

CONGENIT AN UT

URETERS

ALONE

OR

PART OF A DUPLICATED ENTIRE COLLECTING SYS ON 1 SIDE

2 JOINED LOWER POLES

IMPINGEMENT URETERS

MAY CAUSE

UT OBSTO

- GS = GLOMERULOSCLEROSIS
- FSGS = FOCAL SEGMENTAL GS
- M = MEMBRANOUS
- GN = GLOMERULONEPHRITIS
- NP = NEPHROPATHY
- RP = RAPIDLY PROGRESSIVE
- MP = MEMBRANO PROLIFERATIVE
- F = FOCAL

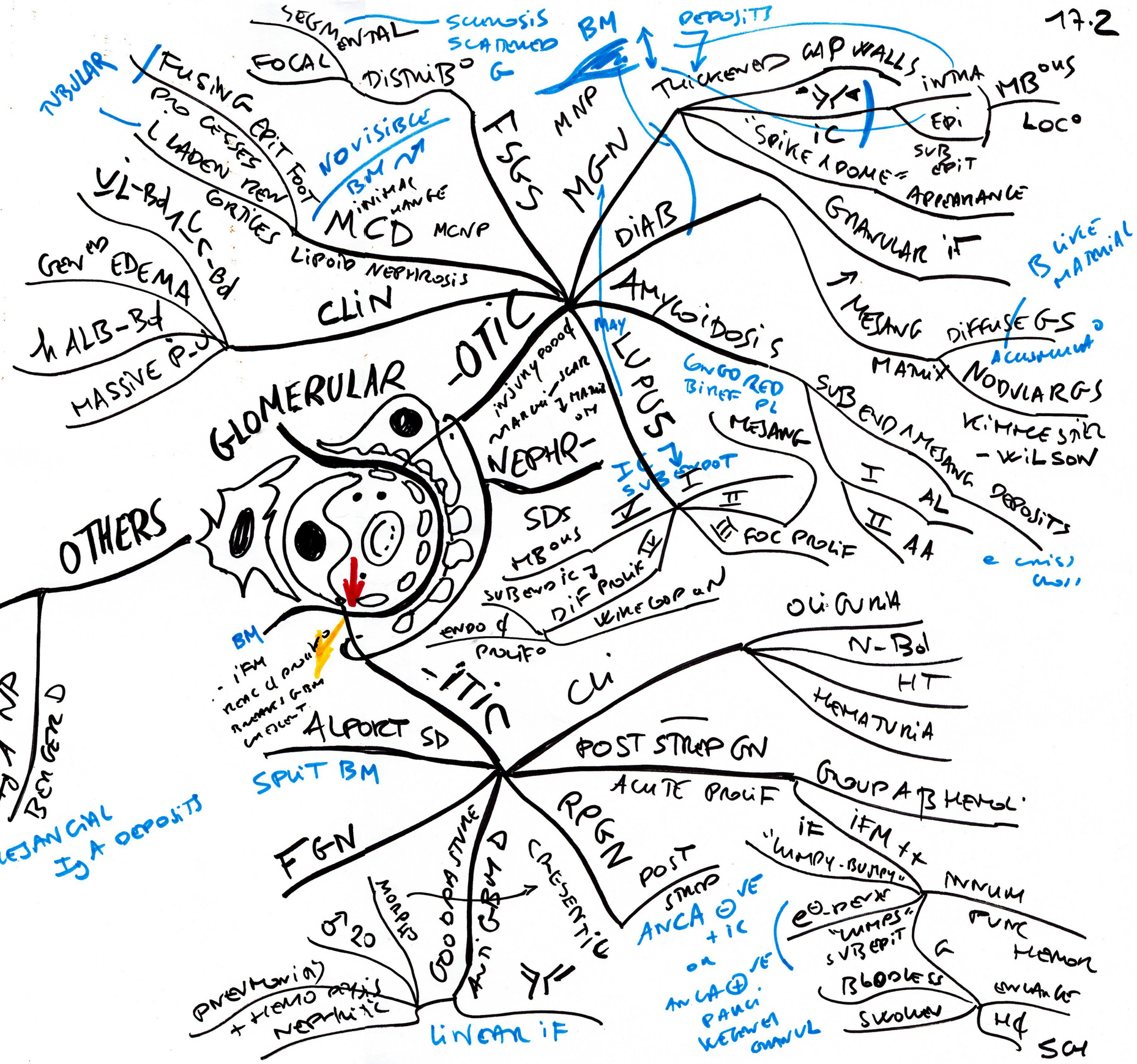

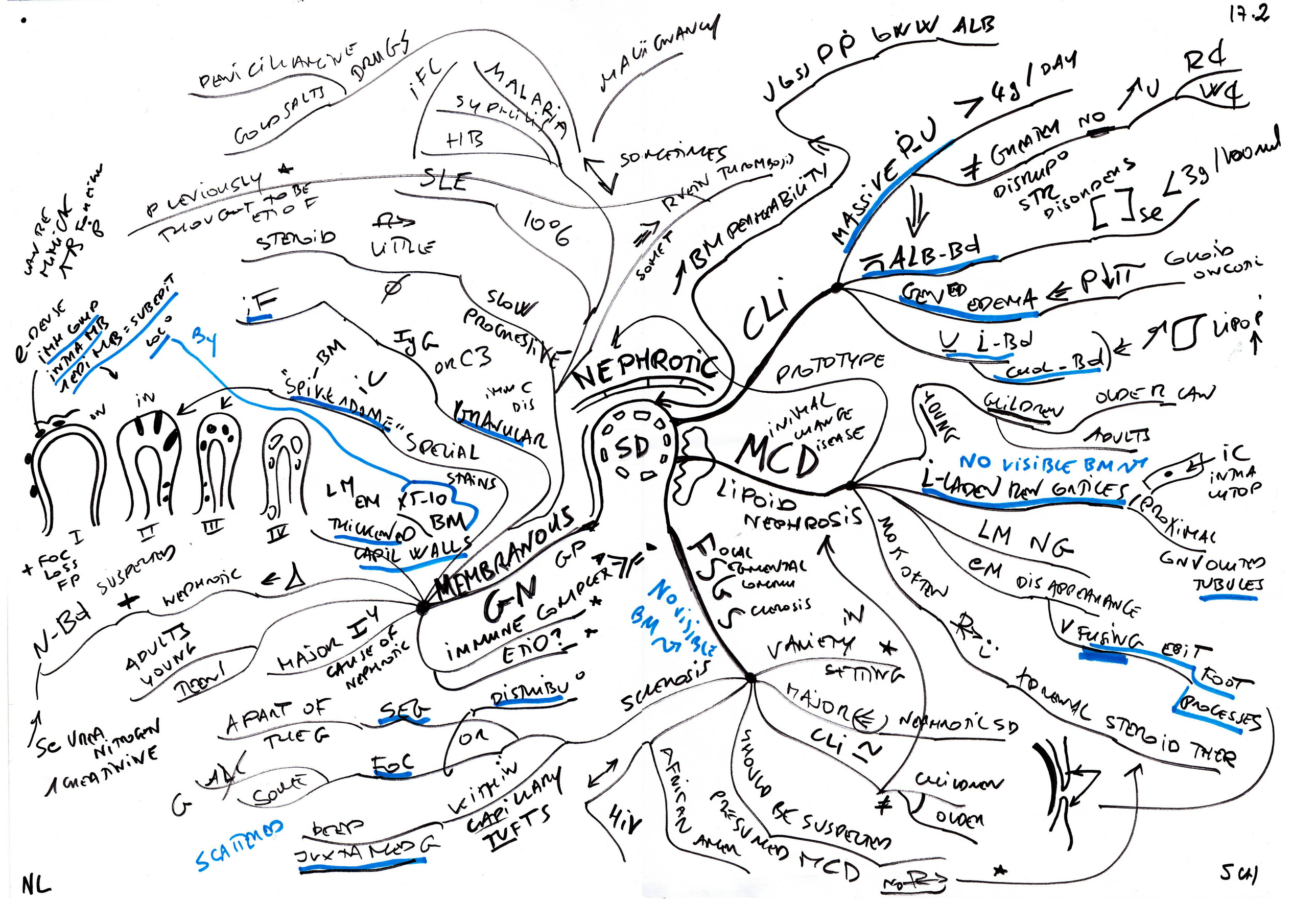
PENICILLAMINE
GOLD SALTS
DRUGS
IFC
MALARIA
SYPHILIS
HIB
MALIGNANCY
SOMETIMES
SLE
PREVIOUSLY THOUGHT TO BE ETIOF
STEROID
LITTLE
100%
RVEIN THROMBOSIS
SOMET
↑BM PERMEABILITY
JGSJ PP BKW ALB
MASSIVE P-U
>4g/DAY
≠ GNMRM
NO
↑U
RC
WC
DISRUPO STR
DISORDERS
[ ]se
<3g/100ml
ALB-Bd
GENED EDEMA
PTT
GLOB OWCONC
U L-Bd
CHOL-Bd
↑ LIPOP
CLI
PROTOTYPE
NEPHROTIC
SLOW PROGRESSIVE
IgG ON C3
IMM C DIS
MANULAR
IF
Ø
IC
"SPIKE ADAME" SPECIAL STAINS
LM EM XT-10
THICKENED BM CAPIL WALLS
MEMBRANOUS GN
GP
IMMUNE COMPLEX
ETIO?
MAJOR IY CAUSE OF NEPHROTIC
ADULTS
YOUNG
TEEN
N-Bd
NEPHROTIC
SUSPECTED
+ FOC LOSS FP
SC UREA NITROGEN
↑CREATININE
E-DENSE
IMM GMP
INMA MB
EPI MB = SUBEPIT
LOC
By
ON
IN
I
II
III
IV
SD
MCD
MINIMAL CHANGE DISEASE
LIPOID NEPHROSIS
YOUNG
CHILDREN
OLDER CAN
ADULTS
NO VISIBLE BM
L-LADEN FREE GRANULES
IC
INMA MTOP
PROXIMAL CONVOLUTED TUBULES
LM NG
EM DISAPPEARANCE
V FUSING
EPIT FOOT PROCESSES
MOST OFTEN
R: L:
TO NORMAL STEROID THER
FSGS
FOCAL SEGMENTAL GLOMM SCLEROSIS
NO VISIBLE BM
IN VARIETY
SETTING
MAJOR (≤) NEPHROTIC SD
CLI ≈
SCLEROSIS
CHILDREN
≠
OLDER
SHOULD BE SUSPECTED
PRESUMED MCD
NO R:
AFRICAN AMER
HIV
APART OF THE G
SEG
DISTRIBU
OR
FOC
SCATTERED
JUXTAMEDG
KITTIN
CAPILLARY TUFTS
G
AK
SOLE
NL
SCL

17.2

ICDEPOS° IN SUBENDOT LOC°
MAY MANIFEST
AS MBOUS GN

SC AP
OFTEN TBC
LEPROSY

H Φ

II MESANGIAL FORM — FAS^W G → ↑ PRANT MM
OFTEN SLIGHT P-U AMIN HEMATURIA

III FOC PROLIF — < 1/2 GLOMERULI CAN => EXTENS DAM TO INDIV G

IV DIFFUSE PROLIFERATIVE — PROTOT MOST SEVERE
OFTEN NEPHRO + NEPHRI
± ALL G
GN
MANIFESTS
+ SMALL FOC THROMBOSIS
↑ MES PROLIF°

V MBOUS = I

SPATTERNS LUPUS NP

REVAL COMPONENT
SEVERITY ⇓ OFTEN

II
OFTEN NEPHRO
MAY ALSO NEPHRI

MAJ 2 TYPES AMYLOIDOSIS

NEPHROTIC SD

MCD

FSGS

MBOUS GN

DIAB NP GS

ANOTHER NEPHROTIC

DVP^m

OR

IFM
LEG COMMON IN

LONG STANDING NEOP

II AA

I AL

MONOCLONAL LAMBDA LIGHT CHAINS
PC
DYSGMASIAS

WIDAM

MISS GOOS FIBRILLARY
EM
VOL LIGHT + BIREF
THIOFLAVINT SPEC STAINS
CAY STAIN VIOLET
GN HOMOG

IDENTIFICA° CAN PREDOM

MESANG
SUBENDOT

AMYLOID DEPOSITS

AMYLOID

NL

CU

WIRE LOOPING
LM IC
GROSS THICK BM
ENDOTH PROLIF-EM

SUBENDOT IC DEPOSIT
MAJ Δ FEAT

SCANNING +++
NODULAR ACCUMULATION
MM MATERIAL
= KIMMELSTEEL-WILSON NODULES

FOCAL GS FP
THICKENED BM + +
↑ MM
↑ MC

BM LIKE * MATERIAL

STRIKING
ONE OF EARLIEST
PROBLEMS IN DM
DIFFUSE GS CLOSIS
MES ACCUM°
NODULAR GS

OFTEN CU NEPHROTIC
EM

MESANGIAL MATRIX ⇒
2 GLOM PATTERNS

SCH

NEPHRITIC

① CLIN

- OLIGURIA
- AZOTEMIA
- HT
- HEMATURIA

② POST STREPTOCOC GN

- IC DIS
  - Ag → origin
- MOST OFTEN
  - FOLLOWS ACUTE PHARYNGITIS
  - NEPHRITOGENIC STRAINS
    - ~~GROUP A β HEMOLYTIC~~ STREP
- ALSO
  - ↑ ✱ RF ✱
  - FOLLOWS
  - CHIEFLY TONSILITIS
- AFTER
  - SKIN IFC
- ALMOST ALL CHILDREN
- MANY ADULTS COMPLETE RECOVERY
- ✱ VERY SMALL
- LAB
  - ↓ Se C3
  - N-BL
  - URC CASTS
  - U RC
- ASO
  - ANTI STREPTOLYSIN O
  - ↑ TITERS ANTI STREP Ab
- ANTI CATIONIC PROTEINASE
- ANTI DNASE B
- EVIDENCE RECENT STREP IFC

③ EPIT SIDE BM

- SUBEPIT LOCALIZA-
- IMMUNE COMPLEX DEPOSITS
- GLOM CAPILLARIES
- IMMUNE RUPTURE ⇒ BLEEDING IN U SPACE
  - P.U
  - EDEMA
  - MAYBE PRESENT BUT USUALLY ARE MILD

- PROLIFERATION OF ENDOTH
- ↑ MC

- BOTH KIDNEYS
- (± ALL G)
- IFM
- INTENSE ++
- APIDLY PROGRESSIVE RPGN
- ACUTE PROLIFERATIVE
- EXTREMELY LARGE GRANULAR IF IgG or C3
- "LUMPY-BUMPY"
- IF
- GBM
- N
  - THICKNESS
  - UNIFORMITY
- E DENSE "HUMPS"
- DESPITE EXTENSIVE IMMUNT
- G
  - SOMET (N)
  - PROLIFERATION OF ENDOTH
- BOTH KIDNEYS
- STE
- INNUMERABLE PUNCTATE HEMOR
- HUMPLIKE
- IC SUBEPIT
- ↑ MC
- ENLARGED
- U ↓
- SWOLLEN BL-LESS

- CAP
- BOWMAN SPACES
- MANY AGGREGATED INTO TUBULES SHAPE
- ↓
- PROTEIN MATRIX = RED & CASTS
- "SMOKY BROWN" U
- CAN DEGENERATE
- PIGMENTED GRANULAR CASTS

NL

SCH

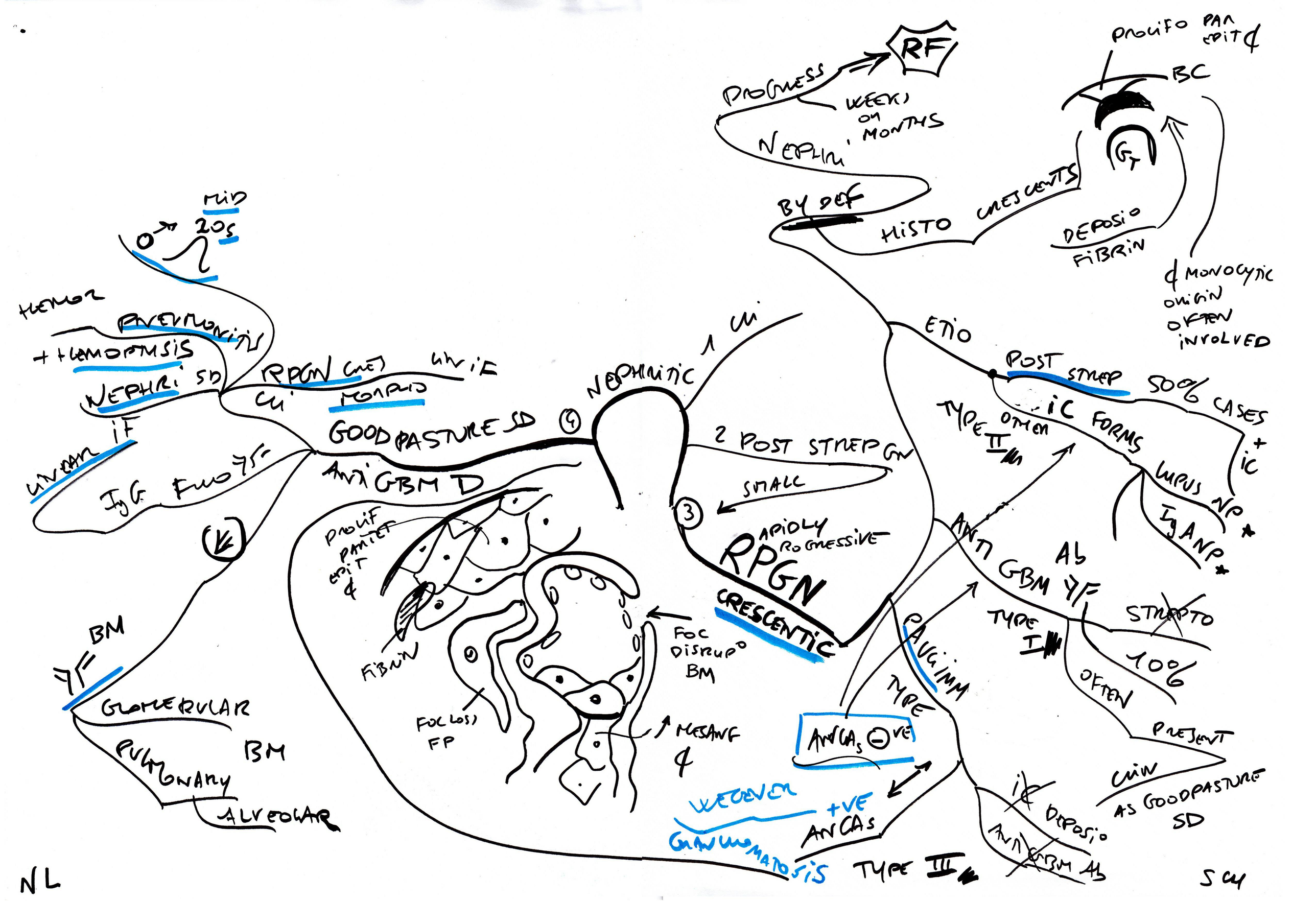
RF
PROGRESS
WEEKS OR MONTHS
NEPHRI
BY DEF
HISTO CRESCENTS
DEPOSIO FIBRIN
BC
GT
PROLIF PAR EPIT ¢
¢ MONOCYTIC ORIGIN OFTEN INVOLVED
ETIO
POST STREP
50% CASES
TYPE II
OTHER IC FORMS
LUPUS NP
IgA NP
+ IC
ANTI GBM Ab
TYPE I
STRPTO
100%
OFTEN PRESENT
CLIN AS GOODPASTURE SD
IC DEPOSIO
ANTI GBM Ab
TYPE III
SCH
PAUCIIMM TYPE
ANCAs ⊖ VE
WEGENER GRANULOMATOSIS
+VE ANCAs
NEPHRITIC
1 CH
2 POST STREP GN
SMALL
3
APIDLY PROGRESSIVE
RPGN
CRESCENTIC
FOC DISRUPT BM
MESANG ¢
PROLIF PARIET EPIT ¢
FIBRIN
FOC LOSS FP
4
GOODPASTURE SD
ANTI GBM D
RPGN
CH
MONOCLO
CLIN
IF
NEPHRI SD
+ HEMOPTYSIS
PNEUMONITIS
HEMOR
0 → 20s
MID
IgG FLUOR
BM
GLOMERULAR
PULMONARY
ALVEOLAR
NL

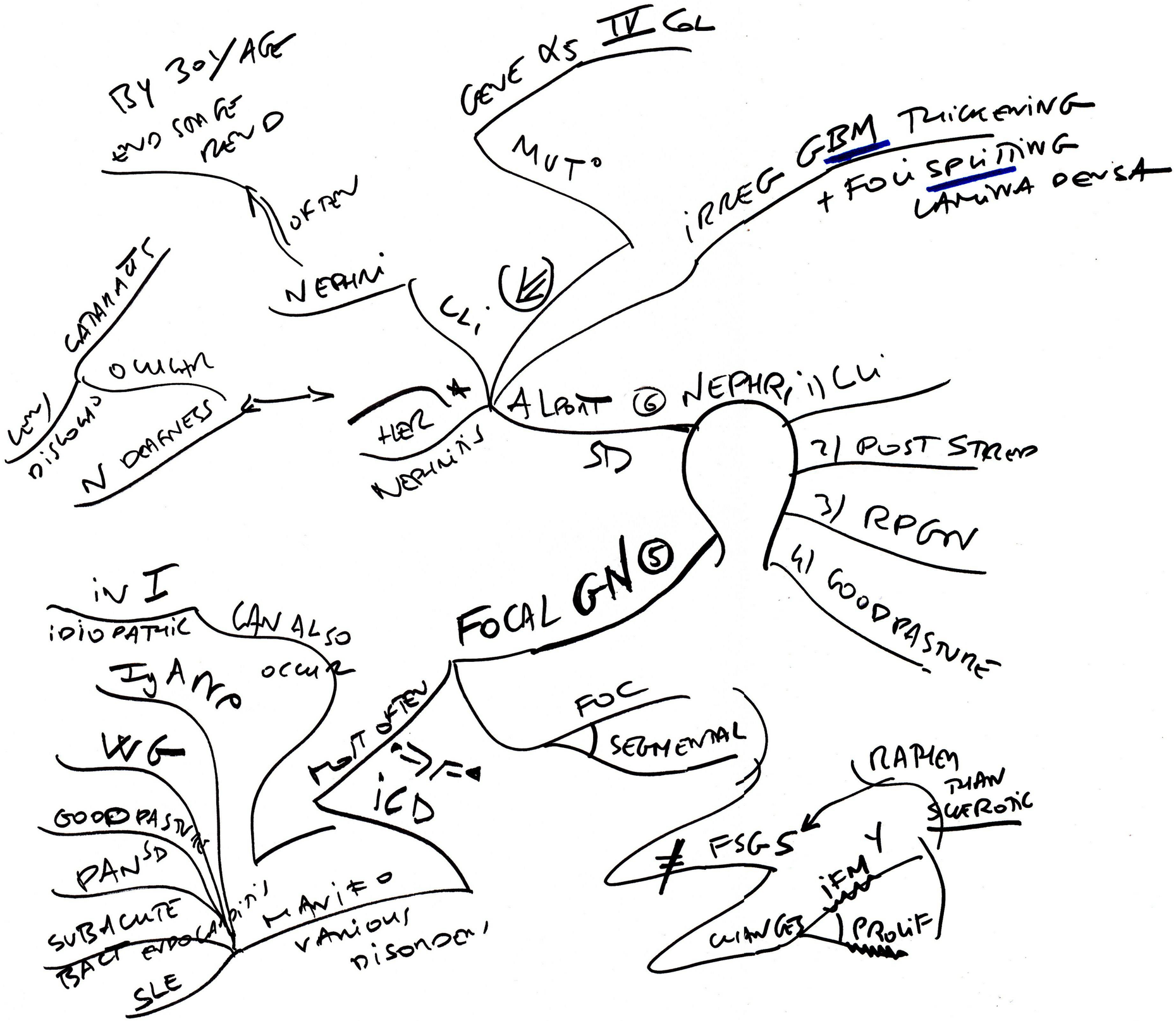
BY 30Y AGE
END STAGE RENAL
OFTEN
NEPHRI
GENE ALS IV COL
MUTS
CL.
IRREG GBM THICKENING
+ FOI SPLITTING
LAMINA DENSA
CATARACTS
OCULAR
LENS DISLOCATS
N DEAFNESS
HER NEPHRITIS
ALPORT ⑥ NEPHRITIS CLI
SD
2) POST STREP
3) RPGN
4) GOODPASTURE
FOCAL GN ⑤
iN I
IDIOPATHIC
CAN ALSO OCCUR
IgA N
WG
GOODPASTURE
PANSD
SUBACUTE BACT ENDOCARDITIS
SLE
MANIFS VARIOUS DISORDERS
MOST OFTEN
ICD
FOC
SEGMENTAL
RAPIDLY PROGRESSIVE
THAN SCLEROTIC
FSGS
CHANGES
iFM
PROLIF

OTHER GLOMERULAR DISEASES

MPGN

- 2 FORMS
  - EMBRANO PROLIFERATIVE
  - ↑ MC
  - ↑ MES
  - PROLIF ↑ MIGRATO
  - PINK CAP
  - PROLIF ENDOT
  - IC LARGE SUBENDOT DEPOSITS
  - IN NON BORDER BM
  - TYPE I
  - HYPER
  - TUFTS
  - NARROW OR SLIT
  - GENERALIZED
  - INTERPOSITION MC / BM BETWEEN EC / ORIGINAL
  - => DOUBLE CONTOUR EFFECT
  - SILVER STAINS
  - MAMMAL
  - APP
  - 2 LAYERS
  - EXPAND MATRIX INTO GLOOPS
  - GBM REDUPLICATION
  - MANY
  - ↓ PROLIFE
  - THICKENING
  - BM
  - HISTO
  - LOBULATE
  - (?AV
  - STRIKING
  - IC NEPHRITIS
  - I
  - IN GMB
  - C3 ADJACENT NOT WITHIN
  - IRREG
  - DENSE MAT
  - SEC3 ↓
  - ?
  - DENSE DEPOSIT
  - H
  - NOT AS APPARENT AS I
  - G
  - AUTO C3 NEPHRITICF
  - SPECIFICALLY FOR C3 CONVERTASE ALT C
  - CH
  - SLOW
  - PROGRESS
  - CHRONIC RENAL D
  - DEF IgA IN MESANGIUM
  - DEPOSITS
  - COMMON ++
  - IC IN MESANGIUM BETWEEN MC / BM
  - IgA NP
  - BERGER'D
  - MEST PATHOLOGY
  - RENIGN RECURRENT
  - HEMAT-U
  - CHILD
  - USUALLY
  - IFC
  - LASTING 1-2 DAYS
  - CHRONIC
  - FOC GN
  - MAYBE
  - PRESERVING FEATURE
  - GN BE COMPONENT
  - G
  - HENOCH - SCHÖLEIND
  - MESANG EXPAND LM
  - + GRAN MES IgA
  - ↓ LIGHT MAIN IF

NL

SCH

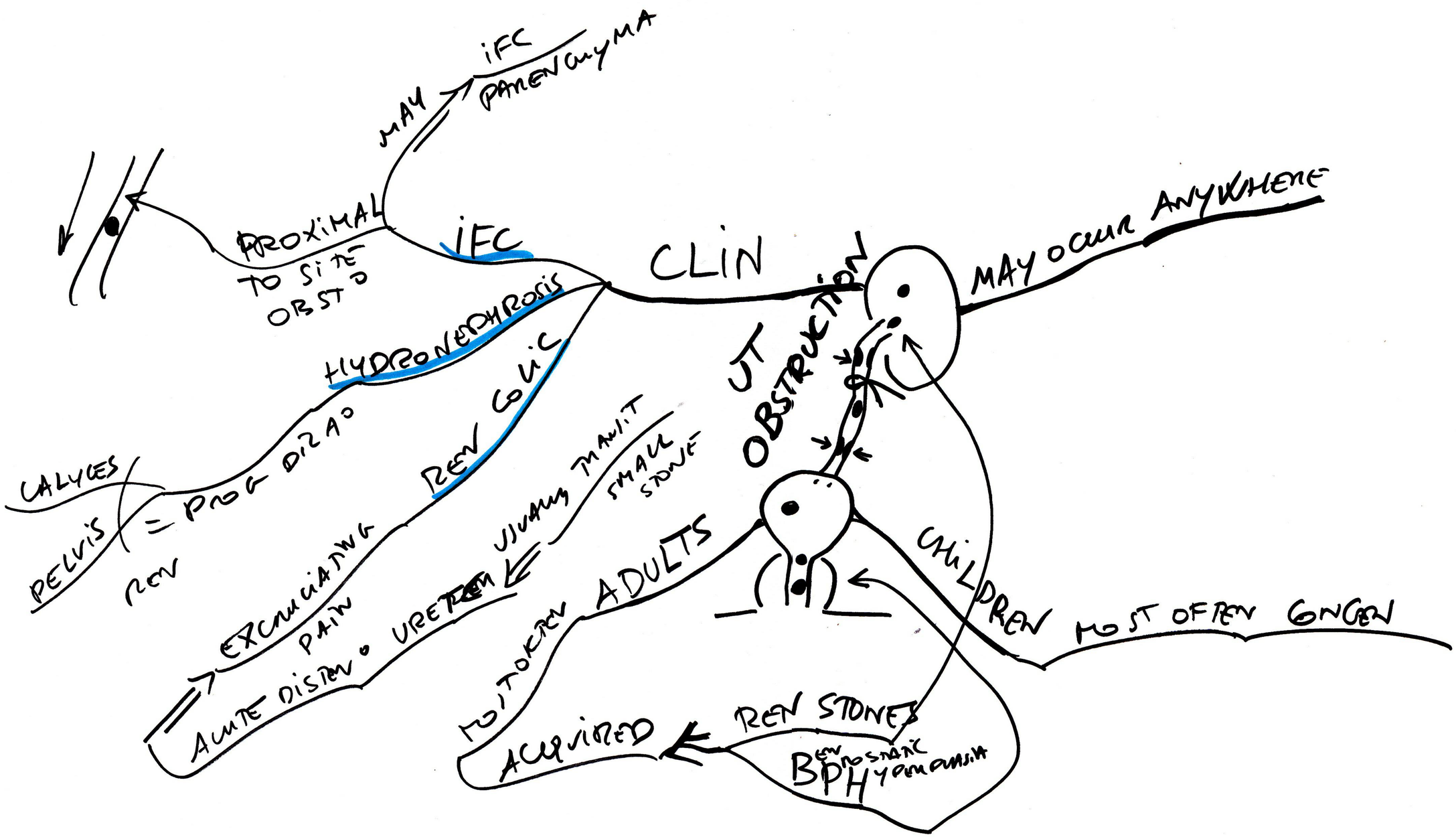
MAY
IFC
PARENCHYMA
PROXIMAL
TO SITE
OBST
IFC
CLIN
MAY OCCUR ANYWHERE
HYDRONEPHROSIS
REN COLIC
CALYCES
PELVIS
= PROG DILAT
REN
EXCRUCIATING
PAIN
ACUTE DISTEN
URETER
URINARY TRACT
SMALL
STONE
JT
OBSTRUCTION
CHILDREN
MOST OF REN CONGEN
MOTOKREN
ADULTS
ACQUIRED
REN STONES
BPH
REN
PROSTATIC
HYPERPLASIA

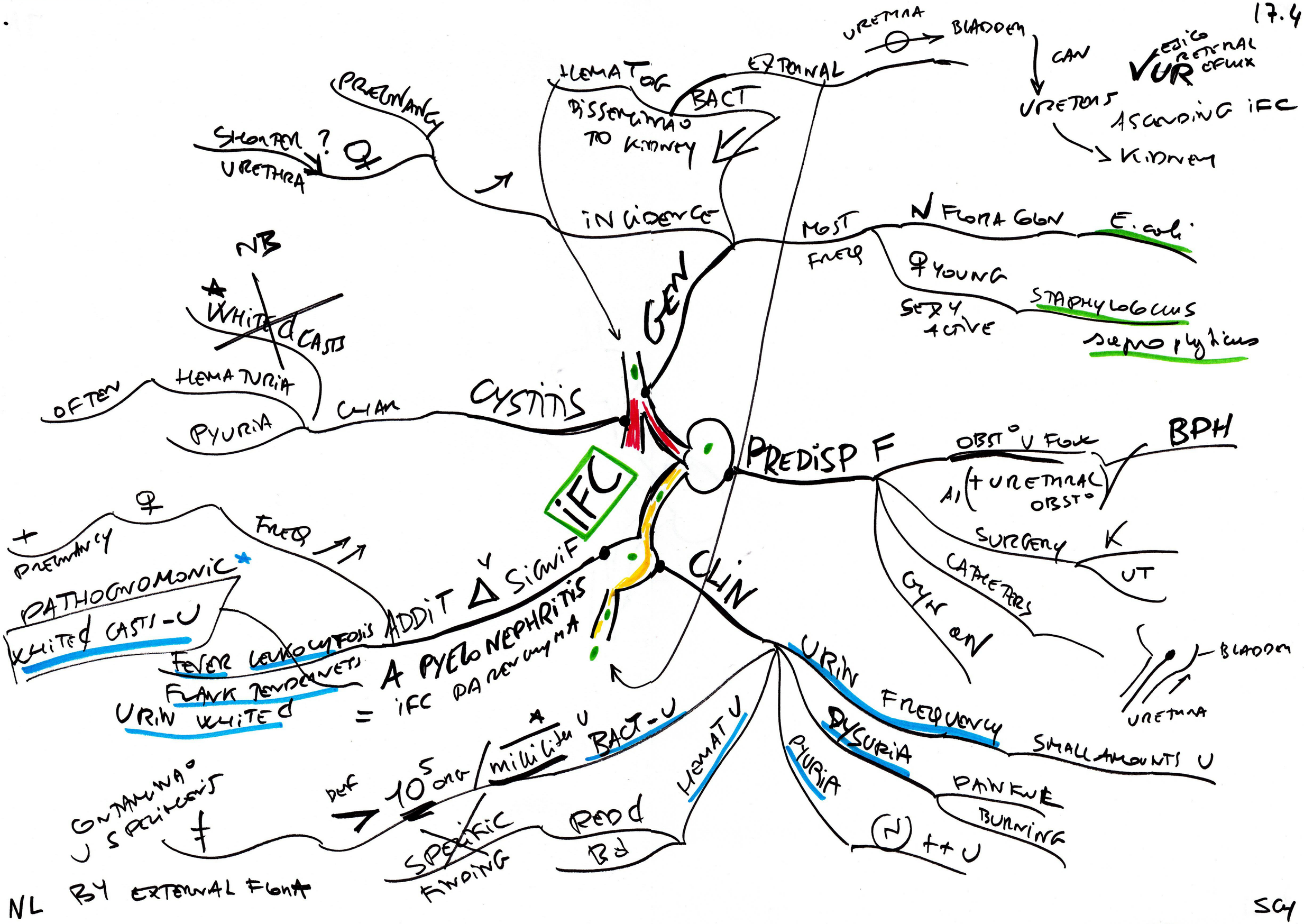
URETHRA → BLADDER
CAN
URETERS
KIDNEYS
VUR
EDICO RETENTAL REFLUX
ASCENDING IFC
EXTERNAL
HEMATOG
BACT
DISSEMINATION TO KIDNEY
PREGNANCY
SHORTER ? ♀ URETHRA
INCIDENCE
MOST FREQ
N FLORA GIGN
E. coli
♀ YOUNG
SEXY ACTIVE
STAPHYLOCOCCUS SAPROPHYTICUS
NB
WHITE CASTS
HEMATURIA
OFTEN
PYURIA
CHAR
CYSTITIS
GEN
iFC
PREDISP F
OBST° V FLOW
BPH
AI (+ URETHRAL OBST°)
SURGERY
K
UT
CATHETERS
GYN ON
BLADDER
URETHRA
+ PREGNANCY
♀
FREQ ↗↗
PATHOGNOMONIC*
WHITE CASTS - U
ADDIT Δ SIGNIF
FEVER LEUKOCYTOSIS
FLANK TENDERNESS
URIN WHITE
= iFC PARENCHYMA
A PYELONEPHRITIS
CLIN
URIN FREQUENCY
SMALL AMOUNTS U
DYSURIA
PAIN ON BURNING
PYURIA
(N) ++ U
HEMAT U
BACT - U
A
milliliter U
> 10^5 org
def
RED BD
SPECIFIC FLOWING
CONTAMINATED SPECIMENS
NL BY EXTERNAL FLORA
SCH

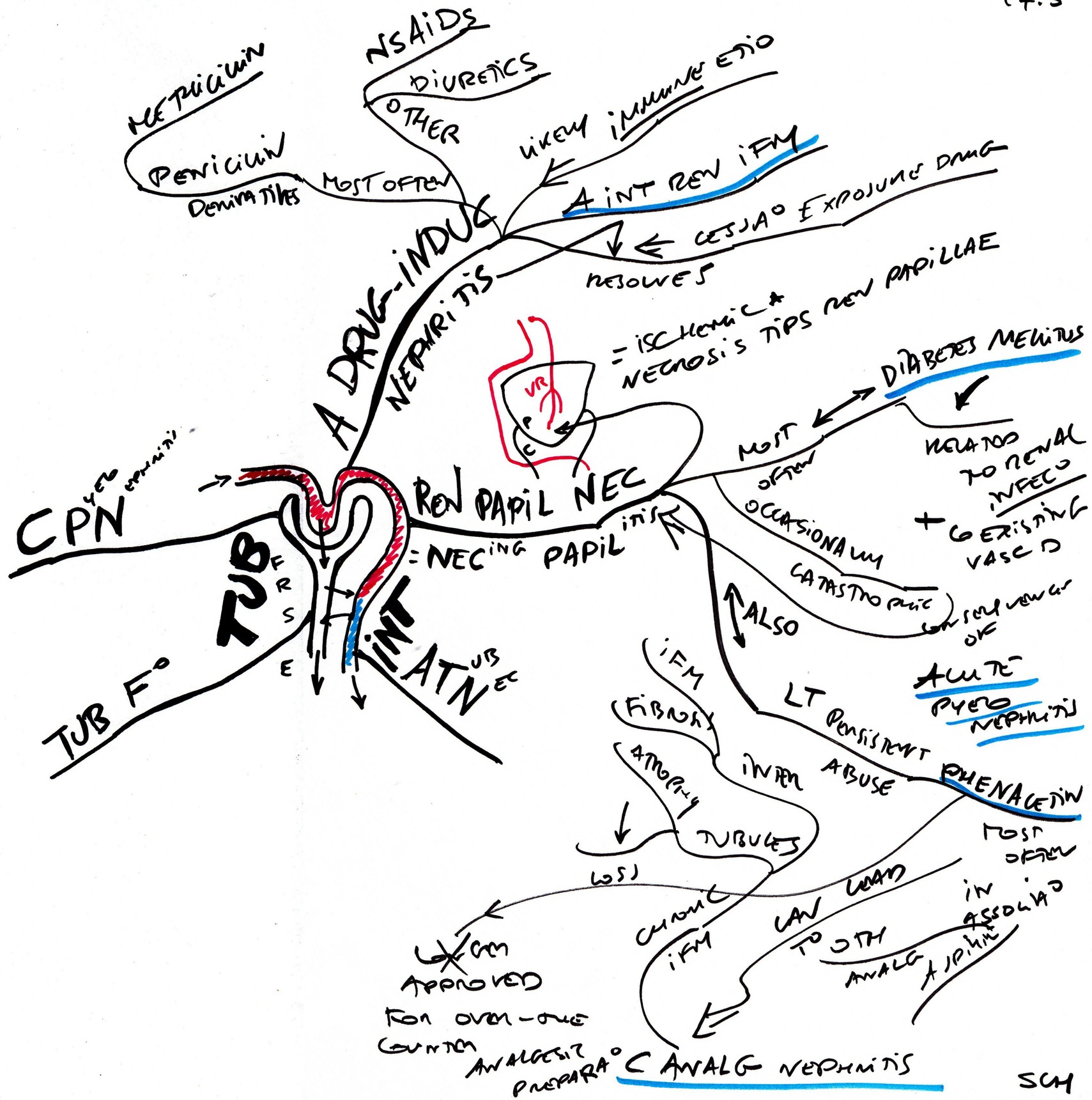
A DRUG-INDUC NEPHRITIS
METHICILLIN
PENICILLIN
DERIVATIVES
MOST OFTEN
NSAIDS
DIURETICS
OTHER
LIKELY IMMUNOLOGIC
A INT REN IFM
CESSATION EXPOSURE DRUG
RESOLVES
= ISCHEMIC + NECROSIS TIPS REN PAPILLAE
VR
P
C
DIABETES MELLITUS
MOST OFTEN
RELATED TO RENAL INFECTION
+ COEXISTING VASCD
OCCASIONALLY
CATASTROPHIC
CPN
REN PAPIL NEC
= NECING PAPILITIS
TUB F
TUB F
R
S
E
INT
ATN
ALSO
IFM
FIBROSIS
ATROPHY
TUBULES
LOSS
CHRONIC IFM
LT PERSISTENT ABUSE
PHENACETIN
MOST OFTEN
IN ASSOCIATION
ASPIRIN
ANALG
CAN LEAD TO OTH
ACUTE PYELONEPHRITIS
OTC
APPROVED
FOR OVER-THE COUNTER
ANALGESIC PREPARATION
C ANALG NEPHRITIS

NL

SCM

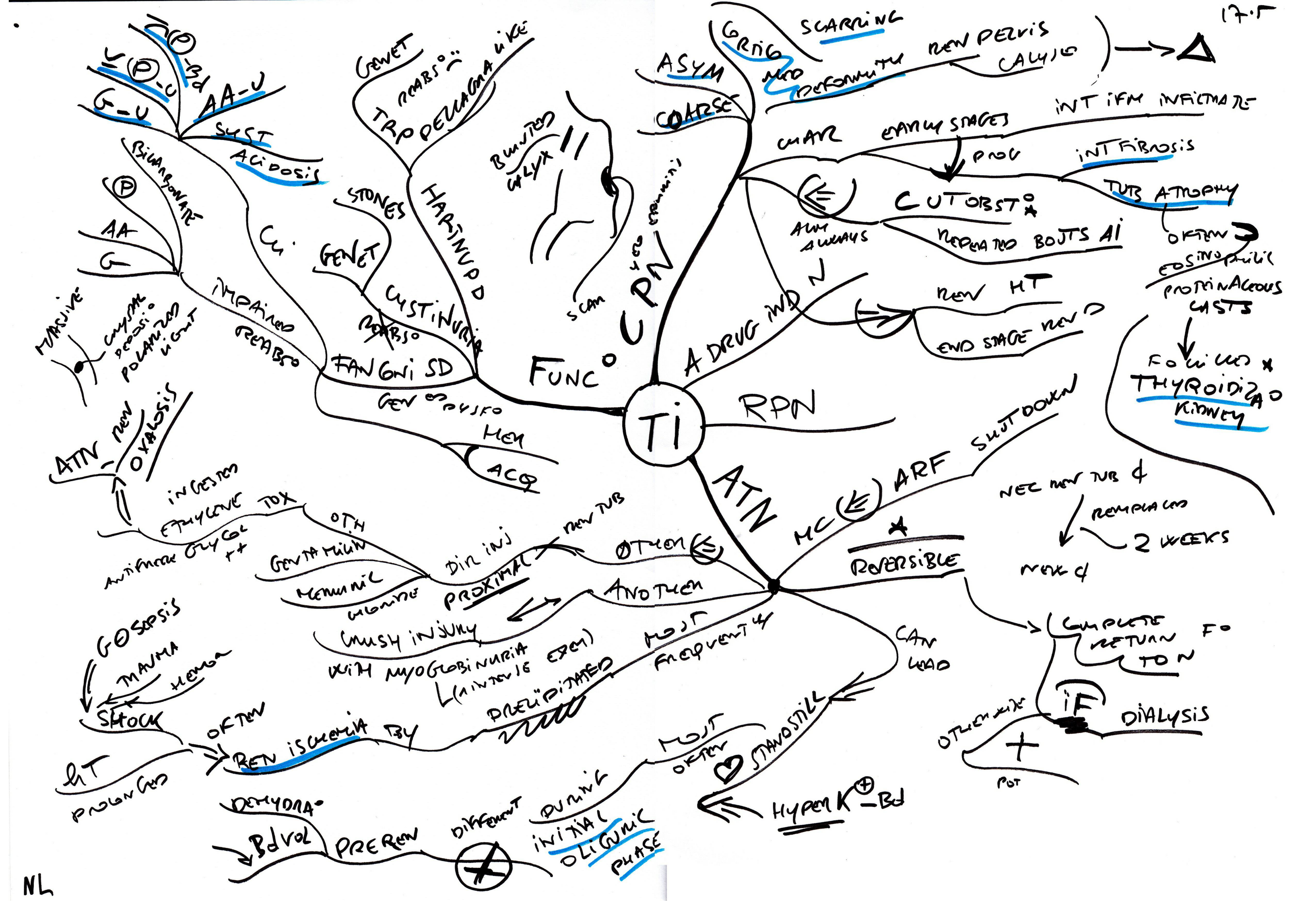
Ti
ATN
MC
ARF
REVERSIBLE
SHUTDOWN
NEC NEW NUB ↓
REPLACES
NEW ↓
2 WEEKS
COMPLETE RETURN TO N
IF
DIALYSIS
OTHER MEDS
POT
CAN LEAD
HYPER K+ - Bd
MOST OFTEN
STANDSTILL
MOST FREQUENTLY
PRECIPITATED
WITH MYOGLOBINURIA
(MUSCLE EXEM)
CRUSH INJURY
ANOTHER
OTHER
PROXIMAL
DIR INJ
NEW TUB
OTH
GENTAMICIN
MEMBRANE
ALBUMIN
INGESTION
ETHYLENE GLYCOL
TOX
ANTIFREEZE
ATN - NEW OXALOSIS
SEPSIS
TRAUMA
HEMORR
SHOCK
OFTEN
REN ISCHEMIA
BY
LT
PROLONGED
DEHYDRA
Bd VOL
PRERENAL
DIFFERENT
DURING
INITIAL
OLIGURIC
PHASE
ACQ
HEM
RPN
A DRUG IND
NEW HT
END STAGE REN
EOSINOPHILIC
PROTEINACEOUS
CASTS
FOCI
THYROIDIZATION
KIDNEY
CUTOBST
REPEATED BOUTS AI
ALW ALWAYS
TUB ATROPHY
OFTEN
INT FIBROSIS
CHAR
EARLY STAGES
PROG
INT IFM INFILTRATE
NEW PELVIS
CALYCES
SCARRING
GRIG
MED
DEFORMITY
ASYM
COARSE
BLUNTED CALYX
SCAR
FUNC
CPN
GENET
TRABS
TRPDELLAMA LIKE
HARINVPD
STONES
GENET
CYSTINURIA
FANGNI SD
GEN ANOMALIES
IMPAIRED REABS
Cu
BICARBONATE
AA-U
SYST
ACIDOSIS
AA
G
MASSIVE
CRYSTAL DEPOSIT
POLARIZED LIGHT
NL

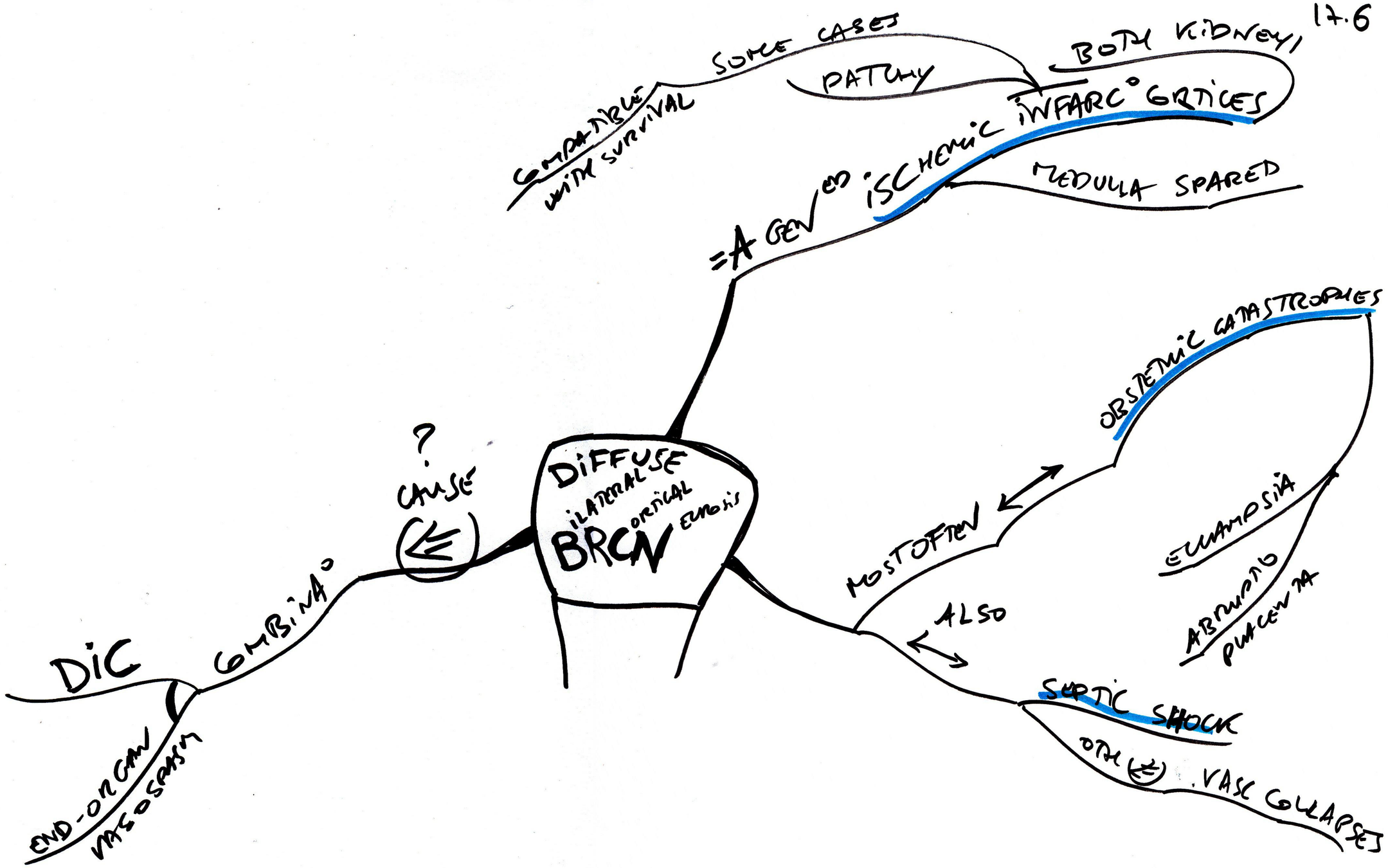
DIFFUSE
BILATERAL
CORTICAL
BRCN
EMBOLIS
=A GEN ED
ISCHEMIC INFARC° CRTICES
BOTH KIDNEYS
PATCHY
SOME CASES
COMPATIBLE WITH SURVIVAL
MEDULLA SPARED
OBSTETRIC CATASTROPHES
MOST OFTEN
ECLAMPSIA
ABRUPTIO PLACENTA
ALSO
SEPTIC SHOCK
OTHER
VASC COLLAPSES
? CAUSE
DIC
COMBINA°
END-ORGAN VASOSPASM

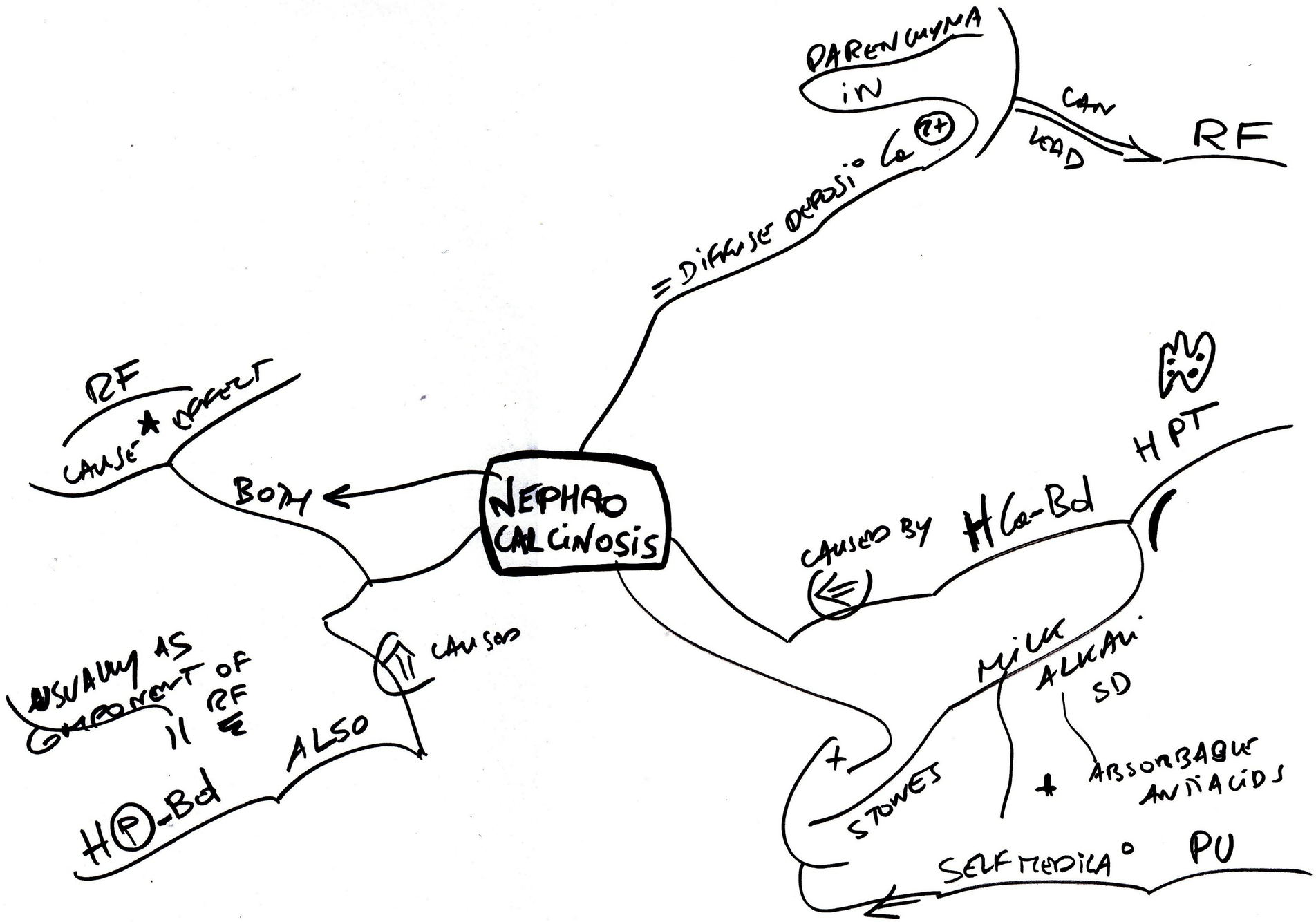
NEPHRO CALCINOSIS
PARENCHYMA in
= DIFFUSE DEPOSIT Ca ⊕
CAN LEAD
RF
RF CAUSE ★ EFFECT
BONE
USUALLY AS COMPONENT OF RF
ALSO
CAUSES
HPT
CAUSED BY Ca-Bd
MILK ALKALI SD
+ ABSORBABLE ANTIACIDS
+ STONES
SELF MEDICATION
PU

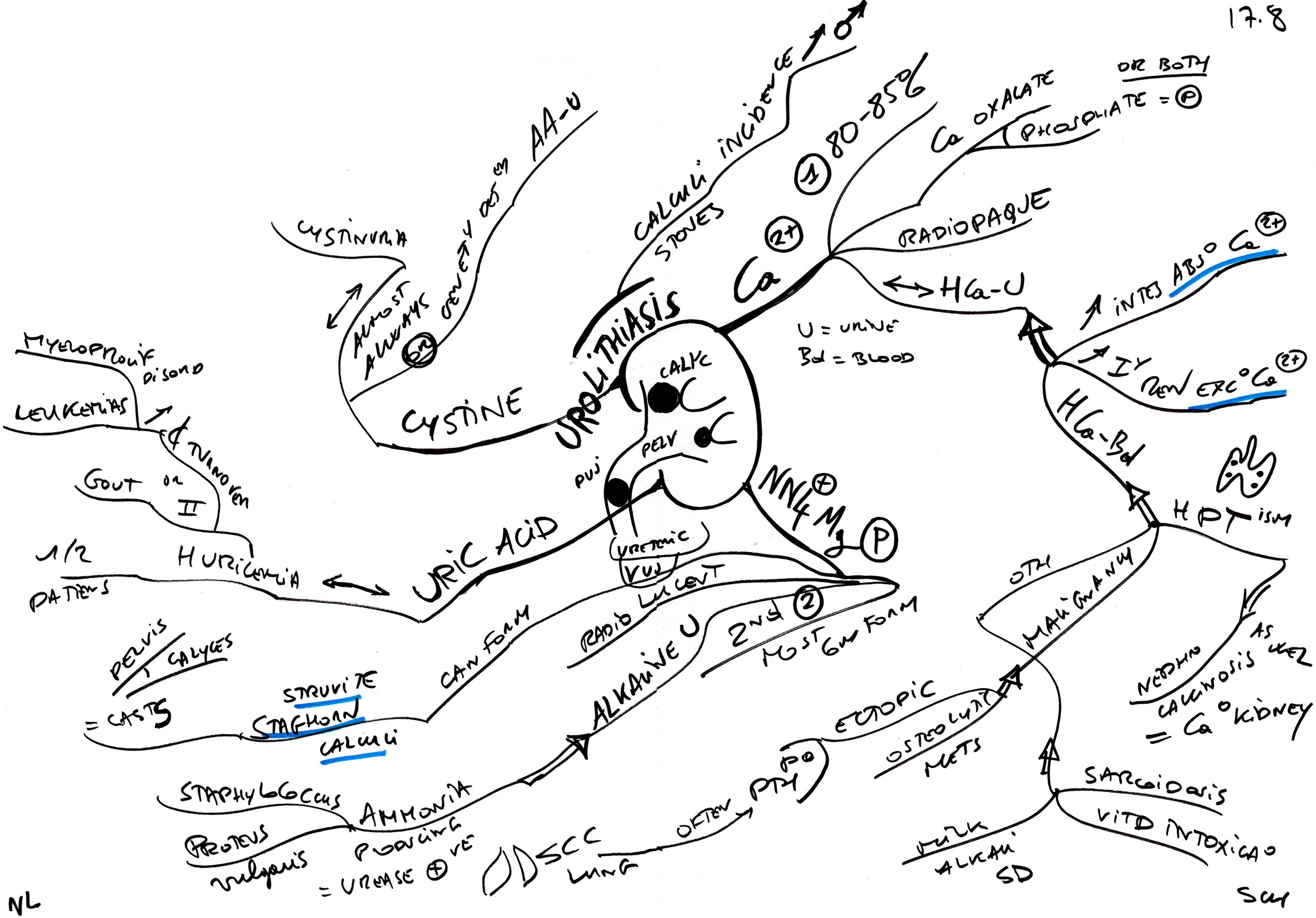
UROLITHIASIS
CALCULI INCIDENCE ↑ ♂
STONES
Ca (2+)
(1) 80-85%
Ca OXALATE
PHOSPHATE = (P)
OR BOTH
RADIOPAQUE
↔ HCa-U
U = URINE
Bd = BLOOD
↑ INTES ABS° Ca (2+)
↑ IV REN EXC° Ca (2+)
HCa-Bd
HPTism
CYSTINURIA
ALMOST ALWAYS GENETIC DIS IN AA-U
CYSTINE
CALYX
PELV
PUJ
URETHRIC
VUJ
NH4Mg (P)
URIC ACID
MYELOPROLIF DISORD
LEUKEMIAS
↓ TUMOR
GOUT OR II
HURICEMIA
1/2 PATIENTS
PELVIS / CALYCES = CASTS
STRUVITE
STAGHORN CALCULI
CAN FORM
RADIO LUCENT
ALKALINE U
2nd (2) MOST COM FORM
STAPHYLOCOCCUS
PROTEUS vulgaris
AMMONIA PRODUCING = UREASE (+) VE
DDSCC LUNG
OFTEN PTH
PO
ECTOPIC
OSTEOLYTIC METS
OTH
MALIGNANCY
MILK ALKALI SD
SARCOIDOSIS
VITD INTOXICATION
NEPHRO CALCINOSIS AS UNCL = Ca KIDNEY
NL
SCM

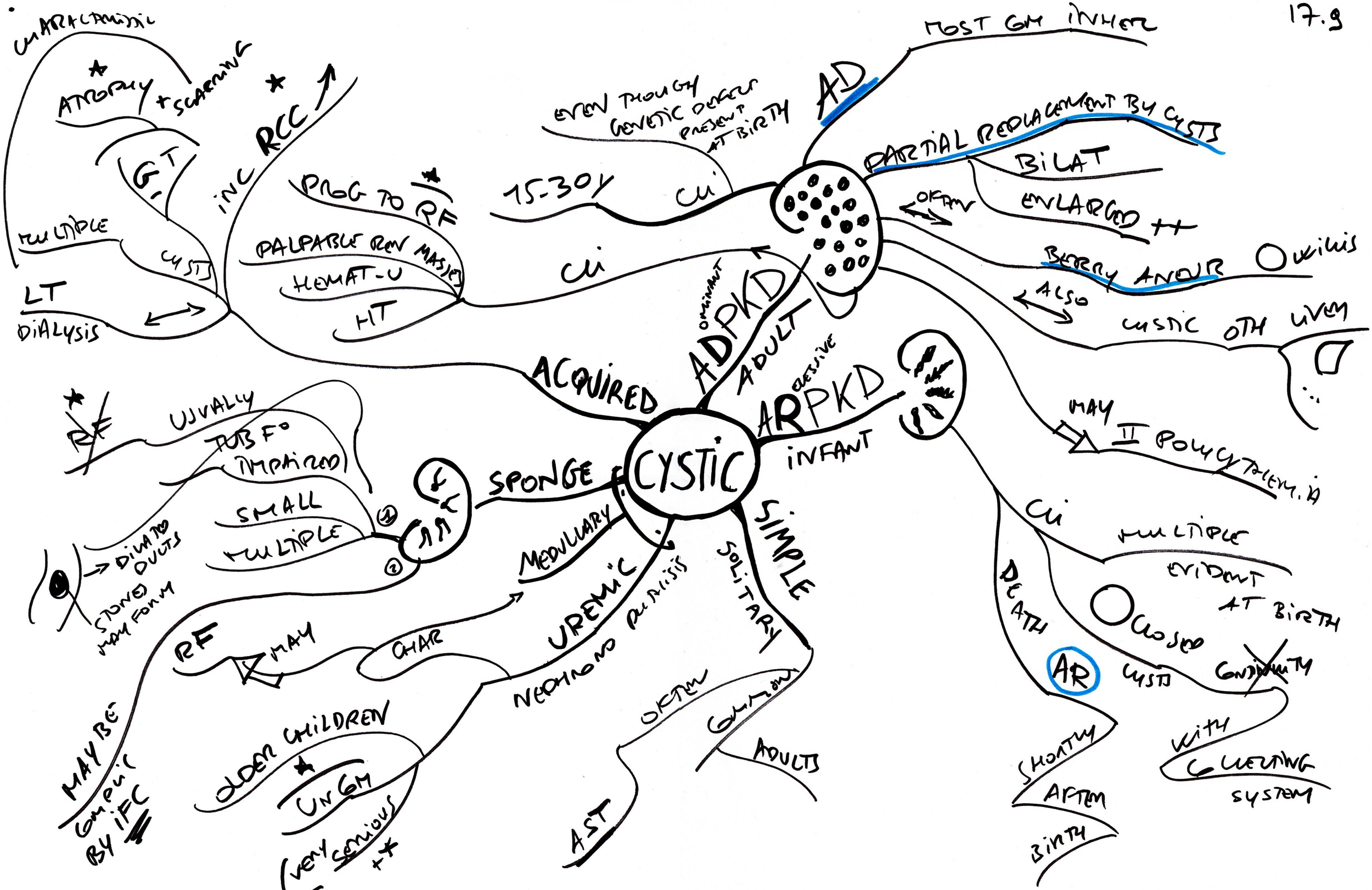
CYSTIC
AD
MOST GM INVOLVE
PARTIAL REPLACEMENT BY CYSTS
BILAT
ENLARGED ++
OFTEN
BERRY ANEUR
ALSO
CYSTIC OTH LIVER
EVEN THOUGH GENETIC DEFECTS PRESENT AT BIRTH
15-30Y
CLI
ADPKD
DOMINANT
ADULT
ARPKD
RECESSIVE
INFANT
MAY
II POLYCYTHEMIA
ACQUIRED
PROG TO RF
PALPABLE REN MASSES
HEMAT-U
HT
CLI
INC RCC
ATROPHY + SCARRING
GT
MULTIPLE
CYSTS
LT
DIALYSIS
UNARTHRAMISTIC
RF
USUALLY
TUBF° IMPAIRED
SMALL
MULTIPLE
DILATED DUCTS
STONES MAY FORM
SPONGE
MEDULLARY
UREMIC
NEONATAL PERIOD
SIMPLE
SOLITARY
OFTEN
COMMON
ADULTS
AST
RF
MAY
CHAR
OLDER CHILDREN
UNCOM
VERY SERIOUS ++
MAYBE COMPLIC BY IFC
CLI
MULTIPLE
EVIDENT AT BIRTH
CLOSED CYSTS
AR
DEATH
SHORTLY AFTER BIRTH
WITH GASTROINTESTINAL SYSTEM

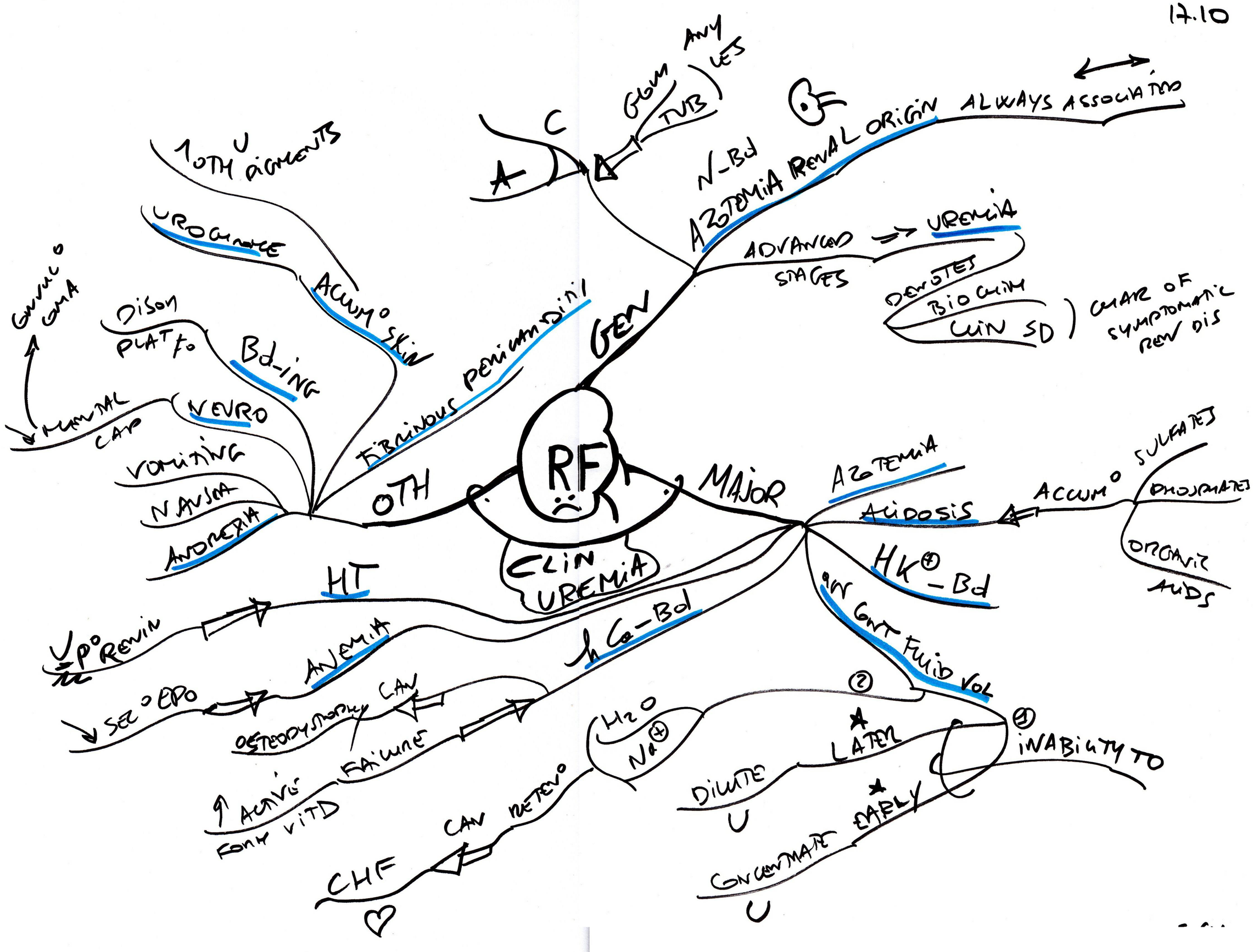
RF
CLIN UREMIA
GEN
A
C
GLOM
TUB
ANY
LES
B
N-Bd
AZOTEMIA
RENAL ORIGIN
ALWAYS ASSOCIATED
ADVANCED STAGES
UREMIA
DEMOTES
BIOCHEM
CLIN SD
CHAR OF SYMPTOMATIC REN DIS
MAJOR
AZOTEMIA
ACIDOSIS
ACCUM°
SULFATES
PHOSPHATES
ORGANIC ACIDS
HK⊕-Bd
GRT FLUID VOL
① INABILITY TO
② ★ LATER
★ EARLY
DILUTE
CONCENTRATE
H2O
Na⊕
CHF
CAN RETENT°
↑ ACTIVE FORM VITD
FAILURE
OSTEODYSTROPHY
CAN
↓ SEC° EPO
ANEMIA
↓ PRENIN
HT
↓ Ca-Bd
OTH
FIBRINOUS PERICARDITIS
ACCUM° SKIN
UROCHROME
TOTH PIGMENTS
NEURO
Bd-ING
DISORD PLATLETS
CAP
VOMITING
NAUSEA
ANOREXIA
GASTRO COLITIS

NL

17.11

h = HYPO !
H = HYPER !

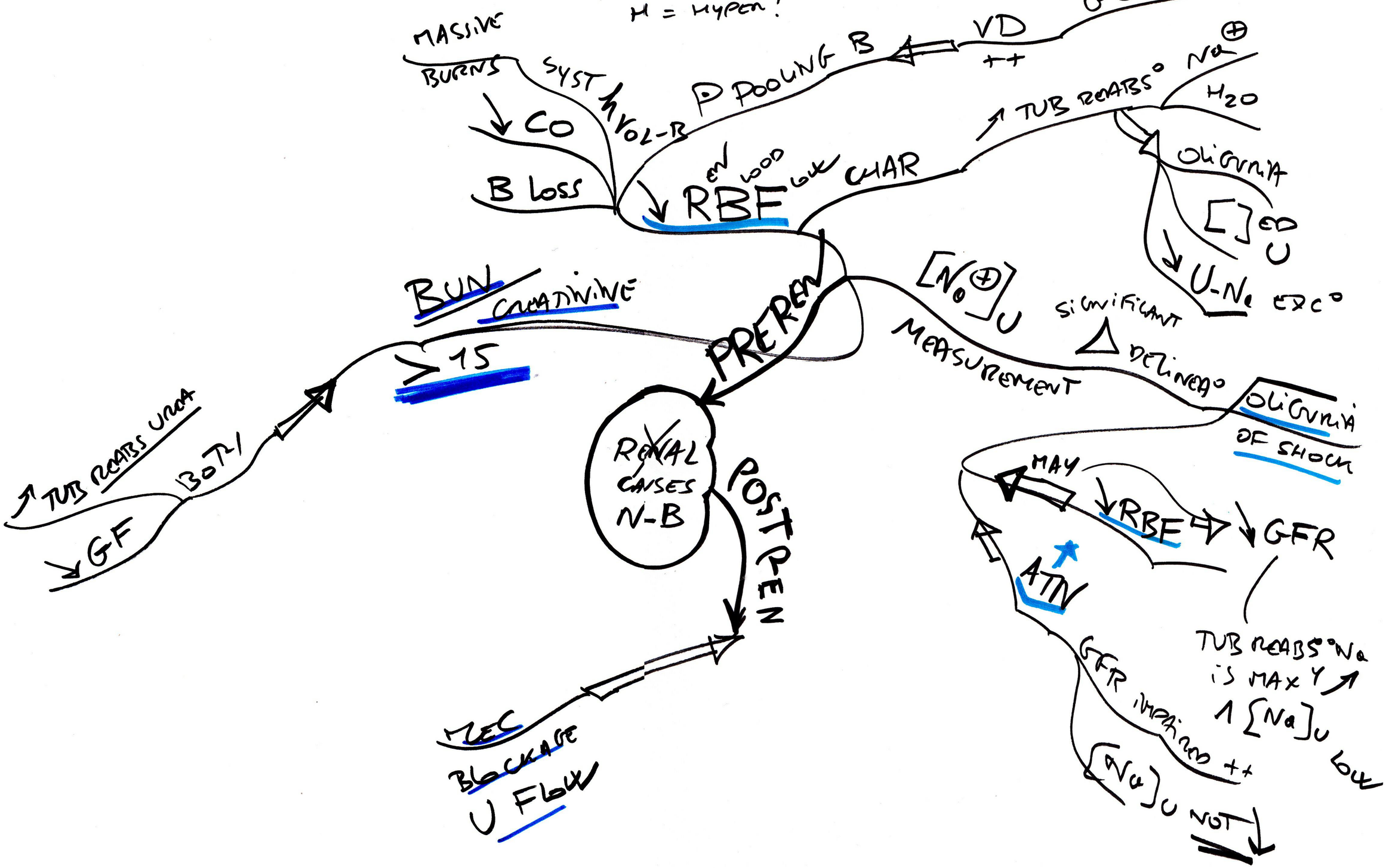

NL

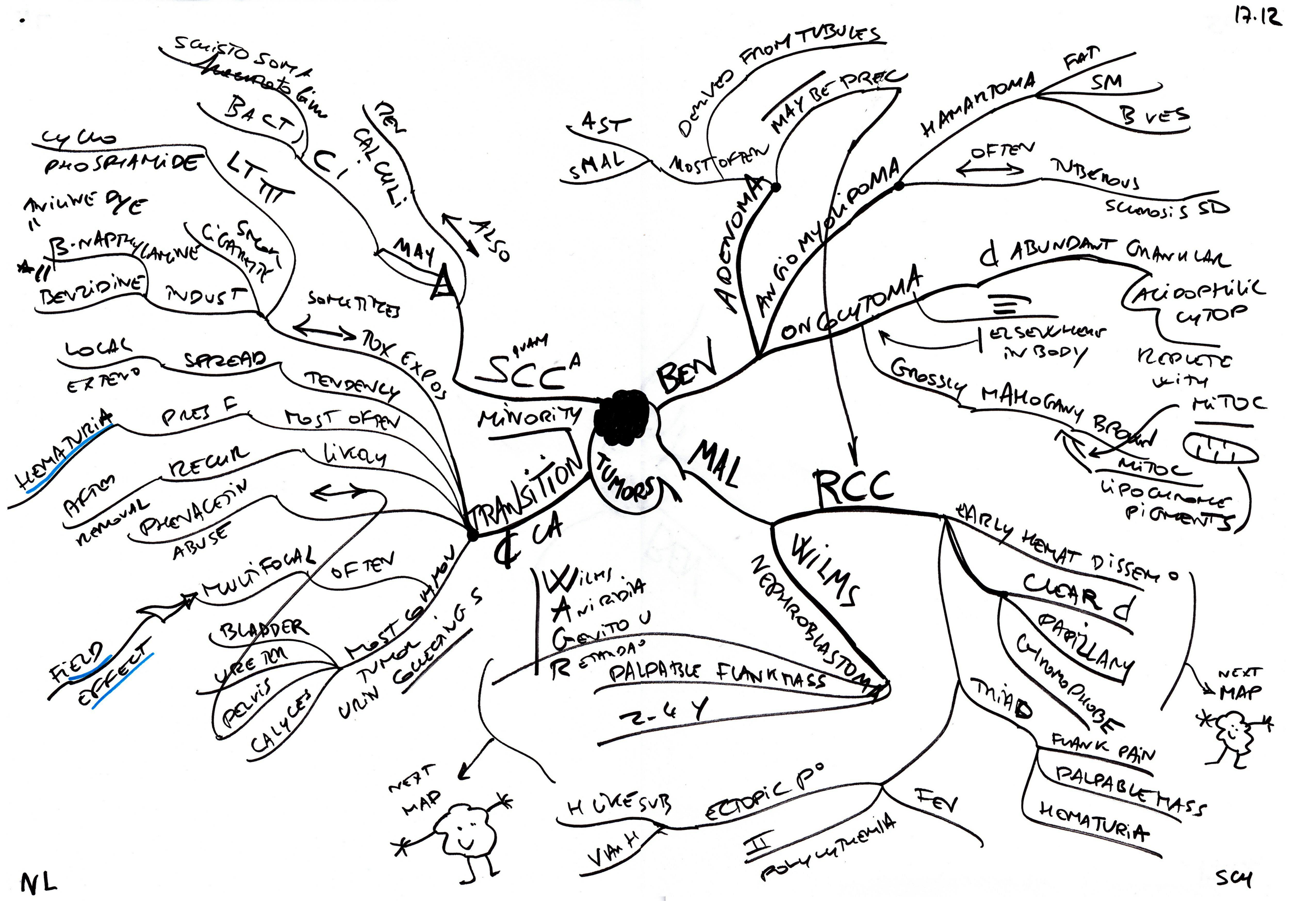
TUMORS
BEN
MAL
ADENOMA
AST
SMAL
MOST OFTEN
DERIVED FROM TUBULES
MAY BE PREC
ANGIOMYOLIPOMA
HAMARTOMA
FAT
SM
B VES
OFTEN
TUBEROUS
SCLEROSIS SD
ONCOCYTOMA
d ABUNDANT GRANULAR
ACIDOPHILIC CYTOP
REPLETE WITH MITOC
MITOC
LIPOCHROME PIGMENTS
ELSEWHERE IN BODY
GROSSLY MAHOGANY BROWN
RCC
EARLY HEMAT DISSEM
CLEAR d
PAPILLARY
CHROMOPHOBE
NEXT MAP
TRIAD
FLANK PAIN
PALPABLE MASS
HEMATURIA
FEV
II
POLYCYTHEMIA
ECTOPIC P°
H LIKE SUB
VAN H
WILMS
NEPHROBLASTOMA
2-4 Y
PALPABLE FLANK MASS
Wilms
Aniridia
Genito U
Retardat°
NEXT MAP
SCC^A
MINORITY
TRANSITION CA
A
MAY
ALSO
SCHISTOSOMA
BACT
C
CALCULI
PEN
CYCLO PHOSPHAMIDE
LT TTT
ANILINE DYE
B-NAPHTHYLAMINE
BENZIDINE
INDUST
CIGARETTE
SMOK
SOMETIMES
TOX EXPOS
LOCAL
EXTENO
SPREAD
TENDENCY
PRES F
MOST OFTEN
HEMATURIA
LIKELY
RECUR
AFTER
REMOVAL
PHENACETIN
ABUSE
MULTIFOCAL
OFTEN
FIELD EFFECT
BLADDER
URETER
PELVIS
CALYCES
MOST SYNCH
TUMOR
URIN GLEENINGS

NL

SCM

17.12

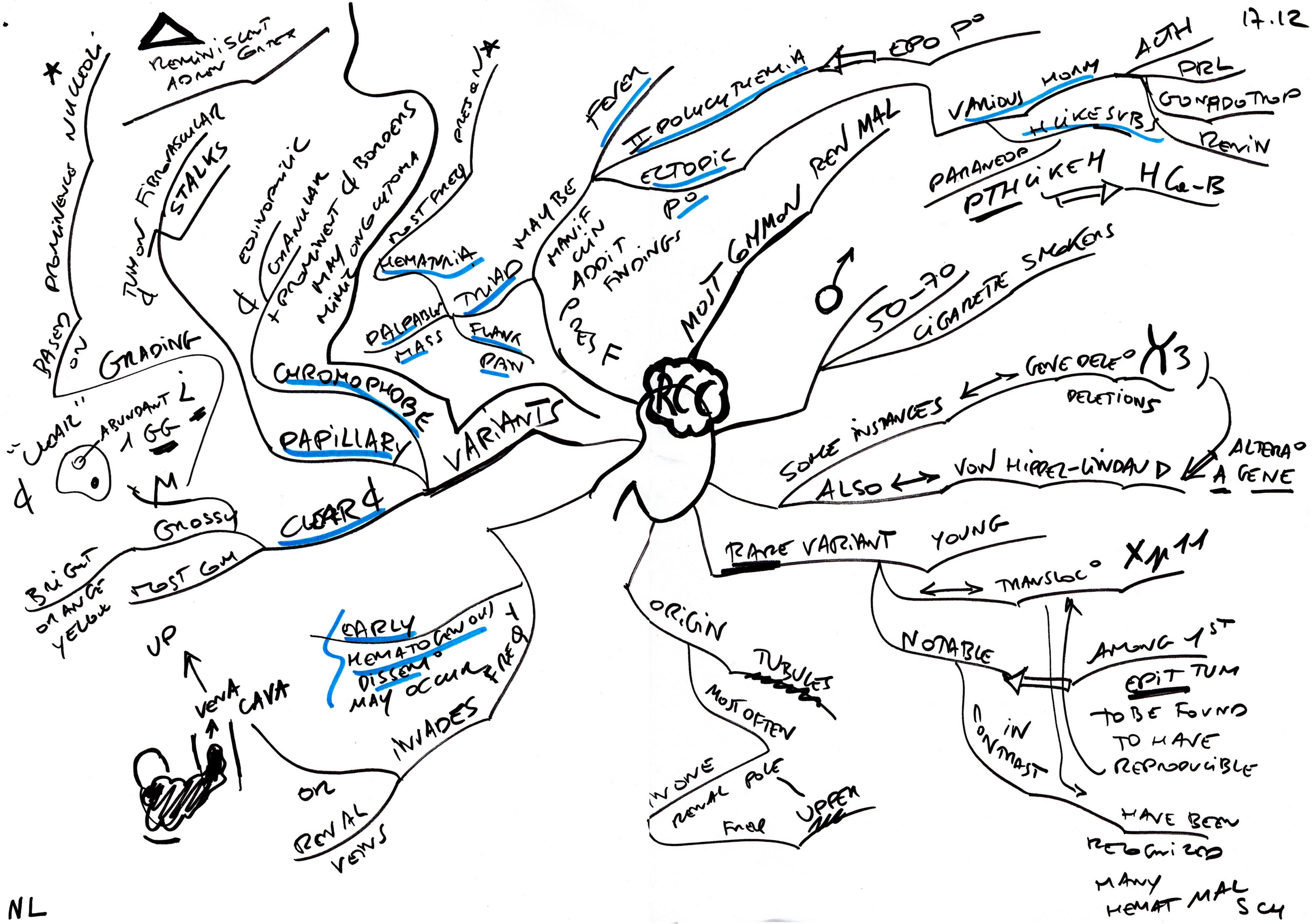
RCC
REMINISCENT ADRENAL CORTEX
BASED ON PROMINENCE OF NUCLEOLI
TUMOR FIBROVASCULAR STALKS
EOSINOPHILIC GRANULAR + PROMINENT MAY ONCOCYTOMA MINUS & BODIES
MOST FREQ PRESENT
GRADING
"UGLIER" ABUNDANT 1 GG
M
CHROMOPHOBE
PAPILLARY
VARIANTS
CLEAR &
GROSSY
BRIGHT ORANGE YELLOW
MOST COM
UP
VENA CAVA
EARLY HEMATOGENOUS DISSEM. MAY OCCUR & REQ
INVADES
OR RENAL VEINS
FEVER
POLYCYTHEMIA
EPO P
ECTOPIC
PO
HEMATURIA
TRIAD MAYBE
DALPAIN MASS
FLANK PAIN
MANIF CLIN ADDIT FINDINGS
PRES F
MOST COMMON REN MAL
♂
50-70
CIGARETTE SMOKERS
VARIOUS HORM
ACTH
PRL
GONADOTROP
RENIN
HUMESUBS
PARANEOP
PTH LIKE H
HCG-B
GENE DELE°
X3
DELETIONS
SOME INSTANCES
ALSO
VON HIPPEL-LINDAU
ALTERA° A GENE
RARE VARIANT YOUNG
TRANSLOC°
X11
ORIGIN
TUBULES
MOST OFTEN
IN ONE RENAL POLE
FREQ
UPPER
NOTABLE
IN ONTMAST
AMONG 1ST
EPITHUM
TO BE FOUND TO HAVE REPRODUCIBLE
HAVE BEEN RECOGNIZED
MANY HEMAT MAL SCH

NL

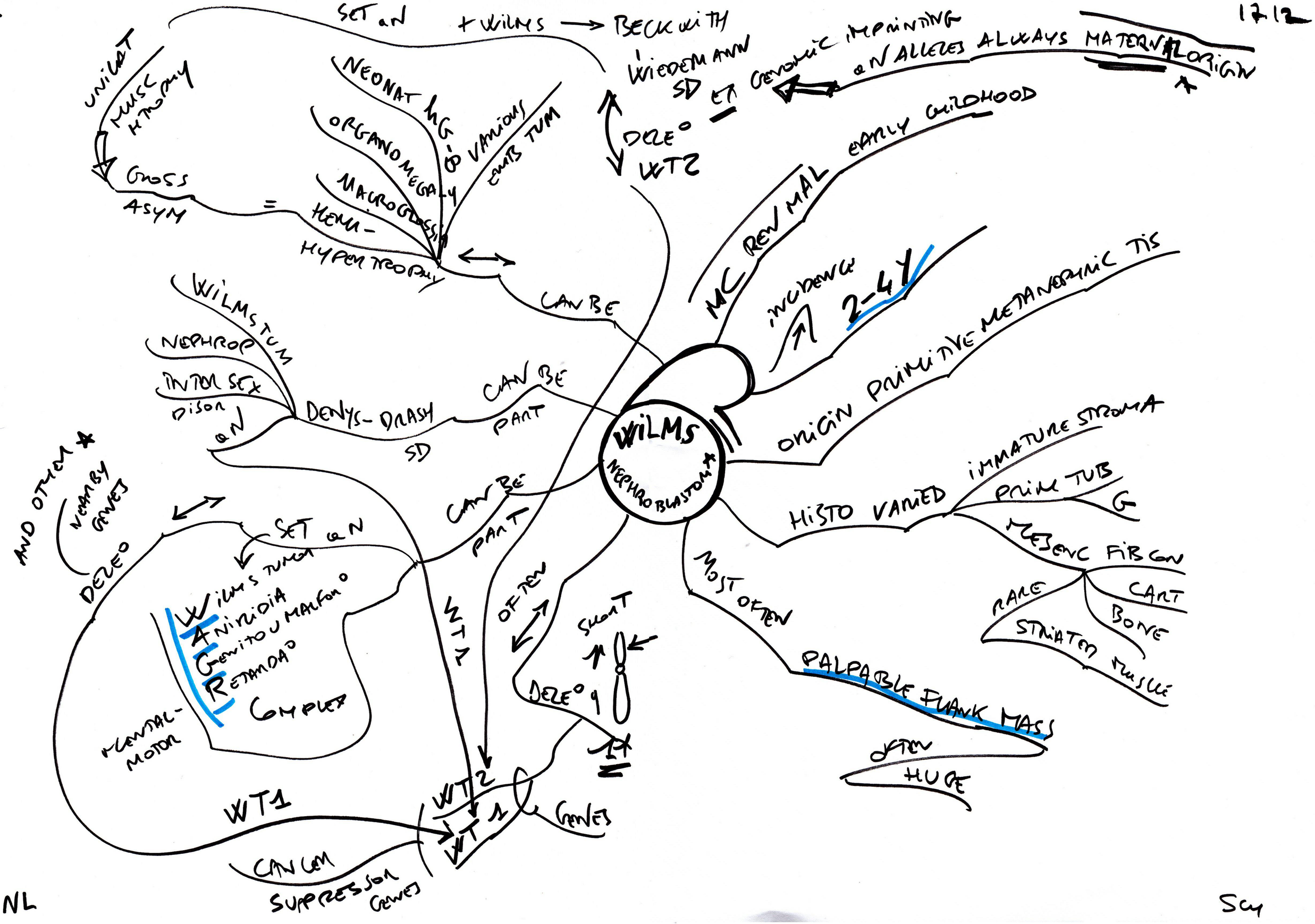
WILMS
NEPHROBLASTOMA
SET ON
+ WILMS → BECKWITH
WIEDEMANN SD
GENOMIC IMPRINTING ON ALLELES ALWAYS MATERNAL ORIGIN
DELE° WT2
UNILAT
MUSC HYPOPLY
GROSS ASYM
=
NEONAT hG
ORGANOMEGALY
MACROGLOSSIA
HEMI-HYPERTROPHY
VARIOUS EMBRYOM
CAN BE
MC RENAL
EARLY CHILDHOOD
INCIDENCE ↑ 2-4Y
ORIGIN PRIMITIVE METANEPHRIC TIS
IMMATURE STROMA
PRIM TUB
G
MESENC FIBCON
CART
BONE
STRIATED MUSCLE
RARE
HISTO VARIED
MOST OFTEN
PALPABLE FLANK MASS
OFTEN HUGE
WILMS TUM
NEPHROP
INTER SEX DISOR
ON
DENYS-DRASH SD
CAN BE PART
AND OTHER ★
NEARBY GENES
DELE°
SET ON
WILMS TUMOR
WAGR
ANIRIDIA
GENITOURINARY MALFOR°
RETARDAT
COMPLEX
MENTAL-MOTOR
WT1
CAN BE PART
WT2
OFTEN
SMART
DELE° 9
14
WT1
GENES
CAN CAN SUPPRESSOR GENES
NL
SCH