A = ACUTE
C = CHRONIC

LIVER

A VIRAL
- HSV-1
- CMV
- EBV
- YELLOW FEVER
- OTH VIR
- NEONAT
- AUTOIMM
- C
- EXCEPT
- G
- E
- D
- C
- B
- A
- GEN

JAUNDICE
- CONGEN HYPERBILIRUBIN-Bd
- PHYSIO NEWBORN

OTH
- SCHISTOSOMIASIS
- ECHINOCOCCUS granulosus
- LEPTOSPIROSIS

IFM
- -ITIS

MICROVESIC FATTY
- TETRACYCLINE TOXICITY
- PREGNANCY
- REYE SD

ALCOHOLIC D
- FATTY CHANGE
- STEATOSIS
- -ITIS
- CIR

CIRRHOSIS
- GEN
- ALC
- LAENNEC NUT
- POSTNEC
- MACRONOD POSTHEP
- BILIARY I
- II
- ISCLER ING CHOLANGITIS
- HEMOCHROMATOSIS
- HEMED
- II
- WILSON D
- HEP LENT DEGEN
- INBORN ERRORS
- MET
- CLI
- MORPH

VASC
- PORTAL HT
- INFARC°
- PRE
- INTRA
- POST
- BUDD-CHIARI SD
- CONGES CHF

TUM
- BEN
- HEMANGIOMA
- ADENOMA
- MAL
- METS
- HEPATOC CA
- CHOLANGIO CA
- BILE DUCT
- ANGIOSARC

GALLBLADDER
- CHOLE-
- -CYSTITIS
- IFM
- A
- C
- -LITHIASIS
- CHOLESTEROLOSIS
- STRAWBERRY
- GALL STONES
- TYPES
- CHOLEST
- PIGMENT
- MIXED
- CLI
- COMPLIC°

PANCREAS
- EXOCRINE
- -ITIS
- TUM
- C
- A
- OTH
- ADENO CA

TUM
- EXTRAHEP BIL DUCTS
- AMPULLA VATER
- GALLBLADDER

CONGEN HYPERBILIRUBIN-Bd
- ROTOR
- DUBIN-JOHNSON
- CRIGLER-NAJJAR
- GILBERT
- SDS

SCHNEIDER 2013

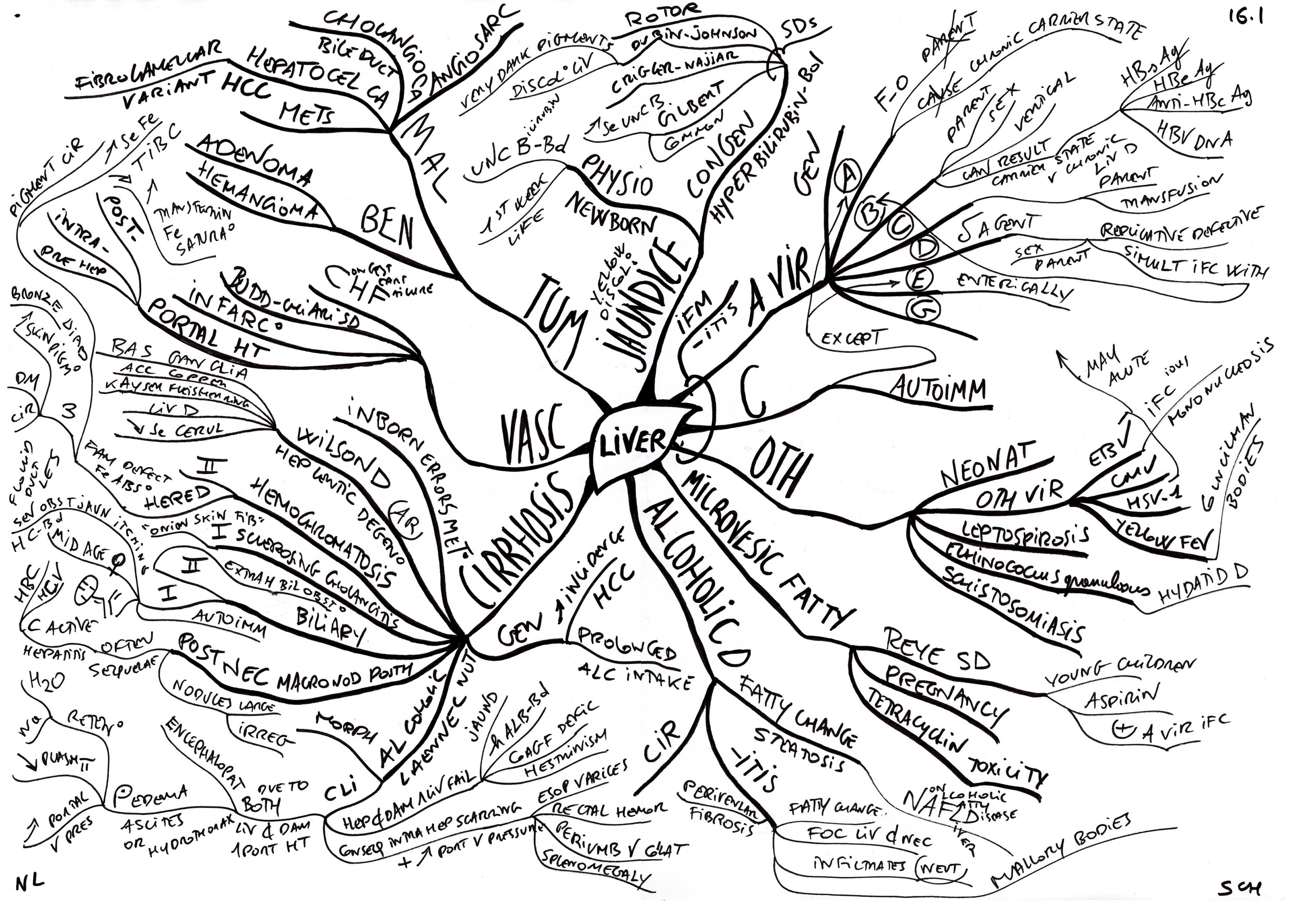
LIVER
MAL
CHOLANGIOCA
BILE DUCT
ANGIOSARC
HEPATOCEL CA
FIBROLAMELLAR
VARIANT HCC
METS
BEN
ADENOMA
HEMANGIOMA
TIBC
↑ Se Fe
PIGMENT CIR
POST-
INTRA-
PRE HEP
TRANSFERRIN
Fe SATURA°
CHF
CONGEST
CART
FAILURE
BUDD-CHIARI SD
INFARC°
PORTAL HT
BRONZE DIAB
SKIN PIGM°
DM
CIR
3
BAS GANGLIA
ACC COPPER
KAYSER FLEISCHER RING
LIV D
↓ Se CERUL
WILSON D
(AR)
HEP LENTIC DEGEN°
INBORN ERRORS MET°
FAM DEFECT
Fe ABS°
HERED
II
HEMOCHROMATOSIS
"ONION SKIN FIB"
I SCLEROSING CHOLANGITIS
II
EXTRAH BIL OBST°
I
BILIARY
AUTOIMM
FLUID DUCT LES
SEV OBST JAUN ITCHING
HC-Bd
MID AGE
HBC
HCV
C ACTIVE
HEPATITIS
OFTEN
SEQUELAE
POST NEC MACRONOD POSTH
NODULES LARGE
IRREG
MORPH
AL COHOLIC
LAENNEC NUT
CLI
ENCEPHALOPAT
DUE TO
BOTH
LIV & DAM
↑ PORT HT
PEDEMA
ASCITES
OR HYDROTHORAX
↑ PORTAL
V PRES
H2O
Na
RETEN°
↓ PLASM π
VASC
CIRRHOSIS
GEN
↑ INCIDENCE
HCC
PROLONGED
ALC INTAKE
JAUND
hALB-Bd
COAGF DEFIC
HESTRINISM
HEP & DAM ↑ LIV FAIL
CONSEQ INTRA HEP SCARRING
+ ↑ PORT V PRESSURE
ESOP VARICES
RECTAL HEMOR
PERIUMB V COLAT
SPLENOMEGALY
TUM
JAUNDICE
PHYSIO
NEWBORN
1ST WEEK
LIFE
UNC B-Bd
BILIRUBIN
VERY DARK PIGMENTS
DISCOL° LIV
ROTOR
DUBIN-JOHNSON
CRIGLER-NAJJAR
↑ Se UNC B
GILBERT
COMMON
SDs
CONGEN
HYPERBILIRUBIN-Bol
IFM
-ITIS
A VIR
GEN
A
B
C
D
E
G
F-O
PARENT
CAUSE CHRONIC CARRIER STATE
PARENT
SEX
VERTICAL
CAN RESULT
CARRIER STATE
V CHRONIC LIV D
HBs Ag
HBe Ag
ANTI-HBc Ag
HBV DNA
PARENT
TRANSFUSION
SAGENT
REPLICATIVE DEFECTIVE
SEX
PARENT
SIMULT IFC WITH
ENTERICALLY
EXCEPT
C
AUTOIMM
OTH
MICROVESIC FATTY
NEONAT
OTH VIR
EBV
CMV
HSV-1
YELLOW FEV
MAY
ACUTE
IFC
IOUS
MONONUCLEOSIS
GUNCILMAN BODIES
LEPTOSPIROSIS
ECHINOCOCUS granulosus
SCHISTOSOMIASIS
HYDATID D
REYE SD
PREGNANCY
TETRACYCLIN
TOXICITY
YOUNG CHILDREN
ASPIRIN
(+) A VIR IFC
ALCOHOLIC D
FATTY CHANGE
STEATOSIS
-ITIS
NAFLD
ON LCOHOLIC FATTY DISEASE
LIVER
CIR
PERIVENLAR
FIBROSIS
FATTY CHANGE
FOC LIV & NEC
INFILTRATES (NEUT)
MALLORY BODIES
NL
SCH

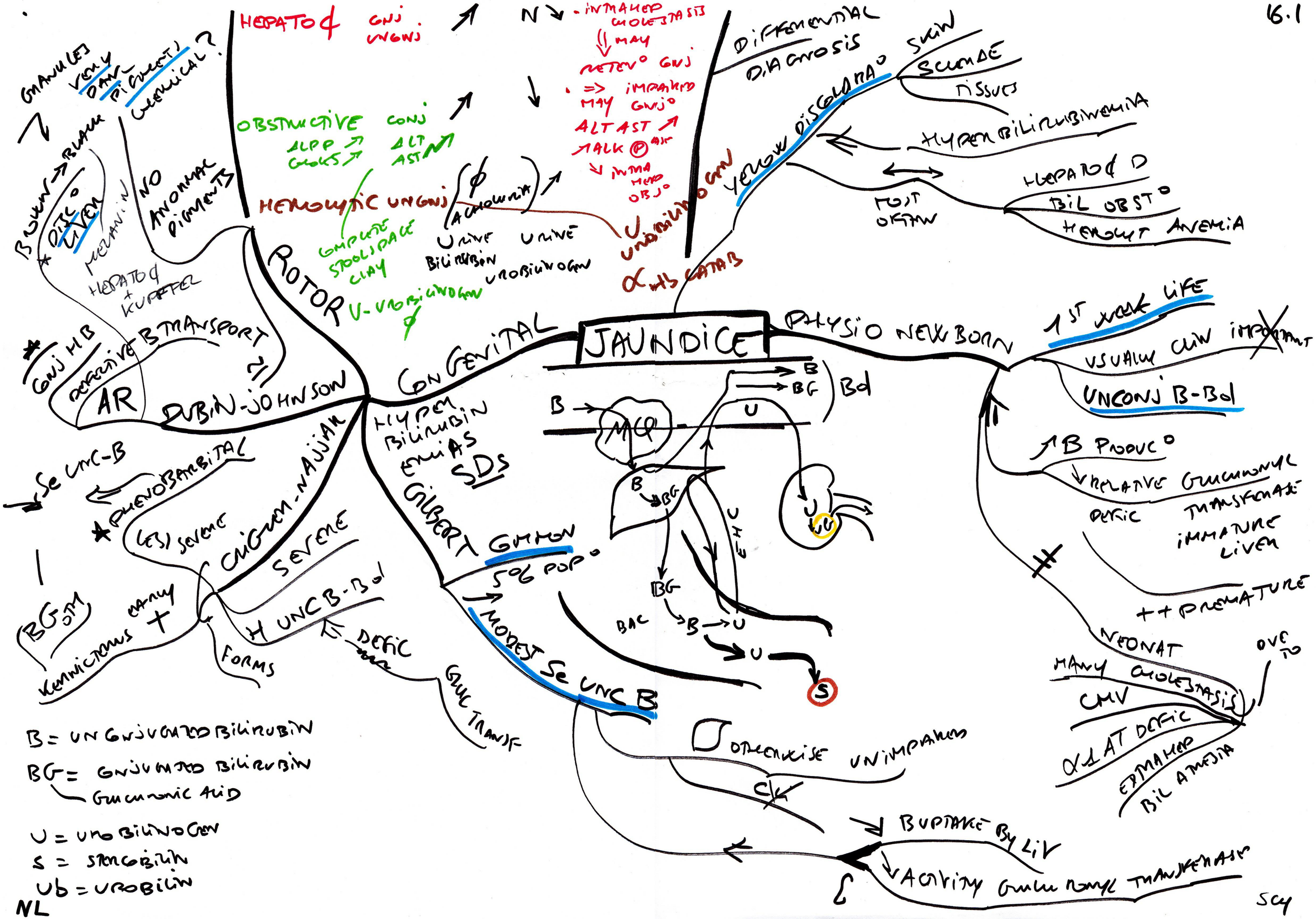
JAUNDICE
ROTOR
CONGENITAL
PHYSIO NEWBORN
DIFFERENTIAL DIAGNOSIS
HEPATO ¢
CONJ
UNCONJ
N
INTRAHEP CHOLESTASIS
MAY
RETEN° CONJ
=> IMPAIRED MAY CONJ°
ALT AST
ALK P
INTRA HEP OBJ°
OBSTRUCTIVE
CONJ
ALPP
GLOKS
ALT AST
HEMOLYTIC UNCONJ
ACHOLURIA
U RINE BILIRUBIN
U RINE UROBILINOGEN
COMPLETE STOOLSPACE CLAY
U-UROBILINOGEN
U UROBILINOGEN
α HB CATAB
YELLOW DISCOLORA°
SKIN
SCLERAE
TISSUES
HYPERBILIRUBINEMIA
MOST OFTEN
HEPATO ¢ D
BIL OBST°
HEMOLYT ANEMIA
GRANULES
VERY DAN
PIGMENTS
CHEMICAL?
BROWN → BLACK
DISC° LIVER
MELANIN
HEPATO ¢ + KUPFFER
NO ANORMAL PIGMENTS
CONJ HB
DEFECTIVE B TRANSPORT
AR
DUBIN-JOHNSON
Se UNC-B
PHENOBARBITAL
LESS SEVERE
CRIGLER-NAJJAR
SEVERE
H UNC B-Bd
DEFIC
GLUC TRANSF
FORMS
BG OTH
KERNICTERUS
EARLY
HYPER BILIRUBIN EMIAS
SDS
GILBERT
COMMON
5% POP°
MODEST Se UNC B
B
MQ
BG
U
Bd
EHC
BAC
S
OTHERWISE UNIMPAIRED
BUPTAKE BY LIV
ACTIVITY GLUCURONYL TRANSFERASE
1ST WEEK LIFE
USUALLY CLIN IMPORTANT
UNCONJ B-Bd
B PRODUC°
RELATIVE GLUCURONYL TRANSFERASE
DEFIC
IMMATURE LIVER
++ PREMATURE
NEONAT
MANY CHOLESTASIS
CMV
α1 AT DEFIC
EXTRAHEP BIL ATRESIA
DUE TO
B = UNCONJUGATED BILIRUBIN
BG = CONJUGATED BILIRUBIN
GLUCURONIC ACID
U = UROBILINOGEN
S = STERCOBILIN
Ub = UROBILIN
NL
SCY

ACUTE VIRAL HEPATITIS

A

- HIGH INCIDENCE
- RECENTLY 2006
- WHEN OCCURRING IN PREGNANCY
- HCC
- ? ↔
- * NO
- CHRONIC
- UNDERDEVELOPED
- 1/3 WORLD
- WARM BORNE EPIDEMIC
- ≃ HAV
- F-O
- ENTERICALLY
- CONCURRENT INFECTION
- ↔ IV DRUG USERS
- SEX PARTNER
- REPLICATING OFFSPRING
- RECOVIR
- SIMULT
- VACCINE HBV
- RNA
- + HDAg
- SPHERICAL
- SMALL
- JAUNDICE SYMPTOMS
- ALT
- FREQUENT
- CHRONIC
- CARRIER
- HCC
- FREQ
- DETECT
- TRANSFUSION
- FREQUENT CARRIER
- TEST
- PARENT
- HBsAg
- HBe Ag
- DNA-P
- HBV-DNA
- Anti-HBs
- Anti-HBc
- Anti-HBe
- Anti-HBc-IgM
- NL

G

- FREQUENT
- MOST ACUTE?
- SIGNIFICANCE CHRONIC
- PATHO ?
- HEALTHY BLOOD DONORS
- 1%-2%
- PARENT
- = GBV-C RNA
- ~ SS RNA
- E

F

- ASPARTATE ALANINE AMINOTRANSFERASES
- → * EXTREMELY Se
- JAUNDICE
- CHAR
- ↔ NO ↔ HCC ?

D

- GAT HBsAg
- D
- SS RNA
- ↔ AGENT

C

- PARTIALLY DS DNA
- e
- = DANE PARTICLE

NON

- SS RNA

GEN

B

- SS RNA
- DNA POL
- CORE
- LP
- SAT
- GAT
- ↔ ∞

A

- VIR
- EBV
- CMV
- USUALLY
- ↔
- @ @ → VP

RECOVERY ALMOST ALWAYS OCCURS

- F-O
- PARENT
- INCUBA°
- 15-45D
- CHARACTERISTIC
- MIN STATE
- OR → CHRONIC
- NO
- RARE ° HCC

INCUBATION 60-90D

- PARENT
- SEX
- VERTICAL
- WOMEN → MORE HOMOSEXUEL
- MEN → NEON
- MAJOR ↔ HCC
- HEPATOC "GROUNDGLASS"
- CAN CARRIER
- CHRONIC
- FREQUENT
- SEQUENCE
- Ag or Ab ?!
- ▲ APPEAR → CLINICAL SIGNIFICANCE

BEFORE SYMPTOMS → CLI

- A
- e INFECTIVITY
- DNA
- 6M → CANNOT ANTIS - RECOVERY + IMMUNITY
- 3-4M
- ANTI©

HAV

- GPT
- ANTI HAV
- 16.1
- IgG
- IgM

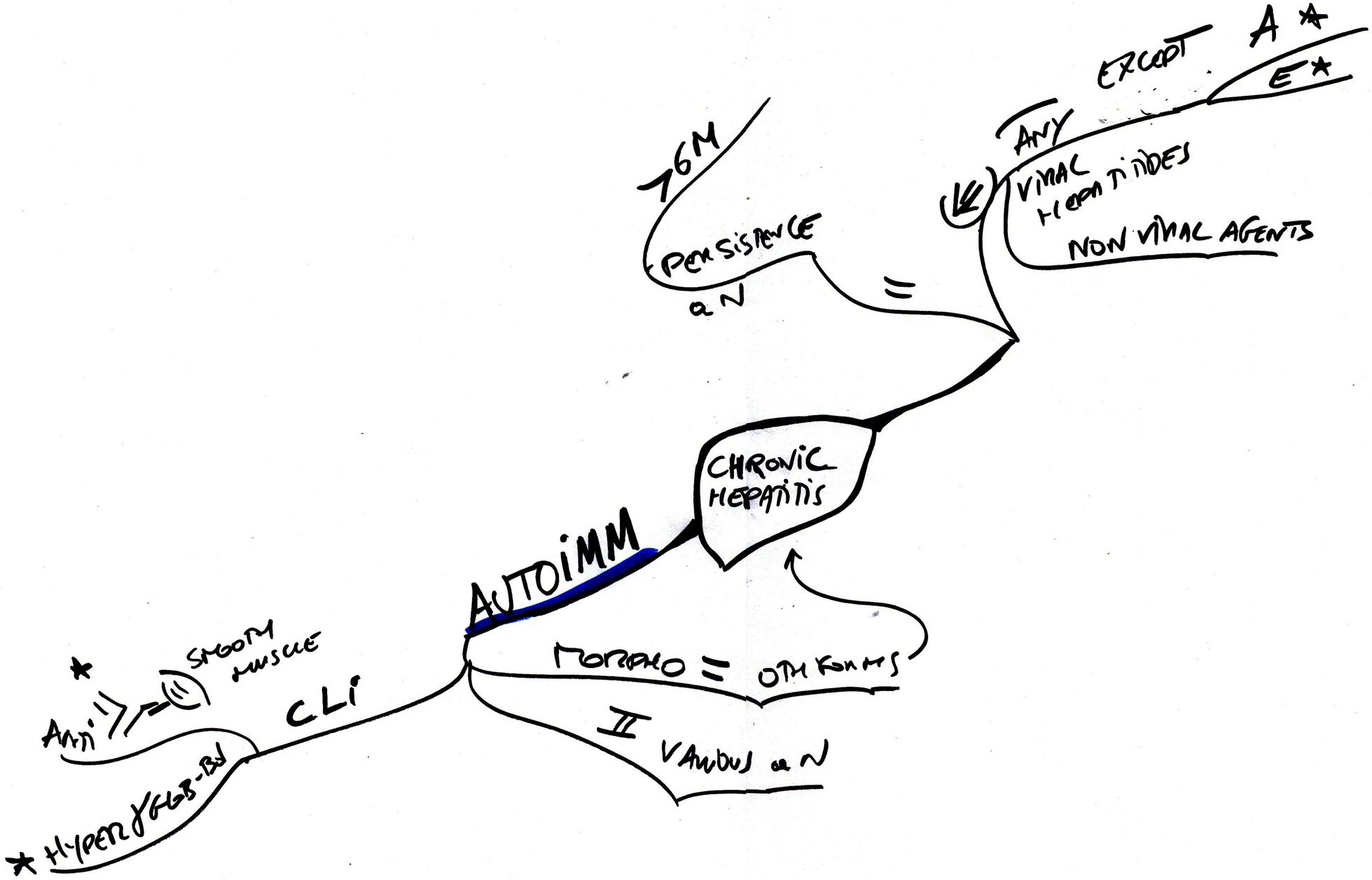
AUTOIMM
CHRONIC HEPATITIS
MORPHO = OTH FORMS
II VARIOUS aN
CLI
* ANTI ⟩ = (||) SMOOTH MUSCLE
* HYPER γ GLOB-BJ
PERSISTENCE aN
>6M
=
ANY EXCEPT A *
E *
VIRAL HEPATITIDES
NON VIRAL AGENTS

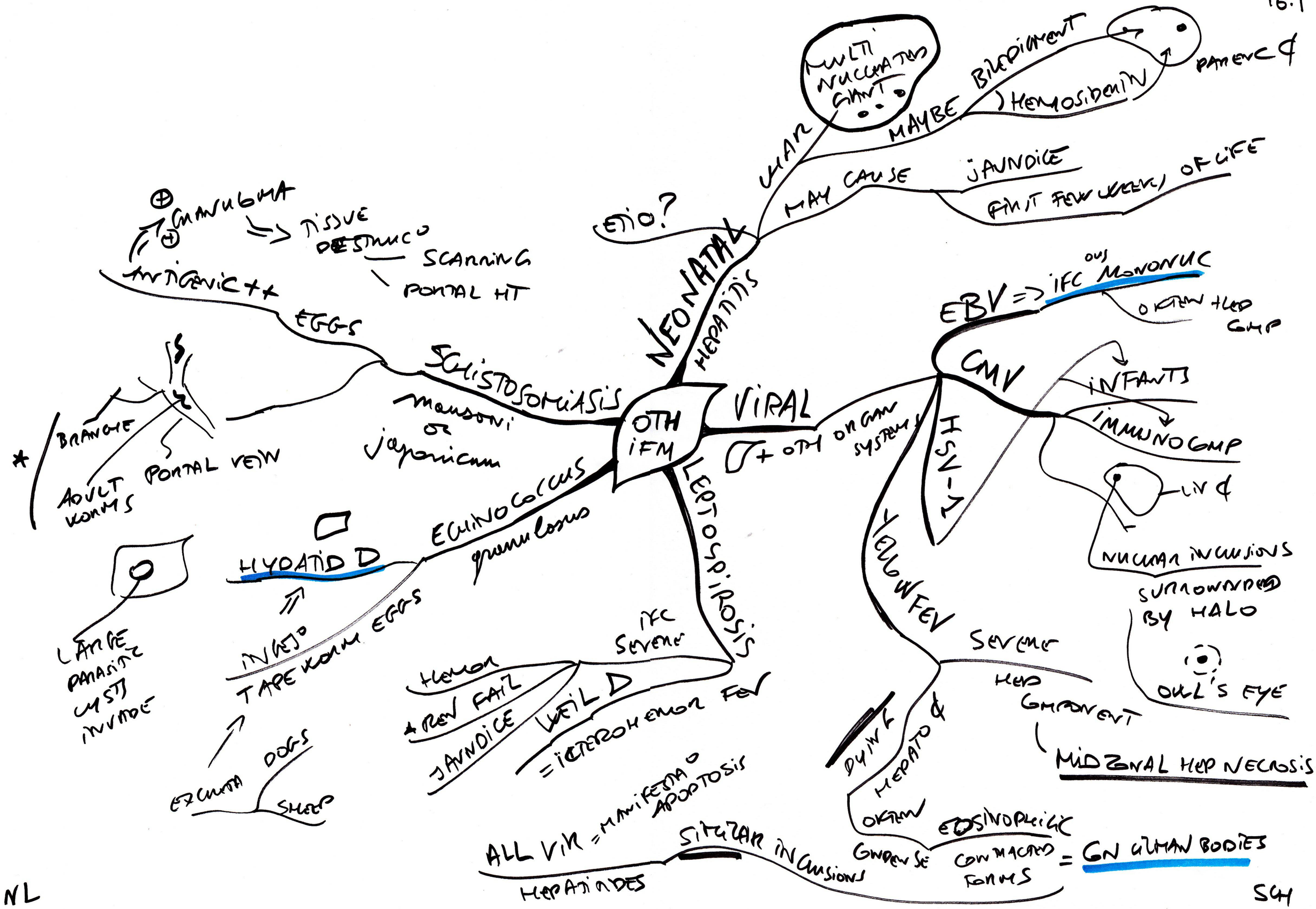
OTH IFM
NEONATAL
HEPATITIS
ETIO?
WAR
MULTI NUCLEATED GIANT
MAYBE
BILEDIGMENT
HEMOSIDERIN
PARENC ¢
MAY CAUSE
JAUNDICE
FIRST FEW WEEKS OF LIFE
VIRAL
+ OTH ORGAN SYSTEMS
EBV => IFC OUS MONONUC
OKTEN HEP COMP
CMV
INFANTS
IMMUNOCOMP
LIV ¢
NUCLEAR INCLUSIONS
SURROUNDED BY HALO
OWL'S EYE
HSV-1
YELLOWFEV
SEVERE
HEP COMPONENT
MIDZONAL HEP NECROSIS
DYING
HEPATO ¢
OKTEN
EOSINOPHILIC
CONDENSE
CONTRACTED FORMS
= CONCILMAN BODIES
LEPTOSPIROSIS
IFC SEVERE
HEMOR
+ REN FAIL
JAUNDICE
WEIL D
= ICTEROHEMOR FEV
ECHINOCOCCUS
granulosus
HYDATID D
INGEST°
TAPEWORM EGGS
EXCRETA
DOGS
SHEEP
LARGE PARASITIC CYSTS INVADE
SCHISTOSOMIASIS
mansoni or japonicum
EGGS
ANTIGENIC ++
GRANULOMA
TISSUE DESTRUC°
SCARRING
PORTAL HT
BRANCHE
ADULT WORMS
PORTAL VEIN
ALL VIR = MANIFESTA° APOPTOSIS
HEPATITIDES
SIMILAR INCLUSIONS

NL

SCH

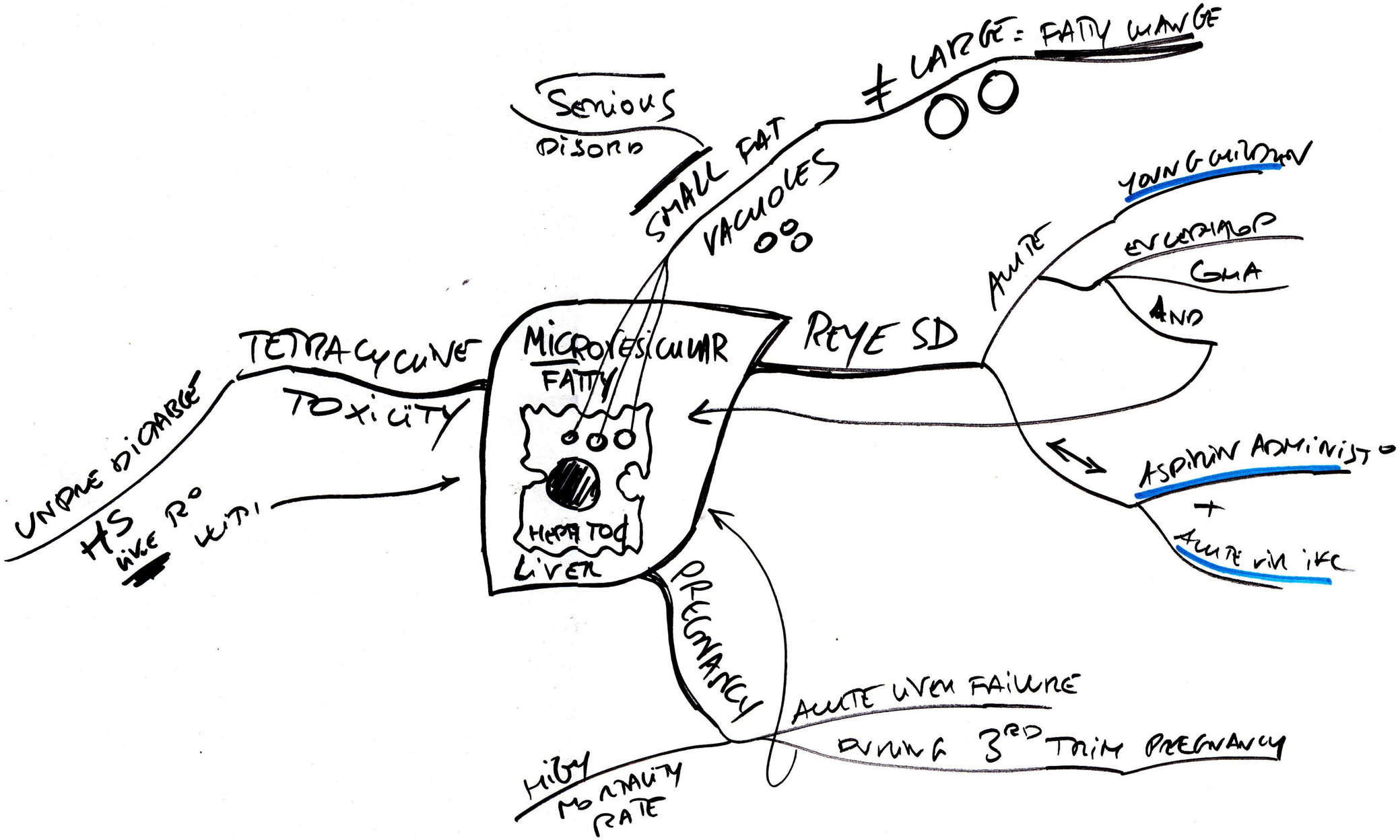
≠ LARGE = FATTY CHANGE
Serious
DISORD
SMALL FAT
VACUOLES
YOUNG CHILDREN
ENCEPHALOP
COMA
AND
ACUTE
REYE SD
TETRACYCLINE
TOXICITY
MICROVESICULAR
FATTY
HEPATOC
LIVER
UNPRE DICTABLE
HS
LIKE RO
ASPIRIN ADMINISTO
+
ACUTE VIR IFC
PREGNANCY
ACUTE LIVER FAILURE
DURING 3RD TRIM PREGNANCY
HIGH
MORTALITY
RATE

NL

SCH

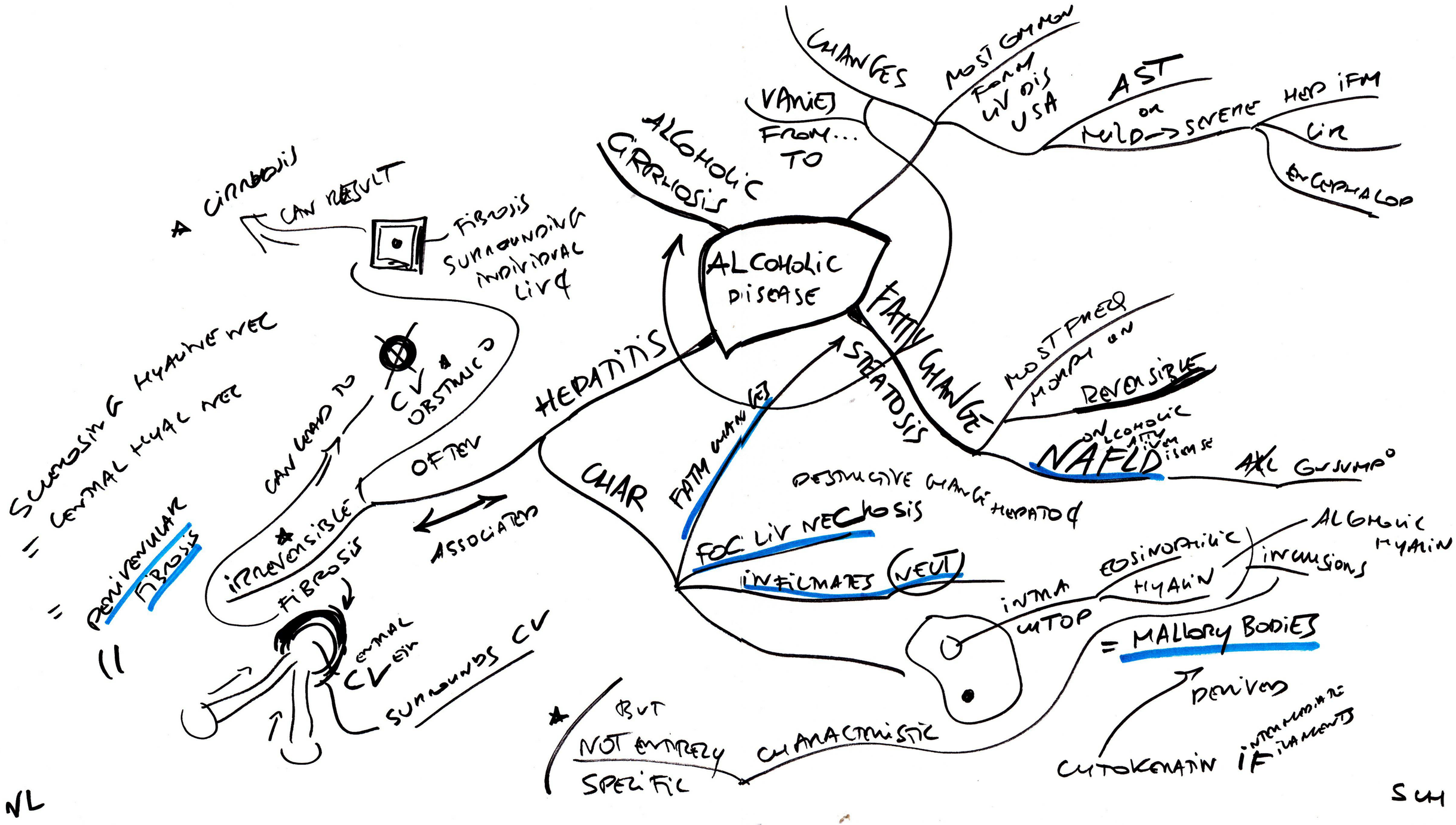
ALCOHOLIC DISEASE
ALCOHOLIC CIRRHOSIS
CHANGES
VARIES FROM... TO
MOST COMMON FORM LIV DIS USA
AST
OR
MILD → SEVERE
HEP IFM
LIR
ENCEPHALOP
FATTY CHANGE
STEATOSIS
MOST FREQ MORPH ON
REVERSIBLE
ON ALCOHOLIC FATTY LIVER DISEASE
NAFLD
ALC CONSUMP°
HEPATITIS
CHAR
FATTY CHANGES
DESTRUCTIVE CHANGE HEPATO¢
FOC LIV NECROSIS
INFILTRATES (NEUT)
INTRA CUTOP
EOSINOPHILIC HYALIN
ALCOHOLIC HYALIN
INCLUSIONS
= MALLORY BODIES
DERIVED
CYTOKERATIN IF INTERMEDIATE FILAMENTS
BUT NOT ENTIRELY SPECIFIC
CHARACTERISTIC
OFTEN
ASSOCIATED
CAN LEAD TO
CV OBSTRUC°
IRREVERSIBLE FIBROSIS
CENTRAL CV EIN
SURROUNDS CV
CIRRHOSIS
CAN RESULT
FIBROSIS SURROUNDING INDIVIDUAL LIV¢
SCLEROSING HYALINE NEC
= CENTRAL HYAL NEC
= PERIVENULAR FIBROSIS
NL
SCH

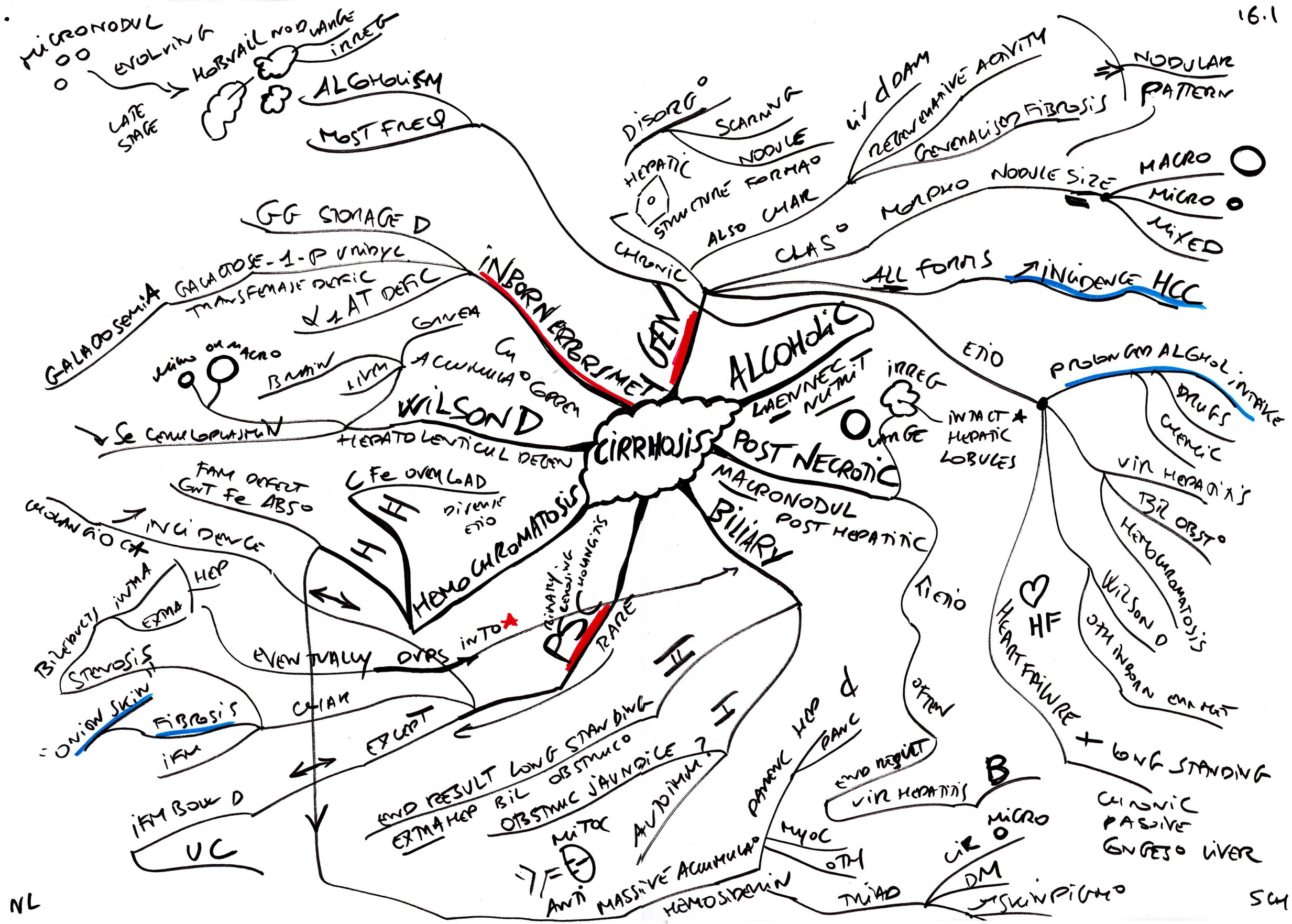
CIRRHOSIS
GEN
INBORN ERRORS MET
ALCOHOLIC
POST NECROTIC
BILIARY
HEMOCHROMATOSIS
WILSON D
MICRONODUL
EVOLVING
LATE STAGE
HOBVAIL NOD
LARGE
IRREG
ALCOHOLISM
MOST FREQ
DISORG°
SCARRING
NODULE
HEPATIC
STRUCTURE FORMA°
ALSO CHAR
CHRONIC
REGENERATIVE ACTIVITY
GENERALISED FIBROSIS
NODULAR PATTERN
MACRO
MICRO
MIXED
NODULE SIZE
MORPHO
CLAS°
ALL FORMS
INCIDENCE HCC
ETIO
PROLONGED ALCOHOL INTAKE
DRUGS
CHEMIC
VIR HEPATITIS
BIL OBST°
HEMOCHROMATOSIS
WILSON D
OTH INBORN ERR MET
HF
HEART FAILURE + LONG STANDING
CHRONIC PASSIVE CONGES° LIVER
GG STORAGE D
GALACTOSEMIA
GALACTOSE-1-P URIDYL TRANSFERASE DEFIC
α1 AT DEFIC
CORNEA
ACCUMULA° COPPER
BRAIN
LIVER
MICRO OR MACRO
Se CERULOPLASMIN
HEPATOLENTICUL DEGEN
FAM DEFECT
GNT Fe ABS°
C Fe OVERLOAD
DIVERSE ETIO
INCIDENCE
CHOLANGIO CA
BILEDUCTS INTRA
EXTRA
HEP
STENOSIS
"ONION SKIN"
FIBROSIS
IFM
EVENTUALLY OVRS INTO
PSC
RARE
CHAR
EXCEPT
IFM BOWD
UC
END RESULT LONG STANDING
EXTRA HEP BIL OBSTRUC°
OBSTRUC JAUNDICE
AUTOIMM?
MITOC
ANTI
MASSIVE ACCUMULA°
HEMOSIDERIN
PARENC HEP
PANC
MYOC
OTH
TRIAD
END RESULT
VIR HEPATITIS
B
MICRO
CIR
DM
SKIN PIGM°
NL
SCH

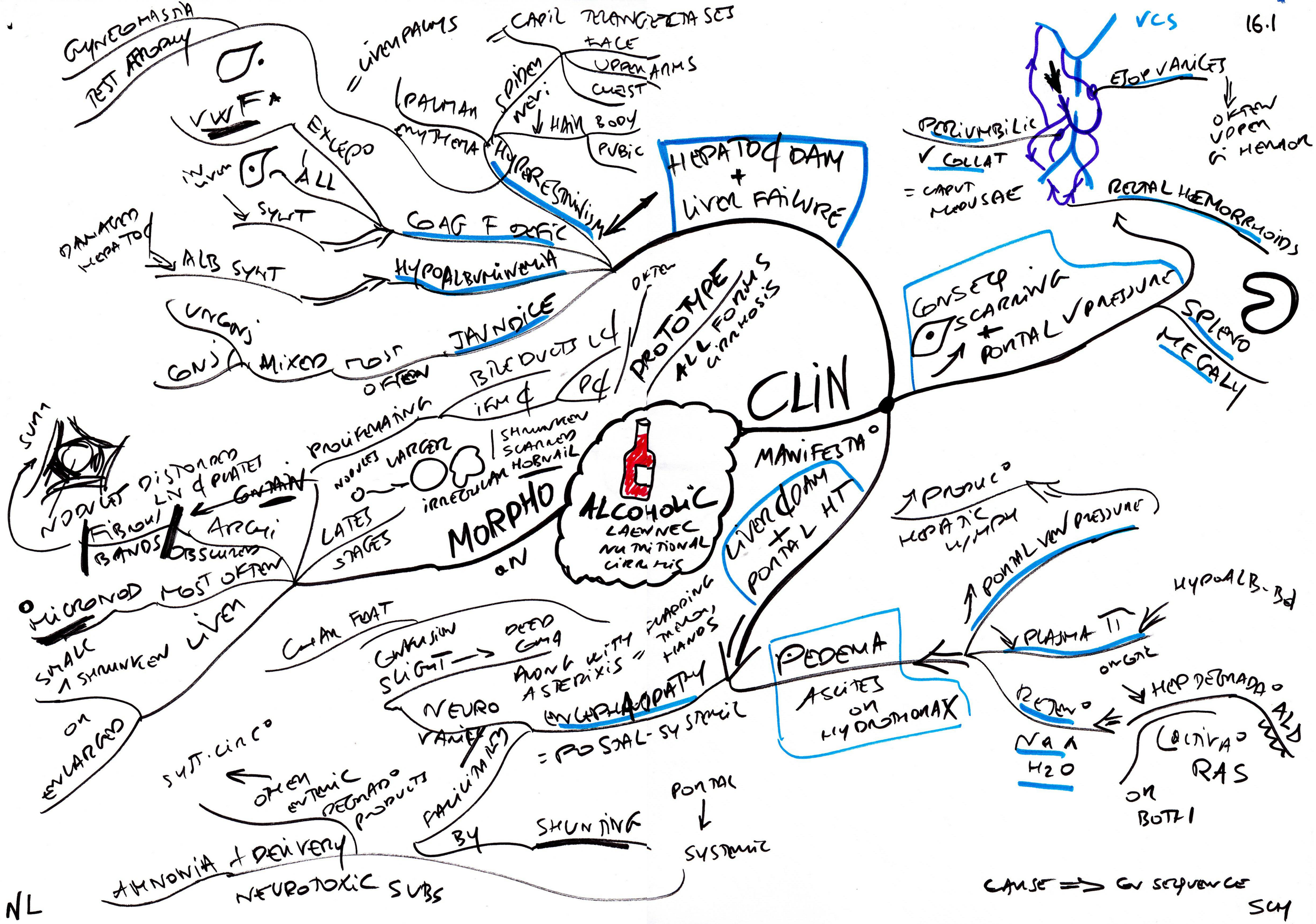
16.1
GYNECOMASTIA
TEST ATROPHY
VWF
EXCEPO
IN LIVER
ALL
SYNT
DAMAGED HEPATOC
ALB SYNT
COAG F DEFIC
HYPOALBUMINEMIA
= LIVER PALMS
PALMAR ERYTHEMA
SPIDER NEVI
CAPIL TELANGECTASES
FACE
UPPER ARMS
CHEST
HAIR BODY
PUBIC
HYPERESTRINISM
HEPATOC DAM + LIVER FAILURE
VCS
ESOP VARICES
OFTEN UPPER GI HEMOR
PERIUMBILIC
COLLAT
= CAPUT MEDUSAE
RECTAL HEMORRHOIDS
CONSEQ SCARRING + PORTAL PRESSURE
SPLENO MEGALY
UNCONJ
CONJ
MIXED
MOST OFTEN
JAUNDICE
BILE DUCTS LC
IFM C
PC
OFTEN
PROTOTYPE
ALL FORMS CIRRHOSIS
CLIN
MANIFESTA°
LIVER C DAM + PORTAL HT
PROLIFERATING
NODULES
LARGER
SHRUNKEN SCARRED
IRREGULAR
HOBNAIL
LATES STAGES
MORPHO
ON
ALCOHOLIC
LAENNEC
NUTRITIONAL CIRRHOSIS
SUM
NODULES DISTORTED LN C PLATES
CONTAIN
FIBROUS BANDS
ARCHI
OBSCURED
MICRONOD
MOST OFTEN
SMALL
SHRUNKEN
LIVER
OR ENLARGED
CHAR FEAT
CONFUSION SLIGHT → DEEP COMA
ALONG WITH ASTERIXIS = FLAPPING TREMOR HANDS
NEURO VARIES
ENCEPHALOPATHY
= POSTAL-SYSTEMIC
FACILITATED
BY SHUNTING
PORTAL
SYSTEMIC
SYST. CIRC°
OTHER ENTERIC DEGRADO PRODUCTS
AMMONIA + DELIVERY
NEUROTOXIC SUBS
PEDEMA
ASCITES OR HYDROTHORAX
PRODUC°
HEPATIC LYMPH
PORTAL VEN PRESSURE
HYPOALB-Bd
PLASMA TT
ONCOTIC
RETENO
NaA
H2O
HEP DEGRADA°
ALD
CACTIVA°
RAS
OR BOTH
CAUSE ⇒ CONSEQUENCE
NL
SCH

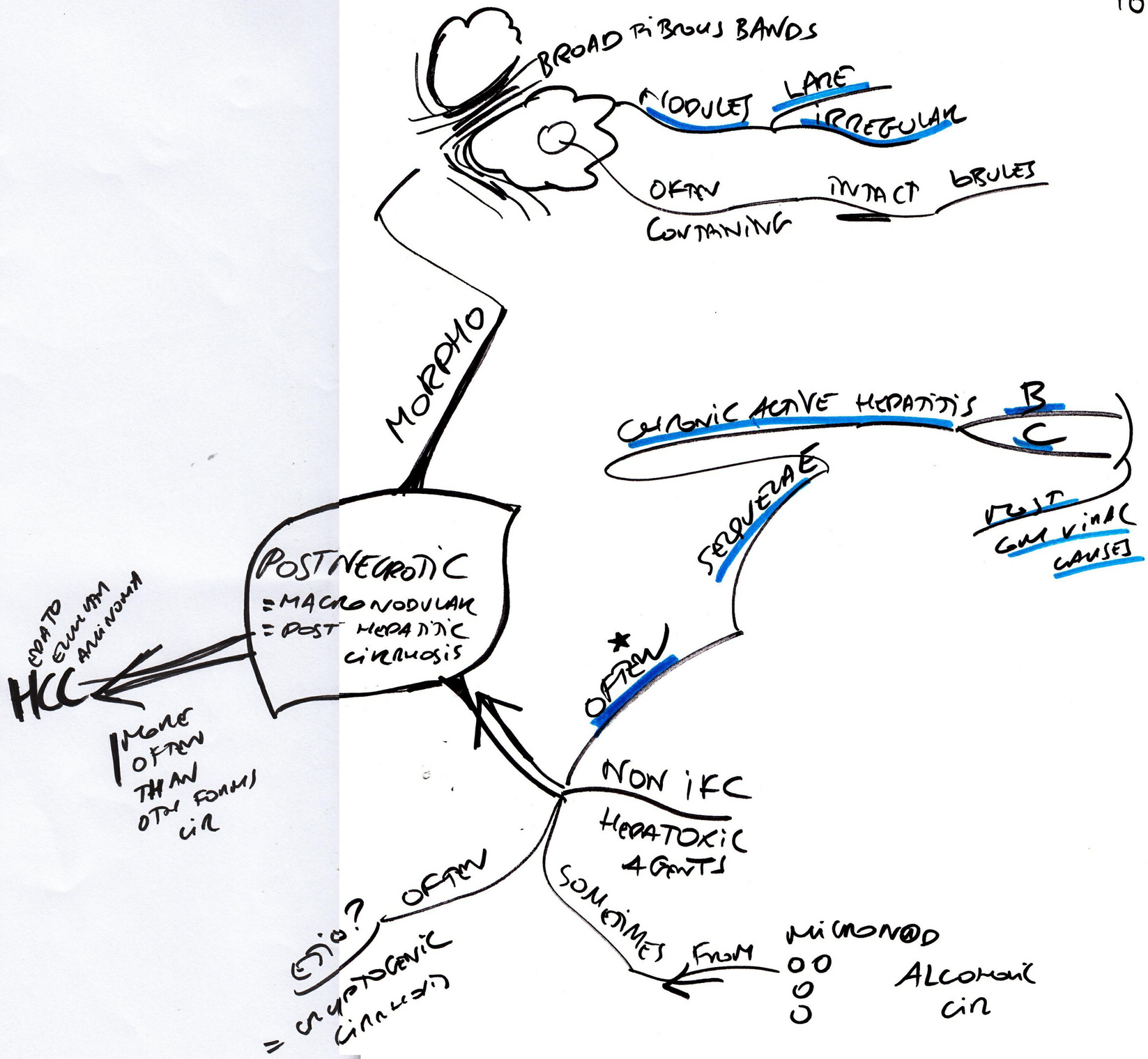
BROAD FIBROUS BANDS
NODULES
LARE
IRREGULAR
OFTEN
CONTAINING
INTACT
LOBULES
MORPHO
CHRONIC ACTIVE HEPATITIS
B
C
SEQUELAE
MOST COM VIRAL CAUSES
POSTNECROTIC
= MACRONODULAR
= POST HEPATITIC CIRRHOSIS
HCC
EPATO ELLULAR ARCINOMA
MORE OFTEN THAN OTH FORMS CIR
OFTEN
NON IFC
HEPATOXIC AGENTS
SOMETIMES
FROM
MICRONOD
ALCOHOLIC CIR
OFTEN
ETIO?
= CRYPTOGENIC CIRRHOSIS

NL

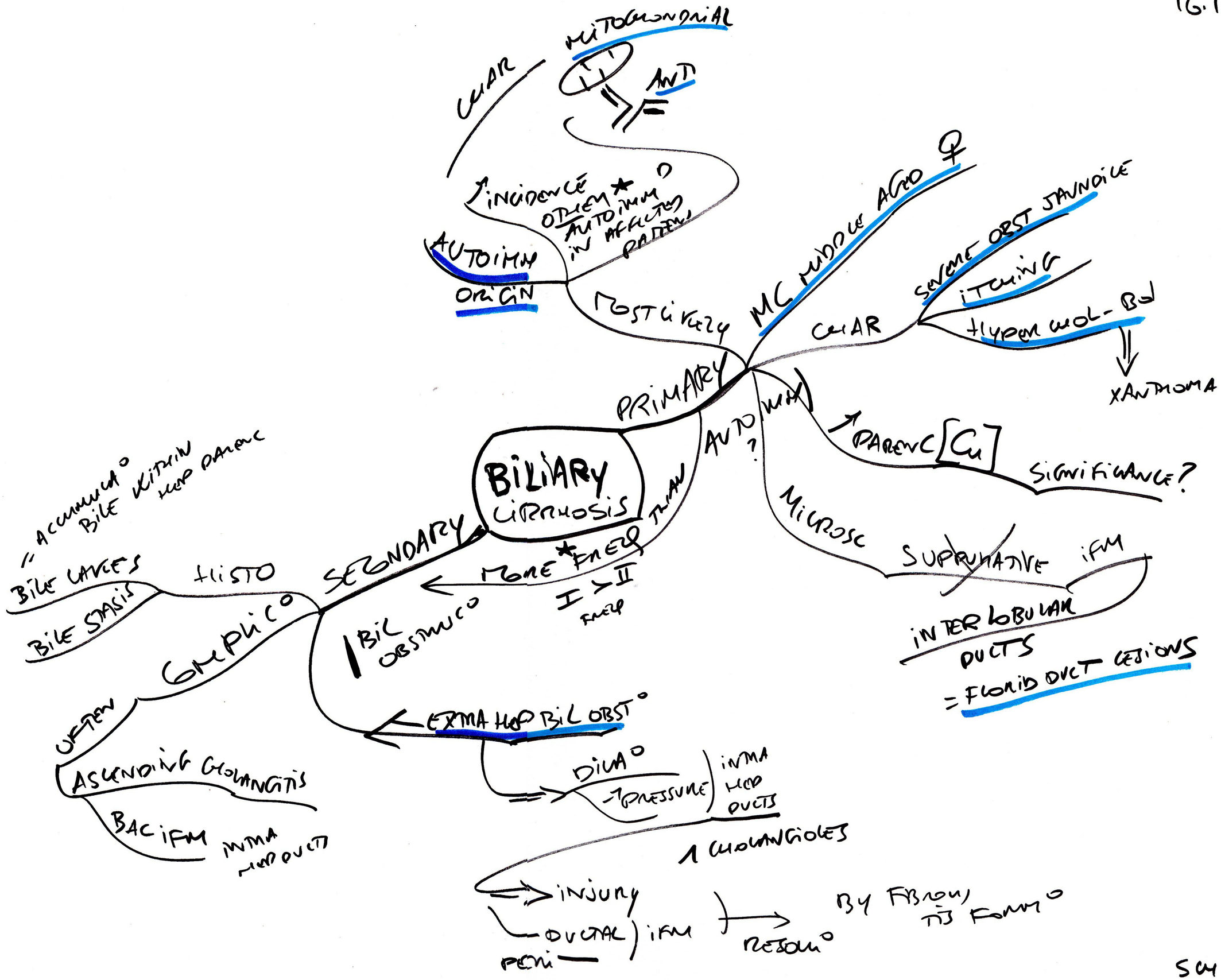
BILIARY CIRRHOSIS
PRIMARY
MC MIDDLE AGED ♀
CHAR
SEVERE OBST JAUNDICE
ITCHING
HYPERCHOL-BOL
XANTHOMA
MITOCHONDRIAL
ANTI
CHAR
↑ INCIDENCE OTHER ★ AUTOIMM IN AFFECTED PATIENTS
AUTOIMM ORIGIN
MOST LIKELY
AUTOIMM ?
↑ PARENC [Cu]
SIGNIFICANCE?
MICROSC
SUPPURATIVE
IFM
INTERLOBULAR DUCTS
= FLORID DUCT LESIONS
SECONDARY
MORE ★ FREQ THAN
I > II FREQ
BIL OBSTRUC°
EXTRA HEP BIL OBST°
DILA°
↑ PRESSURE
INTRA HEP DUCTS
↑ CHOLANGIOLES
INJURY
DUCTAL
PERI
IFM
RESOLU°
BY FIBROUS TIS FORM°
COMPLIC°
HISTO
BILE LAKES
BILE STASIS
= ACCUMULA° BILE WITHIN HEP PARENC
OFTEN
ASCENDING CHOLANGITIS
BAC IFM
INTRA HEP DUCTS

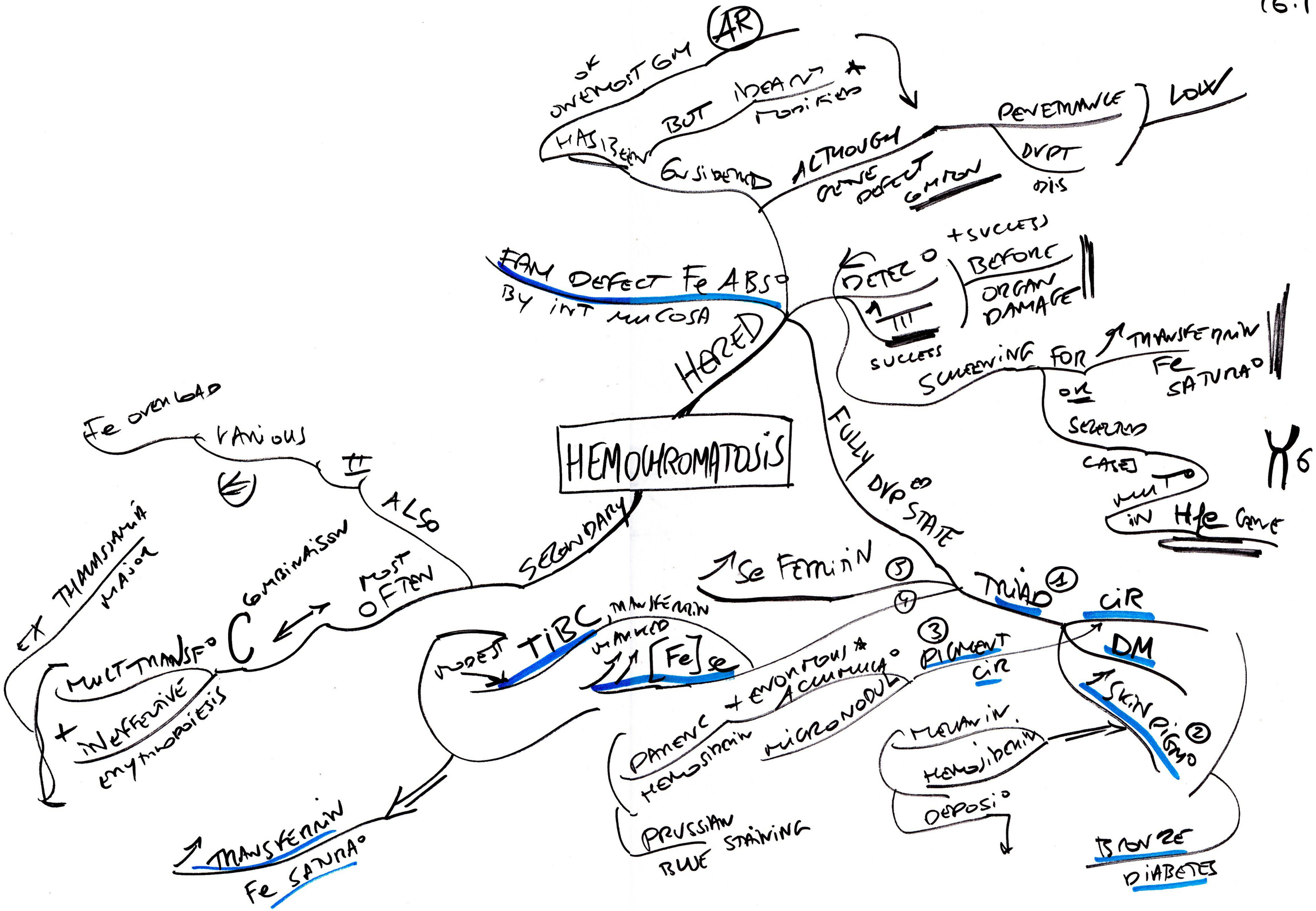
HEMOCHROMATOSIS
HERED
AR
OK
OVERMOST GM
HAS BEEN
BUT IDEAL
MODIFIED
CONSIDERED
ALTHOUGH
GENE DEFECT COMMON
PENETRANCE
DVPT
DIS
LOW
FAM DEFECT Fe ABS°
BY INT MUCOSA
DETEC°
+ SUCCESS
BEFORE
ORGAN DAMAGE
III
SUCCESS
SCREENING FOR
TRANSFERRIN
Fe SATURA°
OR
SELECTED
CASES
MUT°
IN Hfe GENE
6
FULLY DVP ED STATE
SECONDARY
ALSO
II
VARIOUS
Fe OVERLOAD
EX THALASSAMIA MAJOR
MULT TRANSF°
+ INEFFECTIVE ERYTHROPOIESIS
C
COMBINAISON
MOST OFTEN
TRANSFERRIN
Fe SATURA°
MODEST
TIBC, TRANSFERRIN
MARKED
[Fe]se
Se FERRITIN
5
4
TRIAD
1
CIR
DM
SKIN PIGM°
2
3
PIGMENT
CIR
PARENC
+ ENORMOUS ACCUMULA°
HEMOSIDERIN
MICRONODUL
PRUSSIAN BLUE STAINING
MELANIN
HEMOSIDERIN
DEPOSI°
BRONZE
DIABETES

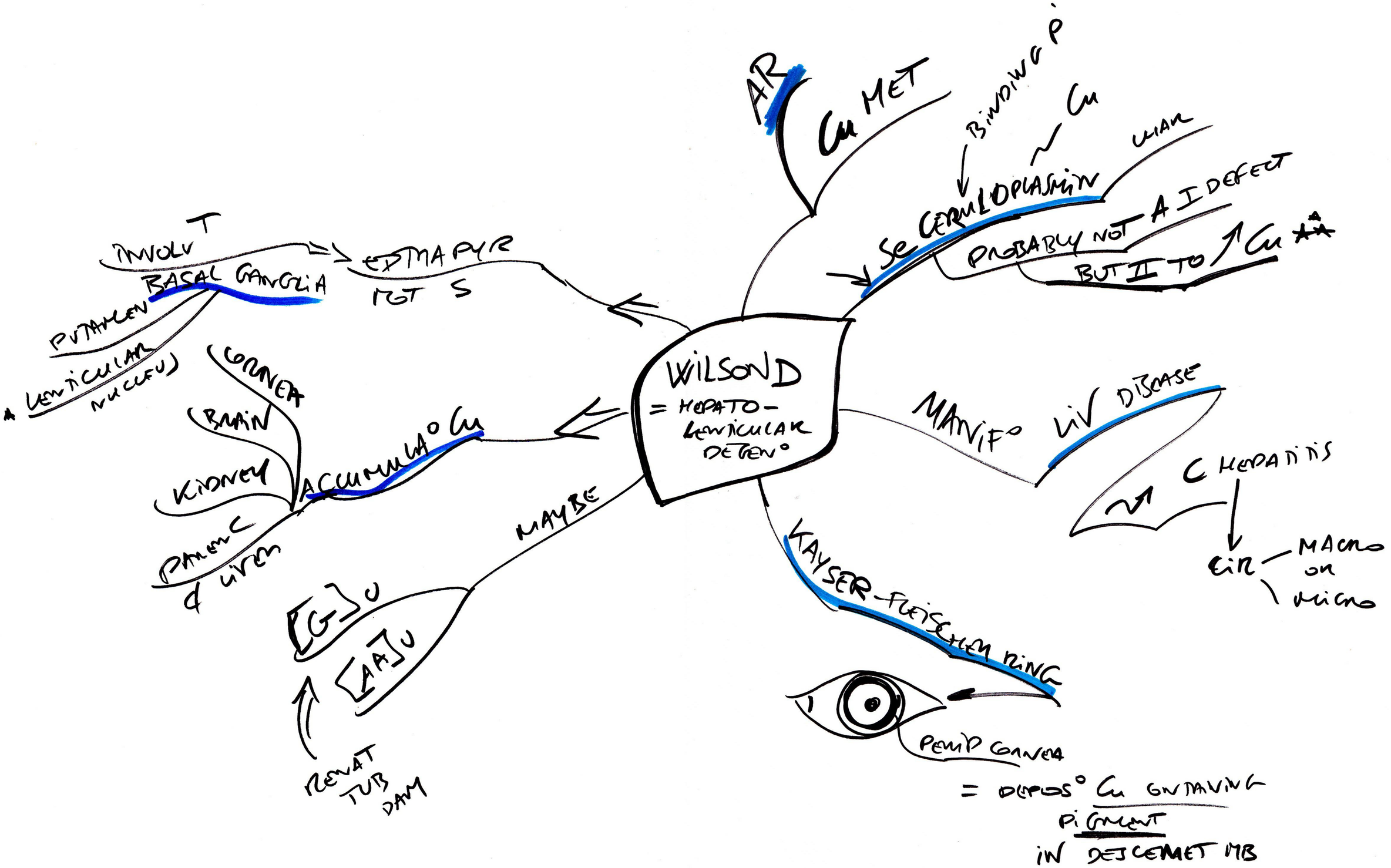
WILSON D
= HEPATO-LENTICULAR DEGEN°
AR
Cu MET
BINDING P
Cu
Se CERULOPLASMIN
LIAR
PROBABLY NOT A I DEFECT
BUT II TO ↑ Cu **
MANIF° LIV DISEASE
C HEPATITIS
CIR
MACRO OR MICRO
KAYSER-FLEISCHER RING
PERIP CORNEA
= DEPOS° Cu CONTAINING PIGMENT IN DESCEMET MB
MAYBE
[G]U
[AA]U
RENAT TUB DAM
ACCUMULA° Cu
CORNEA
BRAIN
KIDNEY
PARENC of LIVER
INVOLV T
BASAL GANGLIA
PUTAMEN
* LENTICULAR NUCLEUS
EPTHAPYR
NOT S

NL

SCH

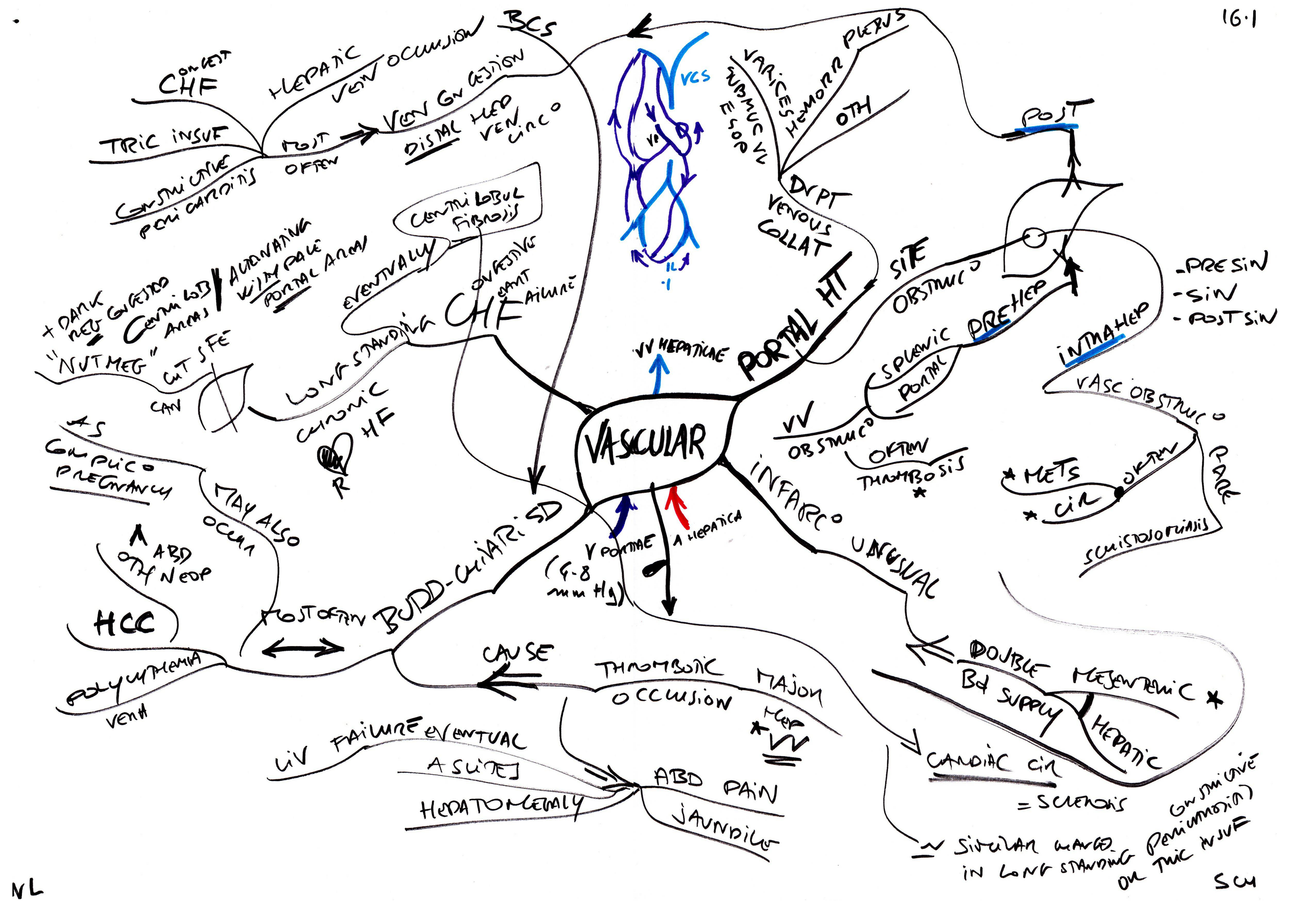
VASCULAR
PORTAL HT
BUDD-CHIARI SD
BCS
CONGEST CHF
HEPATIC VEIN OCCLUSION
TRIC INSUF
CONSTRICTIVE PERICARDITIS
MOST OFTEN
VEIN CONGESTION
DISTAL HEP VEIN CIRC°
CENTRILOBUL FIBROSIS
EVENTUALLY
ALTERNATING WITH PALE PORTAL AREAS
+ DARK REG CONGESTED CENTRILOB AREAS
"NUTMEG"
CUT SFE
CAN
LONG STANDING CHF
CHRONIC HF
R
CONGESTIVE EART FAILURE
AS COMPLIC° PREGNANCY
MAY ALSO OCCUR
ABD OTH NEOP
HCC
POLYCYTHEMIA VERA
MOST OFTEN
VCS
VARICES
SUBMUC VL ESOP
HEMORR
PLEXUS
OTH
DVPT VENOUS COLLAT
POST
SITE OBSTRUC°
PREHEP
SPLENIC PORTAL
VV OBSTRUC°
OFTEN THROMBOSIS *
INTRAHEP
VASC OBSTRUC°
-PRESIN
-SIN
-POSTSIN
RARE
* METS
* CIR
OFTEN
SCHISTOSOMIASIS
VV HEPATICAE
V PORTAE (4-8 mm Hg)
A HEPATICA
INFARC° UNUSUAL
DOUBLE MESENTERIC *
Bd SUPPLY
HEPATIC
CARDIAC CIR
= SCLEROSIS
~ SIMILAR CHANGES IN LONG STANDING CONSTRICTIVE PERICARDITIS OR TRIC INSUF
CAUSE
THROMBOTIC MAJOR OCCLUSION
HEP * VV
LIV FAILURE EVENTUAL
ASCITES
HEPATOMEGALY
ABD PAIN
JAUNDICE

NL

SCH

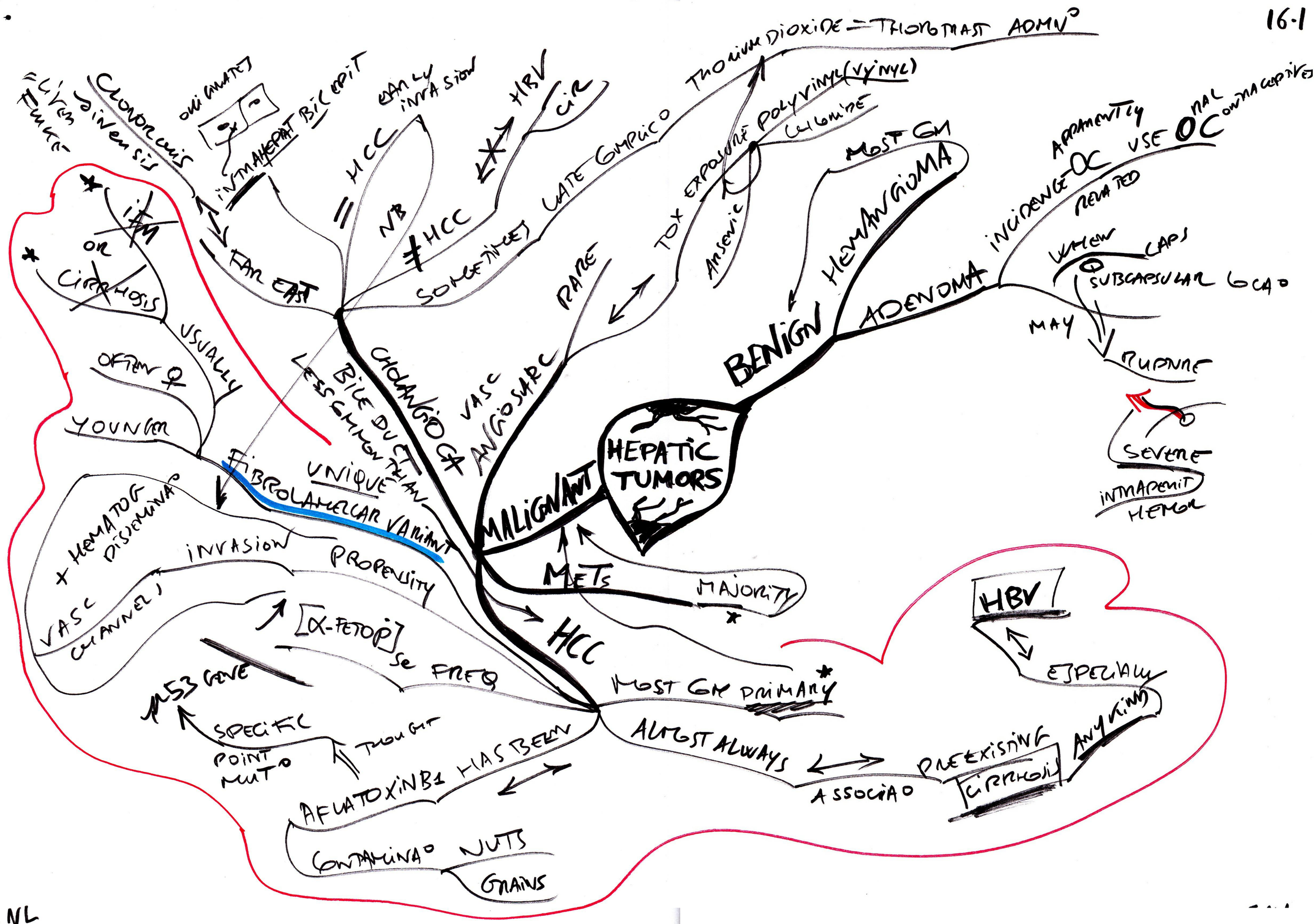
HEPATIC TUMORS
BENIGN
HEMANGIOMA
ADENOMA
MALIGNANT
HCC
CHOLANGIOCA
BILE DUCT
LESS COMMON THAN
UNIQUE
FIBROLAMELLAR VARIANT
FAR EAST
CLONORCHIS
SINENSIS
LIVER FLUKE
ORIGINATES
INTRAHEPAT BILEPIT
EARLY INVASION
HCC
NB
HCC
HBV
CIR
SOMETIMES LATE COMPLICO
THORIUM DIOXIDE = THOROTRAST ADMN°
TOX EXPOSURE
POLYVINYL (VYINYL)
CHLORIDE
ARSENIC
MOST COM
RARE
VASC ANGIOSARC
APPARENTLY INCIDENCE OC
USE OC
RELATED
WHEN
CAPS
SUBCAPSULAR LOCA°
MAY
RUPTURE
SEVERE
INTRAPERIT HEMOR
METS
MAJORITY
MOST COM PRIMARY
ALMOST ALWAYS
ASSOCIA°
PREEXISTING
CIRRHOSIS
ANY KIND
HBV
ESPECIALLY
AFLATOXINB1
HAS BEEN
CONTAMINA°
NUTS
GRAINS
SPECIFIC
POINT MUT°
THOUGHT
μ53 GENE
[α-FETOP]
Se
FREQ
PROPENSITY
INVASION
VASC CHANNELS
+ HEMATOG DISSEMINA°
USUALLY
OFTEN ♀
YOUNGER
IFM
OR
CIRRHOSIS

NL

TUMORS GALLBLADDER

ADENOCA
ALMOST
ALWAYS
OBST JAUNDICE
PROGRESSIVE
RELENTLESS
LESS COM THAN CA EXTRAHEP BILT / AMPULLA VATER
JAUND + PALP PABLE
ENLARGED GALLBLADDER
OBSTRUCTIVE CBD
OBSTRUCTIVE SIGNS DO NOT COEXIST
COURVOISIER
WALK
LHD
RHD
CHD
CBD
CD
PD
SO
MOST COMMON GALLBLADDER
ADENOCA
RARE
SPECIAL
IPM CHANCES
YOUNG
CHAR
NO ASSOCIAO
CHOLESTEROLOSIS
STRAWBERRY
MALIGNANCY
MUCOCELE
DISTENDED MUCUS-FILLED
CHRONIC CD OBSTRUCO
OFTEN GALLSTONES
GALLSTONES ILEUS
ACUTE PANCREATITIS
INT OBST OF PASSAGE
LARGE STONE THROUGH WALL ADJ STRUCTURE
INTO BOWEL
* CYSTS CONTAINING FLUKS IN ORIENTAL SEA

CHOLECYSTITIS

RECIPROCAL ASSOCIAO = EACH PREDISPOSES TO THE OTHER

ACUTE

MOST OFTEN PYOGENIC
CHOLE
NAUSEA
VOMITING
FEVER
LEUKOCYTOSIS
PAIN RIGHT UPPER QUADRANT EPIGASTRIC

CHRONIC

FREQ COMPLICATED BY
WALL THICKENING
EXTENSIVE FIBROSIS
MULTIPLE PREGNANCIES
OFTEN
OBESITY
HIGHER
INCIDENCE

CHOLELITHIASIS GALLSTONES

COMPLIC°
TYPES
CHOLEST
PIGMENT
MIXED
SOLITARY
TOO LARGE
OFTEN
TO ENTER CYSTIC DUCT OR COMMON BILE DUCT
CLI
FATTY FOOD INTOL
OFTEN
SILENT
AST
MOST COMMON
75-80%
CHAR

MALIGNANCY

ASCENDING CHOLANGITIS
OBST BILEFLOW
IFC
HYPER B-BIL
ALK PASE
HYPER CHOL-BIL
OBSTRUCTIVE JAUNDICE
IMPACTA° GALLSTONE
CBD OBSTRUC
BIL GLIC
CBD
CD
RADIOG VISUALIZED
Ca SALTS
MOST CHOLES
BACT IFC
HEMOLYT ANEMIA
OFTEN
PRECIPITATED EXCESS INSOLUBLE BILIRUBIN
UNC
SCH
NL

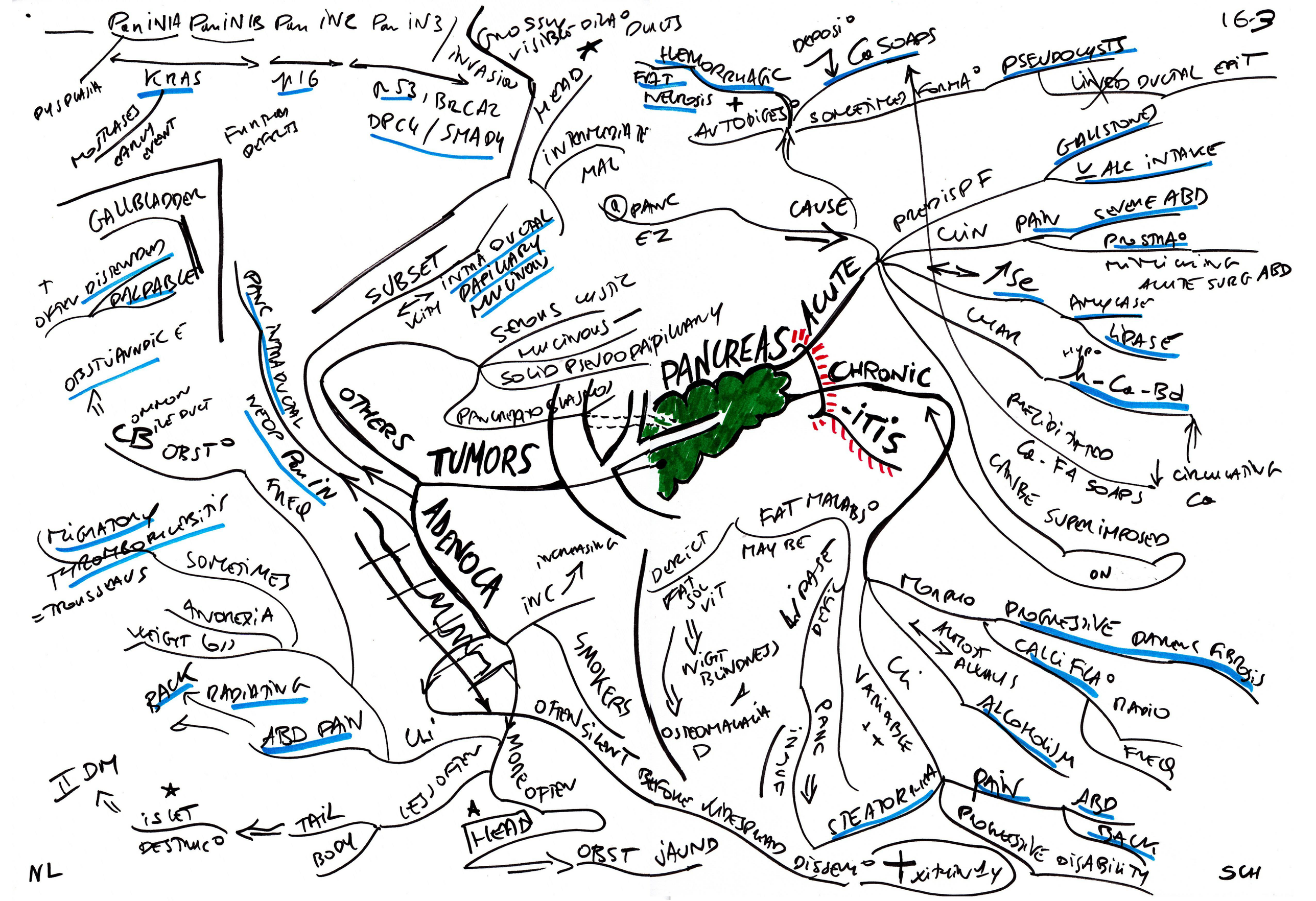
PanINIA PanINIB PanINC PanIN3
KRAS
p16
p53, BRCA2
DPC4/SMAD4
DYSPLASIA
MOSTLASES
EARLY EVENT
FUNCTION DEFECTS
INVASION
GROSSLY VISIBLE DILA° DUCTS
HEAD
INTERMEDIATE MAL
HEMORRHAGIC
FAT NECROSIS
+
AUTODIGES°
DEPOSI°
Ca SOAPS
SOMETIMES FORMA°
PSEUDOCYSTS
LINED DUCTAL EPIT
GALLSTONES
ALC INTAKE
PREDISPF
CLIN
PAIN
SEVERE ABD
PROSTRA°
MIMICKING ACUTE SURG ABD
↑Se
AMYLASE
LIPASE
CLAR
HYPO
h-Ca-Bd
PRECIPITATED Ca-FA SOAPS
CIRCULATING Ca
CANBE SUPERIMPOSED ON
@PANC
EZ
CAUSE
GALLBLADDER
+ OFTEN DISTENDED
PALPABLE
OBSTJAUNDICE
CB
COMMON BILE DUCT
OBST°
PANC INTRADUCTAL
NEOP
PanIN
FREQ
SUBSET
INTRADUCTAL PAPILLARY MUCINOUS
SERONS CYSTIC
MUCINOUS
SOLID PSEUDOPAPILLARY
PANCREATOBLASTOS
OTHERS
TUMORS
PANCREAS
ACUTE
CHRONIC
-ITIS
ADENOCA
MIGRATORY THROMBOPHLEBITIS
= TROUSSEAUS
SOMETIMES
ANOREXIA
WEIGHT LOSS
BACK
RADIATING
ABD PAIN
CLI
INC
INCREASING
SMOKERS
OFTEN SILENT BEFORE WIDESPREAD DISSEM°
FAT MALABS°
MAY BE
DERICT
FAT SOL VIT
NIGHT BLINDNESS
OSTEOMALACIA
LIPASE
DEFIC
PANC
INJUR
VARIABLE
STEATORRHEA
MORPHO
PROGRESSIVE DARENS FIBROSIS
CALCIFICA°
RADIO
FREQ
ALCOHOLISM
PAIN
ABD
BACK
PROGRESSIVE DISABILITY
XITHIN 1Y
II DM
ISLET DESTRUC°
TAIL
BODY
LESS OFTEN
MORE OFTEN
HEAD
OBST JAUND
NL
SCH