GI

COLON

IFM
- HAMAR
- IFM
- HYPOMP
- TUB
- NEOP
- TERM
- ADENOMATOUS POLYPS
- FAP
- ATTENUT
- GOL 1 RECTUM
- MULT POLYPOSIS SDs
- ADENO CA
- APC
- MISMATCH REPAIR GENES
- HNPCC
- TV
- VES
- CHOLERA
- AMEBIC COLITIS
- PSEUDOMEMBRANOUS COLITIS
- ULCERATIVE COLITIS
- BEN POLYPS

TUM
- A-ITIS
- TUM
- CARCINOID

IFM
- HEMORR
- ANGIODYSPLAS
- ISC BOWD

VASC
- ATHEROS

DIVERTIC
- -ITIS
- -OSIS
- S AI
- BRIGHT RED RECTAL BLEEDING

HIRSCHSPRUNG D
- DILAO

TUM
- METs
- GISTs
- ADENOCA
- LYMPHOMA
- NEUROENDOC
- GEN
- = CARCINOID

MALABS° SDs
- OTH
- CELIAC D

MECKEL DIVERTIC
- VOLVULUS
- INTUS
- ALL LAYERS
- GEN

CROHN D
- INFILTRATING = DIF
- INTES
- SKIP LESION
- BOWEL WALL THICK
- VIRCHOW NODE
- ADENO

PU
- H. pylori

SMALL INT

APPEND
- SURG RESEC°

MOUTH & JAW

ORAL MUC BEN
- EPULIS
- FIBR
- PAPILL
- LOBCAP
- HEMANG = PG

IFM
- A NEUROTIZING ULC GINGIVITIS
- ORAL CANDIDIASIS
- APHTHOUS STOMATITIS
- HERPES LABIALIS

TUM
- TUM-LIKE
- HAMARTOMA
- ODONTOMA
- NEVOID BASAL CELL SD = GORLIN
- 7 DENTIGEROUS
- KERATOCYST
- EPIT PREC ENAMEL
- AMELOBLASTOMA
- LEUKOPLAKIA
- ODONTOGENIC
- ORAL CANCER

SALIV GLANDS

IFM
- SIALADENITIS
- PAROTITIS
- SJÖGREN SD
- KERATOCONJUNCTIVITIS SICCA
- XEROSTOMIA
- CONNECTIVE TISSUE DIS

TUM
- MUCOCELE
- RANULA
- TUM
- BEN PAROT
- BILAT
- PLEOMORPHIC ADENOMA OTH
- LARGE
- WARTHIN ONCOCYTOMAS
- BEN
- PCL
- MUCO EPIDERMOID CA
- ADENOID CYST CA
- PERIN PAIN
- CYSTIC CA
- ALIVIA CA

ESOP

TE FIST
- MC VAR
- 2
- 3

DIVERTIC
- PULSION
- TRAC°
- LOC° ZENKER

ACHALASIA
- EPINEPHRIC

VARICES
- DILATED SUBMUC VV

IFM RELATED
- GER
- BARRETT
- COLUM METAP OF SQUAMOUS EPIT
- SALMON PINK
- PREC ADENO CA

CARCINOMA
- DYSPHAGIA
- CANDIDA-ITIS MONOCHASIS
- HERPETIC-ITIS
- LESS COM
- STRICTURE
- SCC
- 1/3
- BARRETT
- SCC
- ADENOCA
- SPREAD LOC
- EXTEN°
- CALC MASS
- PROJECTILE VOMITING
- CUSHING

STOM

CONG PYL STEN
- DUODENAL ULC
- H. pylori
- NITROSAMINES

GASTRITIS
- A: EROSIVE
- C

MENETRIER D
- CDH1
- SIGNETRING
- LOBCA
- DEFECTS
- GERMLINE
- H. pylori
- AUTOIMM

MAL TUM
- GISTs
- LYMPHOMA
- CA
- SOY ♂
- PROGESTIN

PU
- PLACEMENT of CAPITAL
- MIT COUNT SIZE LOC° COLIT
- c-KIT

IFM

HERPES LABIALIS
- PRODROME
- TRAUMA
- MENSTRUATION
- FEB ILLNESS
- OFTEN
- +ISV
- VESICULAR
- RECURR
- FEV BUSTENS
- COLD SORES

APHTHOUS STOMATITIS
- ORAL ULCERATION
- EROSIVE
- REC
- PAINFUL

ORAL CANDIDIASIS
- THRUSH
- MONILIASIS
- WHITE LOC
- MBOUCHES
- CANDIDA albicans
- DEBILITATED
- INFANT
- CHILDREN
- IMMUNOGMP
- DIABETES

CLL
- GINGIVITIS
- INFILTRATING

V MOUTH & JAW
- TUMOUR
- TUM-LIKE

BEN ORAL MUC
- LEUKOPLAKIA
  - = IRREG WHITE MUC PATCHES
  - USUAL BEN
  - USUAL CINRIT
  - HYPERKERATOSIS
  - OFTEN REPARATIVE RATHER NEOP
  - GROWTH GINGIVA
  - ANY BEN USUAL MUC
- EPULIS
  - PREGNANT
  - BUC MUC
  - LIP
  - TONG
- LOBULAR CAPIL HEMANGIOMA = PYOGENIC GRANULOMA
- FIBROMA
  - HYPERPLASTIC
  - MOST OFTEN
  - C IRRITATED
- PAPILLOMA
  - MC BEN
  - ANY WHERE MC
  - MUCOSA GING
  - TONGUE LIPS

TUMA
- TUM-LIKE
- ODONTOGENIC
  - KERATOCYST
  - AMELOBLASTOMA
  - EPIT PART ENAMEL
  - MANDIBLE
  - <35Y
  - ODONTOMA
    - MC
    - CIS
    - DYSP
    - BUT
    - IMPACTED TEETH
    - CAN RESORB
- CA MOUTH
  - BETEL NUTS
  - CHEWING TOB
  - PIPE SMOK
  - SCC TONGUE
  - INNER LOC ET
  - (EXPAN) BEN JAW
  - UNLIKE ORO CAN CA
  - TYPIC RELATED TO HPV
  - MOST FREQ SCC
  - ORAL CAN
  - YOUNGER
  - INFANT
- ALC
- TOB +
- MYXOMA
  - MC
  - POTENTIAL
  - MYXOID BASD
  - SD
  - GORLIN
  - ODONTOGENIC CYSTS
  - MULTIPLE
  - AMEMAL
  - ODONTOMA
    - COMPOUND ODONTOMA
    - IMPACTED TEETH
    - ODONTOMA

NL

SCH

SALIV GLANDS

TUMORS

PAROTID (SEROUS)

SUBLING (MUCOUS)

SUBMAND (SER + MUCOUS)

MUCOEPIDERMOID CA

- MINOR
- LARGE GRANULAR
- VERY RARE
- EPIT MITOT + BRIGHTLY EOSINOPHILIC
- ONCOCYTOMAS
- STROMA
- LYMPHOID
- EPIT
- TUM MOST FREQ
- STROK
- FREQ BILAT
- BEN
- ELDER
- BEN
- RARE
- WARTHIN
- =PAPILLARY CYSTADENOMA LYMPHOMATOSUM
- PAROT
- MOTOR OIL FLUID
- RECUR AFTER RESEC°
- PROXIM
- * FACIAL N
- => DIFFICULT TO REMOVE
- FIRM
- TENDER
- SWELLING
- USUALLY
- 90%
- PAROTID
- MOSTOFTEN
- 2x EOSINOPHILIC EPIT
- MAST CELL INFIL
- INTERM
- LOW 5Y SURV 90%
- HIGH 5Y 20-40%
- SQUAMOID
- ADENOID CYSTIC CA
- DARK
- LATE METS
- CLINICAL CA ≃ N ANIMAL
- UNCOMMON
- YOUNG
- OTH

PLEOMORPHIC ADENOMA

- MIXED
- MOST FREQ
- 20-60Y/O
- HISTO VARY
- EPIT
- MYXOID
- CART-LIKE
- MIX
- +MESENCHYME LIKE ELEMENTS
- MAJ PAROTID
- BEN*
- 1/2 TUM SUBMAX MAL*
- BEN
- FREQ RECUR
- RARE MAL
- CHAR
- FLOOR MOUTH
- MOST COMMON SALGL TUM
- CAN OCCUR IN SUBM V MINOR
- CAPS-LIKE
- MYXOINFLAM
- MAY DISPLAY
- FIBROUS
- MYXOID STROMA
- EMBEDDED
- TUBULES FORMING DUCTS
- SOME OFTEN
- INNER MASSES
- VARIABLE STROMA
- VARIFORM

SIALADENITIS

- STONES
- DUCTS = SIALOLITHIASIS
- OCCLUSION
- IMMED
- IFC
- MUMPS
- OTH IFC

SJÖGREN SD

- MOST LIKELY AUTOIMM ORIGIN
- KERATOCONJUNCTIVIS SICCA
- XERO STOMIA
- GN TISD
- OFTEN
- RA
- ↔ INCIDENCE MAL LYMPHOMA

MUCOCELE

- LINED BY GRANULA° TISSUE
- MUST-LIKE
- POOL MUCUS
- DUCT NEAR MINOR SALGL
- MUC LEAKAGE
- RUPTURE
- OBSTRUC
- TRAUM
- DUCT

RANULA

= LARGE SAL GLAND ORIGIN

PAIN

PERIN INVAS° => PAIN

NL

SCH

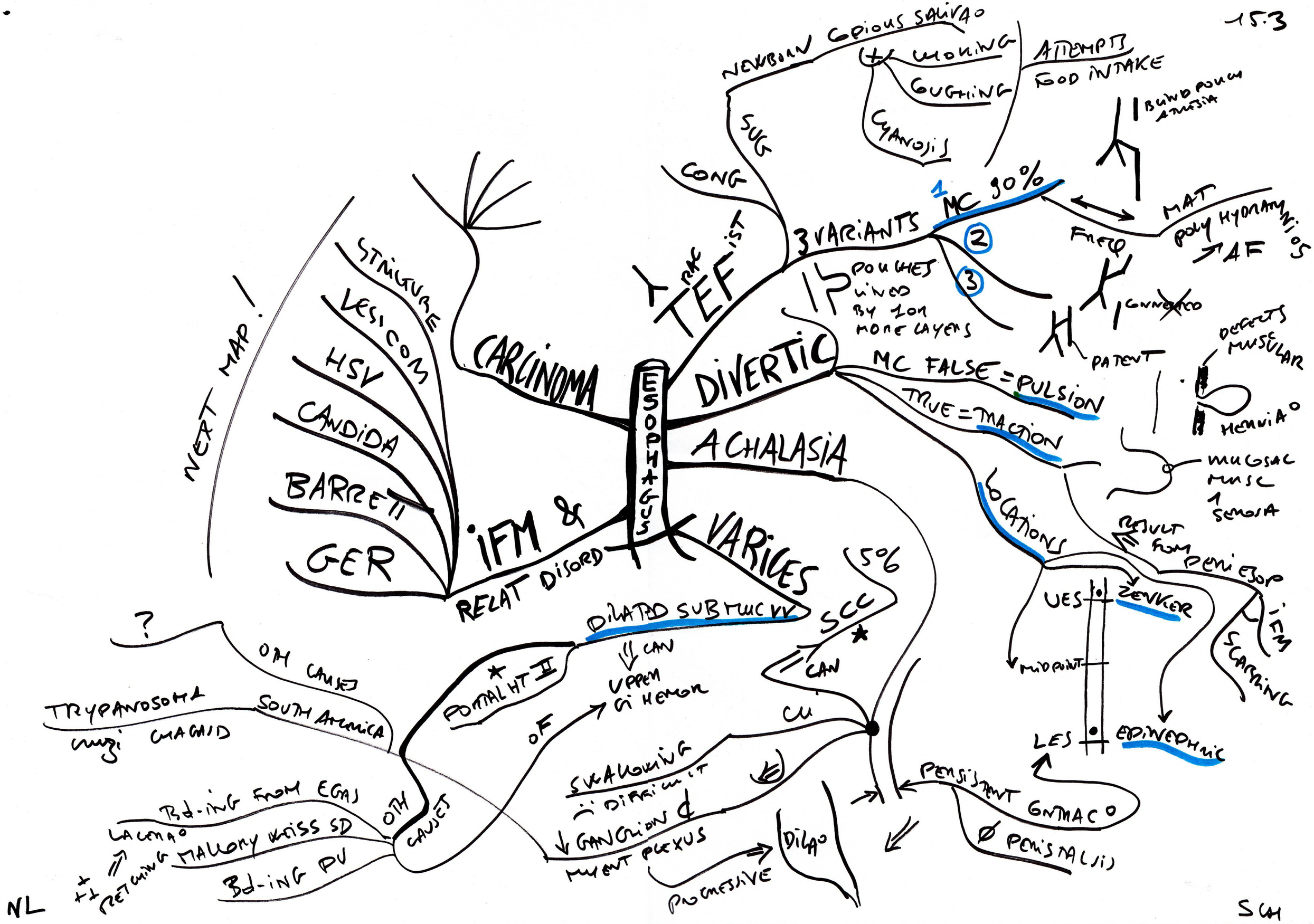
ESOPHAGUS
CARCINOMA
STRICTURE
VESICOM
HSV
CANDIDA
BARRETT
GER
NEXT MAP!
IFM &
RELAT DISORD
TEF
RAC
IST
CONG
SUG
NEWBORN
COPIOUS SALIVAO
MOKING
COUGHING
CYANOSIS
ATTEMPTS
FOOD INTAKE
BLIND POUCH
ATRESIA
3 VARIANTS
1 MC 90%
2
3
FREQ
MAT
POLY HYDRAMNIOS
AF
POUCHES
LINED
BY 1 OR
MORE LAYERS
CONNECTED
PATENT
DIVERTIC
MC FALSE = PULSION
TRUE = TRACTION
DEFECTS
MUSCULAR
HERNIAO
MUCOSAL
MUSC
1
SEROSA
ACHALASIA
VARICES
5%
SCC
CAN
LOCATIONS
RESULT
FROM
PERIESOP
IFM
SCARRING
UES
ZENKER
MIDPOINT
LES
EPINEPHRIC
DILATED SUBMUCVV
CAN
UPPER
GI HEMOR
PORTAL HT II
OF
CLI
SWALLOWING
DIFFICULT
GANGLION ¢
MYENT PLEXUS
PROGRESSIVE
DILAO
PERSISTENT CONTRACO
Ø PERISTALSIS
?
OTH CAUSES
TRYPANOSOMA
CRUZI CHAGAID
SOUTH AMERICA
OTH
CAUSES
Bd-ING FROM EGAS
LACERAO
MALLORY WEISS SD
Bd-ING PU
+ ++ RETCHING
NL
SCH

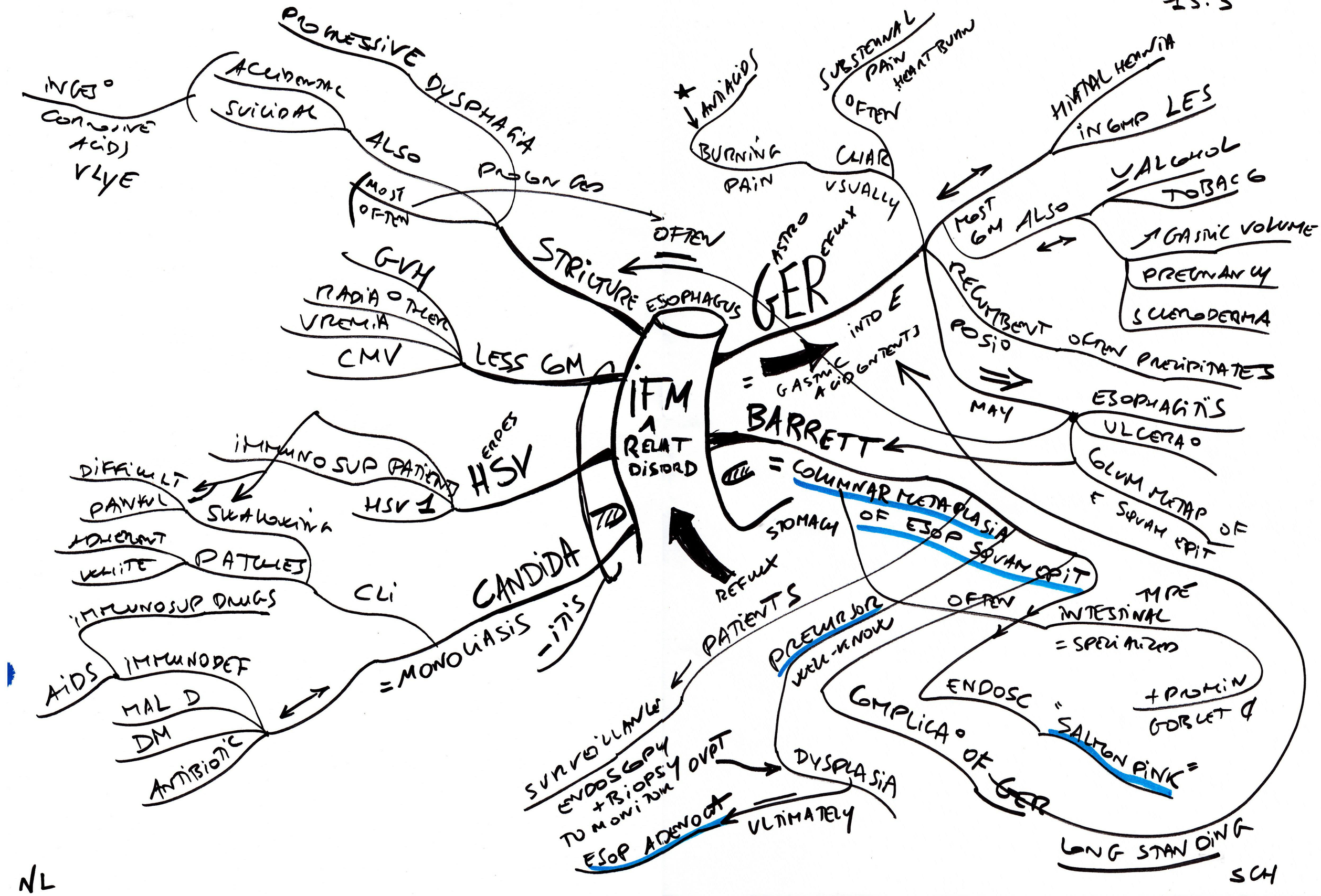

INGES°
CORROSIVE ACIDS
VLYE
ACCIDENTAL
SUICIDAL
ALSO
PROGRESSIVE DYSPHAGIA
PROLONGED
MOST OFTEN
OFTEN
STRICTURE
ESOPHAGUS
GVH
RADIA° THER
VREMIA
CMV
LESS COM
IFM
RELAT DISORD
ERPES
HSV
IMMUNOSUP PATIENTS
HSV 1
DIFFICULT
PAINFUL
SWALLOWING
ADHERENT
WHITE
PATCHES
CLI
CANDIDA
= MONOLIASIS
-ITIS
IMMUNOSUP DRUGS
AIDS
IMMUNODEF
MAL D
DM
ANTIBIOTIC
ANTIACIDS
BURNING PAIN
SUBSTERNAL PAIN
HEARTBURN
OFTEN
CHAR
USUALLY
ASTRO
EFFUX
GER
= GASTRIC ACID CONTENTS
INTO E
BARRETT
= COLUMNAR METAPLASIA OF ESOP SQUAM EPIT
STOMACH
REFLUX
PATIENTS
SURVEILLANCE
ENDOSCOPY + BIOPSY OVPT TO MONITOR
ESOP ADENOCA
ULTIMATELY
DYSPLASIA
PRECURSOR
WELL-KNOWN
HIATAL HERNIA
INCOMP LES
MOST COM ALSO
VALCOHOL
TOBACCO
GASTRIC VOLUME
PREGNANCY
SCLERODERMA
RECUMBENT POSIO
OFTEN PRECIPITATES
MAY
ESOPHAGITIS
ULCERA°
COLUM METAP OF E SQUAM EPIT
OFTEN
TYPE
INTESTINAL
= SPECIALIZED
ENDOSC
"SALMON PINK"
+ PROMIN GOBLET ¢
COMPLICA° OF GER
LONG STANDING

NL

SCH

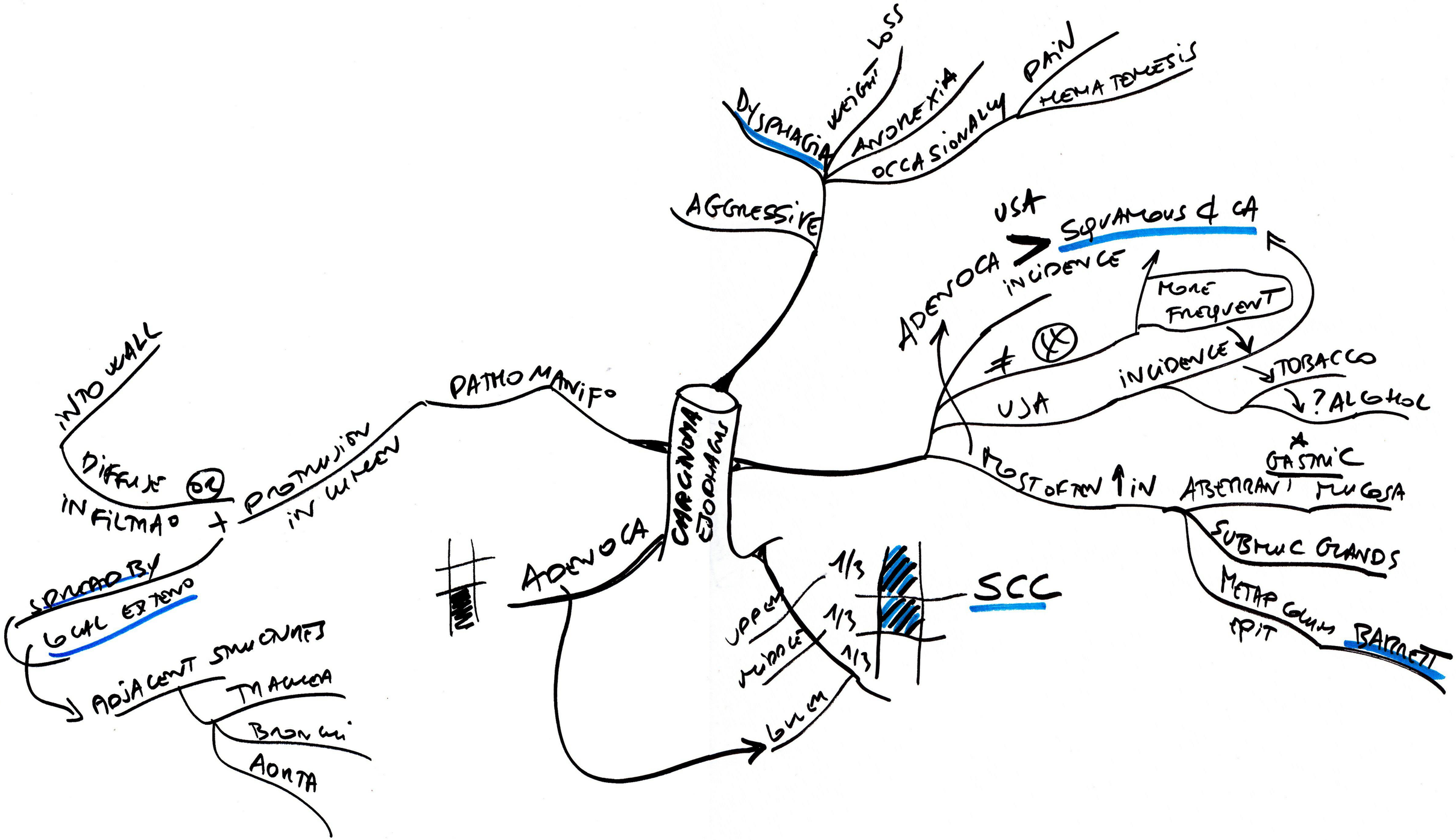
DYSPHAGIA
WEIGHT LOSS
ANOREXIA
OCCASIONALLY PAIN
HEMATEMESIS
AGGRESSIVE
CARCINOMA ESOPHAGUS
PATHOMANIFO
INTO WALL
DIFFUSE OR INFILTRAO + PROTRUSION IN LUMEN
SPREAD BY LOCAL EXTENO
ADJACENT STRUCTURES
TRACHEA
BRONCHI
AORTA
ADENOCA
USA
ADENOCA > SQUAMOUS & CA
INCIDENCE
MORE FREQUENT
≠ ⊗
USA
INCIDENCE
TOBACCO
? ALCOHOL
MOST OFTEN ↑ IN ABERRANT MUCOSA
GASTRIC
SUBMUC GLANDS
METAP COLUM EPIT
BARRETT
SCC
UPPER
MIDDLE
LOWER
1/3
1/3
1/3

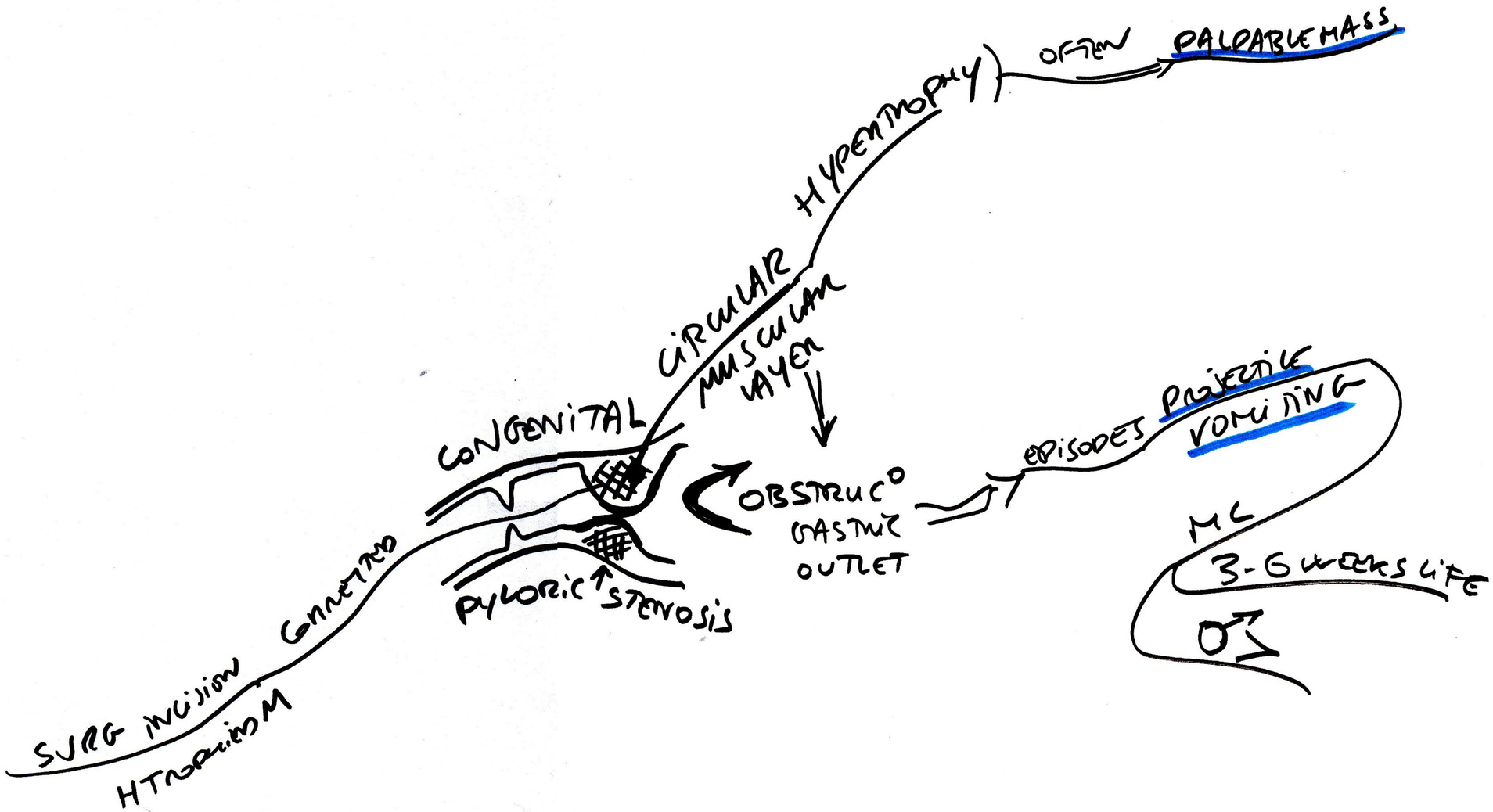
SURG INCISION CORRECTED
HTROPHIED M
CONGENITAL
CIRCULAR
MUSCULAR
LAYER
HYPERTROPHY
OFTEN
PALPABLE MASS
PYLORIC STENOSIS
OBSTRUC°
GASTRIC
OUTLET
EPISODES
PROJECTILE
VOMITING
MC
3-6 WEEKS LIFE
♂

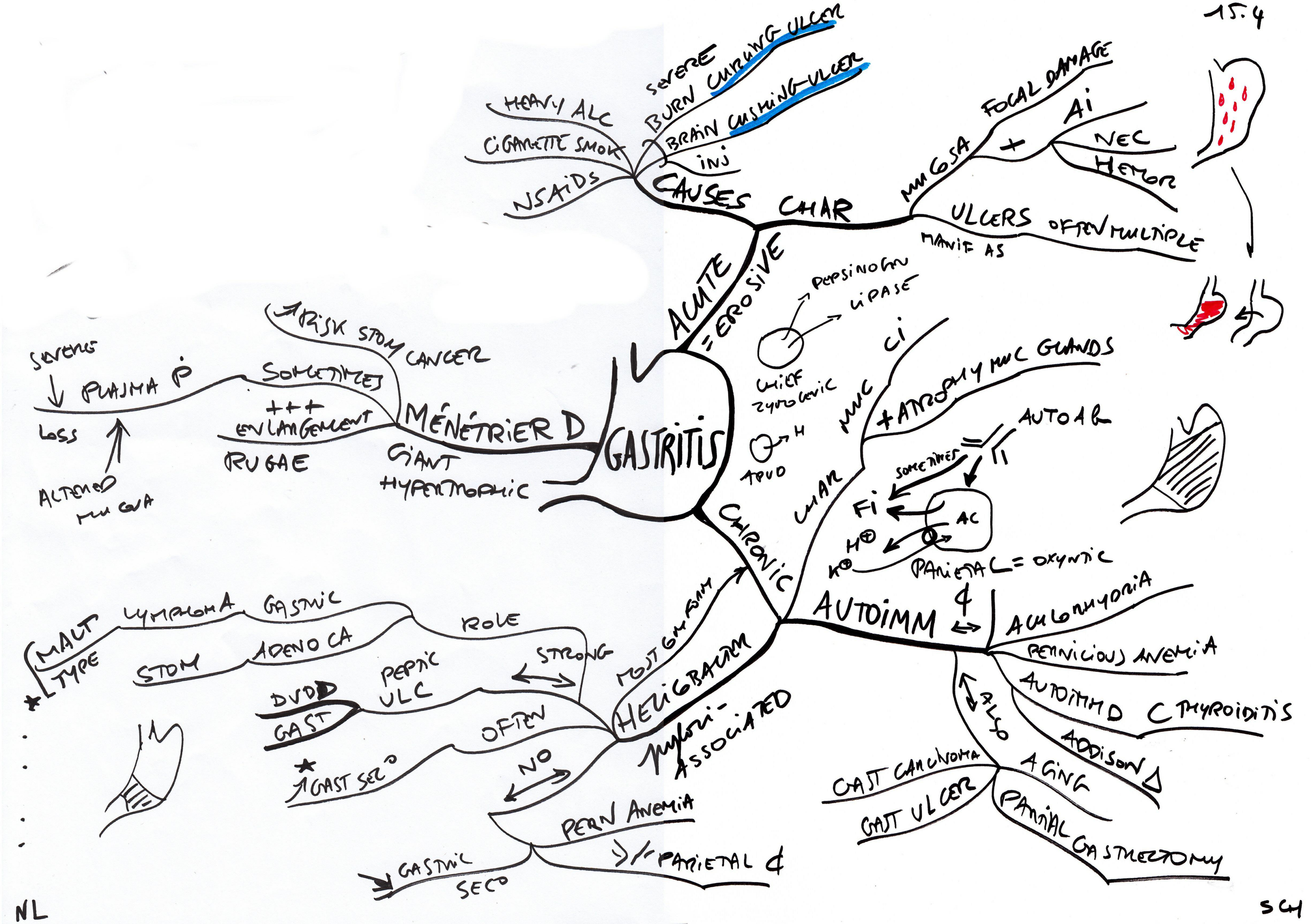
GASTRITIS
ACUTE = EROSIVE
CAUSES
HEAVY ALC
CIGARETTE SMOK
NSAIDS
SEVERE
BURN CURLING ULCER
BRAIN CUSHING ULCER
INJ
CHAR
MUCOSA
FOCAL DAMAGE
+
Ai
NEC
HEMOR
ULCERS
OFTEN MULTIPLE
MANIF AS
PEPSINOGEN
LIPASE
CHIEF ZYMOGENIC
H
APUD
CHRONIC
MUC
CI
+ ATROPHY MUC GLANDS
CHAR
AUTOAB
SOMETIMES
Fi
AC
H⊕
K⊕
PARIETAL = OXYNTIC
AUTOIMM
ACHLORHYDRIA
PERNICIOUS ANEMIA
AUTOIMM D
C THYROIDITIS
ADDISON Δ
ALSO
AGING
GAST CARCINOMA
GAST ULCER
PARTIAL GASTRECTOMY
HELICOBACTER
pylori-ASSOCIATED
MOST COMFORM
STRONG
ROLE
PEPTIC ULC
DVDD
GAST
OFTEN
NO
GAST SEC°
PERN ANEMIA
PARIETAL ¢
GASTRIC SEC°
MÉNÉTRIER D
GIANT
HYPERTROPHIC
RUGAE
+++
ENLARGEMENT
SOMETIMES
RISK STOM CANCER
PLASMA Ṗ
SEVERE
LOSS
ALTERED MUCOSA
MALT
TYPE
LYMPHOMA
GASTRIC
STOM
ADENOCA

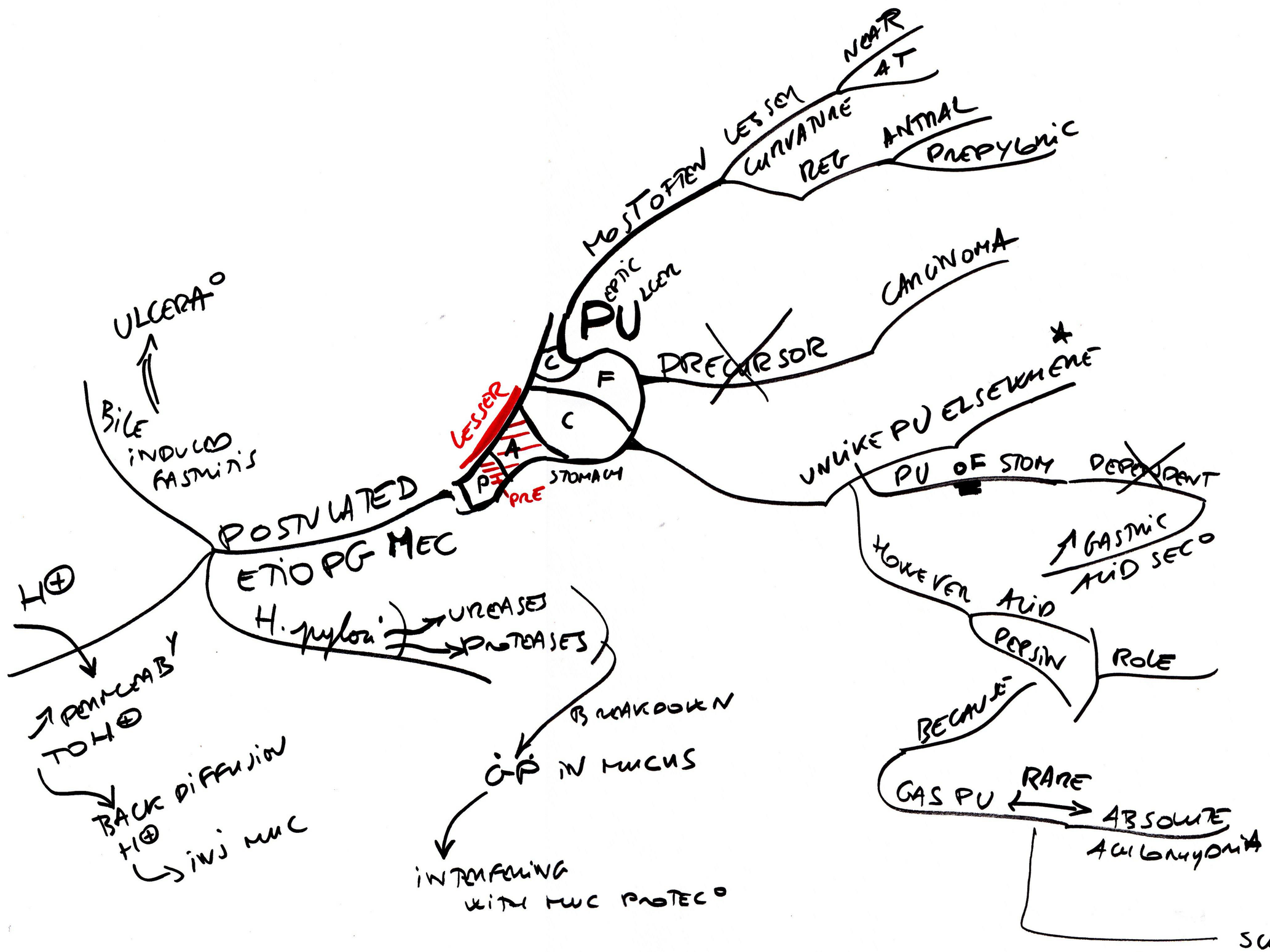
MOST OFTEN LESSER
NEAR
AT
CURVATURE
REG
ANTRAL
PREPYLORIC
PU
EPTIC
ULCER
CARCINOMA
PRECURSOR
C
F
C
A
P
PRE
STOMACH
LESSER
UNLIKE PU ELSEWHERE
PU OF STOM
DEPENDENT
GASTRIC
ACID SEC°
HOWEVER
ACID
PEPSIN
ROLE
BECAUSE
GAS PU
RARE
ABSOLUTE
ACHLORHYDRIA
SCH
POSTULATED
ETIOPG MEC
ULCERA°
BILE
INDUCED
GASTRITIS
H⊕
PERMEABY
TO H⊕
BACK DIFFUSION
H⊕
INJ MUC
H. pylori
UREASES
PROTEASES
BREAKDOWN
G-P IN MUCUS
INTERFERING
WITH MUC PROTEC°

NL

CARCINOMA

GEN

- ? GENET PREDISP
- ↑FREQ BLOOD GROUP A
- INC ↑
- MC >50%
- ↑↑ INCID
  - JAPAN ++
  - FINLAND
  - ICELAND
  - ↓ USA

ETIO F

- ① H. pylori
  - HIGH SUSPECT
- ② NITROSAMINES
  - NITR DIET AMINES
  - FOOD PRESERVATIVES
  - ↑ SMOKED FISH
  - PICKLED VEG
- ↑ SALT
- ③ ↓ FRESH FRUITS & VEG

CHAR

- ★ ACHLORHYDRIA
- ④ CHRONIC GASTRITIS
  - WITH OR WITHOUT
  - PERN ★ ANEMIA
- ⑤ MINOR GENETIC DEFECTS
  - MANY FAM
  - E-CADHERIN GEN
  - CDH1
  - MUTO
  - USUALLY
    - DIFFUSE INFILTO
    - SIGNET RING ↑
    - +PREDISP
    - LOBULAR CA BREAST
  - ADENOCA
    - ALMOST ALWAYS
    - ACHLORHYDRIA
    - PERN ANEMIA
    - ON PREPYL ANTRUM
      - LESION
      - DISTAL
      - FUNGOUS TUM
    - EARLY LYMPHMETS
      - REGIONAL LN
      - ↑ LIVER
      - PERIT
      - ADJ ORG
    - AGGRESSIVE SPREAD

MORPHO VARIANTS

- ⑥ SIGNET-RING
  - ONE SIDE
  - MUCIN ++
  - BILAT OVARIES
  - = KRUKENBERG TUM
  - MORE DISTAL MAY BE
  - SUPRACLAV LN
  - = VIRCHOW NODE
- HNPCC = LYNCH SD ALSO ↑ RISK
  - IN COMPONENT
- MALIGNANT TUMORS STOM

LYMPHOMA

- NEXT MAP!

GISTs

- STROMAL

INFILTRATING = DIFFUSE

- DIFFUSE INFILTRATION OF TUM + EXTENSIVE FIBROSIS
- WALL THICKENED RIGID
- = LINITIS PLASTICA = LEATHER-BOTTLE STOM
- ULCERATED CAN
- OFTEN
- INTESTINAL TYPE
  - PROJECTING INTO LUMEN
  - HIGH
  - H. pyl
  - POLYPOID = FUNGATING
  - SOLID MASS

ECARCINOMA

- PUNCHED OUT MARGINS
- BASE INDEF NEMOSIC
- RAISED
- FIRM RAISED MARGINS
- DIFF BY BIOPSY ESSENTIAL

H. pylori

- ↑ RISK
- ↑ RISK

NL

SCM

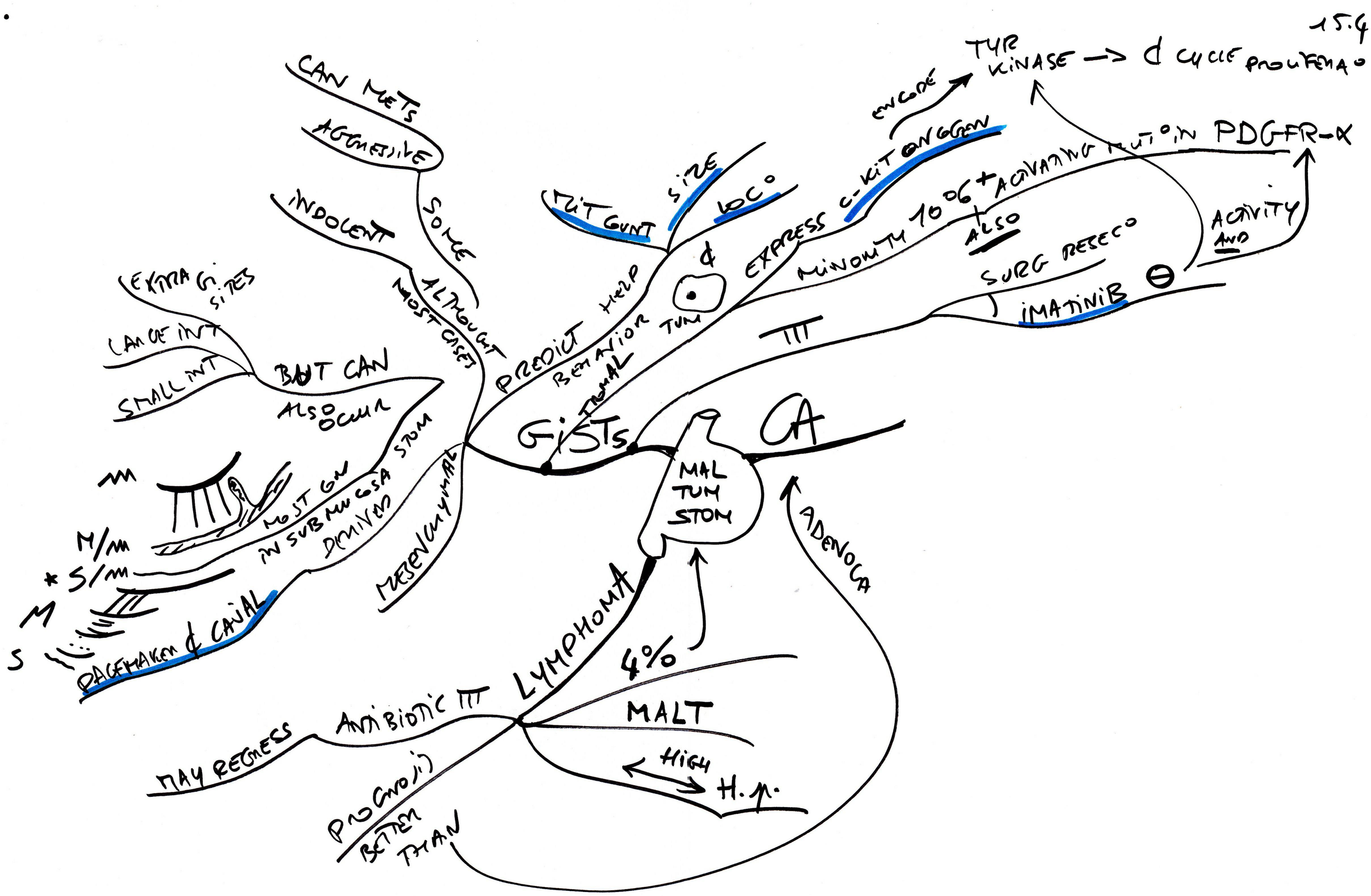
CAN METS
AGGRESSIVE
SOME
INDOLENT
ALTHOUGHT
MOST CASES
EXTRA GI SITES
LARGE INT
SMALL INT
BUT CAN
ALSO OCCUR
MOST ON
IN SUBMUCOSA STOM
DERIVED
MESENCHYMAL
M/m
* S/m
M
S
PACEMAKER ¢ CAJAL
PREDICT HELP
BEHAVIOR
TROMAL
MIT GUNT
SIZE
LOC°
¢
TUM
GISTS
EXPRESS C-KIT ONGGEN
ENCODE
TYR KINASE → ¢ CYCLE PROLIFERA°
MINORITY 10°6 + ACTIVATING MUT° IN PDGFR-α
ALSO
SURG RESEC°
IMATINIB ⊖
ACTIVITY AND
III
CA
MAL TUM STOM
ADENOCA
LYMPHOMA
4%
MALT
HIGH
H.p.
ANTIBIOTIC III
MAY REGRESS
PROGNOSIS
BETTER THAN

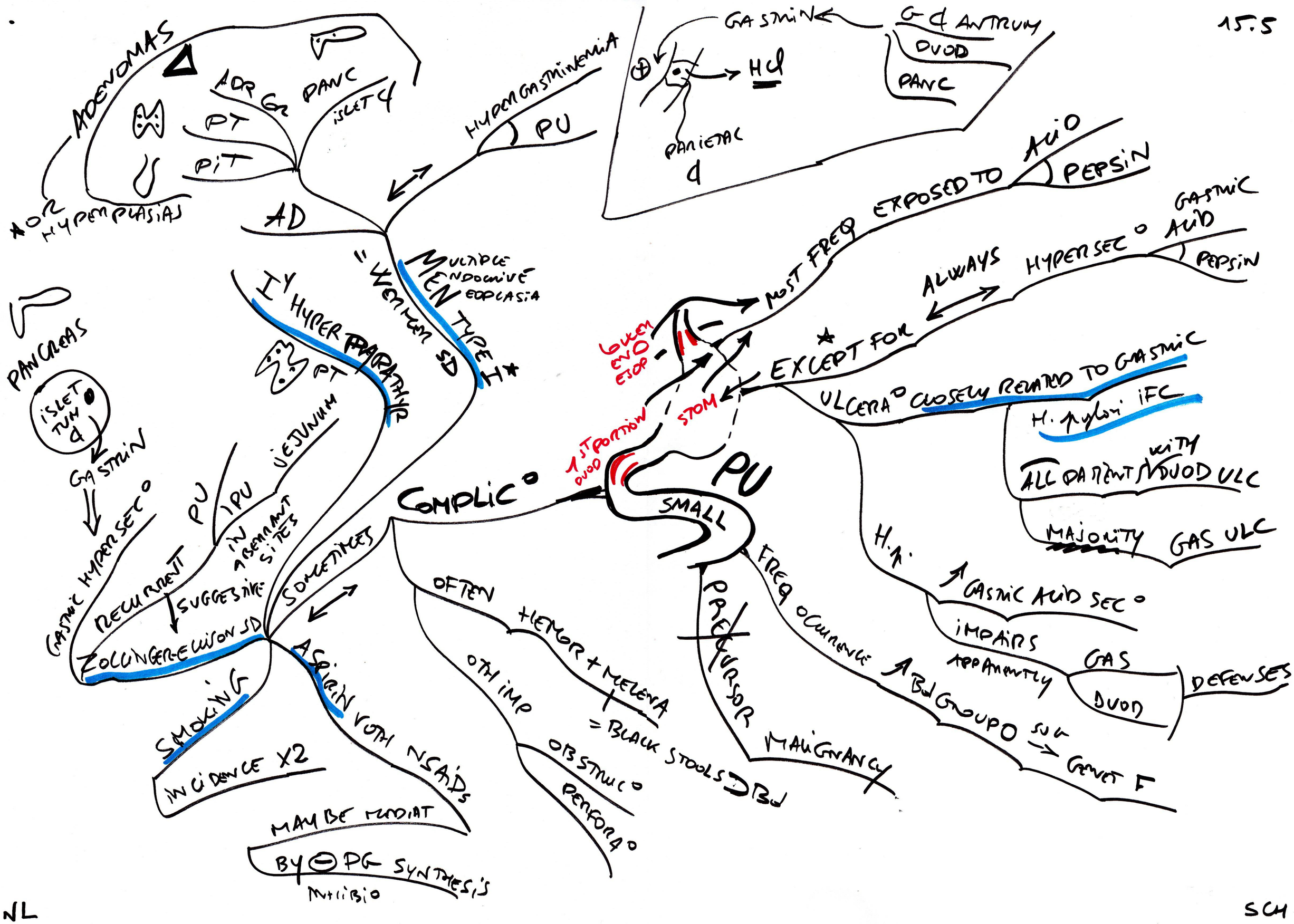
ADENOMAS
ADR GR
PANC
PT
PIT
ISLET ¢
AOR HYPERPLASIAS
HYPERGASTRINEMIA
PU
AD
GASTRIN
G ¢ ANTRUM
DUOD
PANC
HCl
PARIETAL ¢
MULTIPLE ENDOCRINE EOPLASIA
MEN TYPE I*
"WERMER SD
I^Y HYPERPARATHYR
PT
PANCREAS
ISLET TUM ¢
GASTRIN
GASTRIC HYPERSEC°
PU
IPU
JEJUNUM
IN ABERRANT SITES
RECURRENT
SUGGESTIVE
ZOLLINGER-ELLISON SD
SOMETIMES
SMOKING
INCIDENCE X2
ASPIRIN VOTH NSAIDs
MAYBE MEDIAT
BY ⊖ PG SYNTHESIS
INHIBIO
COMPLIC°
OFTEN
HEMOR + MELENA
= BLACK STOOLS ⊃ Bd
OTH IMP
OBSTRUC°
PERFORA°
1ST PORTION DUOD
LOWER END ESOP
STOM
PU
SMALL
PRECURSOR
MALIGNANCY
FREQ OCCURRENCE
Bd GROUP O
SUG
GENET F
MOST FREQ EXPOSED TO ACID
PEPSIN
ALWAYS
HYPERSEC° GASTRIC ACID
PEPSIN
EXCEPT FOR
ULCERA° CLOSELY RELATED TO GASTRIC
H. pylori IFC
ALL PATIENTS WITH DUOD ULC
MAJORITY GAS ULC
H.p.
GASTRIC ACID SEC°
IMPAIRS
APPARENTLY
GAS
DUOD
DEFENSES

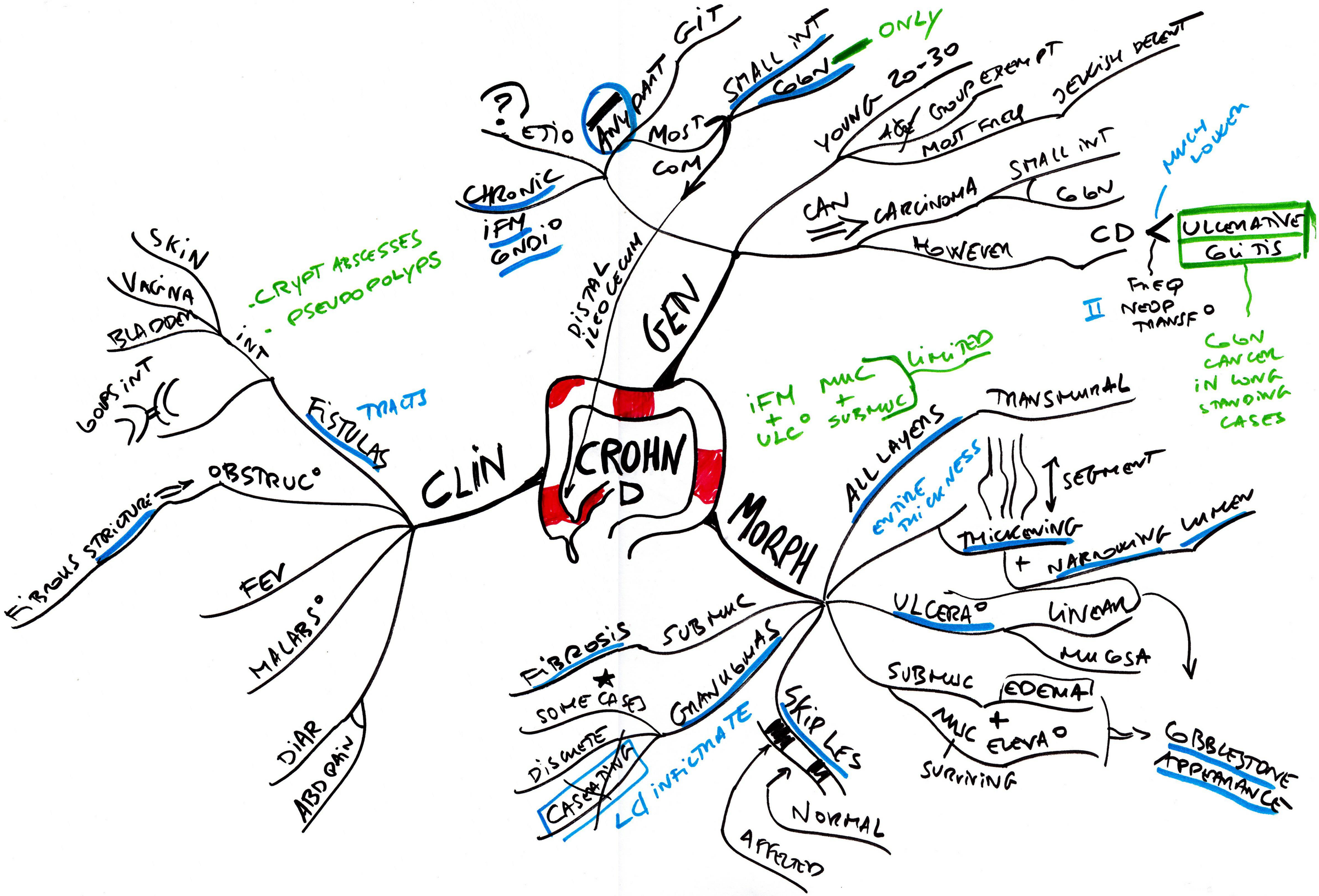
CROHN D
GEN
CLIN
MORPH
ETIO
ANY PART GIT
MOST COM
SMALL INT
COLON
ONLY
YOUNG 20-30
AGE GROUP EXEMPT
MOST FREQ
JEWISH DECENT
CHRONIC
IFM
CONDIO
CAN
CARCINOMA
SMALL INT
COLON
HOWEVER
CD
ULCERATIVE COLITIS
MUCH LOWER
FREQ
II NEOP TRANSF°
COLON CANCER IN LONG STANDING CASES
DISTAL ILEOCECUM
SKIN
VAGINA
BLADDER
INT
GOOPS INT
CRYPT ABSCESSES
PSEUDOPOLYPS
FISTULAS
TRACTS
OBSTRUC°
FIBROUS STRICTURE
FEV
MALABS°
DIAR
ABD PAIN
IFM + ULC°
MUC + SUBMUC
LIMITED
ALL LAYERS
TRANSMURAL
ENTIRE THICKNESS
SEGMENT
THICKENING
+ NARROWING LUMEN
ULCERA°
LINEAR
MUCOSA
SUBMUC
EDEMA
MUC + ELEVA°
SURVIVING
COBBLESTONE APPEARANCE
SKIP LES
NORMAL
AFFECTED
FIBROSIS
SUBMUC
SOME CASES
GRANULOMAS
DISCRETE
CASEATING
LCI INFILTRATE

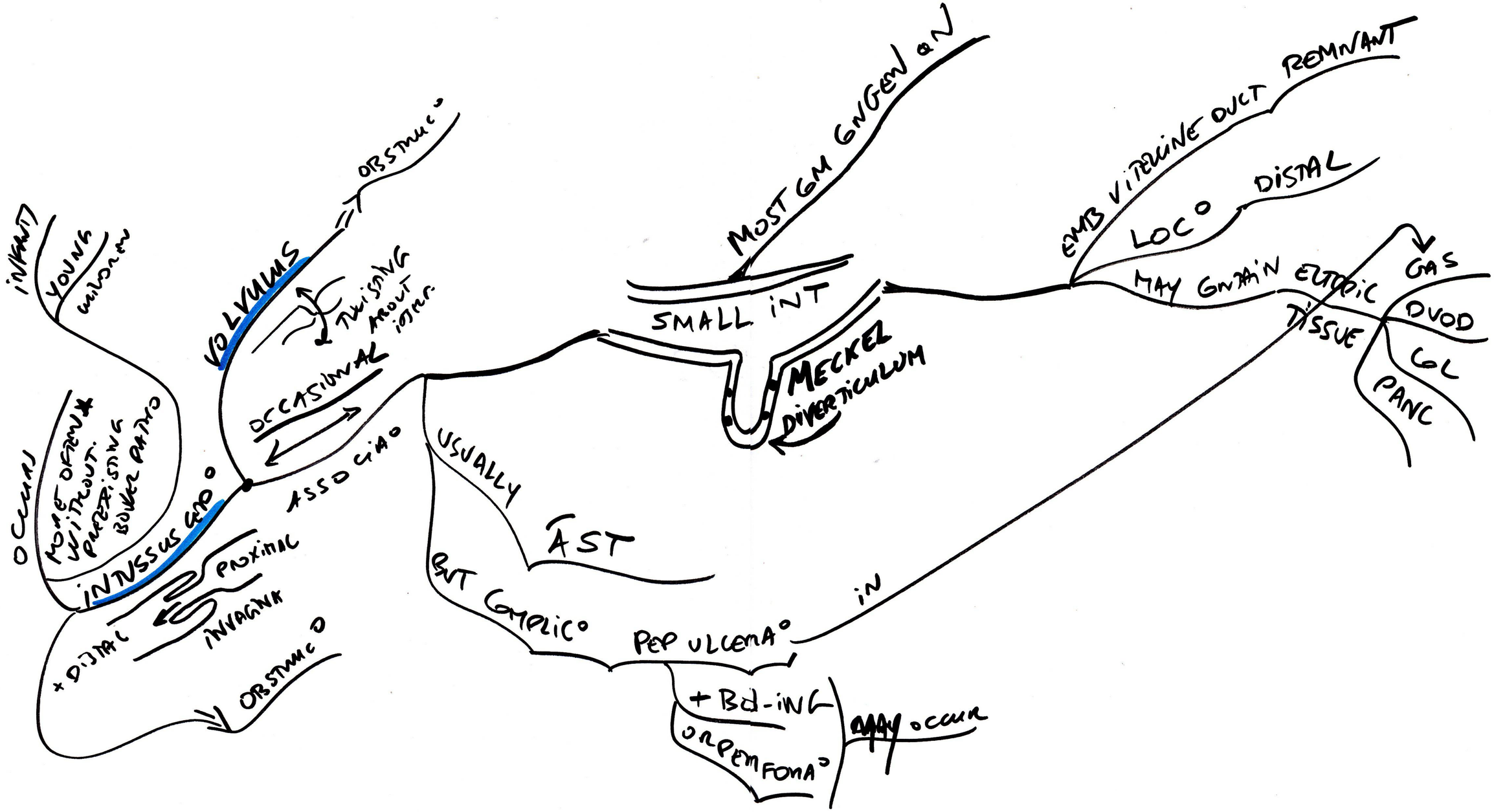
INFANT
YOUNG CHILDREN
OCCUR
MORE OFTEN WITHOUT PRECEDING BOWEL PATHO
INTUSSUSCEPT°
VOLVULUS
OBSTRUC°
TWISTING ABOUT ITSELF
OCCASIONAL
ASSOCIA°
PROXIMAL
INVAGNK
+DISTAL
OBSTRUC°
MOST COMMON
SMALL INT
MECKEL DIVERTICULUM
USUALLY
AST
ENT COMPLIC°
PEP ULCERA°
IN
+Bd-ING
ORPEMFONA°
EMB VITELLINE DUCT REMNANT
LOCO
DISTAL
MAY CONTAIN ECTOPIC
GAS
DUOD
TISSUE
GL
PANC

NL

SCH

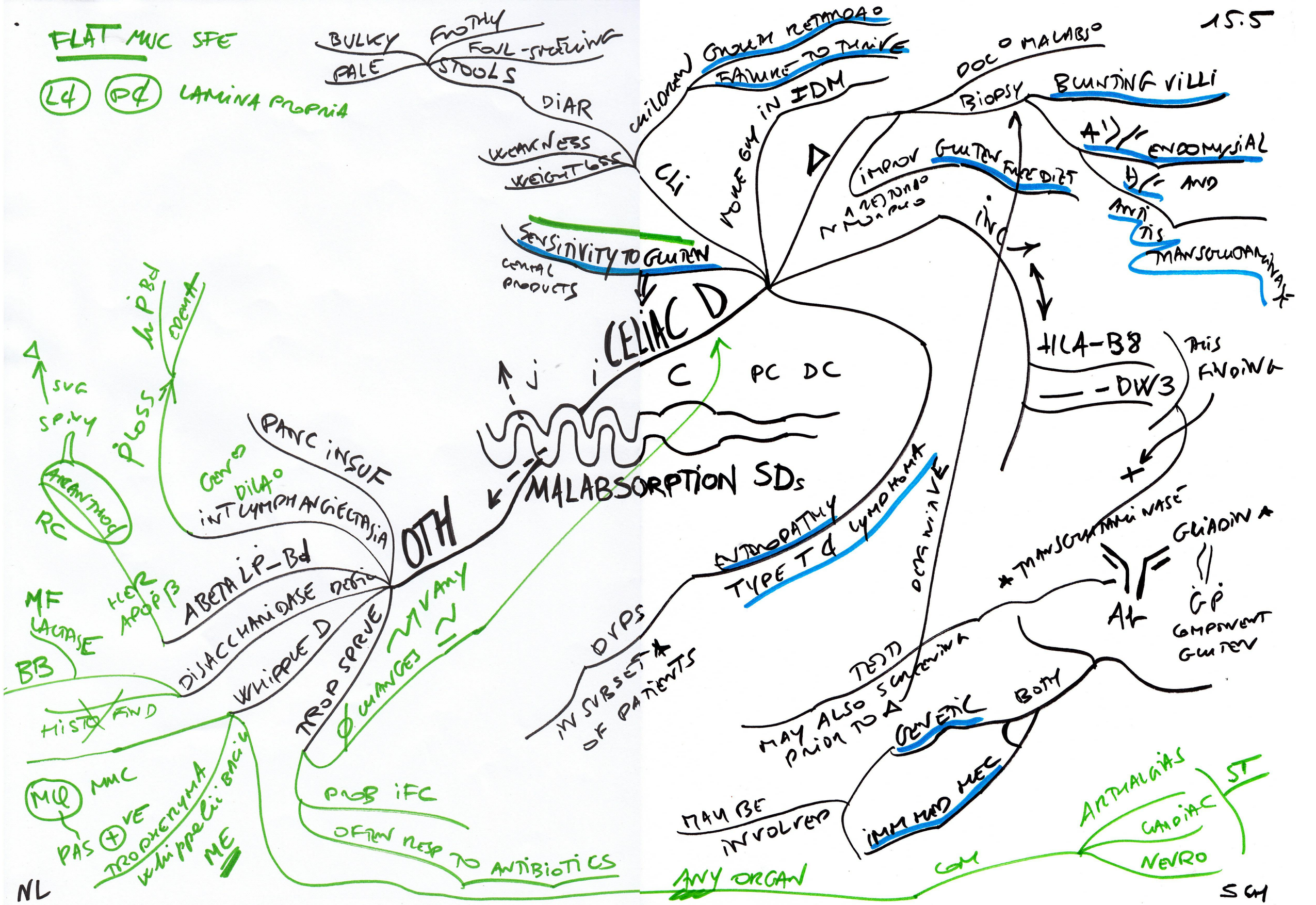
15.5
FLAT MUC SFE
L¢ P¢ LAMINA PROPRIA
BULKY
PALE
FROTHY
FOUL-SMELLING
STOOLS
DIAR
WEAKNESS
WEIGHT LOSS
CHILDREN
GROWTH RETARDAO
FAILURE TO THRIVE
CLI
MORE GRY IN IDM
DOC MALABSO
BIOPSY
BLUNTING VILLI
A ENDOMYSIAL
AND
ANTI TIS TRANSGLUTAMINASE
IMPROV GLUTEN FREE DIET
A RESTORAO
N MORPHO
INC
SENSITIVITY TO GLUTEN
CEREAL PRODUCTS
CELIAC D
HLA-B8
DW3
THIS FINDING
C
PC DC
MALABSORPTION SDs
OTH
PANC INSUF
GENES
DILAO
INT LYMPHANGIECTASIA
ABETA LP-Bd
DISACCHARIDASE DEFIC
WHIPPLE D
TROP SPRUE
VARY
CHANGES
ENTEROPATHY
TYPE T¢ LYMPHOMA
DEFINITIVE
DVPS
IN SUBSET OF PATIENTS
TESTS
MAY ALSO SCREENING PRIOR TO
TRANSGLUTAMINASE
GLIADIN
Ab
GP COMPONENT GLUTEN
GENETIC
BOTH
IMM MED MEC
MAY BE INVOLVED
PROB IFC
OFTEN RESP TO ANTIBIOTICS
ANY ORGAN
COM
ARTHALGIAS
CARDIAC
NEURO
ST
SUG
SPINY
ARANTHOC
RC
MF
LACTASE
BB
HISTO FIND
MQ MUC
PAS +VE
TROPHERYMA
whippelii BACIL
ME
NL
SCH

MC = MOST COMMON

MC MALIGNANCY

METS

GEN

SMALL & GI NEOP

SOME FREQUENCIE

30%

SMALL INT

SLOW GROWING

LOW GRADE MAL

MAY MET

UNCOMMON

MOST FREQ APP

NEUROENDOC = CARCINOID

WHEN MET

LIVER

CAN LOAD

CARCINOID SD

TUMORS

GISTs

ORIGINATE SMALL INT → STOM

BEHAVE MALIGNANTLY

SMALL INT

ADENOCA

MC TUM SMALL INT

PANC

LYMPHOMA

MAY PRESENT ABUNDANT TISSUE

MALABS

WHEN DIFFUSE INVOLVEMENT

R

VALVULES

BRONCOSPASM

WATERY DIAR

CUT FUNCTION

CLI

CAUSED

↑ ABD CRAMPS

ELABORATE VASOACTIVE PEPTIDES

↑ AMINES

SEROT

NL

SCH

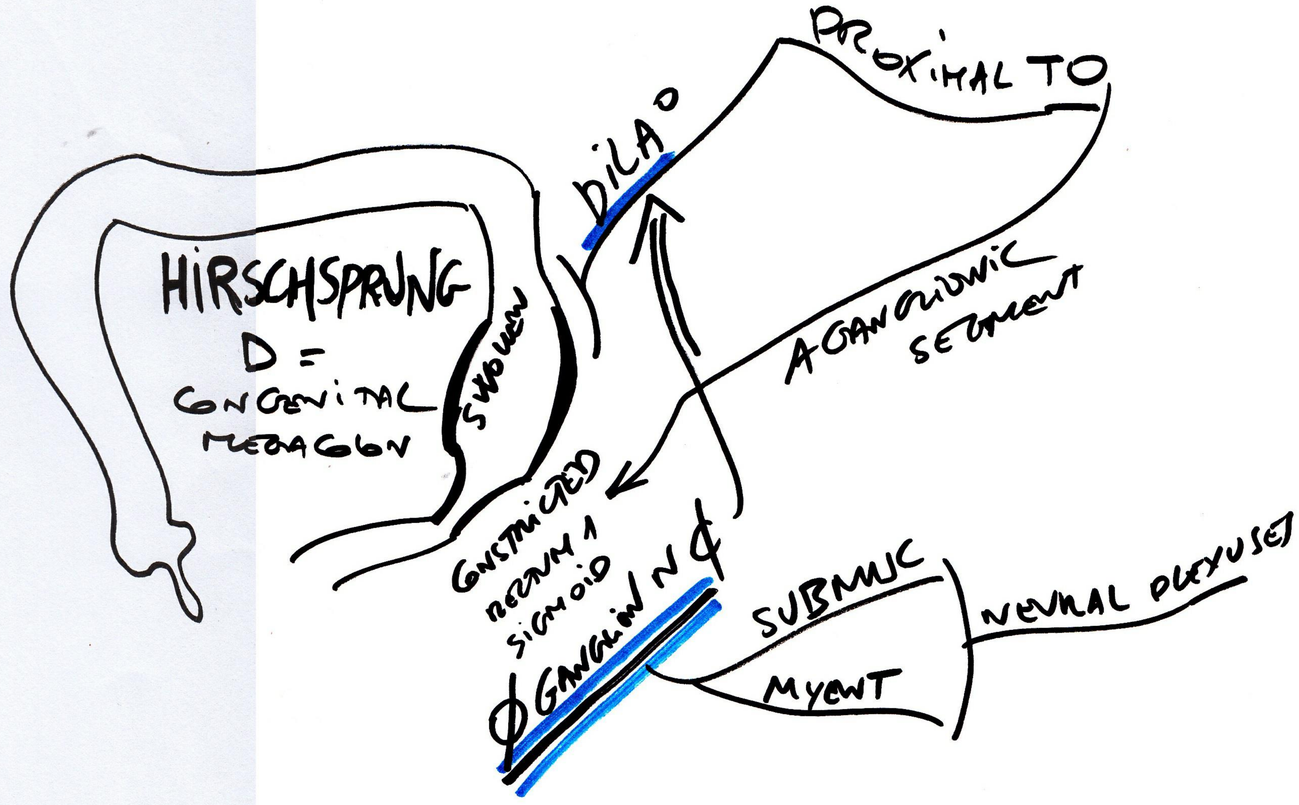
HIRSCHSPRUNG
D =
CONGENITAL
MEGACOLON
DILA°
PROXIMAL TO
AGANGLIONIC
SEGMENT
CONSTRICTED
RECTUM /
SIGMOID
GANGLION
SUBMUC
MYENT
NEURAL PLEXUSES

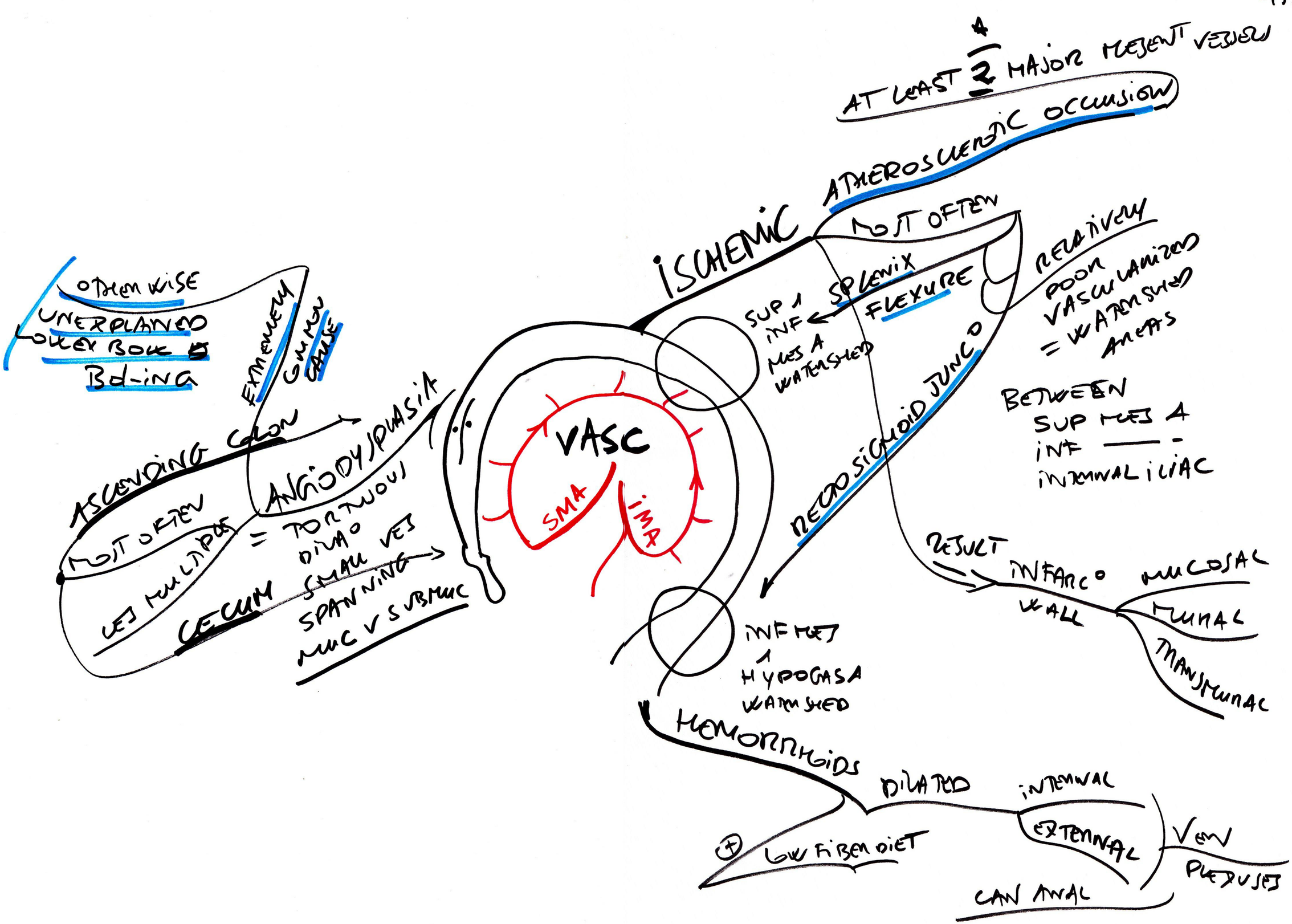
AT LEAST 2/4 MAJOR PRESENT VESSELS
ATHEROSCLEROTIC OCCLUSION
ISCHEMIC
MOST OFTEN
SUP & INF MES A WATERSHED
SPLENIX FLEXURE
RELATIVELY POOR VASCULARIZED = WATERSHED AREAS
SIGMOID JUNCT
NECROSIS
BETWEEN SUP MES A INF —— INTERNAL ILIAC
VASC
SMA
IMA
ISCHEMIC COLON
OTHERWISE UNEXPLAINED OLDER BOWEL Bd-ING
EXTREMELY COMMON CAUSE
ANGIODYSPLASIA
MOST OFTEN
VES MULTIPLE
= TORTUOUS DILATED SMALL VES SPANNING MUC V SUBMUC
CECUM
RESULT
INFARCT
WALL
MUCOSAL
MUSCL
TRANSMURAL
INF MES
↑
HYPOGASA
WATERSHED
HEMORRHOIDS
DILATED
INTERNAL
EXTERNAL
VEIN
PLEXUSES
CANAL
+
LOW FIBER DIET

NL

SCM

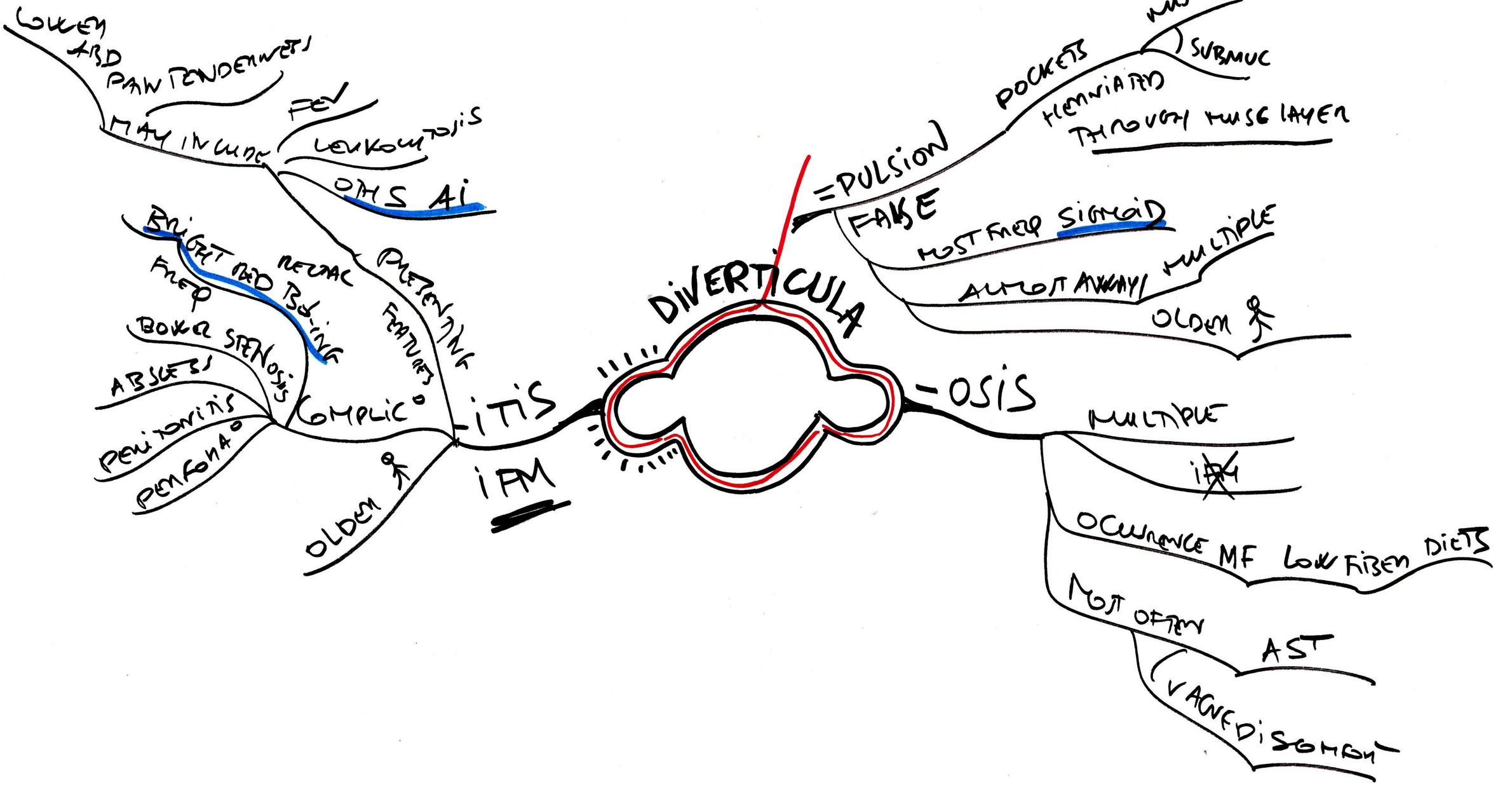
DIVERTICULA
=PULSION
FALSE
POCKETS
MUC
SUBMUC
HERNIATED
THROUGH MUSC LAYER
MOST FREQ SIGMOID
ALMOST ALWAYS
MULTIPLE
OLDER
=OSIS
MULTIPLE
iFM
OCCURANCE MF LOW FIBER DIETS
MOST OFTEN
AST
VAGUE DISCOMFORT
-ITIS
iFM
OLDER
COMPLIC°
PERITONITIS
PERFORA°
ABSCESS
BOWEL STENOSIS
FREQ
BRIGHT RED BLEEING
RECTAL
PRESENTING FEATURES
MAY INCLUDE
FEV
LEUKOCYTOSIS
OMS Ai
LOCAL AND PAN TENDERNESS

NL

SCH

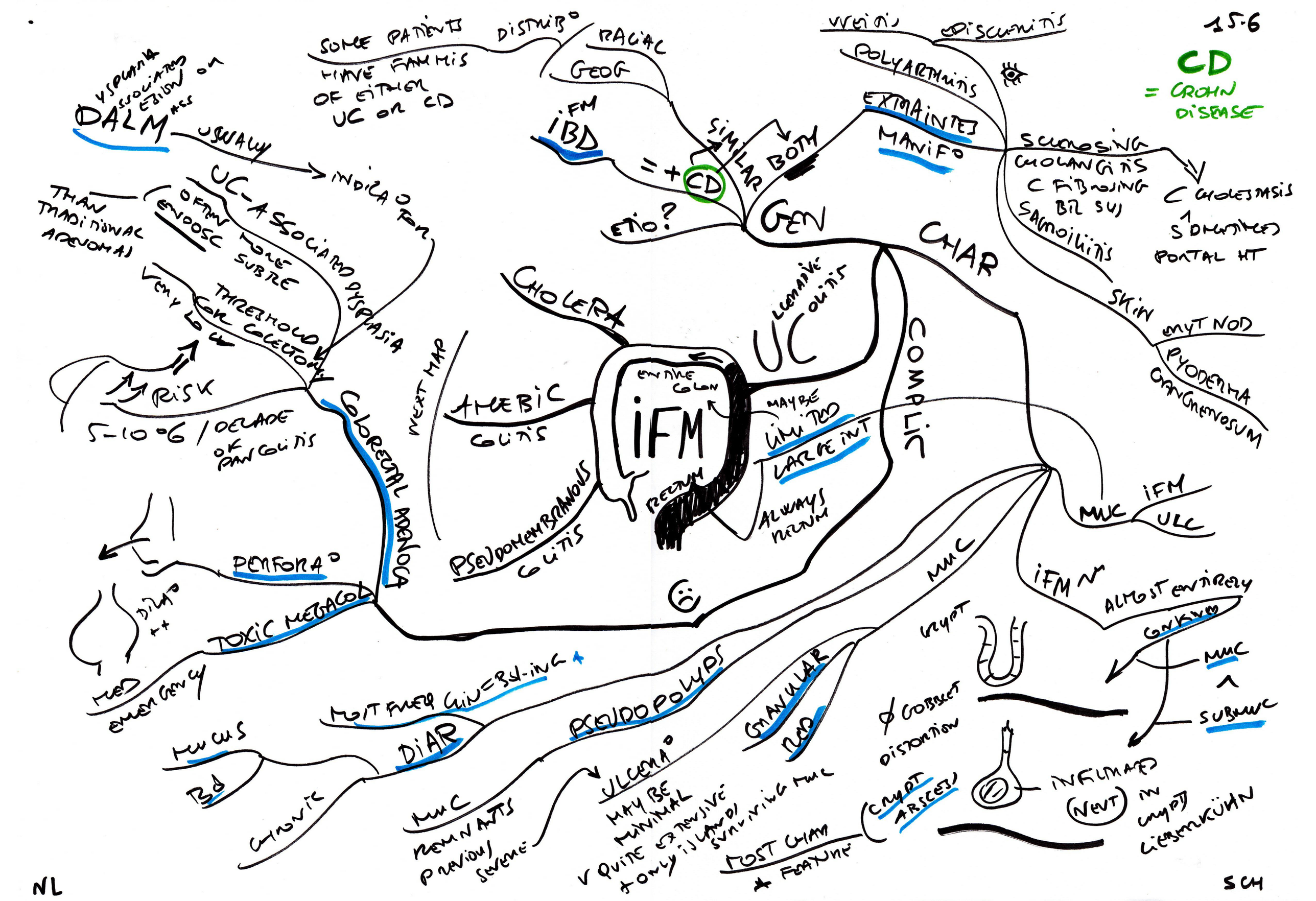
15.6
CD
= CROHN DISEASE
GEN
CHAR
COMPLIC
iFM
ENTIRE COLON
RECTUM
UC
ULCERATIVE COLITIS
MAYBE LIMITED
LARGE INT
ALWAYS RECTUM
CHOLERA
AMEBIC COLITIS
PSEUDOMEMBRANOUS COLITIS
NEXT MAP
COLORECTAL ADENOCA
DALM
DYSPLASIA ASSOCIATED LESION OR MASS
USUALLY
INDICA° FOR
UC-ASSOCIATED DYSPLASIA
OFTEN MORE ENDOSC SUBTLE
THAN TRADITIONAL ADENOMAS
THRESHOLD FOR COLECTOMY
VERY LOW
RISK
5-10 °6 / DECADE OF PANCOLITIS
PERFORA°
DILA° ++
TOXIC MEGACOL
MED EMERGENCY
SOME PATIENTS HAVE FAMMIS OF EITHER UC OR CD
DISTRIB°
RACIAL
GEOG
iFM
iBD
= + CD
SIMILAR
BOTH
ETIO?
EXTRAINTES
MANIFO
POLYARTHRITIS
WEITIS
EPISCLERITIS
SCLEROSING CHOLANGITIS
C FIBROSING BIL SYS
SACROILIITIS
C CHOLESTASIS
SOMETIMES PORTAL HT
SKIN
ERYT NOD
PYODERMA GANGRENOSUM
MUC
iFM
ULC
iFM ~
ALMOST ENTIRELY CONFINED
MUC
SUBMUC
CRYPT
Ø GOBBLET DISTORTION
INFILTRATED (NEUT) IN CRYPTS LIEBERKÜHN
(CRYPT ABSCESS)
MOST CHAR FEATURE
GRANULAR
RED
PSEUDOPOLYPS
MOST FREQ GIN=BSI-ING
DIAR
MUCUS
Bd
CHRONIC
MUC REMNANTS PREVIOUS SEVERE
ULCERA°
MAYBE MINIMAL
V QUITE EXTENSIVE + ONLY ISLANDS SURVIVING MUC
NL
SCH

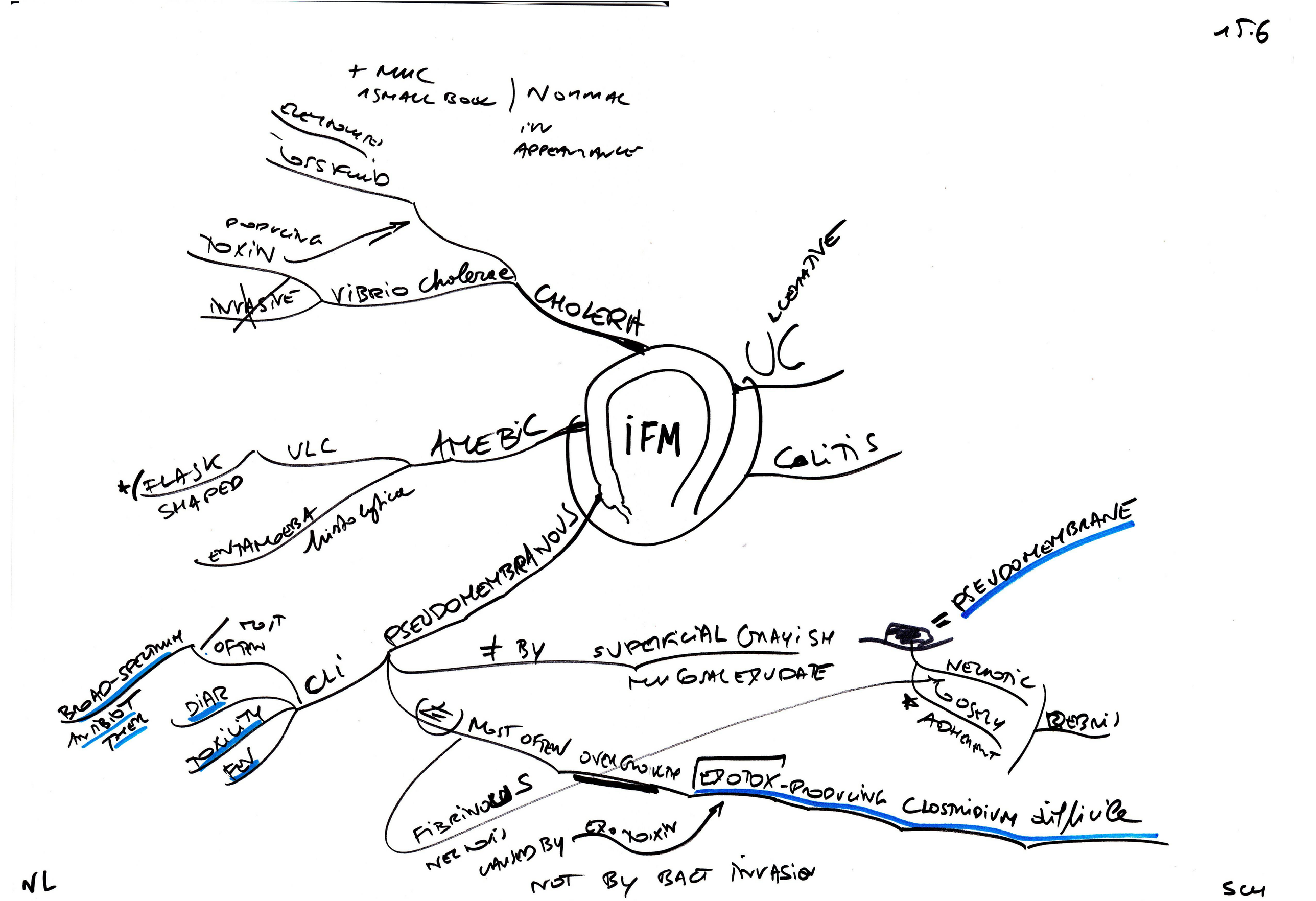
+ MUC
1 SMALL BOOK
NORMAL
IN
APPEARANCE
ELEMENTARY
LOSS FLUID
PRODUCING
TOXIN
INVASIVE
VIBRIO cholerae
CHOLERA
CHEMATIVE
UC
IFM
COLITIS
AMEBIC
ULC
*(FLASK
SHAPED
ENTAMOEBA
histolytica
PSEUDOMEMBRANOUS
CLI
MOST
OFTEN
BROAD-SPECTRUM
ANTIBIOT
THEM
DIAR
TOXICITY
FEV
≠ BY SUPERFICIAL GRAYISH
MUCOSAL EXUDATE
= PSEUDOMEMBRANE
NECROTIC
LOOSELY
ADHERENT
DEBRIS
(≡) MOST OFTEN OVERGROWTH
EXOTOX-PRODUCING CLOSTRIDIUM difficile
FIBRINOUS
NECROSIS
CAUSED BY
EXO TOXIN
NOT BY BACT INVASION

POLYPS BENIGN

HYPERPLASTIC

ADENOMATOUS

TUBULAR

TUBULOVILLOUS

VILLOUS

SESSILE SERRATED

HAMARTOMATOUS

INFLAMMATORY

TUMORS

ADENOCA COL + RECTUM

CHAR

GEN

PREDISP F

MULTIPLE POLYPOSIS

TURGT SD

PEUTZ-JEGHERS

JUVENILE

PSEUDOPOL

UC

TERMINO

NEOP

SD

FAP

GARDNER SD

HNPCC

MC NEOP

CEA

SPECIFIC

FOLLOW GUNJE

ADENOMA → CA → MET

// SETTING CHANGES

N → ADENOM POL → CA → MET

APC

NOT

SUBSET

SPONADIC ↓ METHYLAT

MISMATCH REPAIR GENES MUTD

MLH1 MSH2 MSH6 PMS2

MSAT INSTAB

NARROW STEM

BROAD BASED ATTACHMENT

SESSILE

PEDUNCULATED

SYNCHRONOUS

METACHRONOUS

↑ RISK MAL TRANSFO

↑ RISK MAL

MICROSATELLITE INSTABILITY

RIGHT COLON

MUC FOLDS

HISTOLOGY

MALIGNANT

RISK ≈ 100%

GERMLINE DEFECT

HUNDREDS → THOUSANDS ADENOMATOUS POLYPS

OSTEOMAS

SOFT TIS TUM

DESMOID

MEDULLOB

ASTOMA

TUM CNS

VARIANT

AMPULLARY

DUODENAL

GASTRIC

JEJUNAL

ILEAL

SMALL INTESTINE

COLON

RECTUM

ANAL CANAL

SKIN

GALL BLADDER

BILIARY TRACT

PANCREAS

STOMACH

OVARY

BREAST

LUNG

ENDOMETRIUM

CERVIX

KIDNEY

URETER

BLADDER

PROSTATE

TESTIS

EPIDIDYMIS

VAGINA

VULVA

PENIS

ANUS

ORAL CAVITY

OROPHARYNX

NASOPHARYNX

LARYNX

HYPOPHARYNX

ESOPHAGUS

THYROID

ADRENAL

KIDNEY

BRAIN

SKIN

BONE

LYMPHOMA

LEUKEMIA

SARCOMA

MELANOMA

MESOTHELIOMA

CHRONIC IBD

CHRONIC IFM BOWEL

IFM

↑ RISK

↑ RISK

↑ RISK

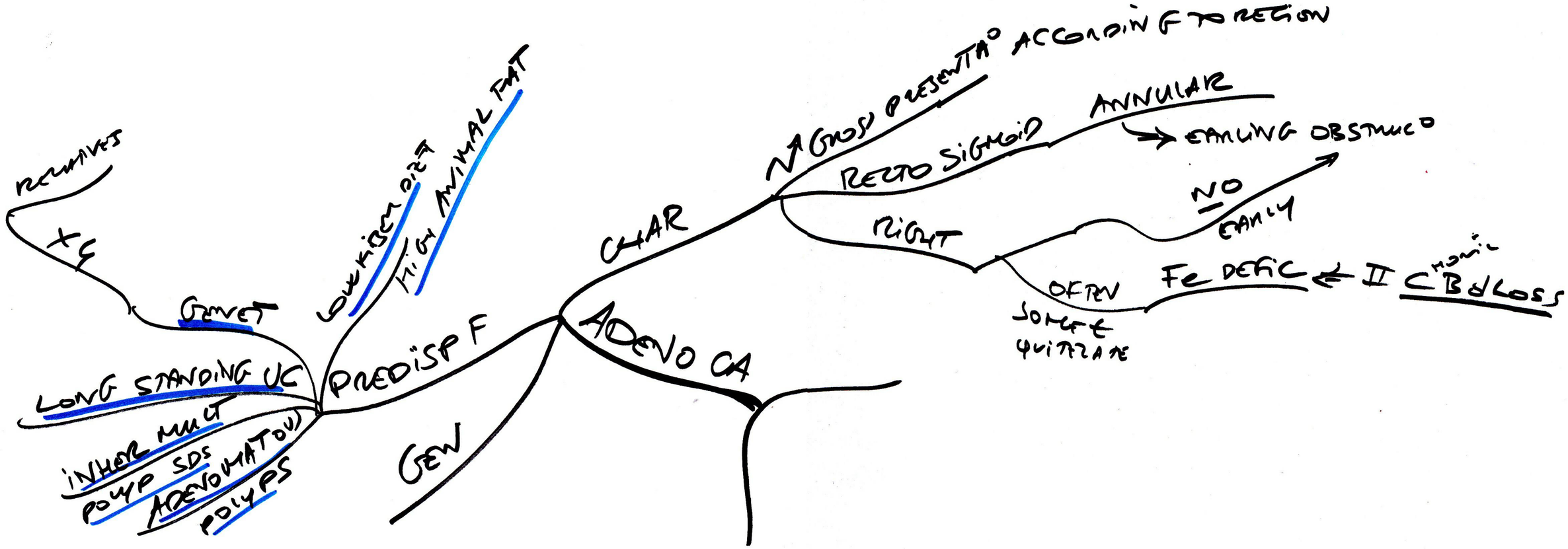
RELATIVES
X4
GENET
LONG STANDING UC
INHER MULT
POLYP SDS
ADENOMATOUS
POLYPS
LOW FIBER DIET
HIGH ANIMAL FAT
PREDISP F
GEN
CHAR
ADENO CA
GROSS PRESENTA° ACCORDING TO REGION
RECTO SIGMOID
ANNULAR
EARLING OBSTRUC°
RIGHT
NO
EARLY
OFTEN
SOME
QUITERATE
Fe DEFIC
II C BdLOSS
HONIC

NL

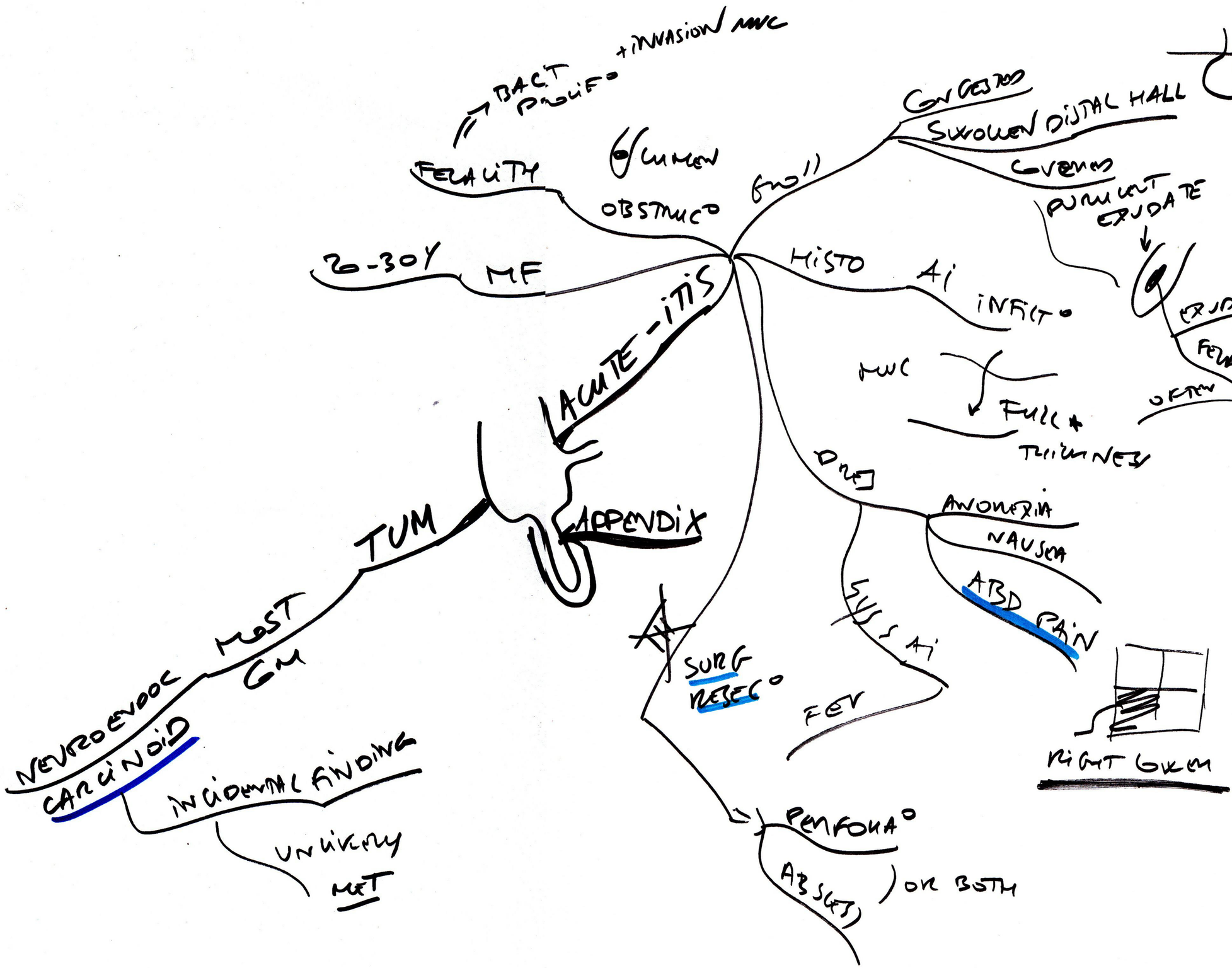
1/2
1/2
BACT PROLIF° + INVASION MUC
FELALITY
LUMEN
OBSTRUC°
GROLL
CONGESTED
SWOLLEN DISTAL HALL
COVERED
PURULENT EXUDATE
EXUDATE
FELALITY
OFTEN
20-30Y
MF
HISTO
AI
INFILT°
MUC
FULL + THICKNESS
ACUTE-ITIS
APPENDIX
DRES
ANOREXIA
NAUSEA
ABD PAIN
SUSS AI
FEV
SURG RESEC°
RIGHT LOWER
TUM
MOST
GM
NEUROENDOC
CARCINOID
INCIDENTAL FINDING
UNLIKELY
MET
PERFORA°
ABSCESS
OR BOTH