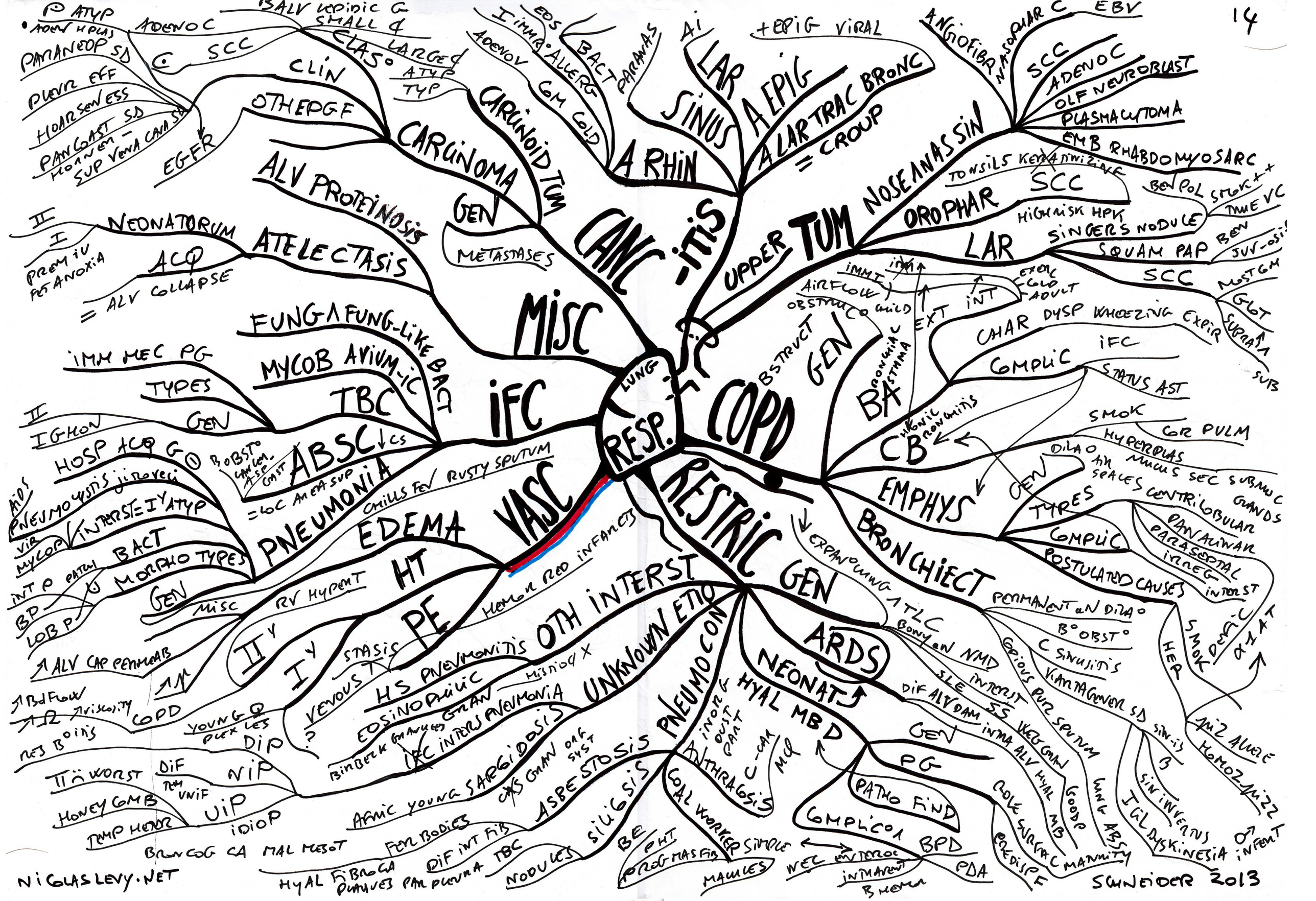

RESP.
CANC
-ITIS
MISC
IFC
YASC
PNEUMONIA
EDEMA
HT
PE
OTH INTERST
UNKNOWN ETIO
PNEUMOCON
RESTRIC
COPD
GEN
BA
CB
EMPHYS
BRONCHIECT
ARDS
NEONAT
HYAL MBD
PG
PATHO FIND
COMPLICOR
BPD
PDA
NOSE ANASSIN
UPPER
TUM
OROPHAR
LAR
SCC
ADENOC
OLF NEUROBLAST
PLASMACYTOMA
EMB RHABDOMYOSARC
SQUAM PAP
SINGERS NODULE
HIGHRISK HPK
TONSILS KERATINIZING
ANGIOFIBR
NASOPHAR C
EBV
SINUS
A RHIN
LAR
A EPIG
A LAR TRAC BRONC
= CROUP
+EPIG VIRAL
CARCINOID TUM
CARCINOMA
CLIN
OTHEPGF
EGFR
ALV PROTEINOSIS
ATELECTASIS
NEONATORUM
ACQ
= ALV COLLAPSE
METASTASES
FUNG ∧ FUNG-LIKE BACT
MYCOB AVIUM-IC
TBC
ABSC
HOSP ACQ G
INTERST = I^Y ATYP
BACT
MORPHO TYPES
GEN
MISC
RV HYPERT
II^Y
I^Y
STASIS
VENOUS
HS PNEUMONITIS
EOSINOPHILIC
GRAN
BIRBECK GRANULES
IFC INTERS PNEUMONIA
SARGIDOSIS
AFRIC YOUNG
ASBESTOSIS
SILICOSIS
FER BODIES
DIF INT FIB
NODULES
HYAL FIBROCA
PLAQUES PAR PLEURA
TBC
BE
PHT
PROG MAS FIB
MACULES
COAL WORKER
SIMPLE
ANTHRACOSIS
C-CAR
MCP
INORG DUST PART
NEC ENTEROC
INTRAVENT
B HEMOR
PNEUMOCYSTIS
JIROVECI
VIR
MYCOP
INT P
PATCH
BP
LOB P
ALV CAP PERMEAB
BdFLOW
VISCOSITY
COPD
YOUNG Q
PLEX LES
DIP
NIP
UIP
IDIOP
DIF
TEM UNIF
HONEY COMB
TEMP HETER
BRONCOG CA
MAL MESOT
IMM MEC PG
TYPES
GEN
IGHON
II
I
PREM IV
PET ANOXIA
II
I
ATYP
ADENOC
SCC
BALV LEPIDIC G
SMALL ¢
LARGE ¢
ATYP
TYP
CLAS°
EOS
I IMMR°
ALLERG
ADENOV
COM COLD
BACT
PARANAS
AI
ANGIOFIBR
SCC
ADENOC
OLF NEUROBLAST
PLASMACYTOMA
EMB RHABDOMYOSARC
BEN POL
SMOK++
TRUE VC
SQUAM PAP
BEN
JUV-OSIS
SCC
MOST COM
GLOT
SUPRA
SUB
IMMI
AIRFLOW
OBSTRUC
CHILD
EXT
INT
EXERC
COLD
ADULT
CHAR
DYSP
WHEEZING
EXPIR
IFC
COMPLIC
STATUS AST
SMOK
COR PULM
HYPERPLAS
MUCUS SEC
SUBMUC GLANDS
DILAO
AIR SPACES
CENTRILOBULAR
TYPES
COMPLIC
PANALINAR
PARASEPTAL
IRREG
INTERST
POSTULATED CAUSES
PERMANENT aN DILAO
B° OBST°
C SINUSITIS
VARTAGENER SD
SIN-IS
HEP
SMOK
DEFIC
α1AT
MIZ ALLELE
HOMOZ MIZZ
SIN INVERTUS
ICIL DYSKINESIA
INFERT
LUNG ABS
GOODP
ROLE SURFAC
MATURITY
PREDISP F
EXPANDING ∧ TLC
BONY aN NMD
SLE
INTERST
DIF ALV DAM
INTRA ALV HYAL
MB
WEG GRAN
OPIOUS PUR SPUTUM
GEN
PG
PATHO FIND
COMPLICOR
BPD
PDA
NICOLASLEVY.NET
SCHNEIDER 2013

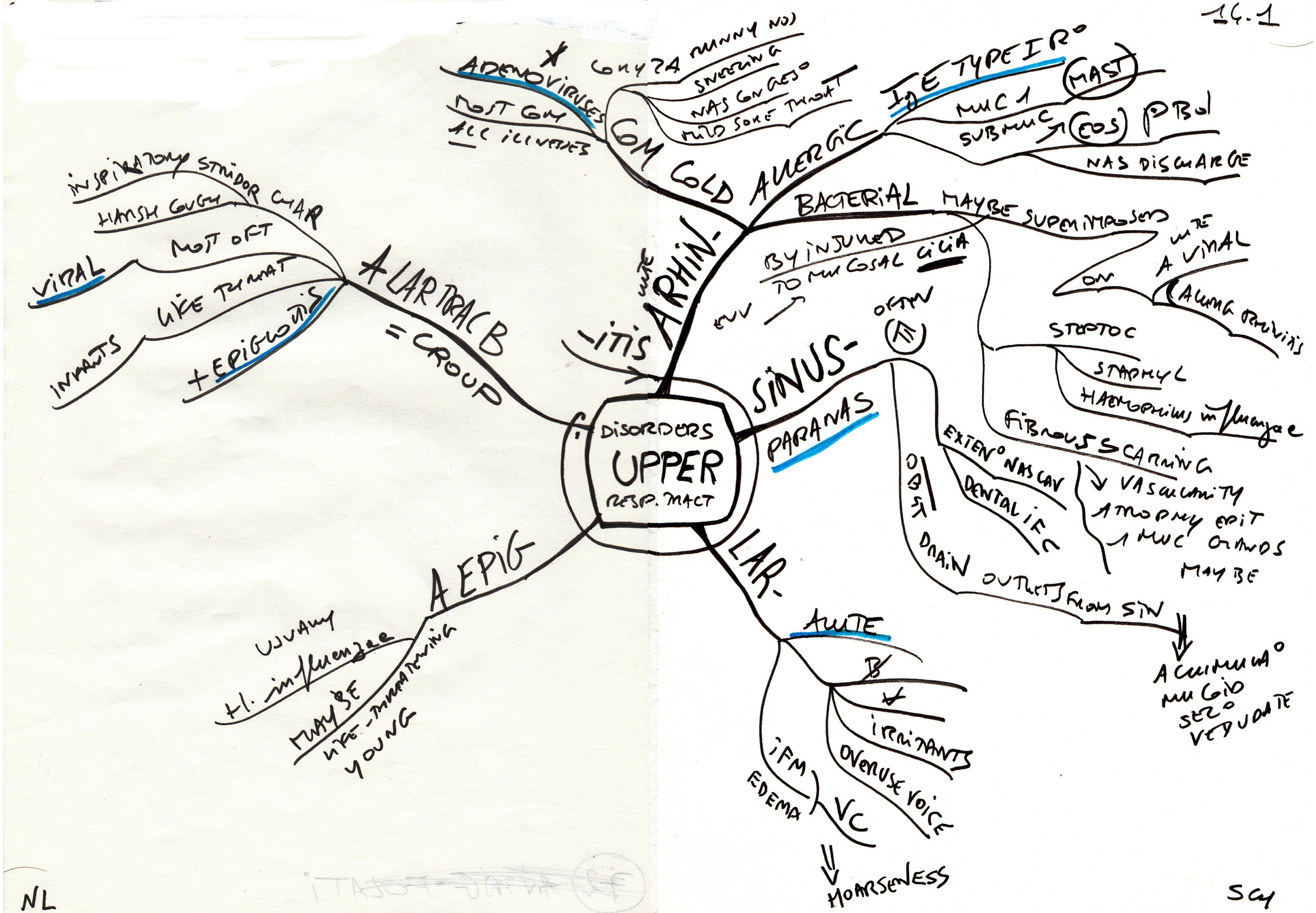
UPPER
DISORDERS
RESP. TRACT
ARHIN-
-ITIS
ACUTE
COM COLD ALLERGIC
ADENOVIRUSES
MOST COM
ALL ILLNESSES
CORYZA
RUNNY NOS
SNEEZING
NAS CONGES°
MILD SORE THROAT
IgE TYPE I R°
MUC 1
MAST
SUBMUC
EOS
PBol
NAS DISCHARGE
BACTERIAL
MAYBE SUPERIMPOSED
ON
ACUTE
A VIRAL
ALLERG RHINITIS
BY INJURED
TO MUCOSAL CILIA
ENV
SINUS-
OFTEN
STEPTOC
STAPHYL
HAEMOPHILUS influenzae
FIBROUS SCARRING
VASCULARITY
ATROPHY EPIT
MUC GLANDS
MAYBE
PARANAS
EXTEN° NAS CAV
DENTAL IFC
OBST
DRAIN OUTLETS FROM SIN
ACCUMULA°
MUCOID
SEC°
VEDUDATE
LAR-
ACUTE
B
V
IRRITANTS
OVERUSE VOICE
IFM
EDEMA
VC
HOARSENESS
A LAR TRAC B
= CROUP
INSPIRATORY STRIDOR CHAR
HARSH COUGH
MOST OFT
VIRAL
LIFE THREAT
INFANTS
+ EPIGLOTTIS
A EPIG
USUALLY
H. influenzae
MAYBE
LIFE-THREATENING
YOUNG
NL
SCY

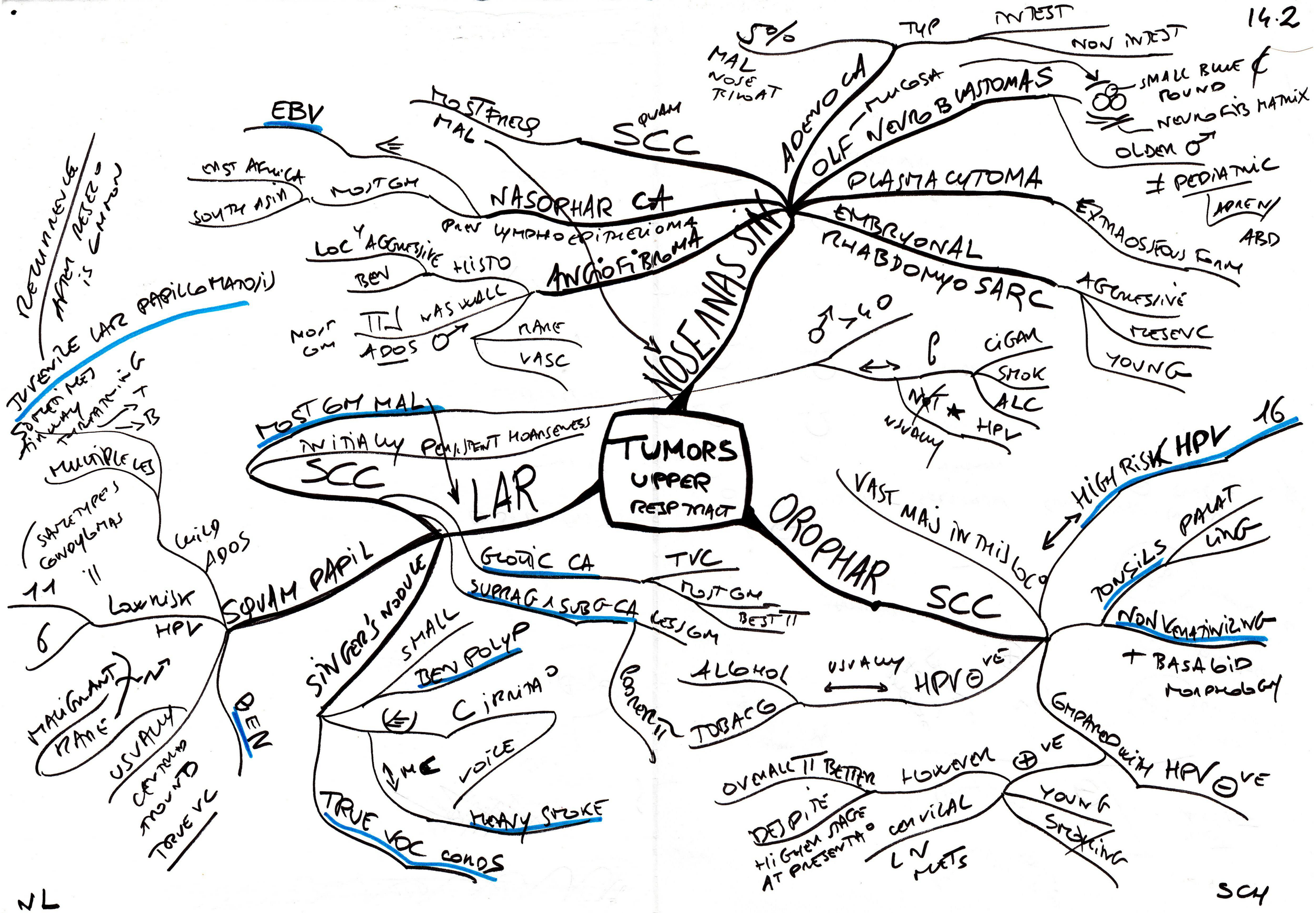
TUMORS
UPPER
RESP TRACT
NOSE ANAS SIN
ADENO CA
5%
MAL
NOSE
TIWAT
TYP
INTEST
NON INTEST
OLF NEVROBLASTOMAS
MUCOSA
SMALL BLUE ¢
ROUND
NEUROFIB MATRIX
OLDER ♂
≠ PEDIATRIC
APREN
ABD
PLASMACYTOMA
EXTRAOSSEOUS FORM
EMBRYONAL
RHABDOMYOSARC
AGGRESSIVE
MESENC
YOUNG
♂ > 40
CIGAR
SMOK
ALC
NOT ★
HPV
USUALLY
NASOPHAR CA
SCC
QUAM
MOST FREQ
MAL
EBV
EAST AFRICA
SOUTH ASIA
MOST GM
PREV LYMPHOEPITHELIOMA
ANGIOFIBROMA
LOC Y AGGRESSIVE
BEN
HISTO
MOST GM
ADOS ♂
NASWALL
RARE
VASC
RECURRENCE
AFTER RESEC
IS COMMON
JUVENILE LAR PAPILLOMATOSIS
SOMETIMES
FIRWAY
THREATENING
→ T
→ B
MULTIPLE LES
SAME TYPES
CONDYLOMAS
11
6
LOW RISK
HPV
WILD
ADOS
SQUAM PAPIL
MALIGNANT
RARE
USUALLY
CENTERED
TROUND
TRUE VC
BEN
MOST GM MAL
INITIALLY PERSISTENT HOARSENESS
SCC
LAR
SINGER'S NODULE
SMALL
BEN POLYP
CIRRITA°
VOICE
MEANY SMOKE
TRUE VOC CORDS
GLOTTIC CA
TVC
MOST GM
BEST ⊤⊤
SUPRAG ∧ SUBG CA
LESS GM
POORER ⊤⊤
OROPHAR
SCC
VAST MAJ IN THIS LOC°
HIGH RISK HPV
16
TONSILS
PALAT
LING
NON KERATINIZING
+ BASALOID
MORPHOLOGY
ALCOHOL
TOBACCO
USUALLY
HPV ⊖ VE
COMPARED WITH HPV ⊖ VE
⊕ VE
YOUNG
SMOKING
HOWEVER
CERVICAL
LN
METS
OVERALL ⊤⊤ BETTER
DESPITE
HIGHER STAGE
AT PRESENTA°
NL
SCH

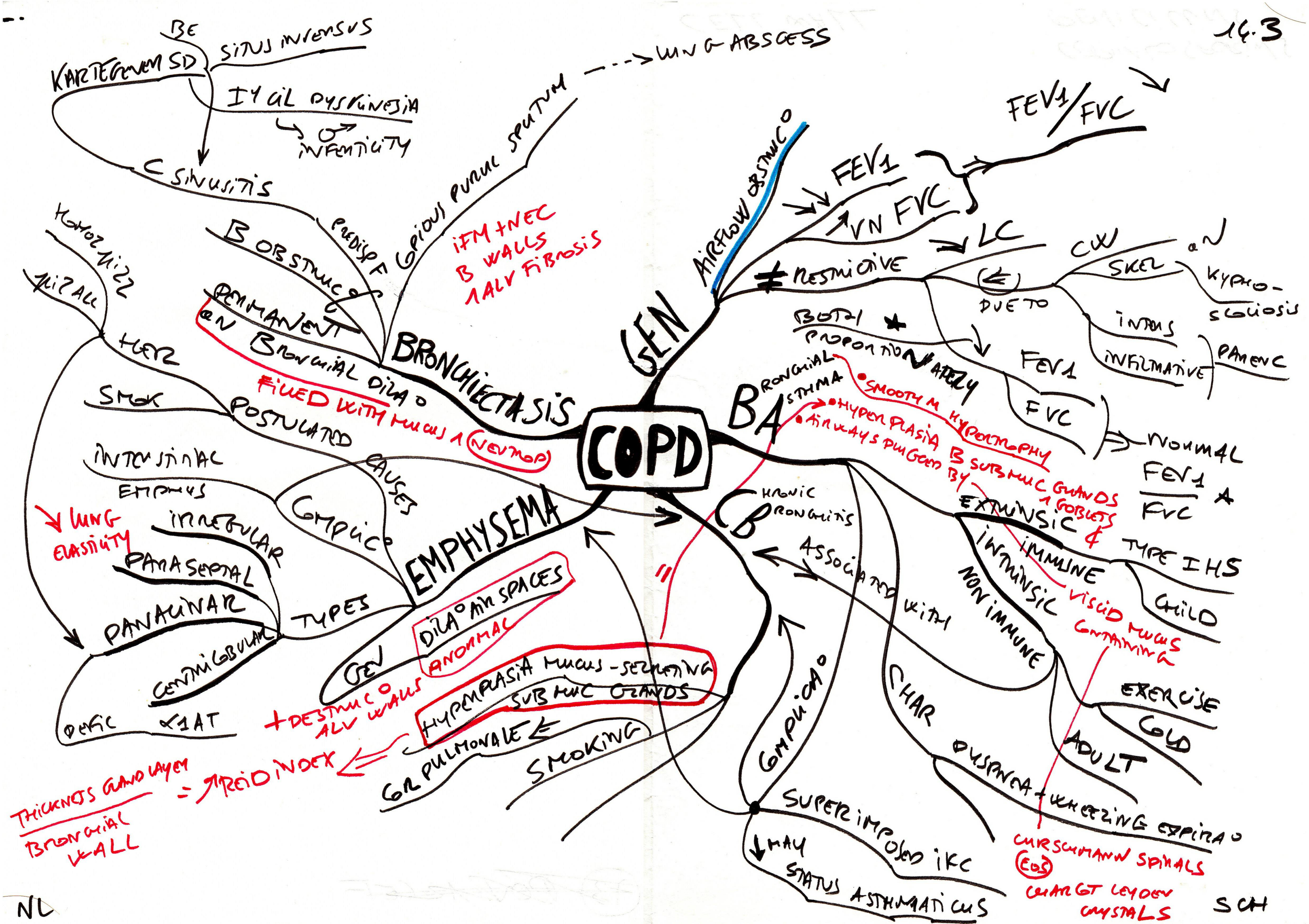
14.3
COPD
GEN
AIRFLOW OBSTRUC°
FEV1
VN FVC
FEV1/FVC
LC
RESTRICTIVE
DUE TO
CW
SKEL
KYPHO-SCOLIOSIS
INTERS
INFILTRATIVE
PARENC
BOTH PROPORTIONATELY
FEV1
FVC
NORMAL FEV1/FVC
BA
BRONCHIAL ASTHMA
SMOOTH M HYPERTROPHY
HYPERPLASIA B SUBMUC GLANDS
AIRWAYS PLUGGED BY
GOBLETS
EXTRINSIC
IMMUNE
INTRINSIC
NON IMMUNE
TYPE IHS
CHILD
VISCID MUCUS CONTAINING
EXERCISE
COLD
ADULT
CHAR
DYSPNEA + WHEEZING EXPIRA°
CURSCHMANN SPIRALS
EOS
CHARGT LEYDEN CRYSTALS
CB
CHRONIC BRONCHITIS
ASSOCIATED WITH
COMPLICA°
SUPERIMPOSED IFC
MAY
STATUS ASTHMATICUS
BRONCHIECTASIS
IFM + NEC
B WALLS
1 ALV FIBROSIS
PREDISP F
COPIOUS PURUL SPUTUM
LUNG ABSCESS
B OBSTRUC°
PERMANENT
BRONCHIAL DILA°
FILLED WITH MUCUS 1 (NEUTROP)
EMPHYSEMA
CAUSES
COMPLIC°
DILA° AIR SPACES
ANORMAL
HYPERPLASIA MUCUS-SECRETING
SUBMUC GLANDS
COR PULMONALE
SMOKING
GEN
+ DESTRUC° ALV WALLS
THICKNESS GLAND LAYER / BRONCHIAL WALL = REID INDEX
TYPES
IRREGULAR
PARASEPTAL
PANACINAR
CENTRIGOBULAR
DEFIC
α1AT
LUNG ELASTICITY
INTERSTITIAL EMPHYS
POSTULATED
SMOK
HER
HOMOZYGOZ
HIZALL
BE
SITUS INVERSUS
KARTEGENER SD
IYCIL DYSKINESIA
INFERTILITY
C SINUSITIS

NL

SCH

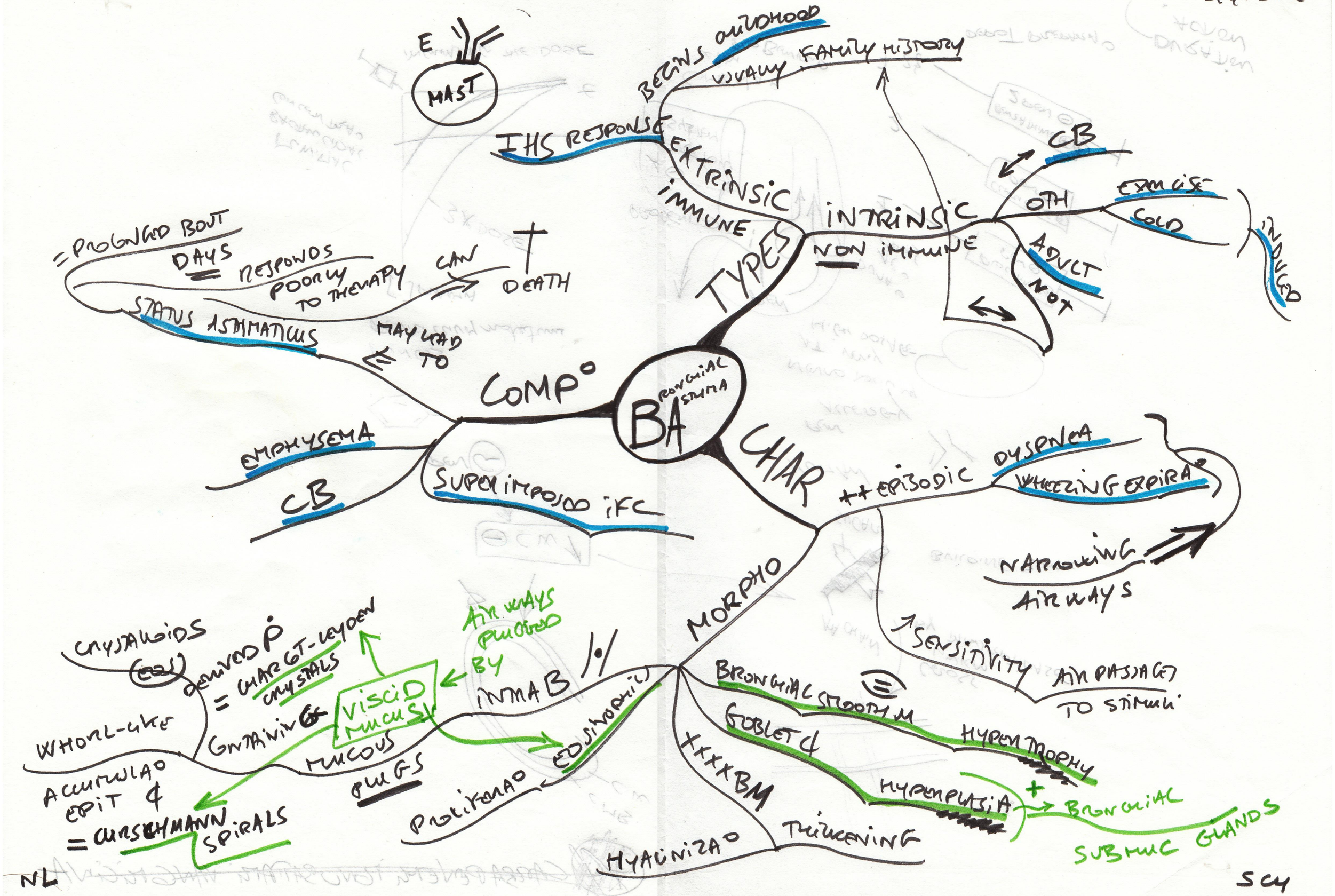
E
MAST
BEGINS CHILDHOOD
USUALLY FAMILY HISTORY
IHS RESPONSE
EXTRINSIC
IMMUNE
TYPES
INTRINSIC
NON IMMUNE
CB
OTH
EXERCISE
COLD
INDUCED
ADULT
NOT
= PROLONGED BOUT
DAYS
RESPONDS POORLY TO THERAPY
CAN
DEATH
STATUS ASTHMATICUS
MAY LEAD TO
COMP°
BA
BRONCHIAL ASTHMA
EMPHYSEMA
CB
SUPERIMPOSED IFC
CHAR
++ EPISODIC
DYSPNEA
WHEEZING EXPIRA°
NARROWING AIRWAYS
SENSITIVITY
AIR PASSAGES TO STIMULI
MORPHO
BRONCHIAL SMOOTH M
HYPERTROPHY
GOBLET ¢
HYPERPLASIA
+
BRONCHIAL SUBMUC GLANDS
XXXXBM
THICKENING
HYALINIZA°
EOSINOPHILS
PROLIFERA°
INTRA B
AIR WAYS PLUGGED BY
VISCID MUCUS
MUCOUS PLUGS
CONTAINING
CRYSTALLOIDS (EOS)
DERIVED Ṗ = CHARGT-LEYDEN CRYSTALS
WHORL-LIKE
ACCUMULA° EPIT ¢ = CURSCHMANN SPIRALS
NL
SCH

14.3.3

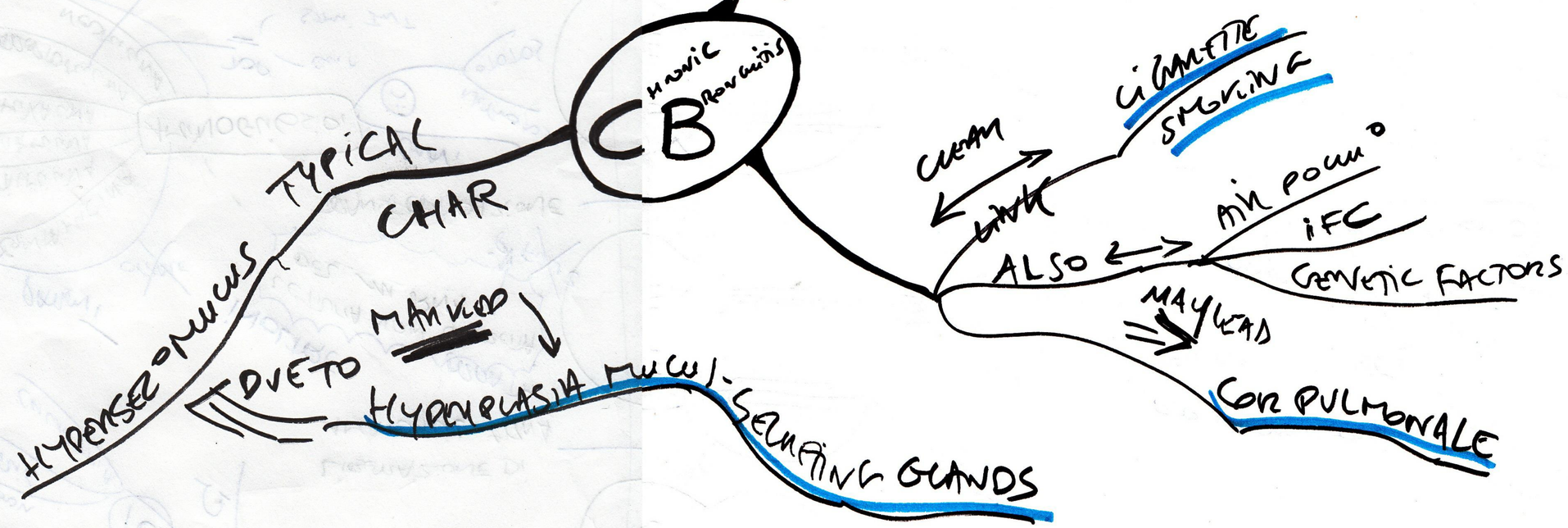
CHRONIC BRONCHITIS
CLINICAL DEFINITION
COUGH PRODUCTIVE
AT LEAST 3 CONSECUTIVE MONTHS
OVER AT LEAST 2 CONSECUTIVE YEARS
CIGARETTE SMOKING
CREAM
AIR POLL°
IFC
ALSO
GENETIC FACTORS
MAY LEAD
COR PULMONALE
TYPICAL CHAR
HYPERSEC° MUCUS
DUE TO
MAINLY
HYPERPLASIA MUCUS-SECRETING GLANDS

NL

SCH

16.3.

POSTULATED CAUSES

EMPHYSEMA

TYPES

GEN

- α_1 AT DEFIC
  - SUB SMALL GROUP CASES
  - PANACINAR EMP
  - CAUSED VARIANTS
  - Z ALLELE → STIMULAR ACTIVITY IN P. INCLUSIONS WITH HEPATIC SEC.
    - HEPATIC DROPOUT
    - LIVER DAMAGE
  - HOMOZYGOTE
    - ACTIVITY ↓↓ α_1 AT
    - PANACINAR EMP
    - 10 YRS HEP CIRRHOSIS
  - ZZ
- DIFFUSE AIR SPACES
  - + DESTRUC ALV WALLS
  - ∅ ELASTIC RECOIL
  - STRONG ↔ CIGARETTE SMOKING
- CLI
  - TVC
    - HYPOXIA
    - CYANOSIS
    - RESP ACIDOSIS
  - MX-II ∅ QUEST
- CIGARETTE SMOKING
- HEREDITARY
- ACTIVATES α_1 AT
- INACTIVATES α_1 AT
- ELASTIN
  - ALV WALL
  - ↑ DESTRUC
  - ↓ ELASTASE
- ELASTASE
  - PROTEOLYTIC ENZ
  - NEUT
  - MØ
  - ATMØ
  - → ELASTASE
- ANTIPROTEASE - ANTIELASTASE ACTIVITIES OF α_1-AT
  - UNLESS NORMALIZE
- PNX
  - RUPTURE SUBPLEURAL BLEB
  - ALVEOLAR WALLS
    - INTO INTERSTITIAL TISSUES
    - FROM A BRONCHUS OR BRONCHIOLE
    - OF NEST
    - INTERSTITIAL EMPHYSEMA
      - COEXISTENT
      - BY OR OFTEN
      - CB
- COMPLIC°
  - + SCARRING IN WALLS OF ENLARGED SPACES
  - IRREGULAR
    - IRREGULAR INVOLVEMENT ACINUS
    - OCCASIONALLY
    - PARASEPTAL
      - VARIOUS IDM PROCESSES
      - USUALLY COMPLIC°
      - ★ MESIAL EXTENT
        - ALV DUCTS
        - ALV
      - SUBJACENT TO PLEURA
      - ↓ INTRALOB TENDS TO SPARE LOBULE
      - MAINLY DILA°
      - LARGE SUBPLEURAL BULLAE = BLEBS ↔ PNX
      - DISTAL PART ACINUS
      - SOMETIMES ↓ ELASTICITY
      - =α_1-PROTEASE INHIBITOR DEFIC α_1-AT
      - GEN Y DETERMINED
      - DISTRIBUTED UNIFORMLY THROUGHOUT LUNG
  - PANACINAR
    - MOST OFTEN DILA° RESP BRONCHIOLES
    - EVENLY ACINUS
    - ALV ALV DUCTS
    - CIGARETTE SMOKING
  - CENTRILOBULAR
    - DILA° RESP BRONCHIOLES
    - UPPER PART LOBES OFTEN
    - STRONG ↔ CIGARETTE SMOKING

B° = BRONCHIOLE

NL

SCH

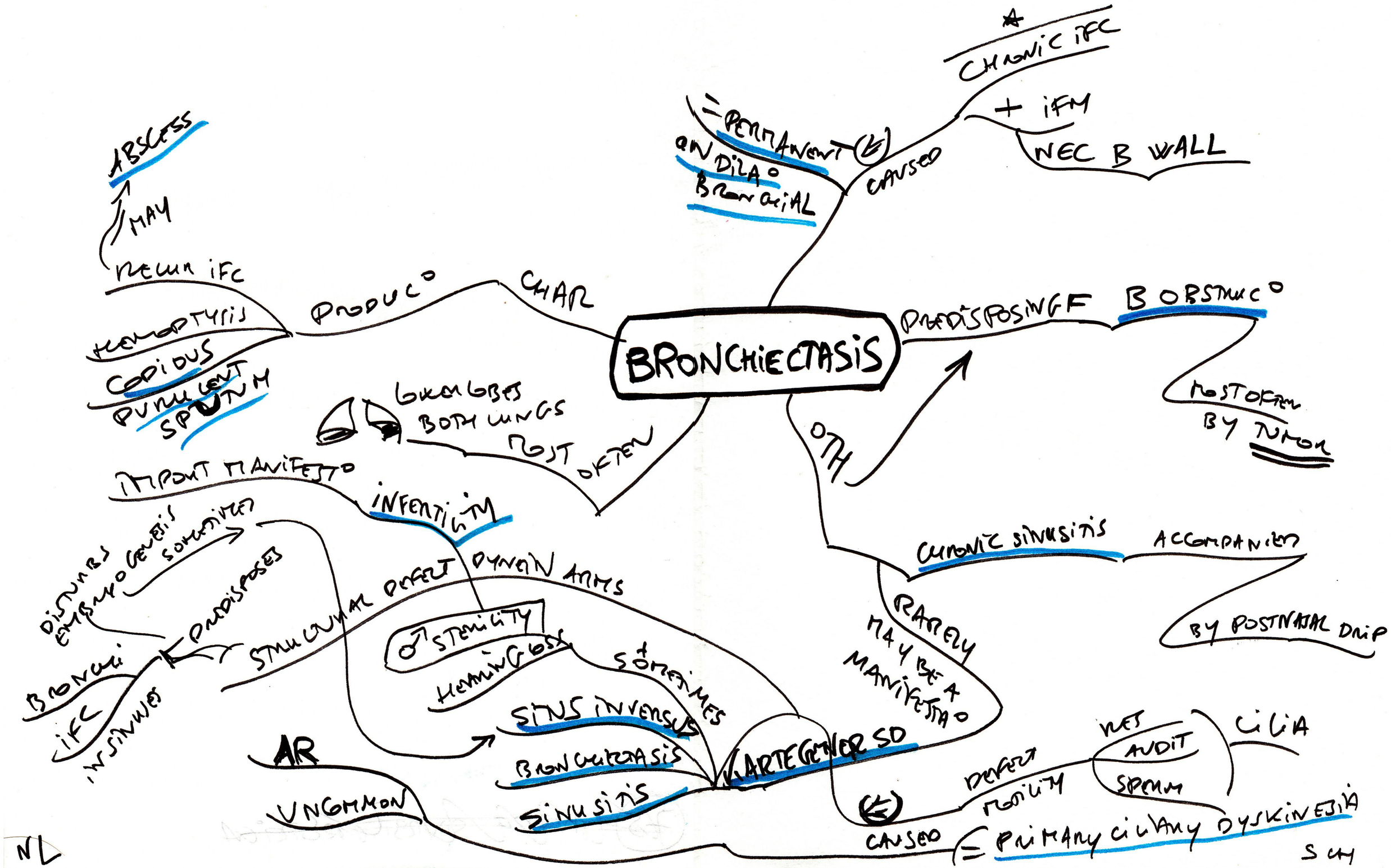
BRONCHIECTASIS
CHAR
PRODUC°
RECUR IFC
MAY
ABSCESS
HEMOPTYSIS
COPIOUS
PURULENT
SPUTUM
CAUSED
= PERMANENT (⇐)
ANDILA°
BRONCHIAL
CHRONIC IFC
+ IFM
NEC B WALL
PREDISPOSING F
B OBSTRUC°
MOST OFTEN
BY TUMOR
OTH
LOWER LOBES
BOTH LUNGS
MOST OFTEN
IMPORT MANIFESTO
INFERTILITY
DISTURBS
EMBRYOGENESIS
SOMETIMES
PREDISPOSES
BRONCHI
IFC
IN SINUSES
STRUCTURAL DEFECT
DYNEIN ARMS
♂ STERILITY
HEARING LOSS
SOMETIMES
SITUS INVERSUS
BRONCHIECTASIS
SINUSITIS
KARTEGENER SD
AR
UNCOMMON
CHRONIC SINUSITIS
ACCOMPANIED
BY POSTNASAL DRIP
RARELY
MAY BE A
MANIFESTA°
(⇐)
CAUSED
DEFECT
MOTILITY
RES
AUDIT
SPERM
CILIA
= PRIMARY CILIARY DYSKINESIA
NL
SCH

- . EXTRINSIC ALLERGIC ALVEOLITIS
- INHALED Ag

SPORES THERMOPHILIC ACTINOMYCETES
MOULDY HAY
FARMER

RESTRICTIVE

HS PNEUMONITIS
- ACUTE
- SUBACUTE
- CHRONIC

AGGRESSIVE HOUSEKEEPING
CHILDREN
FIBROSING
TEMP / METAB
UIP
NIP
DIP
IDIOP
TEEN YOUNG
MALE PREDOT
BG CA
AFRICAN
?
SARCOIDOSIS
CXR
GRAN
UNKNOWN ETIO
IPF : INTERS PNEUMONIA
≠ PULM GRAN
GOODPASTURE WITHOUT RENAL INVOLV

OTH INTERST
- EOSINOPHILIC GRANULOMA
- LANGERHANS
- RESTRICT
- REDUCED EXPANSION LUNG
- TLC
- BONY CAN
- NMD
- CHEST WALL
- GEN

ALSO INCLUDE
INTERSTITIAL
ACCUMULATION OF NON C MAT
DUST RESPIRATORY DISTRESS SYNDROME
ARDS
- IMMUNE MEDIATED DAMAGE
- DAD
- INTIMAL HYALINE MB
- SLE
- SS
- WEGEN GRAN
- GOODPASTURE SD

ASSOCIATION
CHEM
DRUG
- BENYLIOSIS
- BLEOMYCIN

+ PNEUMOCYSTIS PNEUMONITIS + GN
ALV GLOMERULAR BMT
PNEUMONITIS
RHAT OA
VASCULAR

INVALV WALLS
IMPAIRED GAS EXCHANGE

NEONAT
- HYALINE MB D
- GEN
- PG
- PNEUMOSP
- ROLE SURFACTANT
- FETAL PULM MATURITY
- LECITHIN
- SPHINGOMYELIN
- [PHOSPHATIDYL GLYCEROL]
- LAMELLAR BODY COUNT
- FLUOR POLARIZ ASSAY
- SCH

PATHO

PNEUMOCONIOSES
- HYALINIZED FIBROUS PLAQUES
- PAN PULM BENIGN
- DIF INT FIB
- ASBESTOSIS
- ↑ BRONCH PHT
- TBC
- NODULES SILICOSIS
- PROGRESSIVE MASSIVE FIB
- SIMPLE NODULES
- COAL WORKERS
- ANTHRACOSIS
- C DUST CARRYING MΦ
- INHALED INORG DUST PARTICLES
- NEOPLASTIC
- INVAGINATED BRONCH EPITH
- BP DYSPLASIA
- COMPLICATED
- PROLIFERATIVE HISTIOCYTIC REACTION (LANGERHANS) SKIN

NL

16.4.2

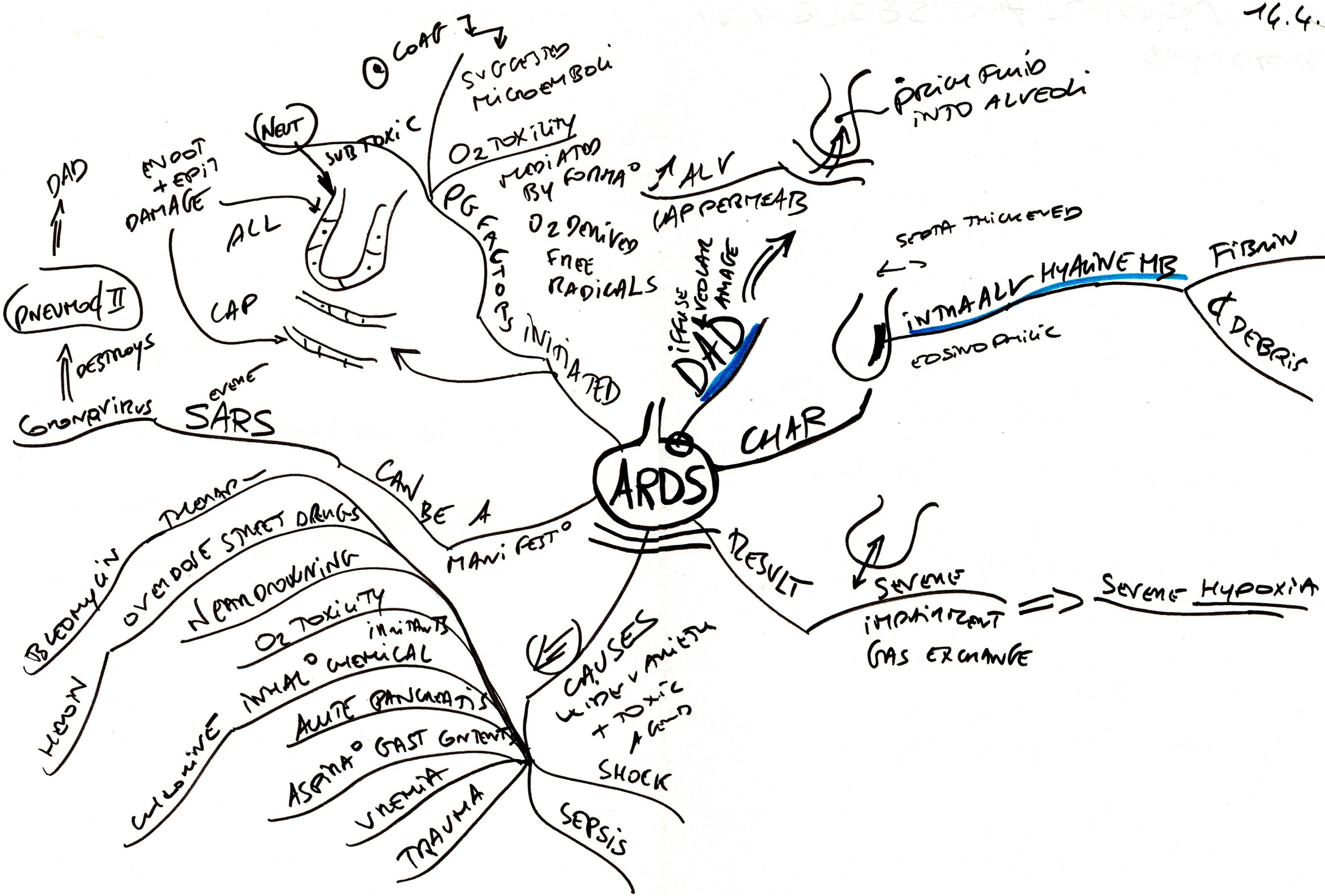
COAG
SYSTEMIC MICROEMBOLI
NEUT
SUB TOXIC
O2 TOXICITY
MEDIATED BY FORMATION
PG FACTORS INITIATED
O2 DERIVED FREE RADICALS
DAD
ENDOT + EPIT DAMAGE
ALL
CAP
PNEUMO II
DESTROYS
CORONAVIRUS
SARS
EVENT
DIFFUSE ALVEOLAR DAMAGE
ALV CAP PERMEAB
PROTEIN FLUID INTO ALVEOLI
SEPTA THICKENED
INTRA ALV HYALINE MB
EOSINOPHILIC
FIBRIN & DEBRIS
CHAR
ARDS
CAN BE A MANIFESTATION
RESULT
SEVERE IMPAIRMENT GAS EXCHANGE
SEVERE HYPOXIA
CAUSES
DIRECT VASCULITIS + TOXIC AGENTS
SHOCK
SEPSIS
TRAUMA
ASPIRATION GAST CONTENTS
ACUTE PANCREATITIS
INHAL CHEMICAL IRRITANTS
O2 TOXICITY
NEAR DROWNING
OVERDOSE STREET DRUGS
THERAP
BLEOMYCIN
HEROIN
CYCLOPHOSPHAMIDE

NL

SCM

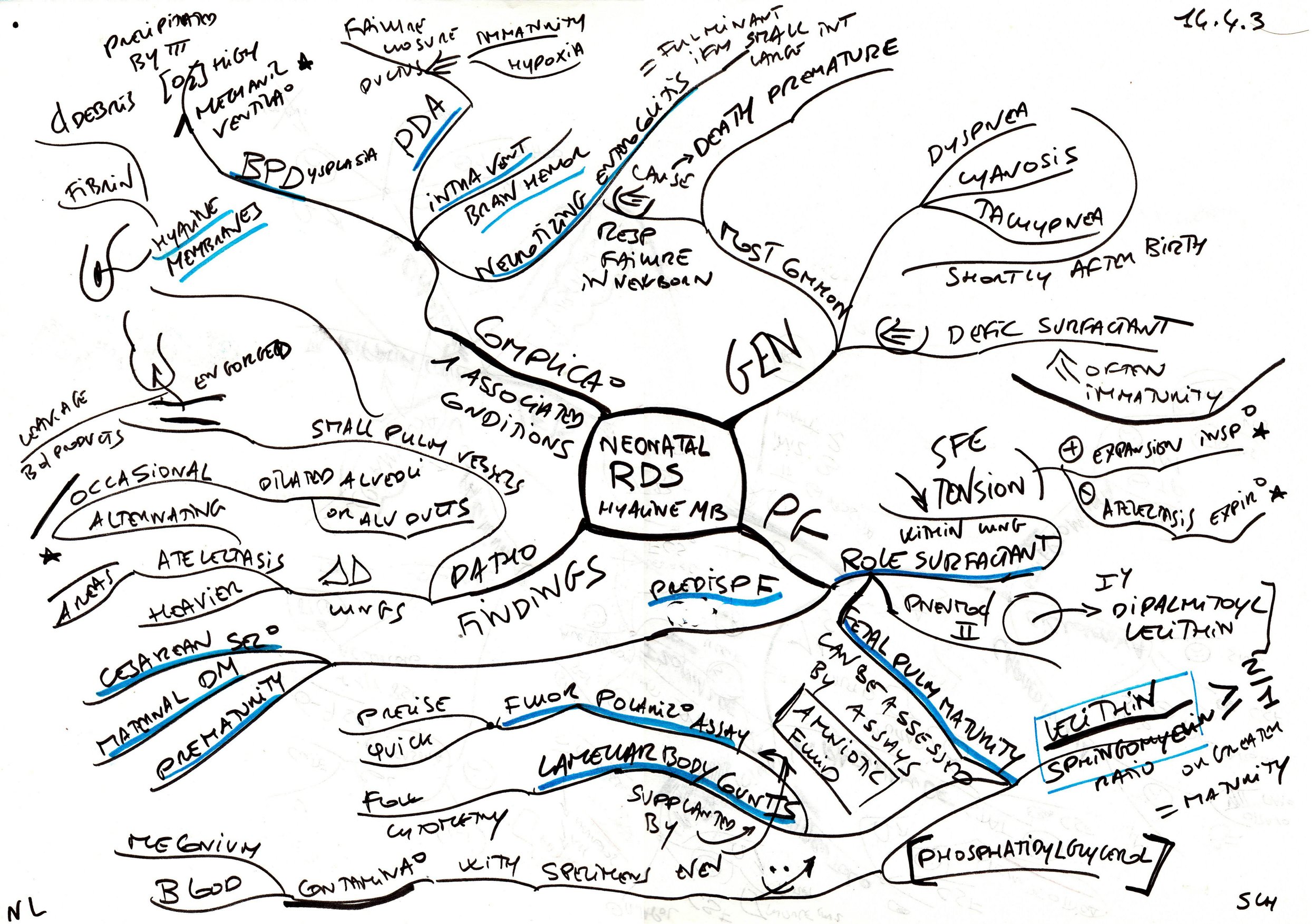

14.4.3
NEONATAL RDS
HYALINE MB
GEN
MOST COMMON
DYSPNEA
CYANOSIS
TACHYPNEA
SHORTLY AFTER BIRTH
DEFIC SURFACTANT
OFTEN IMMATURITY
PF
SFE TENSION
EXPANSION INSP°
ATELECTASIS EXPIR°
WITHIN LUNG
ROLE SURFACTANT
PNEUMOC II
IY DIPALMITOYL LECITHIN
FETAL PULM MATURITY
CAN BE ASSESSED BY ASSAYS
AMNIOTIC FLUID
LECITHIN
SPHINGOMYELIN RATIO
≥ 2/1
OR GREATER = MATURITY
PHOSPHATIDYLGLYCEROL
PREDISPF
PATHO FINDINGS
LUNGS
ATELECTASIS
HEAVIER
AREAS
OCCASIONAL
ALTERNATING
DILATED ALVEOLI
OR ALV DUCTS
SMALL PULM VESSELS
LEAKAGE
BLOOD
CONTAMINA°
WITH SPECIMENS EVEN
MECONIUM
BLOOD
FLOW CYTOMETRY
LAMELLAR BODY COUNTS
SUPPLANTED BY
PRECISE
QUICK
FLUOR POLARIZ° ASSAY
CESAREAN SEC°
MATERNAL DM
PREMATURITY
HYALINE MEMBRANES
FIBRIN
DEBRIS
PRECIPITATED BY ↑↑↑
[O2] HIGH
MECHANIC VENTILA°
BPD DYSPLASIA
PDA
FAILURE CLOSURE
DUCTUS
IMMATURITY
HYPOXIA
INTRA VENT
BRAIN HEMOR
NEUROTIZING ENTEROCOLITIS
= FULMINANT IFM SMALL INT LARGE
CAUSE → DEATH PREMATURE
RESP FAILURE IN NEWBORN
COMPLICA°
ASSOCIATED CONDITIONS
ENGORGED
NL
SCH

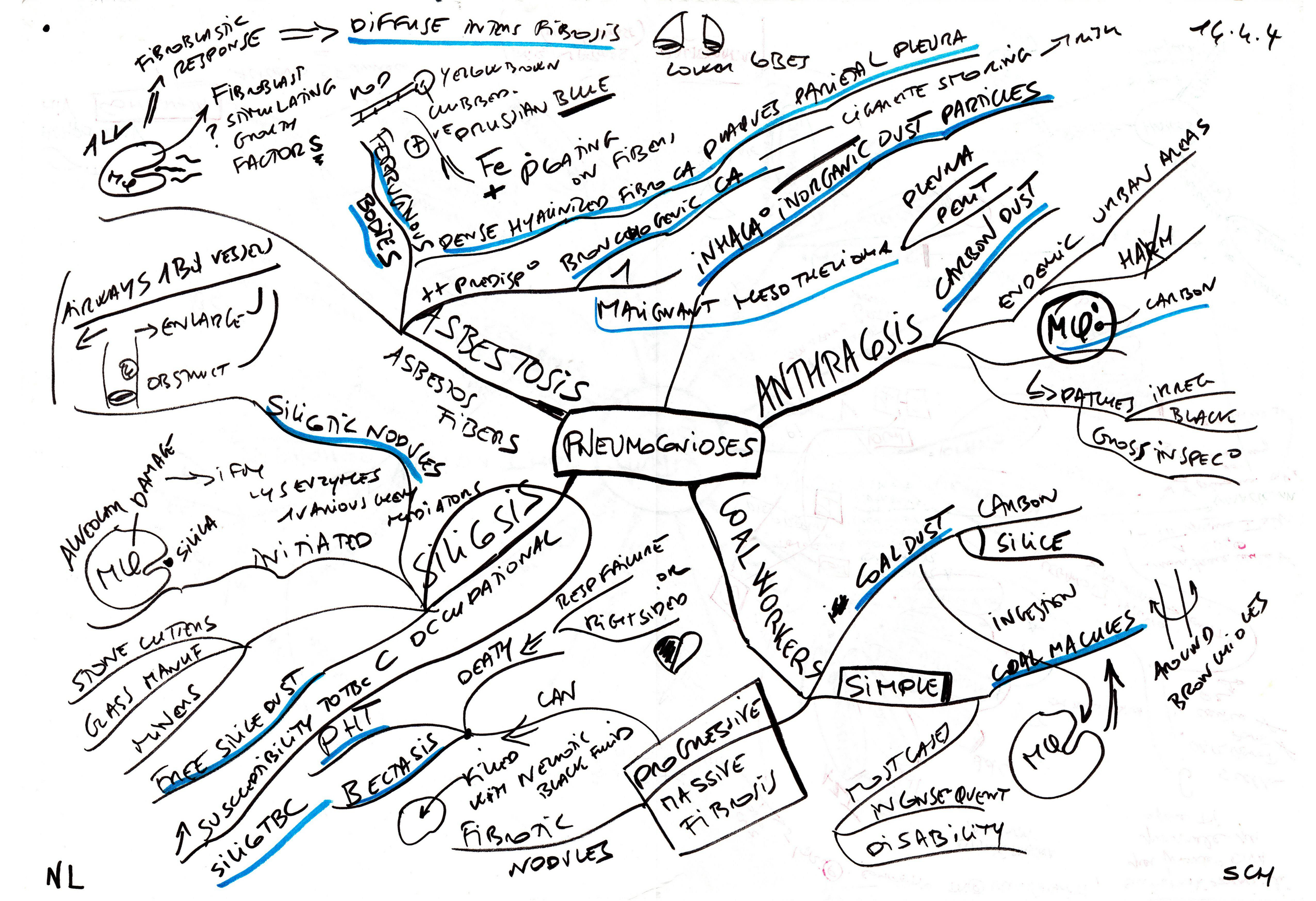

14.4.4
PNEUMOCONIOSES
ASBESTOSIS
ASBESTOS FIBERS
FIBROBLASTIC RESPONSE
DIFFUSE INTERS FIBROSIS
LOWER LOBES
ALL
FIBROBLAST STIMULATING GROWTH FACTORS
MΦ
NOD
YELLOW BROWN
CLUBBED
PRUSSIAN BLUE
Fe
+ PCOATING ON FIBERS
FERRUGINOUS BODIES
DENSE HYALINIZED FIBRO CA PLAQUES PARIETAL PLEURA
CIGARETTE SMOKING
BRONCHOGENIC CA
++ PREDISP°
INHALA° INORGANIC DUST PARTICLES
MALIGNANT MESOTHELIOMA
PLEURA
PERIT
CARBON DUST
ANTHRACOSIS
ENDEMIC URBAN AREAS
HARM
CARBON
MΦ
PATCHES
IRREG
BLACK
GROSS INSPEC°
AIRWAYS ABU VESSELS
ENLARGE
OBSTRUCT
SILICOTIC NODULES
SILICOSIS
ALVEOLAR DAMAGE
IFM
LYS ENZYMES
VARIOUS CHEM MEDIATORS
MΦ
SILICA
INITIATED
STONE CUTTERS
GLASS MANUF
MINERS
FREE SILICE DUST
SUSCEPTIBILITY TO TBC
PHT
SILICOTBC
BECTASIS
DEATH
RESP FAILURE
OR
RIGHTSIDED
CAN
KILLED WITH NECROTIC BLACK FLUID
FIBROTIC NODULES
PROGRESSIVE
MASSIVE FIBROSIS
COAL WORKERS
COAL DUST
CARBON
SILICE
INGESTION
COAL MACULES
AROUND BRONCHIOLES
SIMPLE
MΦ
MOST CASES
INCONSEQUENT
DISABILITY
NL
SCH

16.4.5

SARCOIDOSIS

PRIMARY

ANCHI ALV

PULMONARY FIB

RELATED TO RESP BRONCHIOLITIS-INT LD

SMOKERS

IY

5-Y SURVIVAL → 80%

↓ MUCH BETTER THAN

IPF

SECONDARY

TOY SURVIVAL TO → 100%

TT → UIP

PATHO

CAN MIMICS ★ SMOK

DIP

DESQUAMATIVE

MISSION LOPD

DETERMINANTS FROM EPIT

IN MA ALV

NON INFECTIOUS INTERSTITIAL

RESTRICTIVE UNKNOWN ETIOLOGY

PNEUMONIAS

VARIABLE DEGREES PULM FIBROSIS

SEVERAL INTERSTITIAL PNEUMONIA

UIP

PROGNOSIS WORST MEAN SURVIVAL 4-6Y

END STAGE = HONEYCOMBING = GROSSLY MYSTIC REMODELING WITH SCARRING FIBROSIS

MOST COMMON

CTD

SD

CONNECTIVE TISSUE DISEASE

IDIOPATHIC PULM FIBROSIS

ETIO?

TEMPORAL HETEROGENEITY

= FIBROSIS AT ≠ AGES

PATHO HALLMARK

IMMUNE INVOLVT SUSPECTED

PATTERN CAN BE USEFUL TO VARIETY ETIO

NONSPECIFIC

NIP

PROGR FIBROSING NT

DIFFUSE TEMPORAL UNIFORM

DRUG REACT

HS PNEUMONITIS

CT VASCULITIS

IFC

TEEN YOUNG ADULT YEARS

AFRICAN

MANY

FREQ

CAN INVOLVE

MULTIPLE ORGAN SYSTEM

OFTEN

CASEATING GRANULOMAS

CLIN PRESENT USUALLY

GRANULOMATOUS PATHO FINDINGS

INTERSTITIUM

ENLARGED HILAR LN

UVEITIS

ERYTHEMA NODOSUM

POLYARTHRITIS

IMMUNO PHEN

SENSITIVITY

+ OFTEN ANERGY SKIN TEST

CL: POLYC HYPERGLOBULIN

ROUTINE CHEST RADIOGRAPHY

LAB

ΔDCBW

CONVENTENZ ANGIOT

HRCT

HL-BX

HL-U

LUNG INVOLVT

BIHILAR LYMPHO ADENOPATHY

DIFFUSE RETICULAR DENSITIES

VENOUS TUBERCULIN

NL

SCM

14.4.6

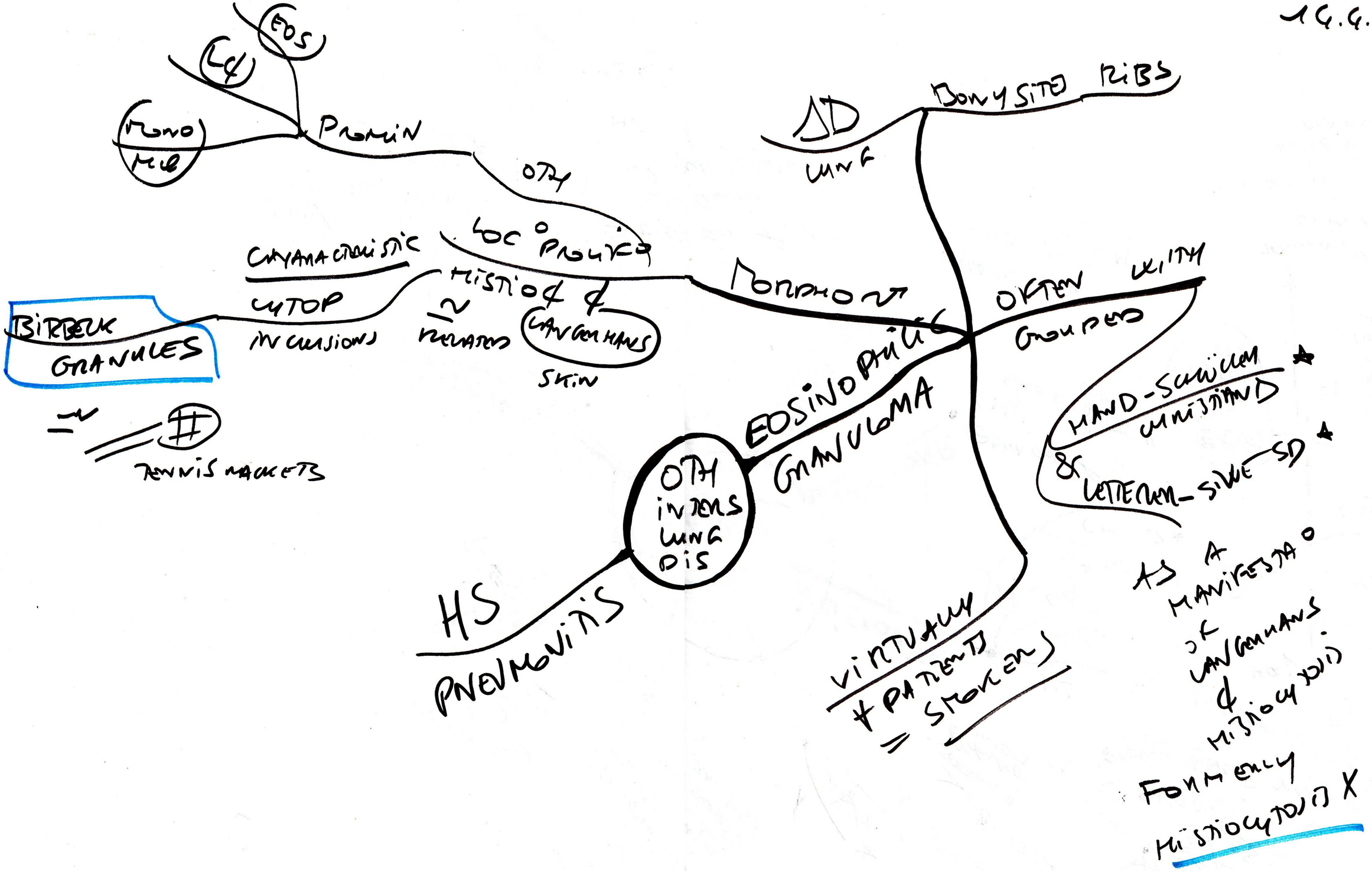
EOS
LC
MONO
MC
PROMIN
OTH
LOC PROLIFO
CHARACTERISTIC
CYTOP
INCLUSIONS
BIRBECK
GRANULES
TENNIS RACKETS
HISTIOC
RELATED
LANGERHANS
SKIN
MORPHOM
ΔD
LUNG
BONY SITES
RIBS
OFTEN
GROUPED
WITH
HAND-SCHÜLLER
CHRISTIAND
&
LETTERER-SIWE SD
EOSINOPHILIC
GRANULOMA
OTH
INTERS
LUNG
DIS
HS
PNEUMONITIS
VIRTUALLY
+ PATIENTS
= SMOKERS
AS A
MANIFESTATION
OF
LANGERHANS
&
HISTIOCYTOSIS
FORMERLY
HISTIOCYTOSIS X

NL

SCY

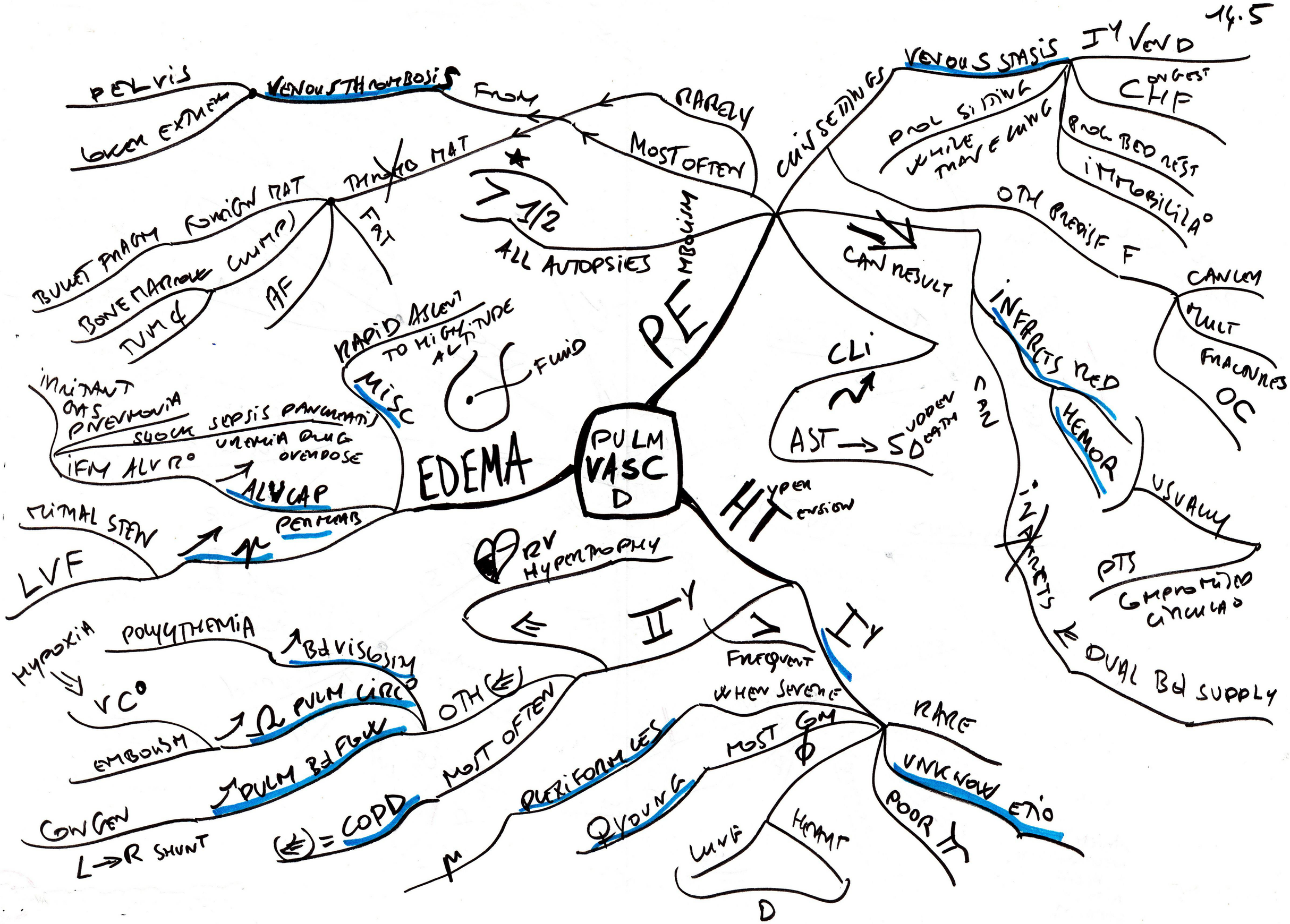
14.5
PULM VASC D
PE
EDEMA
VENOUS THROMBOSIS
PELVIS
LOWER EXTREM
FROM
RARELY
MOST OFTEN
THROMB MAT
FAT
BULLET FRAGM
FOREIGN MAT
BONE MARROW
CLUMPS
TUM ¢
AF
> 1/2
ALL AUTOPSIES
CLIN SETTINGS
VENOUS STASIS
IY VEND
CHF
ONGEST
PROL SITTING
WHILE TRAVELLING
PROL BED REST
IMMOBILIZA°
OTH PREDISF F
CAN RESULT
CANCER
MULT
FRACTURES
OC
INFARCTS RED
HEMOR
CAN
CLI
AST → SD
SUDDEN DEATH
USUALLY
PTS
COMPROMISED CIRCULA°
INFARCTS
DUAL Bd SUPPLY
RAPID ASCENT TO HIGH ALTITUDE
MISC
FLUID
IRRITANT GAS
PNEUMONIA
SHOCK SEPSIS PANCREATIS
UREMIA DRUG OVERDOSE
IFM ALV R°
ALV CAP
PERMEAB
MITRAL STEN
LVF
HYPERTENSION
RV HYPERTROPHY
II Y
I Y
FREQUENT
WHEN SEVERE
RARE
UNKNOWN ETIO
POOR
MOST COM
LUNG
HEART
D
QYOUNG
PLEXIFORMLES
MOST OFTEN
OTH (⇐)
(⇐) = COPD
HYPOXIA
POLYCYTHEMIA
Bd VISCOSITY
VC°
EMBOLISM
PULM CIRC°
PULM Bd FLOW
CONGEN
L→R SHUNT

14.6.1

PNEUMONIA

GEN

HOSP-ACQ
GRAM ⊖VE

COMMUNITY
ATYPICAL
MYCOPLASMA PNEUMONIAE
MOST GM INTERM
CHILDREN
YOUNG ADULTS
MAY EPIDEMICS

CHLAMYDIA PNEUMONIAE
ONSET MORE INSIDIOUS
↑BACT USUALLY MILD SELF LIMITING COURSE

LEGIONELLA
↓BY COMPROMISED
WEEKS INCUBAT°
↔MAY ✱ Fever
SPUTUM
CULT INTMST
IFM GRAM⊖
ED UDATE
ALV
MACRO
INTMA ALV
MYALINE MBS

RICKETTSIAL
CATTLE SHEEP UNPAST MILK
VIRAL

PNEUMOCYSTIS JIROVECI = CARINII

ORNITHOSIS = PSITTACOSIS
CHLAMYDIA
ORNITHOSIS
IFC BIRDS

INTERSTITIAL = ATYPICAL
DIFFUSE PATCHY IFM
IN TODDS ANIMALS
ALV
WALLS
IFM
INFILTRATE EXUDATE

MORPHOTYP
✱CLIN PATTERNS

LP
LOBAR
STREPTOCOCCUS PNEUMONIAE =PNEUMOCOCCUS
↑BAND(N)
SHIFT TO LEFT

BP
BRONCHO
INTERSTITIAL
MANY STAPH AUREUS
HAEM inf
VIRUS ✱
MYCOP PNEU ✱
VIRUS ✱
MYCOP PNEUM ✱

LP
↓TACTILE FREMITUS
INTMA ALV
EXUDATE
MAY INVOLVE ENTIRE LOBE

BP
PATCHY DISTRIB°
ONE OR MORE LOBES

CLIN
FEVER
CHILLS
COUGH PRODUCTIVE
SPUTUM RUSTY
↑BD TINGED
PLEURITIC PAIN
HYPOXIA + SHORTNESS BREATH
SOMETIMES CYANOSIS
IF BACT ⇒ MOST GRAM (N) LEUKOCYTOSIS + ↑BAND(N)

IFM
PARENCHYMA
IFC ⇒ IFM

EXANTHEMS MAY PATTERN
RUBEOLA VARICELLA (CHICKEN POX)
MEASLES
GIANT ℄ OFTEN ℄ ↑MACROBRANCHIS
RESP SYNC V
RHINO
ADENO
INFLUENZA
MC
CHILDHOOD
SPECIFIC GRO AGGLUTININ
NEC ✱ IMMUNE
VARIOUS ETIOLOGY Δ

NL

SCM

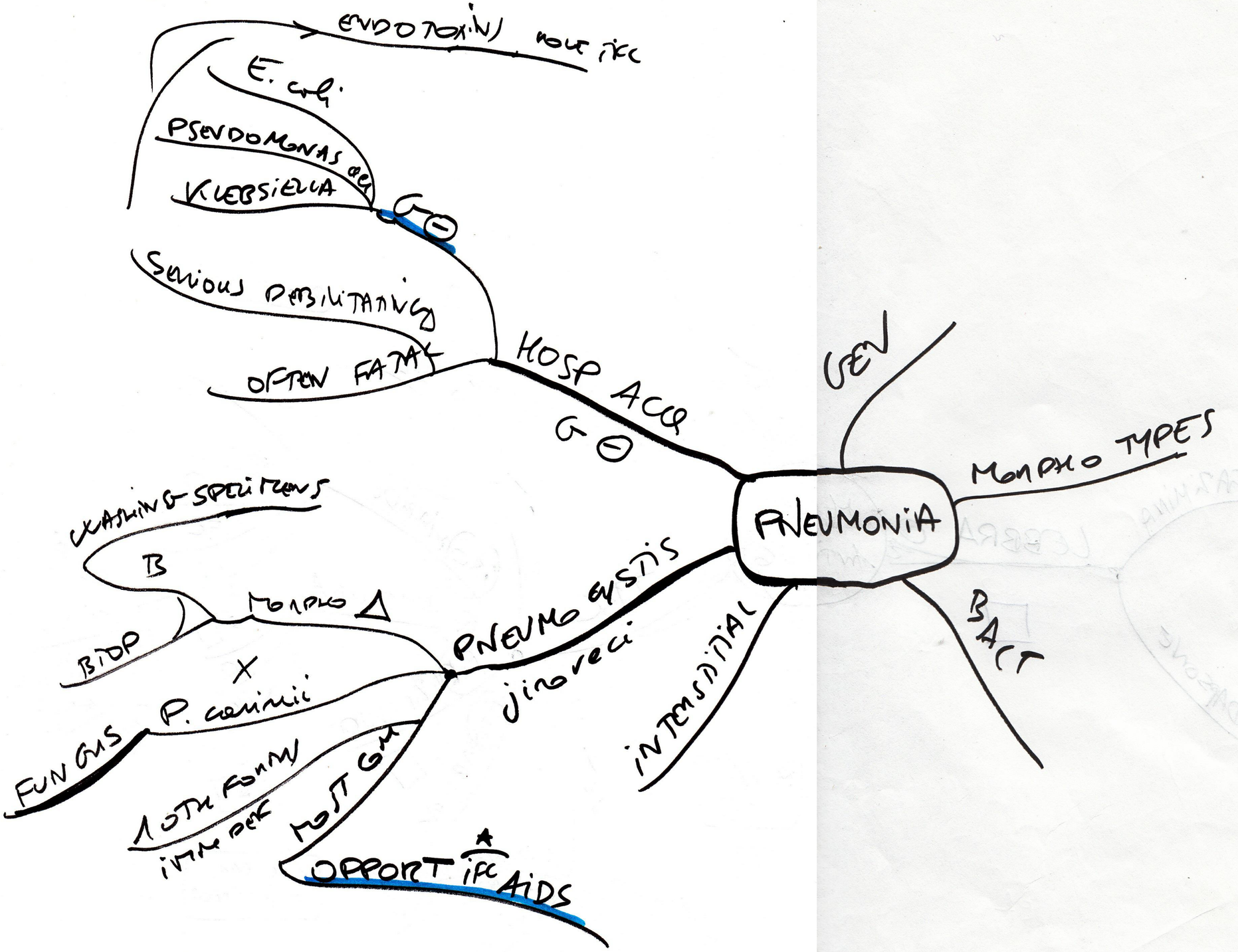
PNEUMONIA
GEN
MORPHO TYPES
BACT
INTERSTITIAL
PNEUMOCYSTIS
jinoveci
HOSP ACQ
G ⊖
ENDOTOXINS
E. coli
PSEUDOMONAS
KLEBSIELLA
G ⊖
SERIOUS DEBILITATING
OFTEN FATAL
WASHING SPECIMENS
B
MORPHO Δ
BIOP
X
P. carinii
FUNGUS
MOST COM
OPPORT IFC AIDS

NL

SCH

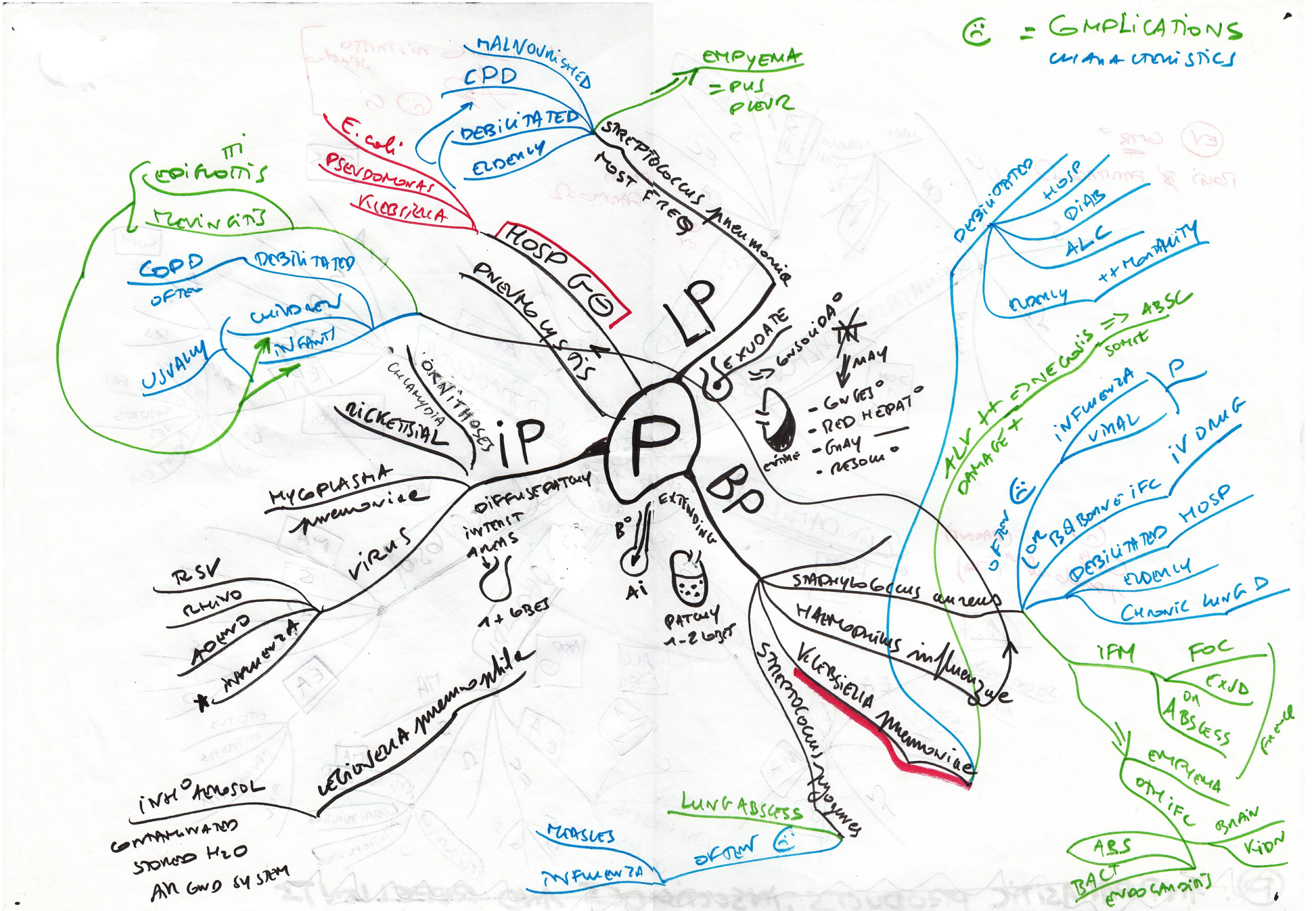

= COMPLICATIONS
CHARACTERISTICS
P
LP
BP
iP
HOSP
PNEUMOLYSTIS
STREPTOCOCCUS pneumoniae
MOST FREQ
MALNOURISHED
CPD
DEBILITATED
ELDERLY
E. coli
PSEUDOMONAS
KLEBSIELLA
EMPYEMA
= PUS
PLEUR
EXUDATE
CONSOLIDA°
MAY
- CONGES°
- RED HEPAT°
- GRAY
- RESOLU°
ENTIRE
DEBILITATED
HOSP
DIAB
ALC
ELDERLY
++ MORTALITY
ALV ++ => NECROSIS => ABSC
SOME
DAMAGE +
INFLUENZA
VIRAL
P
IV DRUG
OFTEN
COR
BOBORNE IFC
DEBILITATED
HOSP
ELDERLY
CHRONIC LUNG D
IFM
FOC
EXUD
OR
ABSCESS
FRENCH
EMPYEMA
OTH IFC
BRAIN
KIDN
ABS
BACT
ENDOCARDITIS
STAPHYLOCOCCUS aureus
HAEMOPHILUS influenzae
KLEBSIELLA pneumoniae
STREPTOCOCCUS pyogenes
LUNG ABSCESS
OFTEN
MEASLES
INFLUENZA
EXTENDING
B°
Ai
PATCHY
1-2 LOBES
DIFFUSE PATCHY
INTERST
AREAS
1+ LOBES
LEGIONELLA pneumophila
INH° AEROSOL
CONTAMINATED
STORED H2O
AIR COND SYSTEM
VIRUS
RSV
RHINO
ADENO
INFLUENZA
MYCOPLASMA pneumoniae
RICKETTSIAL
ORNITHOSES
CHLAMYDIA
EPIGLOTTIS
MENINGITIS
COPD
OFTEN
DEBILITATED
CHILDREN
INFANTS
USUALLY

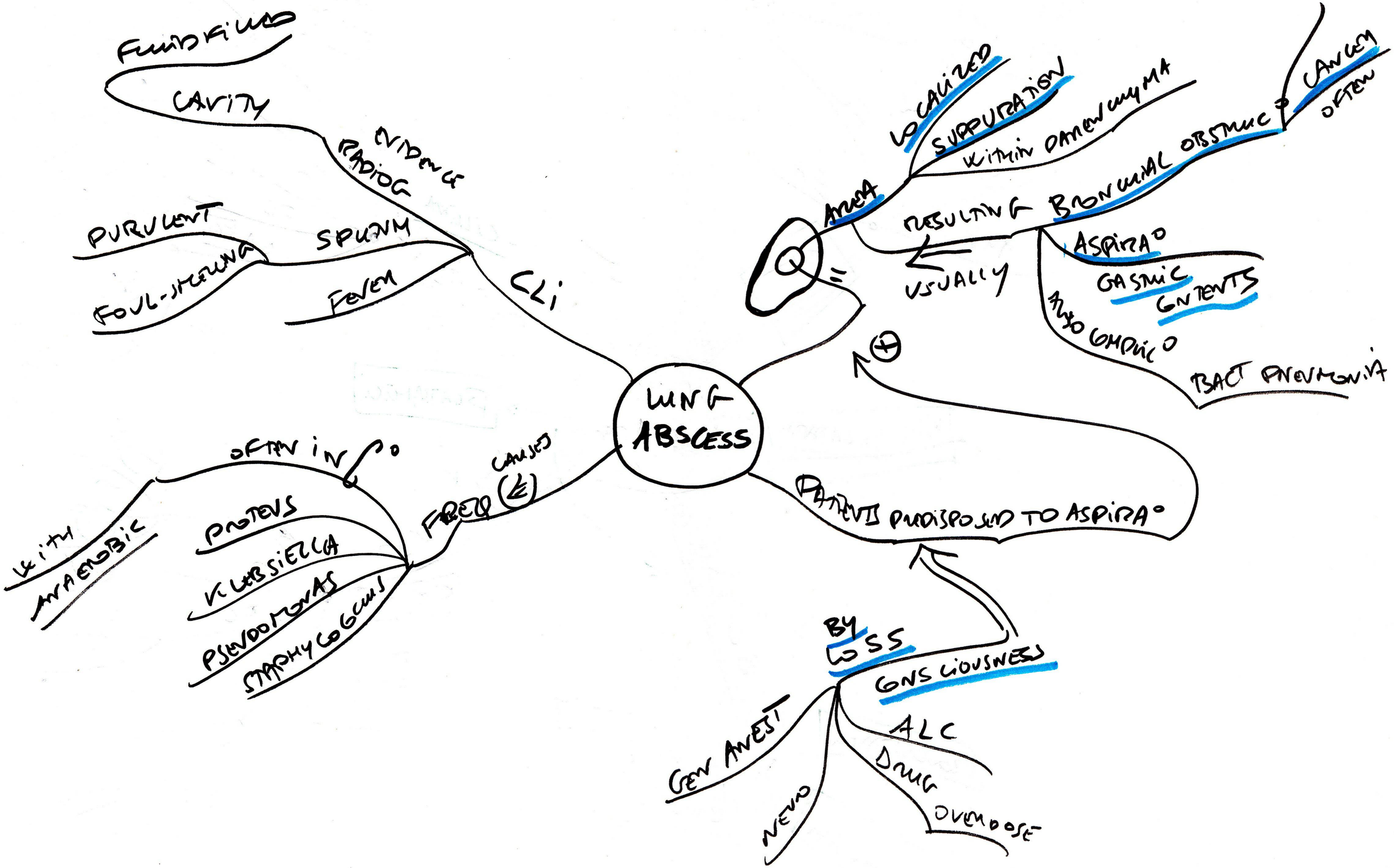
LUNG ABSCESS
CLi
FLUID FILLED
CAVITY
EVIDENCE
RADIOG
SPUTUM
PURULENT
FOUL-SMELLING
FEVER
FREQ (CAUSES)
OFTEN IN
WITH ANAEROBIC
PROTEUS
KLEBSIELLA
PSEUDOMONAS
STAPHYLOCOCCUS
AREA
LOCALIZED
SUPPURATION
WITHIN PARENCHYMA
RESULTING BRONCHIAL OBSTRUC°
CANCER
OFTEN
USUALLY
ASPIRA°
GASTRIC CONTENTS
ALSO COMPLIC°
BACT PNEUMONIA
PATIENTS PREDISPOSED TO ASPIRA°
BY LOSS
CONSCIOUSNESS
GEN ANEST
NEURO
ALC
DRUG
OVERDOSE

TBC

GEN

DISADVANTAGES

IMM MEC in PG

TYPES

PRIMARY

SECONDARY

CLI

NL

SCM

19.6.3

GEN

- ④ CAUSE CAS NEC ? IMMUNO → CYTOKINES
- ⑤ DELAYED HS VS TUBERCULIN SKIN TEST RESULT
- ⊕ DISADVANTAGES
- ② CD4 ⊕ PROLIF° → CYTOKINES
- ATTRACTING L4
- ③ MΦ → KILL SOME
- ALTERNAT MORPHO OR EPITHELIOID
- LANGHANS GIANT ...
- ① MΦ INGESTED
- PROCESS Ag
- MΦ
- TH1
- PSOAS ABS
- PARAVERT ABS
- POTT'S SPINE
- MENINGITIS
- EXTRA
- LYMPH VESSELS
- LYMPHAT
- HEMAT
- MILIARY
- SEED
- DISTAL ORGAN

DISADVANTAGES

- GEN
- PULM
- FORM
- NEW THROUGHOUT LIFE
- INHALD DROPLETS CONTG MYCOBACTERIUM tuberculosis Bacilli
- HS
- RELATIVE IMMUNITY
- PULM
- MOSTLY NEW INFES
- MILK
- COMBINA° PERIPH SUBPLEUR PARENCHYMES
- INVOLVED HILAR LN
- 5.0

TYPES

PRIMARY

- INITIAL IFC
- GHON COMPLEX
- ONLY IN
- GRANUL IFM
- TUBERCLE
- CASEOUS NECROSIS
- OFTEN
- CALCIFIED
- OFTEN
- LANGHANS GIANT
- AST
- OFTEN
- VISIBLE
- USUALLY
- RADIOG
- PROGRESS
- NI EVIDENT

SECONDARY

- ACTIVATION
- SPREAD
- NEW
- PULM
- EXTRAPULM
- SITE
- CAVITATION
- CASEATION
- CANAL IMMUNITY
- PLEUR EFFUS
- HEMOPTYSIS
- OFTEN BLOODY
- PROG DISABILITY
- FEVER
- SCARRING / CALCIFICA°
- INTO BRONCHI
- CAS MAY LIQUEFY & BE EXPELLED
- CAVITARY LES
- LES CONSOLID + TUBERCLE FORMA°
- CALCIFIED
- HILAR LN
- GM
- LOC ED LES
- USUALLY APICAL
- POSTERIOR SEGM UPPER LOB
- PATHO FINDINGS
- SPREAD
- LYMPHAT
- HEMAT
- LANGH GIANT CELLS

18.6.4

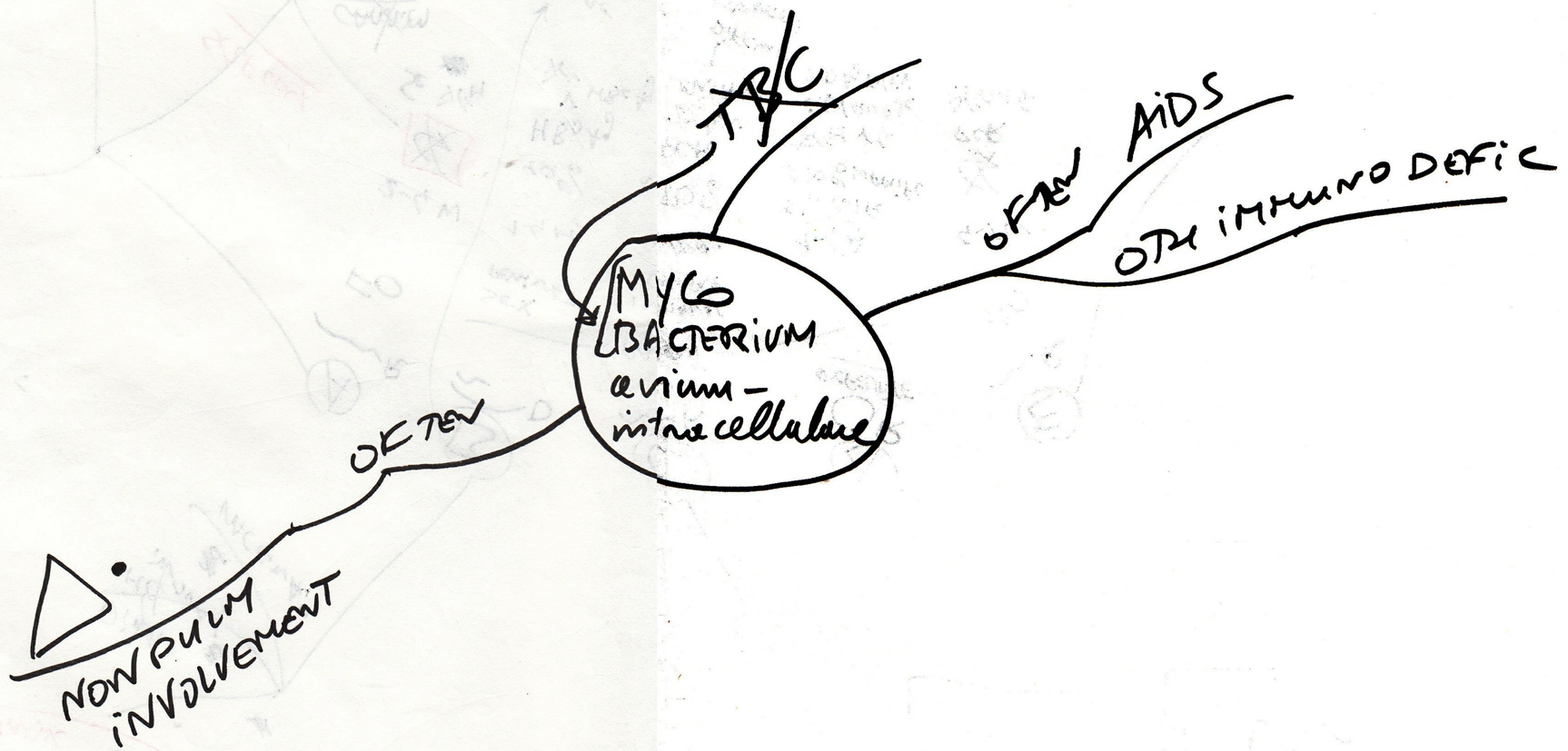
TBC
OTHER AIDS
OTH IMMUNO DEFIC
MYCOBACTERIUM avium-intracellulare
OTHER
NON PULM INVOLVEMENT

NL

SCM

- ACTINOMYCOSIS — G⊕ ANAER FILAMENTOUS
  - ABS 1 SIN TRACT FORMA°
  - EXUDATE = CLAR SULFUR GRANULES YELLOW LUMPS ORGANISM
- NOCARDIOSIS — WEAKLY ACID-FAST
  - OPP
  - → B+ MENINGES (DISS MAN)
- CANDIDIASIS — albicans
  - IMM COMP INVASIVE FORM → B⊕ BONNE DISS
  - ODG ABS VEGET ENDOCARDIA
- CRYPTOCOCCOSIS — neoformans
  - ⊙ LUNG USUALLY
  - MENINGITIS
  - ⊙ ENCAPSULATED INDIA INK
- ASPERGILLOSIS — INVAS FORM
  - VESSELS → HEMAT DIS
- HISTOPLASMOSIS — capsulatum
  - ⊙ ≃ TBC I 1 II FORMS
  - ⇒ MULTIPLE PULM LES + LATE CALCIFICA°
  - DISS ∞ FORM "MULTISYSTEM
  - Mφ — FILLED FUNGAL YEAST FORMS
  - INFILTRATED Mφ
- COCCIDIOIDOMYCOSIS — immitis
  - I 1 DIS ∞ FORMS
  - FUNGAL SPHERULES
  - ⊃ING ENDOSPORES
  - IN GRANULOMAS

FUNGI & FUNGUS-LIKE BACTERIA

- USUALLY
  - INHALA°
  - INOCULA°
  - SKIN
- MOST INSTANCES
  - IFM ≃ TBC

BRONCHIAL OBSTRUC°
EXTERNAL COMPRE° L PARENC
TUMORS *
PLEURAL ACCUMULA° FLUID *
= ALV COLLAPSE
ACQUIRED
ATELECTASIS
NEONATORUM
MISC
PULM ALV PROTEINOSIS
III
BRONCHOALV LAVAGE
UNCOMMON
UNKNOWN ETIO
SOMETIMES APPEARS TO BE SURFACTANT
ACCUMULA° AMORPHOUS
PAS
+ VE ALV SPACES
II
COLLAPSE OF PREVIOUSLY AERATED BRONCHI
I
FAILURE INITIAL AERA° LUNGS
= FAILURE
ALV SPACES TO EXPAND AT BIRTH
ALV REMAIN COLLAPSED
RESP° NEVER FULLY ESTABLISHED
INTRAUTERINE FETAL ANOXIA PREMATURITY
SCH
NL

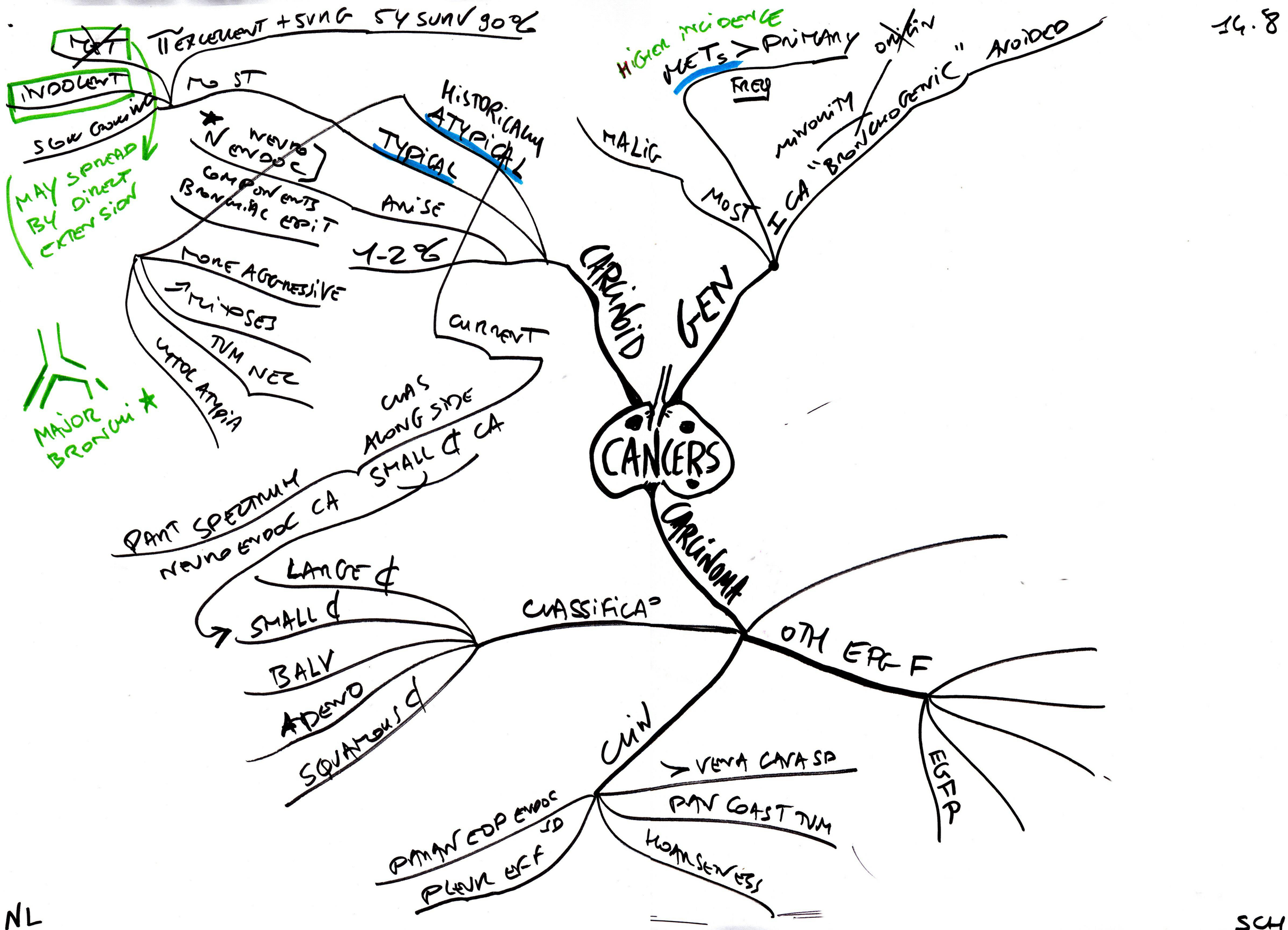
CANCERS
CARCINOID
GEN
CARCINOMA
OTH EPG F
EGFP
CLASSIFICA°
CLIN
MAJOR BRONCHI *
MAY SPREAD BY DIRECT EXTENSION
INDOLENT
SLOW GROWING
MOST
TTEXCELLENT + SVNG 5Y SURV 90%
HISTORICALLY ATYPICAL
TYPICAL
ANISE
1-2%
NEURO ENDOC
COMPONENTS BRONCHIAL EPIT
MORE AGGRESSIVE
MIXSES
TUM NEC
CYTOL ATYPIA
CURRENT
CLAS ALONG SIDE
SMALL ¢ CA
PART SPECTRUM
NEURO ENDOC CA
LARGE ¢
SMALL ¢
BALV
ADENO
SQUAMOUS ¢
HIGHER INCIDENCE
METs > PRIMARY
FREQ
MALIG
MOST
MINORITY
ICA "BRONCHOGENIC"
AVOIDED
VENA CAVA SD
PAN COAST TUM
HOARSENESS
PARAN EOP ENDOC SD
PLEUR EFF

NL

SCH

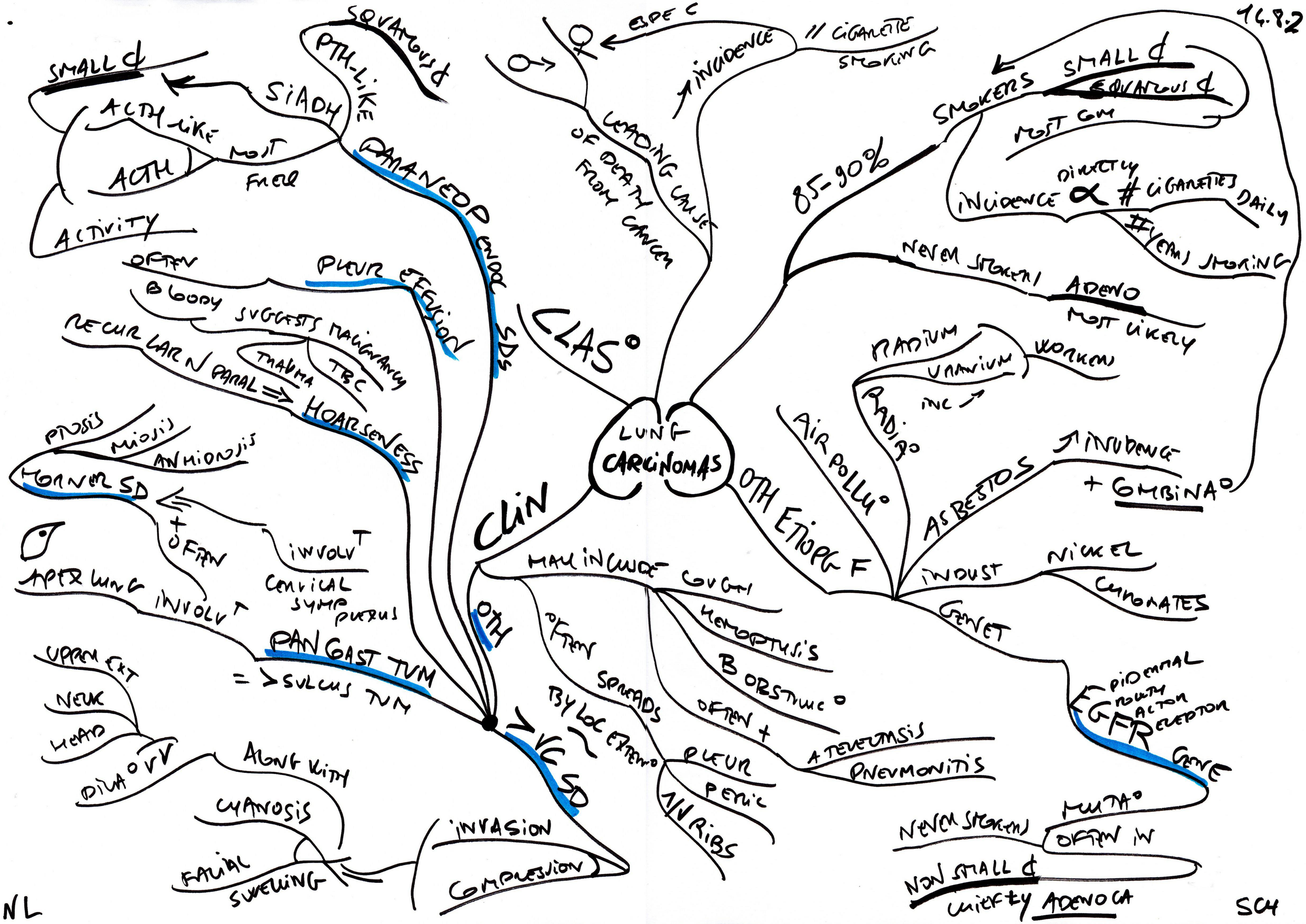
14.8.2
LUNG CARCINOMAS
CLAS°
CLIN
OTH
VC SD
PARANEOP ENDOC SDs
PTH-LIKE
SQUAMOUS ¢
SIADH
SMALL ¢
ACTH-LIKE
ACTH
MOST FREQ
ACTIVITY
OFTEN
BLOODY
PLEUR EFFUSION
SUGGESTS MALIGNANCY
TRAUMA
TBC
RECUR LARN PARAL ⇒ HOARSENESS
PTOSIS
MIOSIS
ANHIDROSIS
HORNER SD
+ OFTEN
INVOLV^T
CERVICAL SYMP PLEXUS
APEX LUNG INVOLV^T
PANCOAST TUM
= > SULCUS TUM
UPPER EXT
NECK
HEAD
DILA° VV
ALONG WITH
CYANOSIS
FACIAL SWELLING
INVASION
COMPRESSION
ESPE C
LEADING CAUSE OF DEATH FROM CANCER
INCIDENCE
// CIGARETTE SMOKING
85-90%
SMOKERS
SMALL ¢
SQUAMOUS ¢
MOST COM
INCIDENCE ∝ DIRECTLY # CIGARETTES DAILY
YEARS SMOKING
NEVER SMOKERS
ADENO
MOST LIKELY
RADIUM
URANIUM
WORKERS
INC ↗
RADIA°
AIR POLLU°
OTH ETIOPG F
ASBESTOS
INCIDENCE
+ COMBINA°
INDUST
NICKEL
CHROMATES
GENET
EGFR
PIDERMAL
MOUTH
ACTOR
ELEPTOR
GENE
MUTA°
NEVER SMOKERS
OFTEN IN
NON SMALL ¢
CHIEFLY ADENOCA
MALI INCLUDE
COUGH
HEMOPTYSIS
B OBSTRUC°
OFTEN +
ATELECTASIS
PNEUMONITIS
OFTEN
SPREADS
BY LOC EXTENS
PLEUR
PERIC
1/V RIBS
NL
SCH

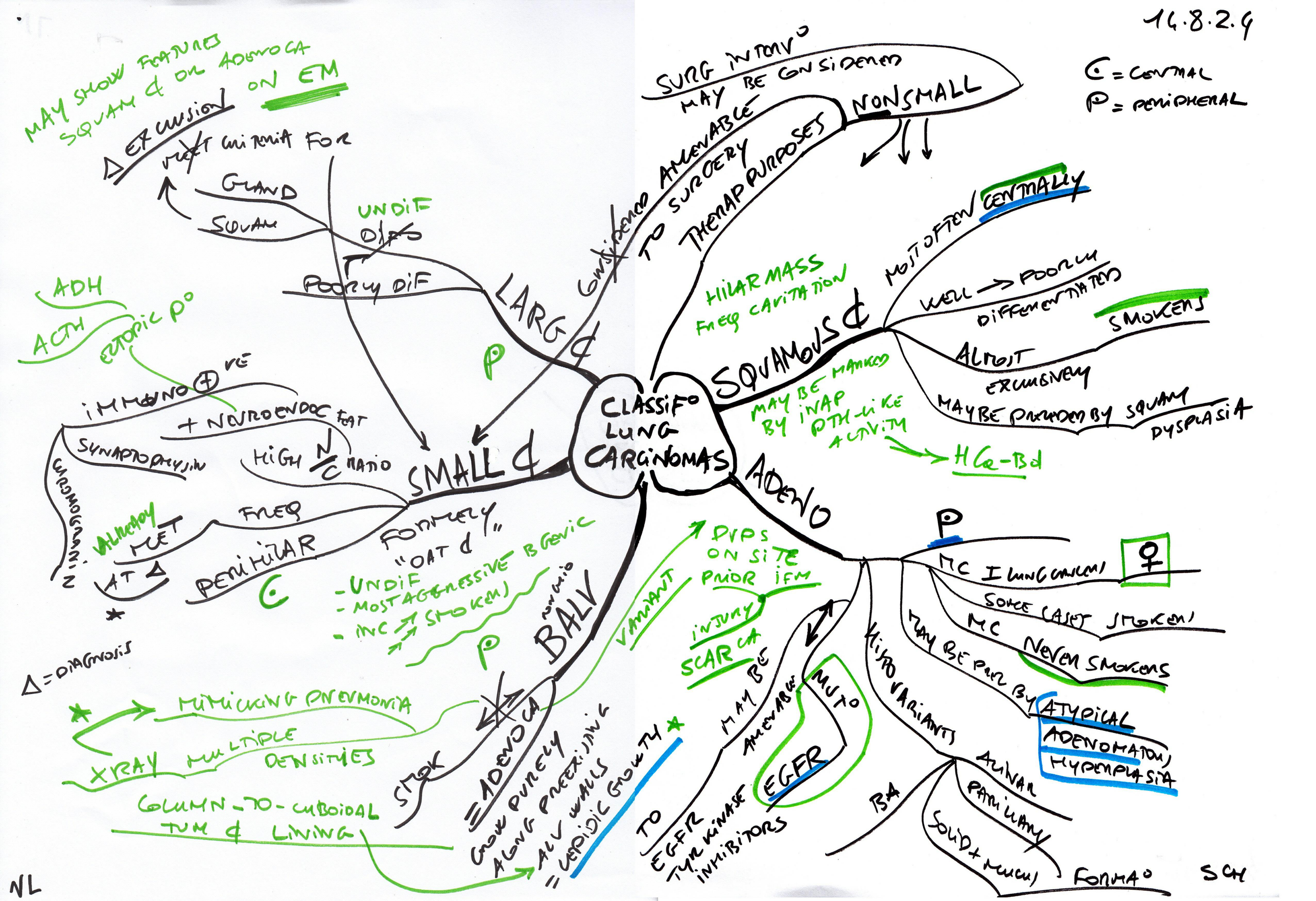
14.8.2.4
C = CENTRAL
P = PERIPHERAL
CLASSIF° LUNG CARCINOMAS
SURG INTERV° MAY BE CONSIDERED
NONSMALL
CONSIDERED AMENABLE TO SURGERY
THERAP PURPOSES
LARG ¢
P
SMALL ¢
SQUAMOUS ¢
MOST OFTEN CENTRALLY
WELL → POORLY DIFFERENTIATED
SMOKERS
ALMOST EXCLUSIVELY
MAY BE PRECEDED BY SQUAM DYSPLASIA
HILAR MASS
FREQ CAVITATION
MAY BE MARKED BY INAP PTH-LIKE ACTIVITY
HCa-Bd
ADENO
P
MC I LUNG CANCERS
♀
SOME CASES SMOKERS
MC NEVER SMOKERS
MAY BE PREC BY ATYPICAL ADENOMATOUS HYPERPLASIA
HISTO VARIANTS
ALVAR
PARILLARY
SOLID + MUCUS
FORMA°
BA
MAY BE AMENABLE TO EGFR TYR KINASE INHIBITORS
MUT°
EGFR
DVPS ON SITE PRIOR IFM
INJURY
SCAR CA
VARIANT
BALV
P
NON GRIO
SMOK
≡ ADENOCA
GROW PURELY ALONG PREEXISTING ALV WALLS
= LEPIDIC GROWTH *
FORMELY "OAT ¢"
- UNDIF
- MOST AGGRESSIVE B GENIC
- INC SMOKERS
PERIHILAR
C
FREQ
MET
ALREADY
AT Δ
*
IMMUNO ⊕ VE
+ NEUROENDOC FEAT
SYNAPTOPHYSIN
HIGH N/C RATIO
CHROMOGRANIN
ADH
ACTH
ECTOPIC P°
MAY SHOW FEATURES SQUAM ¢ OR ADENOCA ON EM
Δ EXCLUSION
MEET CRITERIA FOR
GLAND
SQUAM
UNDIF
DIFS
POORLY DIF
Δ = DIAGNOSIS
* MIMICKING PNEUMONIA
XRAY MULTIPLE DENSITIES
COLUMN-TO-CUBOIDAL TUM ¢ LINING
NL
SCH