# NEOP. & PROLIF. HEMATOP. & LYMPHOID

## LYMPHOID NEOP

- PREC T
- MATURE (P) T
- T GRANULAR LYMPHOCYTIC LE
- ADULT T LY/LE
  - HTLV1+
- ENTEROPAT T LY
- PREC B MAT
  - LE
  - LYMPHOPLASMACYTIC LY
- LYMPHOMAS LE/LY
- FOLLICULAR
- MANTLE ¢
- ZONE B MALT TYPE
- EXTRANOD MARG
- DIFFUSE LARGE B
  - CONG T-ALL
  - 1 MED MASS
  - THYMIC LY
  - PROGRESS TO T-ALL
- PREC T LBLASTIC
  - LY/LE = PREC T ACUTE LBLASTIC LE
- BURKITT (B)
  - ENDEM AFR
  - SPORT WEST
  - IMMUNO DEF
  - "SMALL NON CLEAVED"
  - R TO B-ALL
  - CYTOG ✓
  - t(8;14) c-myc
  - t(2;5)
  - ALK
  - ⊕ VE ALK P
- ANAP LARGE ¢
- ANGIOIMMBLASTT
- CUTT T
  - MYCOSIS FUNGOIDES
    - CONGENIT
    - NAC
    - PAUTIMA
    - MABS
  - SÉZARY SD
- SMALL LCTIC
  - CLL
  - WHO CLAS
  - (B) INDOL
  - (B) INDOLENT OLDER COURSE
  - ANGIOLAPTO GROOVED ¢
  - NOD
  - HISTOM OF RCH
  - CLOSER TO CLL
  - CYTOGENET ✓ ATYPIC
  - bcl-2
  - MAL GRANT LYMPH NODES NUM INVOLV
- HODGKIN LYMPHOMA
  - EFFACEMENT LN ARCHI
  - WIDESPREAD LN INVOLV
  - PROG BETTER PREDICTED
  - DIAG EVAL°
  - ANN ARBOR BASIS MOST
  - PROG GOOD
  - CLI STAGING
  - CLAS°
  - NODULAR LY PREDOM
  - "POPCORN" ¢
  - LY DEPLE°
  - LY RICH
  - MIXED ¢Y = MCL
  - NODULAR SCLEROSIS = NS
  - WHO CLASSICAL
    - ⊕ VE CD15 CD30
    - ⊖ VE CD45
    - "CHL
  - MAL GRANT
  - GEN
  - YOUNG
  - ADULTS ♂

## PLASMA ¢

- MGUS
  - MONOCLONAL GAMMOPAT NOT SIGNIFICANT
  - BENIGN
  - MP
- WALDENSTROM MACROGLOBULIN
  - COMPLIC
  - CLI
  - ON BD-ING
  - HYPERVISCOSITY SD
  - RETVASC DICA°
  - SLOWLY PROG COURSE
  - ♂ > 50Y
  - EMERGENCY PLASMAPHERESIS
  - DEF OUAR
  - LY MPHOPLASMACYTIC LYMPHOMA
  - MALIGNANT TUMOR
  - Se ↗ IM
  - PLASMACYTOID LY
  - BENCE JONES P-J
  - Ø BONE LES
- PLASMACYTOMA
- OTH CLI

## B NEOP

## T NEOP

## HODGKIN LYMPHOMA

## GEN

- MULTIPLE MYELOMA
- LYMPHOID NEOPLASMES
- BONE LES & P & N
  - ANEMIA
    - ↗ SUSC TO IFC
    - H Co-Bd
  - RENAL INSUF + N-Bd
    - ⇐ MEGA KIDNEY
  - AMYLOID
  - POOR LONG FORMATO
  - HYPERGLOB
  - BENCE JONES P
  - LYTIC LES PUNCHED OUT OSTEOP
  - SEVERE PAIN
  - MP

## PROLIF LYMPHOID NEOP

- IFC MONONUC
  - EBV
    - YOUNG ADULTS
    - ATYPICAL LY
    - ↗ = HETEROPHIL
    - ♀ = SCHNEIDER 2013
  - ANTI
  - SPLEEN SUSC TO TRAUMA INJ
- GEN
- ESSENT THROMBOCYTHEMIA
  - = AGNOGENIC MYELOID METAPLASIA
  - (EXTENSIVE EXTRAMED HEMATOP)
  - THROMBOCYTOSIS
  - MEGAKARYOCYTOPOIS
  - BD-ING ↑ IS
  - PBE TEARDROP
  - ENYT
  - ANEMIA
  - SPLENOMEG
  - POSTULATED PGF
  - CLI
- CIDIOP MYELOFIB
  - ♂
- PV POLYCYTHEMIA VERA
  - CLI
  - OTH
  - △
  - THROMB V HEMOR
  - EPO
  - II
  - CHORIA
  - INAP POEPO
  - APKO
  - ↑ TUM
  - ENDOC
  - PHEOC
  - CUSHINGSD
- COM CHAR

## MYELOPROLIF

## LEUKEMIA

- ACUTE
  - GEN
  - ALL LYMPHOBLASTIC
    - RESPONSIVE TO THERAPY
    - LYMPHOBLASTS
    - CHILD NEW
    - PHILAD CROM PH1
    - CHILDREN BLASTS
  - AML MYELOID BLASTIC
    - ADULTS
    - MYELOBLASTS
    - LYMPHOID ¢
- CHRONIC
  - CLL LYMPHOCYTIC
    - GEN
    - NEOP
    - CHAR
    - SMUDGE ¢
    - COMP
    - WARM AG AUTOIMMUNE ANEM
    - IGAMMAG-BD
    - CLI
    - LYMPHADENOPATHY HSMEG
  - HAIRY ¢
    - FILAM PROJECT
    - ⊕ VE STAIN
    - TRAP
    - SPLENOMEG ↑ PANCYTOP
    - DRAIN ⇒ TO SEXUAL THEM A CONTS
    - BM "DRY TAP" ⇐ FIB
  - CML MYELOGENOUS
    - ↑ BODY THROMBOSIS
    - ↑ BODY CIRC GRAN ¢
    - ↑ PLAT
    - SPLENOMEG
    - PRIEN
    - MOLEC CHANGES
    - BCR-ABL
    - CHAR
    - GRANULOCYTOPOIEC ¢
    - MAJ BRAKPOINT (M-bcr) PH CHR
    - ↑ LEUKOCYTOSIS
    - MID TO LATE MYELOID
    - ↓ LAP
    - PROM SPLENOMEG
  - CLI

NICOLASLEVY.NET

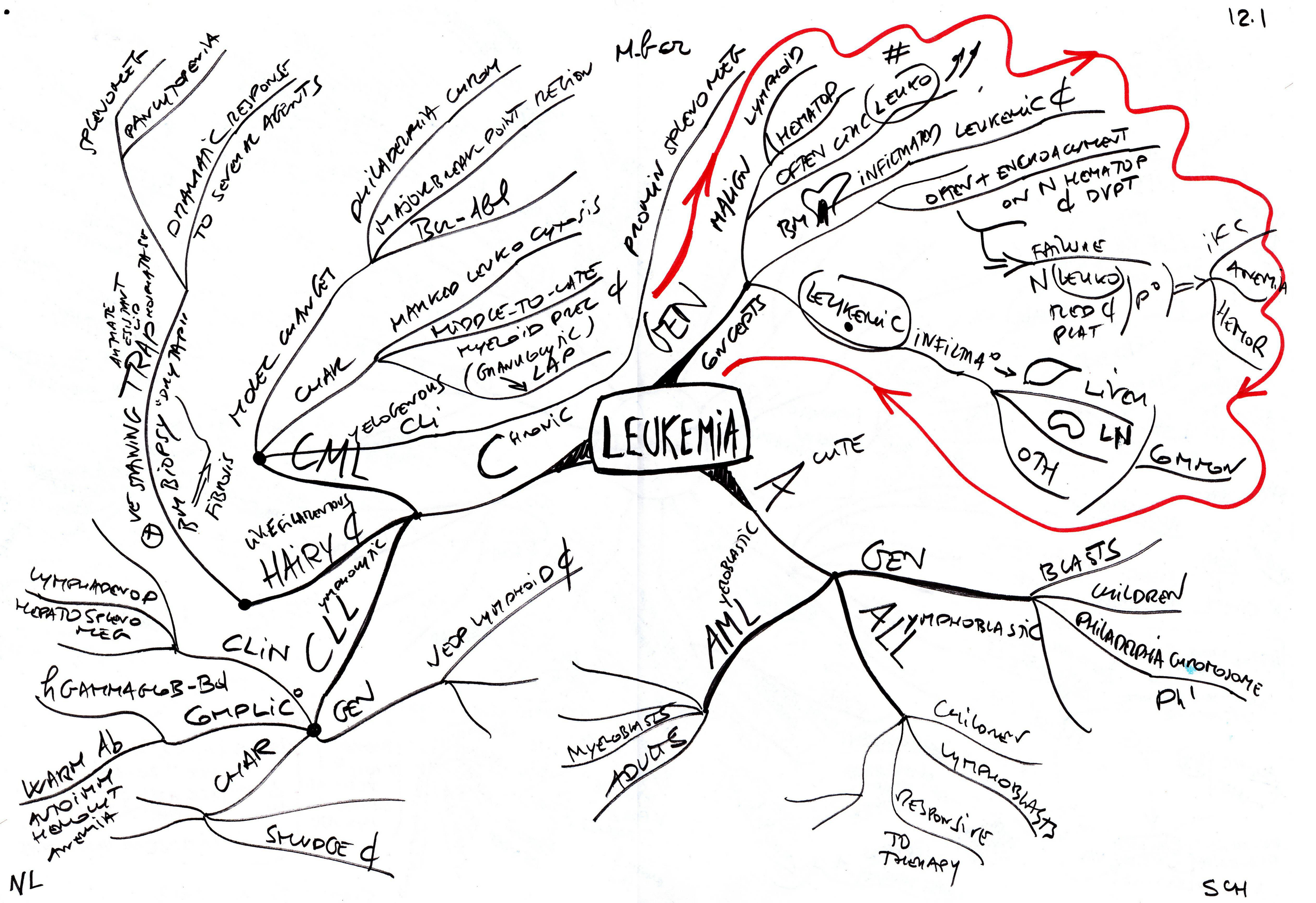
LEUKEMIA
CML
CHRONIC
ACUTE
CLIN
GEN
MOLEC CHANGES
CHAR
MAJOR BREAK POINT REGION
Bcr-Abl
MARKED LEUKOCYTOSIS
MIDDLE-TO-LATE MYELOID PREC (GRANULOCYTIC)
LAP
YELOGENOUS CLL
SPLENOMEGALY
PANCYTOPENIA
DYNAMIC RESPONSE TO SEVERAL AGENTS
ANTIGAE ETIOLOGY
TRAP
BM BIOPSY "DRY TAP"
FIBROSIS
VERY SPARING
UNEXPLANATORY
HAIRY CELL
LYMPHOMATIC
LYMPHADENOP
HEPATOSPLENOMEG
CLIN
CLL
hGAMMAGLOB-BY
COMPLIC°
GEN
CHAR
WARM Ab
AUTOIMM HEMOLYT ANEMIA
SPLENOMEGALY
PROMIN SPLENOMEGALY
MALIGN LYMPHOID
HEMATOP
OFTEN CLINC (LEUKO)
#
INFILTRATIVE LEUKEMIC
BM
OFTEN + ENCROACHMENT ON N HEMATOP & DYPT
FAILURE
N (LEUKO) RBC & PLAT
PC
IFC
ANEMIA
HEMOR
LEUKEMIC INFILTRATION
LIVER
LN
OTH
COMMON
CONCEPTS
GEN
VERY LYMPHOID
AML
MYELOBLASTIC
MYELOBLASTS
ADULTS
GEN
ALL
LYMPHOBLASTIC
BLASTS
CHILDREN
PHILADELPHIA CHROMOSOME
Ph'
CHILDREN
LYMPHOBLASTS
RESPONSIVE TO THERAPY
NL
SCH

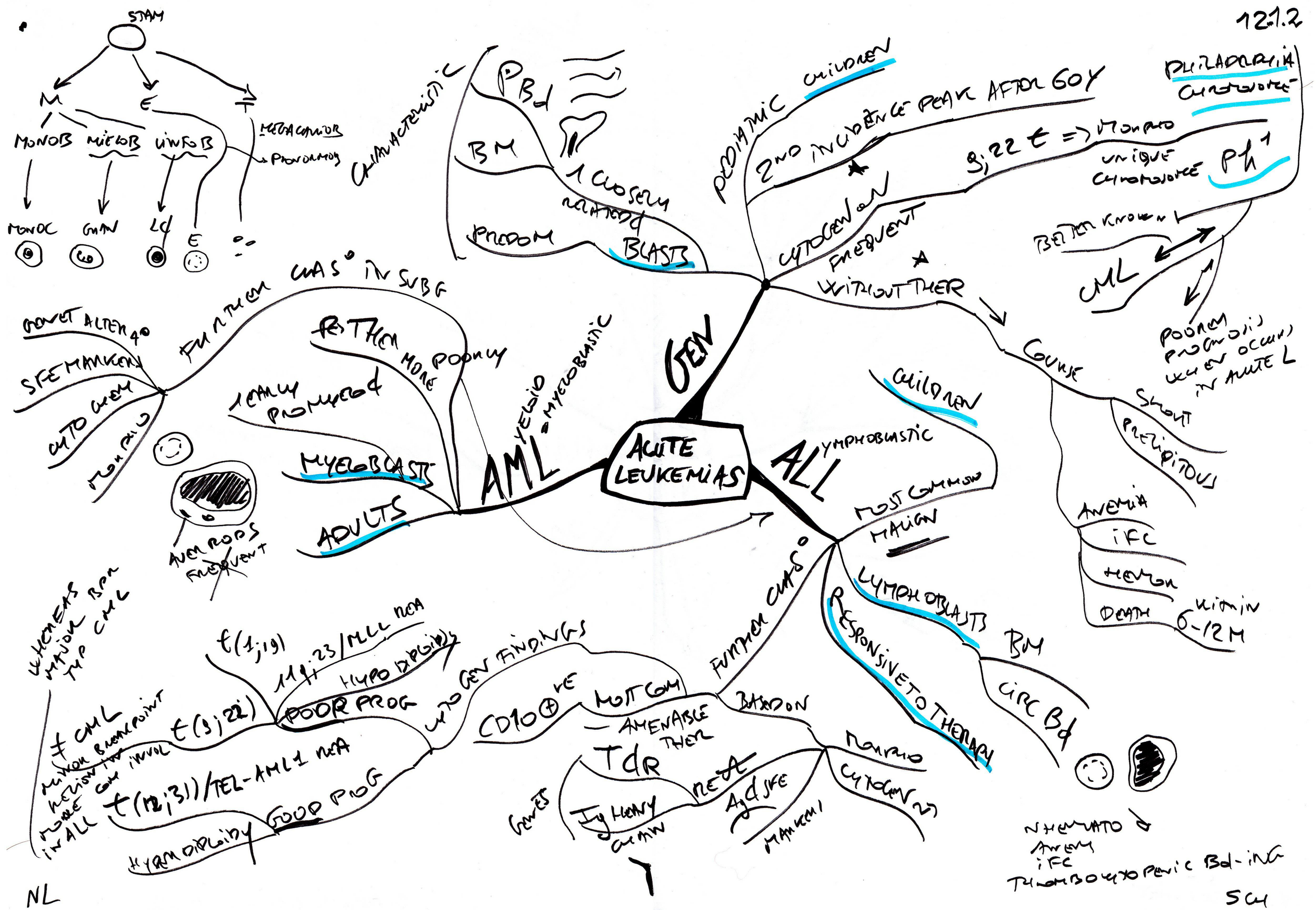
STAM
M
E
T
MONOB
MIELOB
LINFOB
MEGACARIOB
PROMONOC
MONOC
GRAN
LC
E
CHARACTERISTIC
PBd
BM
1 CLOSELY RELATED
PROEOM
BLASTS
PEDIATRIC CHILDREN
2ND INCIDENCE PEAK AFTER 60Y
PHILADELPHIA CHROMOSOME
9;22 t => MONOCLO
UNIQUE CHROMOSOME
Ph1
CYTOGENETICALLY FREQUENT
WITHOUT THER
BETTER KNOWN
CML
POORLY PROMOTING LEUKEMIA OCCURS IN ACUTE L
COURSE
SHORT
PRECIPITOUS
ANEMIA
IFC
HEMOR
DEATH
WITHIN 6-12M
GENERAL
ACUTE LEUKEMIAS
AML
YELOID
MYELOBLASTIC
FURTHER CHAS IN SUBG
RATHER MORE POORLY
LEARLY PROMOTED
MYELOBLASTS
ADULTS
CONVET ALTER 40
SPECIMANCEMIA
CITO CHEM
MONOCLO
AUER RODS FREQUENT
ALL
LYMPHOBLASTIC
CHILDREN
MOST COMMON MALIGN
LYMPHOBLASTS
RESPONSIVE TO THERAPY
BM
CIRC Bd
FURTHER CHAS
BASEDON
NORMO
CYTOGEN 23
NEA
Ag d JKE
MANCHI
GENES
Ig HEAVY CHAIN
TdR
MOST COM
— AMENABLE THER
CD10 ⊕ VE
WITH GEN FINDINGS
POOR PROG
t(1;19)
11q23/MLL REA
HYPO DIPLOIDY
t(9;22)
t(12;21)/TEL-AML1 REA
HYPERDIPLOIDY
GOOD PROG
WHENEVER MAJOR BCR TYP CML
≠ CML
NUMBER BREAKPOINT
REGION CAN INVOL
MORE CAN INVOL
IN ALL
NEUTROPENIA
ANEMIA
IFC
THROMBOCYTOPENIC Bd-ING
NL
SCH

12.1.3

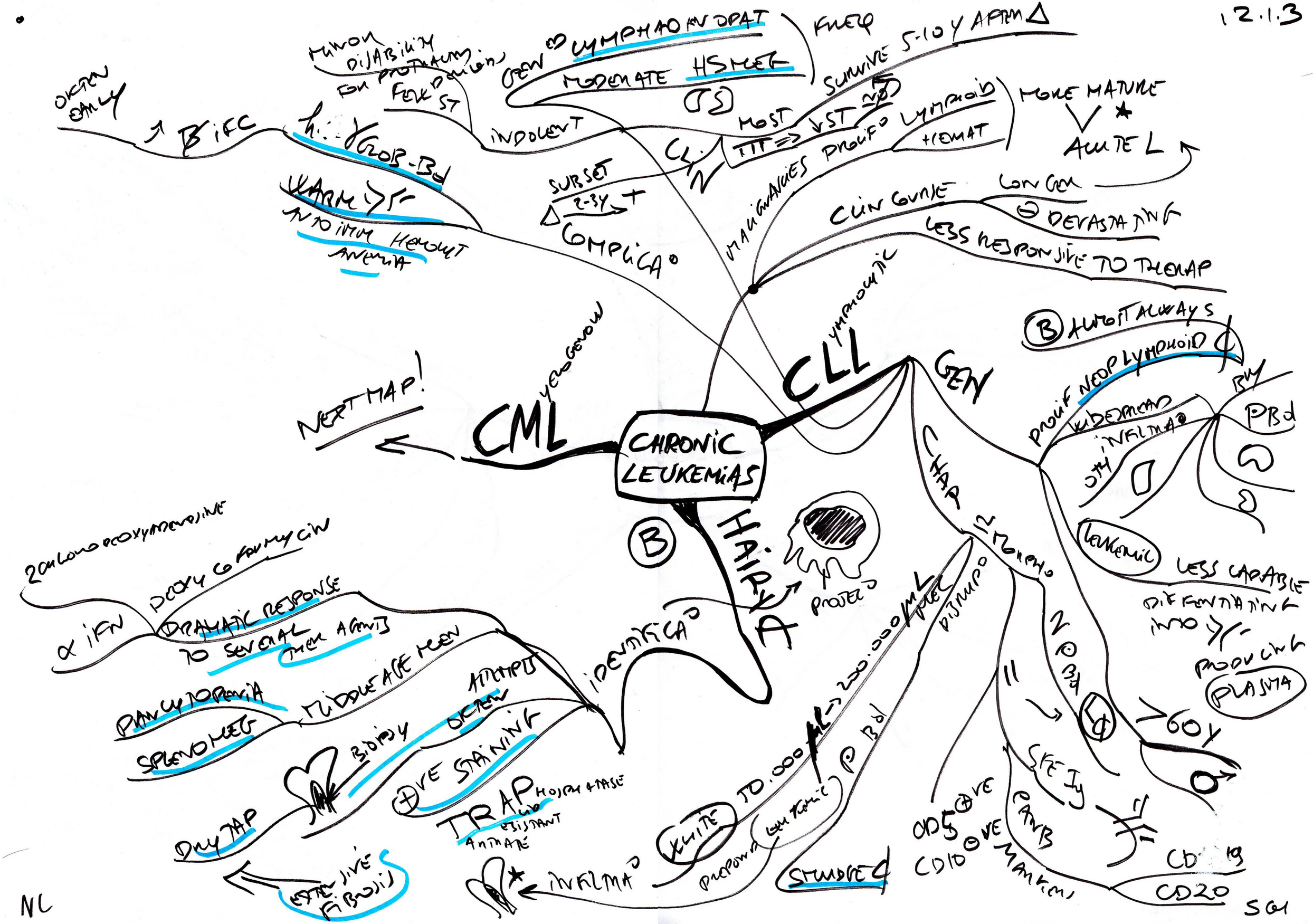
CHRONIC LEUKEMIAS
CML
yeloGenow
NEXT MAP!
CLL
lymphocytic
GEN
CHAR
≈ normo
II
2 ⊕ B
⊕
>60 y
♂
SEE Ig
CD5 ⊕ve
CD10 ⊖ve
FMB
MANTLE
CD19
CD20
SGI
leukemic
LESS CAPABLE
DIFFERENTIATING
INTO Ig-
PRODUCING
PLASMA
B AUTO IT ALWAYS
PROLIF NEOP LYMPHOID
KUBERNAND
INFILTRA
OTH
BM
PBd
FREQ
GEN ⊖ LYMPHADENOPAT
MODERATE HSMEG
CS
SURVIVE 5-10 Y AFTER Δ
MORE MATURE
ACUTE L
MOST
TTT ⇒ ↓ST
LYMPHOID
HEMAT
MALIGNANCIES PROLIF
CLIN COURSE
LONG GEN
⊖ DEVASTATING
LESS RESPONSIVE TO THERAP
SUBSET
2-3Y
COMPLICA
CL
N
INDOLENT
MINOR DISABILITY
FOR PROTRACTED
FEW PATIENTS
ST
OFTEN EARLY
↑ B iFC
GROB-Bd
WARM ↓r
NO IMM HEMOLYT
ANEMIA
B
HAIRY A
PROTEC
IDENTICA
ATTEMPTS
OFTEN
⊕ve STAINING
TRAP
HOSPH ATASE
ENZYME
RESISTANT
ANTIBODY
BIOPSY
DRY TAP
MIDDLE AGE MEN
PANCYTOPENIA
SPLENOMEG
DRAMATIC RESPONSE
TO SEVERAL CHEM AGENTS
α IFN
DOXY
CYCLOPHOSPHAMIDE
ZONULO
EXTENSIVE
FIBROSIS
INFILTRA
XENITE
PROPORTIONAL
LEUKEMIC
10.000 μl → 200.000 μl
PLATELET
DISTURB
P Bd
STUDIED
NL

12.1.3.3

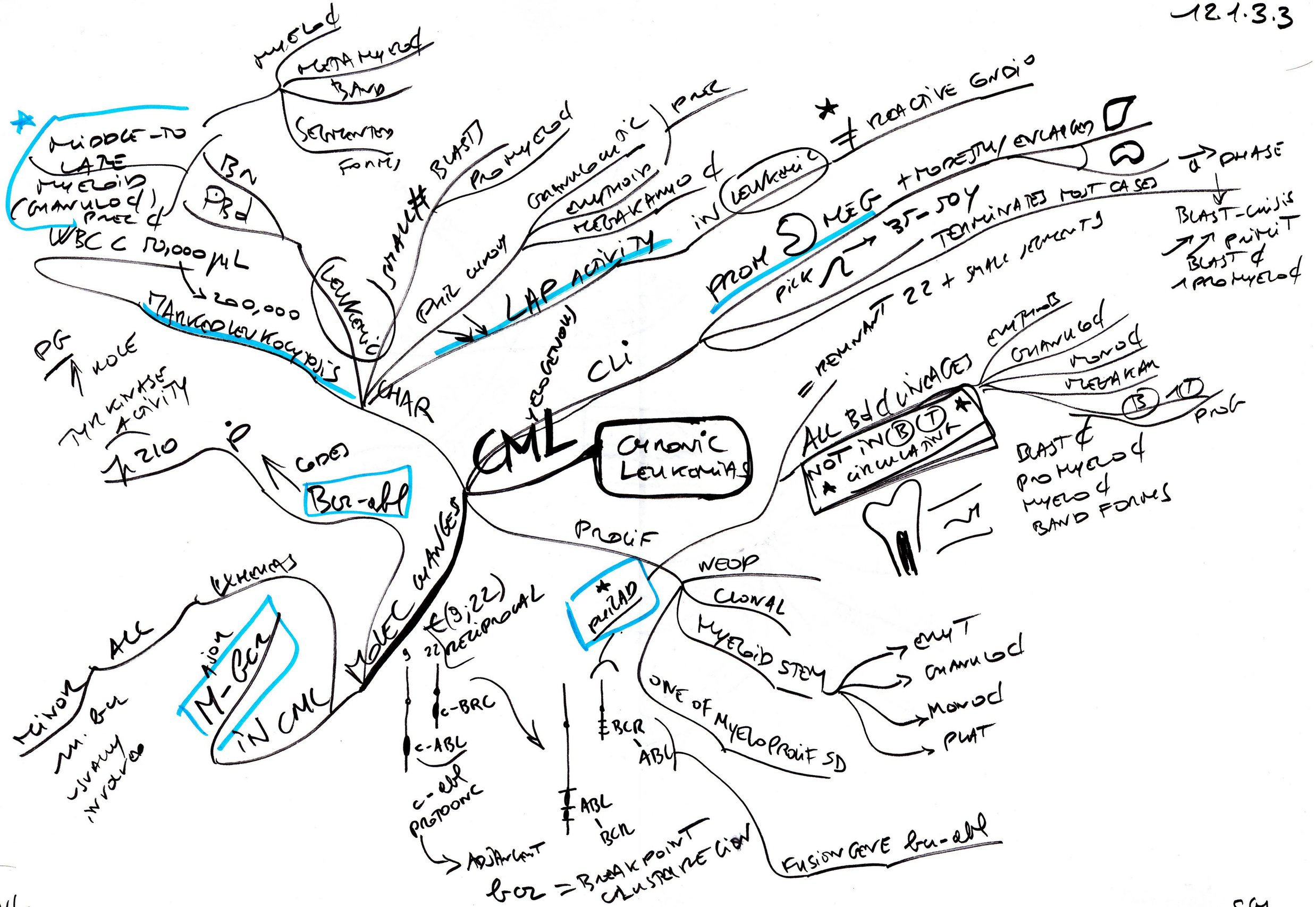
CML
Chronic Leukemias
Middle-to Late Myeloid (Granulocytic) Prec
WBC > 50,000 µL
200,000
Anuclo Leukocytosis
Myelocyte
Metamyelocyte
Band
Segmented Forms
Blast
Promyelocyte
Granulocytic Emphasis
Megakaryocyte
Prec
Leukemic
Char
Blast #
Phil chromosome
LAP activity
in Leukemic
Proliferative Index
Prom
Meg + Morphology/Enlargement
Pick
35-50%
Terminates most cases
Phase
Blast-crisis
Primit Blast & Promyelocyte
Remnant 22 + small segments
Cli
Genetics
Molec changes
Philad
Weop
Clonal
Myeloid Stem
Emyt
Granulocyte
Monocyte
Plat
One of Myeloproliferative
Fusion Gene bcr-abl
Blast & Promyelocyte
Myelocyte
Band Forms
All Bcl Lineages
Emphasis
Granulocyte
Monocyte
Megakaryocyte
Not in B T
Circulating
B T
Prog
Tyrosine Activity
210
P
Codes
Bcr-abl
Minor ALL
Exhemias
Minor Bcr involved
Major M-Bcr in CML
t(9;22) Reciprocal
9 22
c-BRC
c-ABL
c-abl protooncogene
Adjacent
BCR
ABL
ABL
BCR
bcr = Breakpoint Cluster Region
PG
Node
Tyrosine Activity
NL
SCY

12.2

# MYELOPROLIF

## CML

- CLONAL PROLIF MYELOID STEM ¢
- PV
- CIM
- ET
- RUBRA
- MOST IF NOT ALL
- SIGNIFICANT # *
- MUTA° IN GENE FOR JANUS2 SIGNALING P
- 1 ARE JAK2V617F ⊕ VE

## COM CMAR

- MIDDLE AGE ADULTS
- PROLIF ↑ (RONG) OR BASOPHIL
- MYELOID SERIES
- ↑ PBd
- ↑ SE URIC ACID
- PROMIN ↓ MET
- ⊙ RC NUCLEATED
- GRANULOC
- MEGAKAR
- ERYT

## CLI

- ++ ERYTHROMYOSIS
- → MODERATE CIRC (GRAN) IMPT
- ↓ MET
- ↓ EPO
- SCHOOLING HIGH HT
- OFTEN PROGRESS
- THROMBOTIC
- HEMOR

## OTH

- POLYCYTHEMIA VERA
- ↓ SOMEWHAT ↓
- ESSENTIAL THROMBOCYTOPENIA
- PLTS TEAR-DROP ENYMOCY
- GRAN PRECC ↑ NUC ¢ Y
- ANEMIA
- SPLENOMEG
- ↓ PLATELETS
- ↓ MEGAKARYOCYTOSIS ++ THROMBOCYTOSIS
- PBd
- BLEEDING
- THROMBOSIS
- ↑ THROMBOCYTOSIS
- ↑ #
- SPANNED IN PROCESS
- POSTULATED PGF
- PDGF
- TGFβ
- MEGAKAR
- MAY BE I ~~PROLIF~~ ON
- FIBROBLAST PROLIFE
- IDIOP MYELOFIB
- ACMI PRECEDED BY MAR HYPER ¢ Y
- ⊙ EXTENSIVE EXTRAMED HEMATOP
- IN CARINY ⊙ = MYELOFIBROSIS
- PROLIFE = LATE OFTEN ADDMANIF
- ~~NEOP~~ FIBROSIS
- AGNOGENIC MYELOID METAPLASIA
- CBL HEMANGIOMA
- ↑ ENDOCRIN
- ↑ CUSHING SD
- ADRENOMA
- PALEOGENE
- TUMORS
- RENAL ¢ CA
- HEPAT CA
- APKD
- ANALOG THER
- INAPPRO EPO
- ≠ II POLYC
- ↑ EPO
- ↑ UNBCC
- CARCINOIC
- CML
- HEAVY SMOK
- HIGH ALTIT
- GNG HD ♡
- CHXIA
- PULMD
- ≠ OTH CONDITIONS POLYCYT
- ↑ EPO
- ⊙ EXTRA MED HEMATOP
- OFTEN
- ↑ FIBROSIS
- LATE PHASE ANEMIA
- ★ SURVIVES

NL

SCH

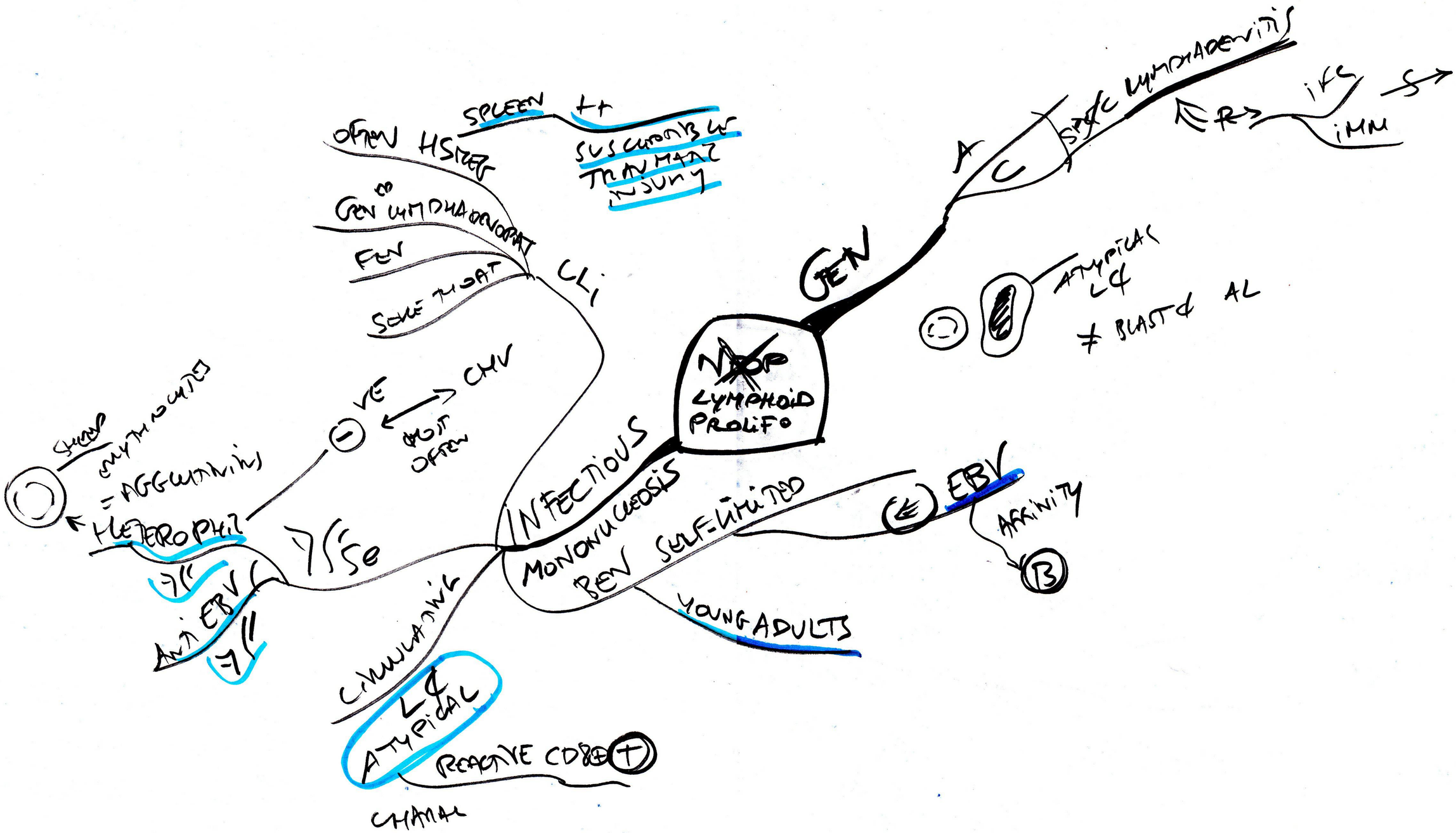
GEN
LYMPHOID PROLIFO
INFECTIOUS MONONUCLEOSIS
BEN SELF-LIMITED
EBV
AFFINITY
B
YOUNG ADULTS
ATYPICAL LY
≠ BLAST & AL
A
C
STATIC LYMPHADENITIS
R
IFG
IMM
S
CLI
OFTEN HSTEG
SPLEEN
++
SUSCEPTIBLE TRAUMATIC INJURY
GEN LYMPHADENOPAT
FEV
SORE THROAT
SHARP CYTOPLASMIC = AGGLUTININS
HETEROPHIL
-VE
MOST OFTEN
CMV
ANTI EBV
CUMULATING
LY ATYPICAL
REACTIVE CD8+
CHANAL

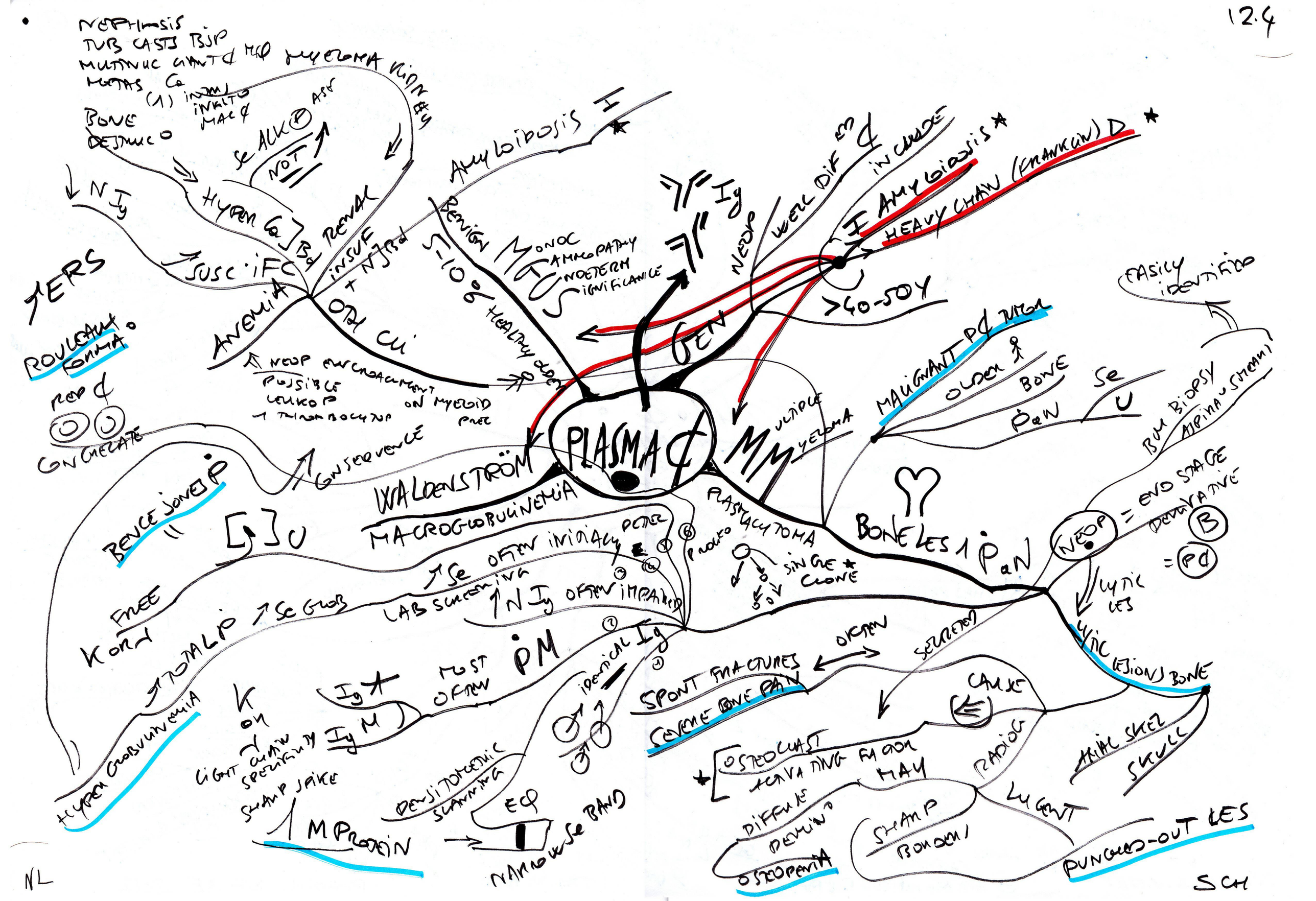
NEPHROSIS
TUB CASTS BJP
MULTINUC GIANT CELL
METAS Ca
(1) INTERM INVLTD MAC
BONE DESTRUCTO
MYELOMA KIDNEY
Se ALK PHOS ASP
NOT
HYPER Ca
Bd RENAL INSUF + NTSd
NTy
SUSCIFC
ANEMIA
ODT CU
AMYLOIDOSIS I
BENIGN
MGUS
MONOC GAMMOPATHY UNDETERM SIGNIFICANCE
5-10% HEALTHY ELDERLY
NEOP ENCROACHMENT ON MYELOID PREC
POSSIBLE LEUKOP + THROMBOCYTOP
GENERALIZED
NEOP
WELL DIF EM
INCIDENCE
AMYLOIDOSIS
HEAVY CHAIN (FRANKLIN) D
>40-50Y
EASILY IDENTIFIED
MALIGNANT PCD TUMOR
OLDER
BONE PAIN
Se Ca
BUM BIOPSY ASPIRATION SUMMARY
ROULEAUX FORMATION
REP CELL
CONGLOMERATE
CONSERVENCE
WALDENSTRÖM MACROGLOBULINEMIA
PLASMA CELL
MM
MULTIPLE MYELOMA
PLASMACYTOMA
PROLIFERATION
SINGLE CLONE
BONE LESION PAIN
NEOP = END STAGE DERIVATIVE
B
= PCD
LYTIC LES
LYTIC LESIONS BONE
BENCE JONES P
FREE K and λ
TOTAL P
Se GLOB
Se OFTEN INITIALLY PETER
LAB SCREENING
NIg OFTEN IMPAIRED
PM
MOST OFTEN
IgA
IgM
K OR λ
LIGHT CHAIN SPECIFICITY
SHARP JAKE
HYPERGLOBULINEMIA
M PROTEIN
DENSITOMETRIC SCANNING
EQ
NARROW Se BAND
IDENTICAL Ig
SPONT FRACTURES
SEVERE BONE PAIN
ORGAN
SECRETION
CAUSE
OSTEOCLAST ACTIVATING FACTOR MAY
RADIOG
LYSENT
AXIAL SKEL SKULL
DIFFUSE DEMINO
OSTEOPENIA
SHARP BORDERS
PUNCHED-OUT LES

NL

SCH

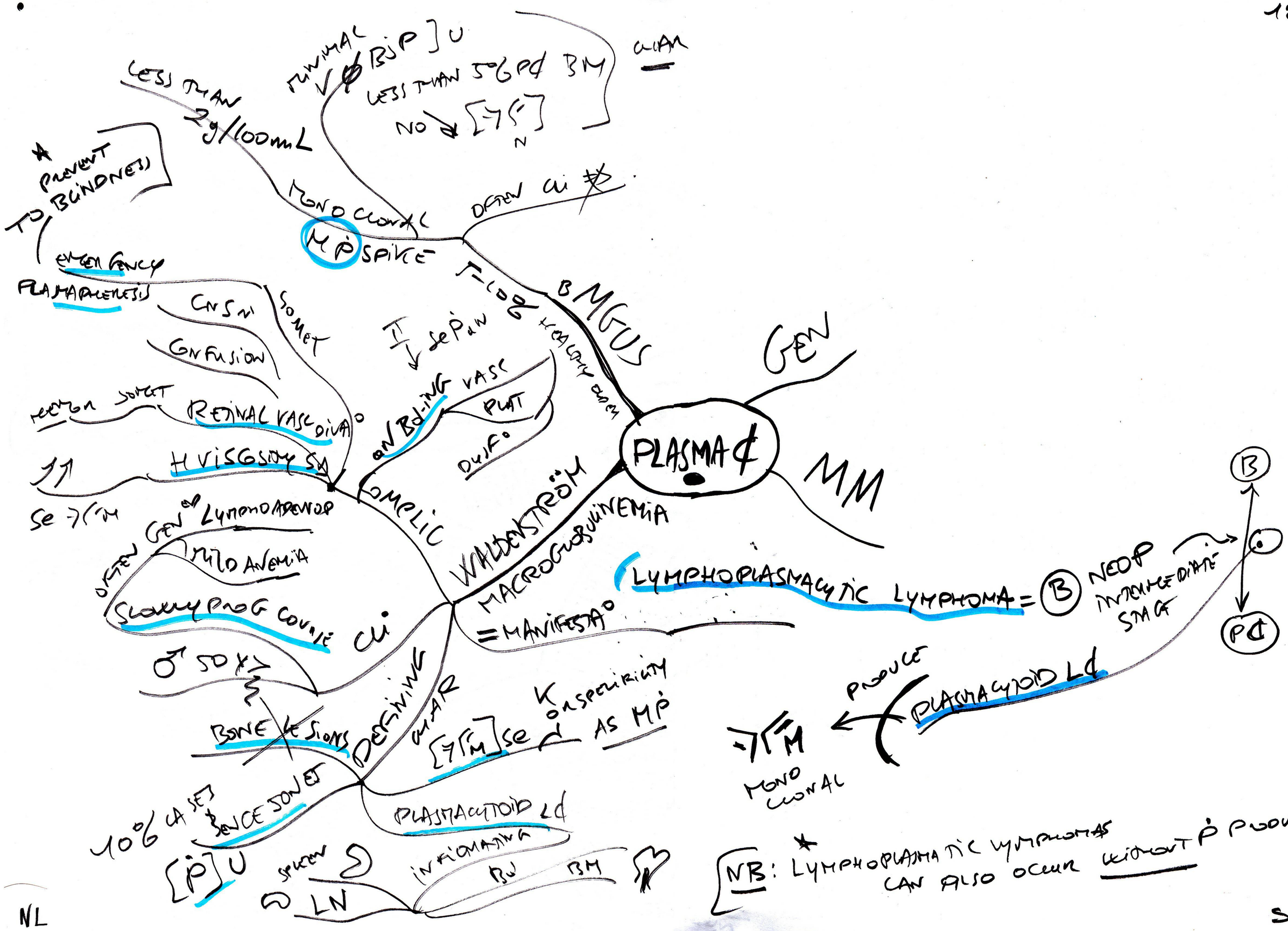
PLASMA ¢
GEN
MM
B MGUS
MONO CLONAL
M P SPIKE
LESS THAN 2g/100mL
MINIMAL ↓ BJP ] U
LESS THAN 5% PC BM
NO ↘ [γ/F] N
CLIN
★ PREVENT TO BLINDNESS
EMERGENCY PLASMAPHERESIS
CNS N
CONFUSION
SOMET
RETINAL VASCULITIS
HYPERVISCOSITY SX
↑↑ SERUM
OPTEN GEN LYMPHOADENOP
MILD ANEMIA
SLOWLY PROG COURSE
CLI
♂ 50 X
BONE LESIONS
10% CASES
SENSE SOMET
[P] U
SPLEEN
LN
PLASMACYTOID LC
INFIAMMATORY
BJ
BM
DEFINING MAR
[γ/F] SE
K ON SPECIFICITY
AS MP
T ↓ SE PAIN
OMPLIC
WALDENSTRÖM MACROGLOBULINEMIA
= MANIFESTATION
LYMPHOPLASMACYTIC LYMPHOMA = B NEOP INTERMEDIATE STAGE
B
PC
PLASMACYTOID LC
PRODUCE
γ/F M
MONO CLONAL
NB: ★ LYMPHOPLASMATIC LYMPHOMAS CAN ALSO OCCUR WITHOUT P PRODUC°
NL
SCM

12.5.1

Δ = DIAGNOSIS
π = PROGNOSIS

# HL

## STAGING

- ESSENTIAL PART OF DIAGNOSIC CRITERIA
  - FEV
  - EXTRALYMP SITES
  - INVOLV T
  - DISSEM ⊖ DEGREE
- PROGNOSIS IS BETTER PREDICTED BY STAGING
  - GAIN BETTER HISTOPATH VAL
  - ↑ ⊘ SYST S
  - ALGORITHM
- BASIS FOR MOST ANN ARBOR
  - CD15 ⊖ VE
  - CD30
  - CD20
  - ⊕ VE CD45
  - CINCHMV
  - CYTOP+
  - FIB
  - NEC
  - NUMER RSC
  - FEW LC
  - EXTENSIVE
  - BACKGROUND LC = CD20 ⊕ (B)
  - "POP GRN'C"
  - MASSIVE ↔ EBV
  - PROGNOSIS π ↑ HL
  - LP
  - ⊘ NAME
  - ++ LC
  - HISTIOC
  - LESS FREQ HL
  - YOUNG ADULTS
  - ♂ > ♀
  - 40% EBV
  - LC DEPLED
  - LC RICH (3)
  - ANIMS
  - NEC + FIB
  - RSC
  - HISTIOC
  - PLASMAC
  - EOS
  - POLYMORPHICT
  - Cu MODER AGONES
  - EBV
  - 70%
  - TYP'Y SEEN
  - LACUNAR C
  - MUMMIFIED C
  - + RSC
  - NOD ANIMI
- H & NHL
- ⊘ ⊘ ⊘

12.5.2

# NHL

- MYCOSIS FUNGOIDES (T)
  - Rash, plaques → STUM
  - Dermal infilt° atypical CD4⊕ (T) + cerebriform nuclei
  - Small pockets & in epid particular abscesses
  - Psorialiform eczematoid erythematous
  - (+) histo
  - Internal org
- SEZARY SD
  - Leukemic form
  - Skin lesions
- CUT (T)
  - Widespread nod inv
  - Aggressive course
  - Advanced stage
  - Elderly
  - Bimodal age
  - Cutaneous plasmacytoma
  - Exp° c-myc
  - t(8;14)
  - Burkitt like
  - LN
  - Mφ = "starry sky"
  - Any highly prolif
  - Immunodef
  - Histo
- ANGIOIMMUNOBLAS (T)
  - Ileocecal valve ABD
  - Sporadic
  - Endemic
  - Afric
  - Not strong
  - EBV
  - Typ
- ANAPLARGE & (T) CD30 ⊕ve
  - R B-ALL
  - Late
  - Often from convolved nuclei
  - Thymic L&
- (B) BURKITT
  - Aggressive
  - Often combina° T-ALL
  - Children
  - And mediast mass
  - Good TT
  - ⊕ve for ALK
  - NPM KS
  - t(2;17)
- PRECUR (T) LYMPHOBLASTIC LY/LE = A LE
  - Often jaw mass
  - T-ALL
  - Progresses to
  - Rapidly dissem
  - Child + young manifest°
  - K2 ALK
- DIFFUSE LARGE (B)
- EXTRANOD MARGINAL ZONE (B) OF MALT TYPE
  - Often ⊖ mass
  - Widespread aggressive dissem°
  - Leukemic involv° rare
  - Many in children
  - Older
  - Sites
  - Autoimm
  - Hashimoto
  - CIFM
  - Sjögren SD
  - Sal gland
  - Often
  - Dissem aggressive
  - H. pylori gastris
  - Invisible older ♂
  - MALTOMA
  - Assoc HGJA
  - ≃ morpho immunophen
  - ≠ t(11;14)
  - ⊕ Cyclin D1
  - Gene Rcl-1
  - Hit ⊕ apop
  - CD19
  - CD20
  - ⊕ve CD5
  - CD10
- WHO (B)
  - Lymphoid neop
  - Class°
  - SMALL LYMPHOCYTIC (B)
    - Indolent course
    - Older ♂
    - Close R CLL
    - WHO B cl chronic lymphocytic LE/small ly
    - Widespread involv°
    - "Diffuse effac° LN arch" "Sea"
    - Small mature appear
    - LC
  - FOLLICULAR (B)
    - Indol older
    - Most com form
    - Grooved &
    - Prolifer angular
    - Cytogen t(14;18)
    - Exp° Bcl-2
    - Nodular
    - Paneb
    - Freq
    - CD19
    - CD20
    - ⊕ve CD5
    - CD10
  - MANTLE &
    - Zone lymp fol
    - Exp° Bcl-2
    - Nodular
    - Often ⊖ mass
    - Widespread aggressive dissem°
    - Leukemic involv° rare
    - Older
    - Many in children
  - Mal neop
    - Originate most freq in LN or oth lymphoid areas
    - Involv° periaortic LN frequent
    - Lymphoid or oth & native to lymphoid tissue
    - HL
    - ALL lymp neop
    - NHL
    - Lymp
    - Leuk
    - 1 mm

NL

SCH