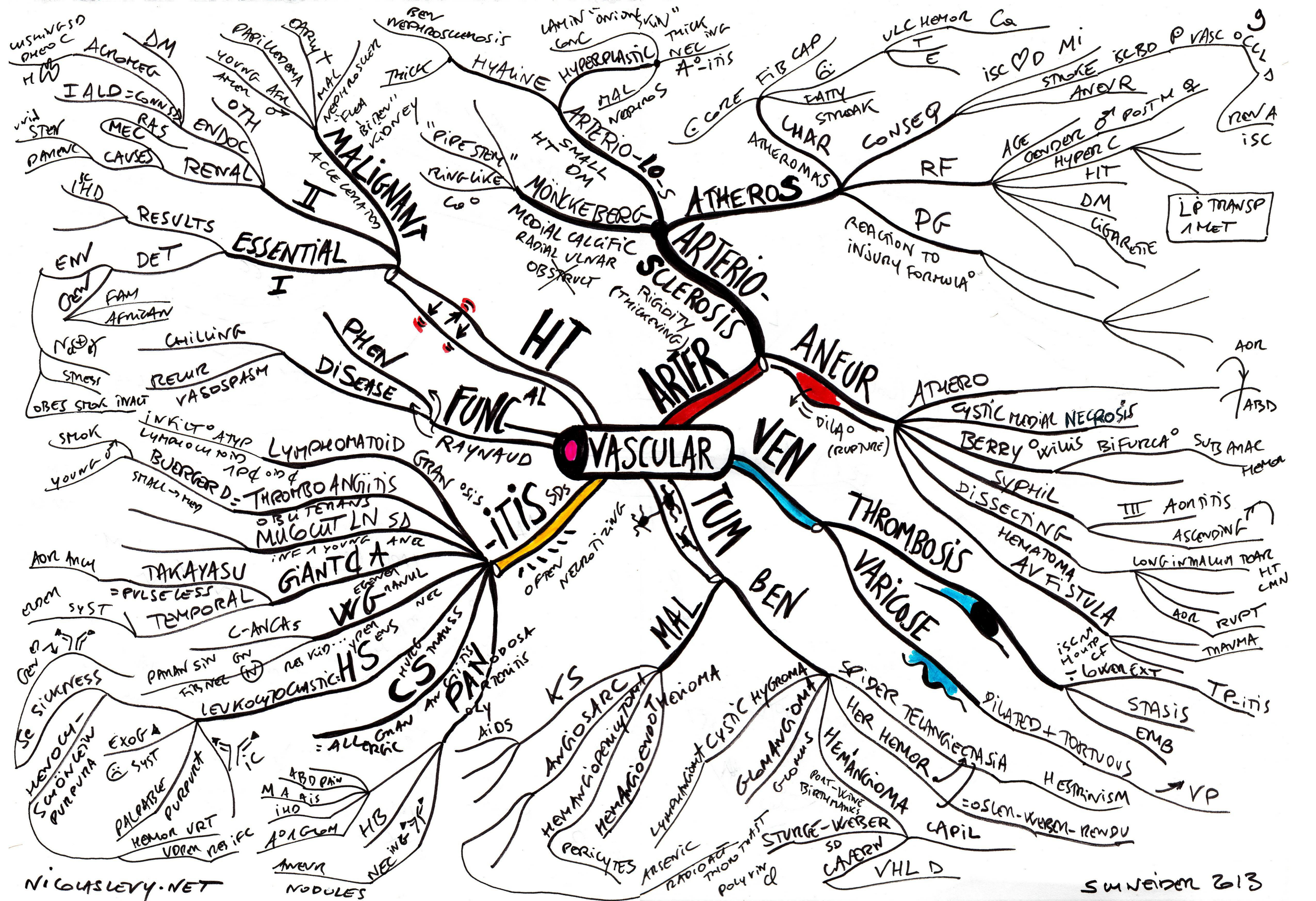

NICOLASLEVY.NET

SMWEIDER 2013

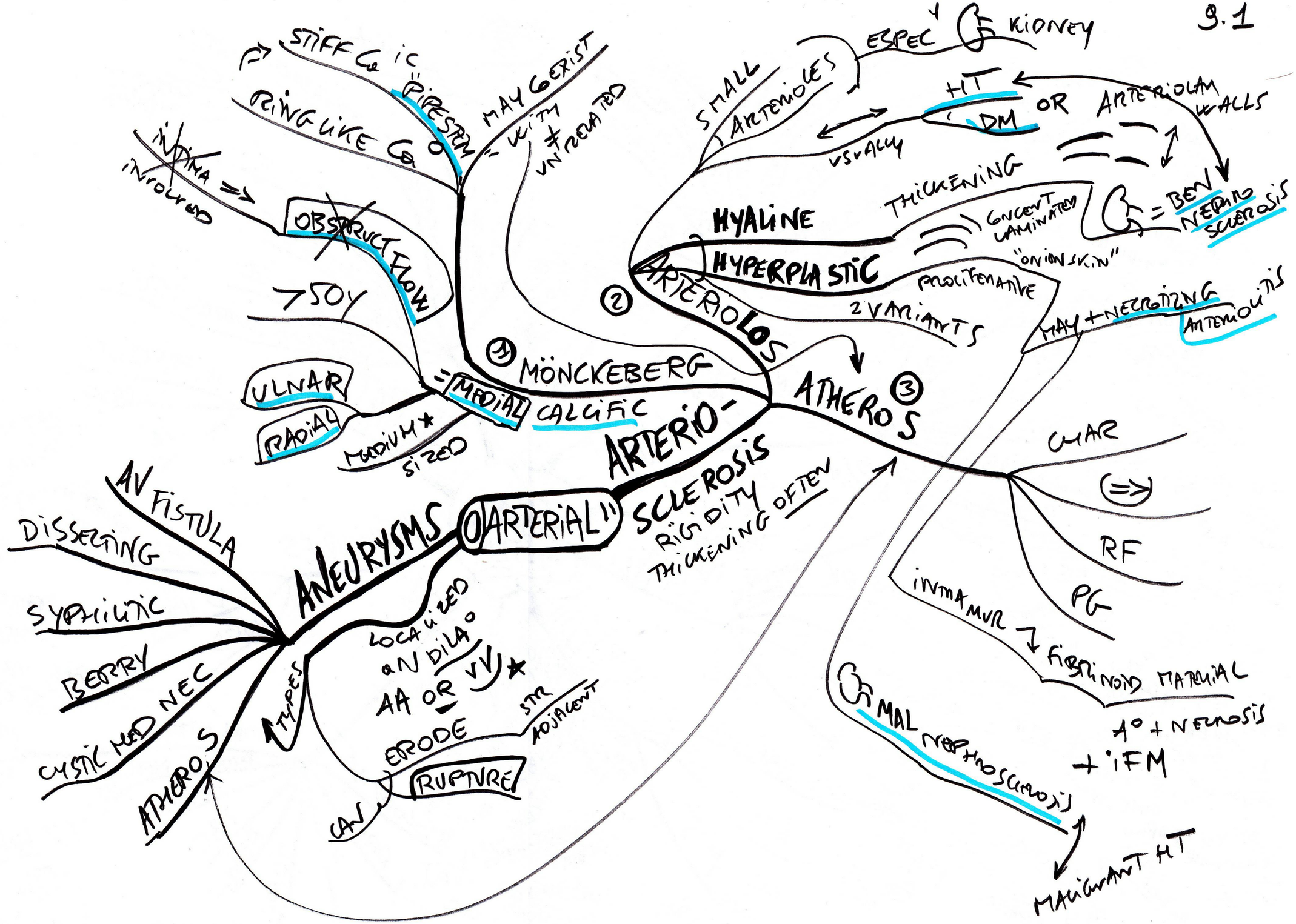
STIFF Ca ic
PIPESTEM
RING LIKE Ca
MAY Ca EXIST
= VERY ≠ UNRELATED
INTIMA INVOLVED
OBSTRUCT FLOW
>50y
ULNAR
RADIAL
MEDIUM* SIZED
= MEDIAL CALCIFIC
① MÖNCKEBERG
ARTERIO-
SCLEROSIS
RIGIDITY
THICKENING OFTEN
ARTERIAL
ANEURYSMS
TYPES
LOCALIZED
ANDILA°
AA OR VV ★
ERODE
STR ADJACENT
RUPTURE
CAN
DISSECTING
AV FISTULA
SYPHILITIC
BERRY
CYSTIC MED NEC
ATHEROS
② ARTERIOLOS
SMALL ARTERIOLES
ESPEC KIDNEY
HT
DM
OR
ARTERIOLAR WALLS
USUALLY
THICKENING
HYALINE
HYPERPLASTIC
CONCENT LAMINATED
"ONION SKIN"
= BEN NEPHRO SCLEROSIS
PROLIFERATIVE
2 VARIANTS
MAY + NECROTIZING ARTERIOLITIS
③ ATHEROS
CHAR
(=>)
RF
PG
INTIMA MUR
FIBRINOID MATERIAL
A° + NECROSIS
+ IFM
MAL NEPHROSCLEROSIS
MALIGNANT HT

NL

SCH

ATHEROSCLEROSIS

CHAR

- PROX CORON
- LARGER BR CAROTID
- O WILLIS
- LARGE VES LOWER EXT
- REN
- MESENT
- FIBROUS PLAQUES INTIMA
  - = ATHEROMAS
    - = FOAM ϕ
    - LADEN
    - MΦ
    - NEC DEBRIS
    - FIB. CAP
    - SMC
    - FOAM ϕ
    - C CE
    - C. CORE
    - Ca
    - ECMAT
    - FIBRIN + OTH COAG P
    - COL
    - ELASTIN
    - GAG
    - PG
- MEDIA
- COMPLICATED
  - MAY BE
  - DEVELOP FROM
    - CAN
    - ULCERATION
    - HEMOR INTO
    - CALCIFICATION
    - THROMBUS => OBSTRUCTION
    - EMBOLIZATION
    - ↑ NATURAL
- FATTY STREAK
- FOCAL ACCUM
  - LADEN FOAM ϕ 1ST Y
  - AORTA
  - MOST OLDEST

CONS

- ISCHD AMI => ↑
- STROKE & CBR ISC
  - INFARCTION
  - ISC BOWEL
  - PVASC OCCLUSIVE
  - CLAUDICATION => NECROSIS
  - ↳ GANGRENE
- REN ISC
  - => ↑↑ HT

SCM

PG

- ATHEROSCLEROSIS
- REACTION TO INJURY
- FORMULATION

RF

- RISK FACTORS
- AGE
- GENDER
  - ♂ > ♀
  - POSTMENOP ♀
- HYPERCHOLESTEROLEMIA
  - = C
  - "BAD" ↑ [CHOLEST] TOTAL
  - CLINICAL PREDICTORS ATHEROGENESIS
  - LDL : 4 / HDL 1 – CHOLEST
  - "GOOD" IDEALLY ANEUR
  - MAY ↓ WITH LOWERING
  - REMOVING CHOLEST FROM PLAQUES
- HT
- DM
- SMOKING
- PREMATURE
- LESS
- PVASC OCCLUSD
  - ↓ OFTEN
  - GANGRENE LOWER EXTREMITIES

MORTFREQ

- (=) MORBIDITY VASC
- ↑ JAPAN
  - 10X INCIDENCE
- FINLAND
- GB
- OTH
- USA
- CANADA

LPA

- HYPERTRIGLYCERIDEMIA
- HYPERURICEMIA
- "TYPE A" PERSON
- PHYS INACTIVITY
- OBESITY

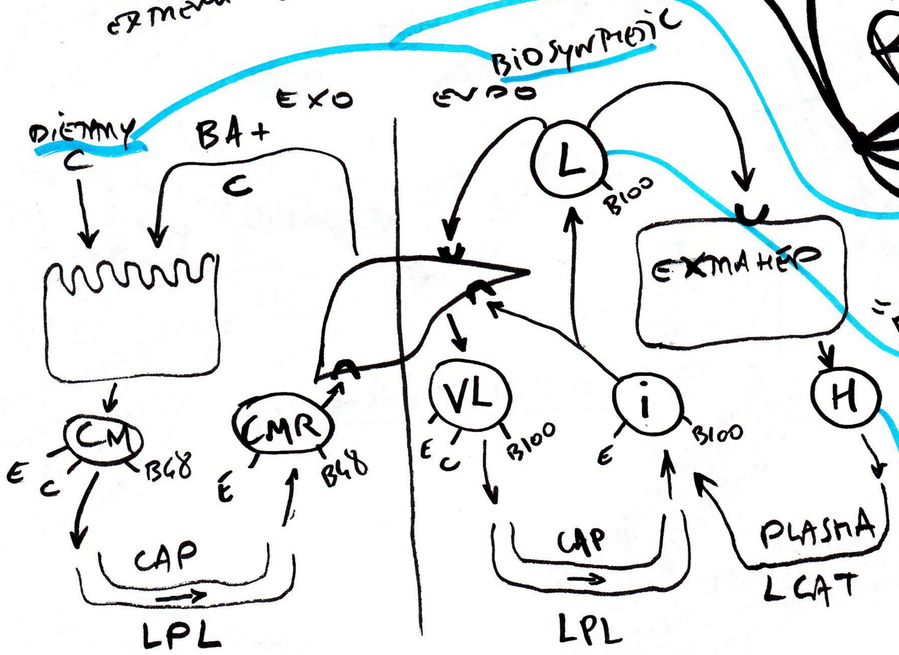

NL

REACTION TO INJURY FORMULATION

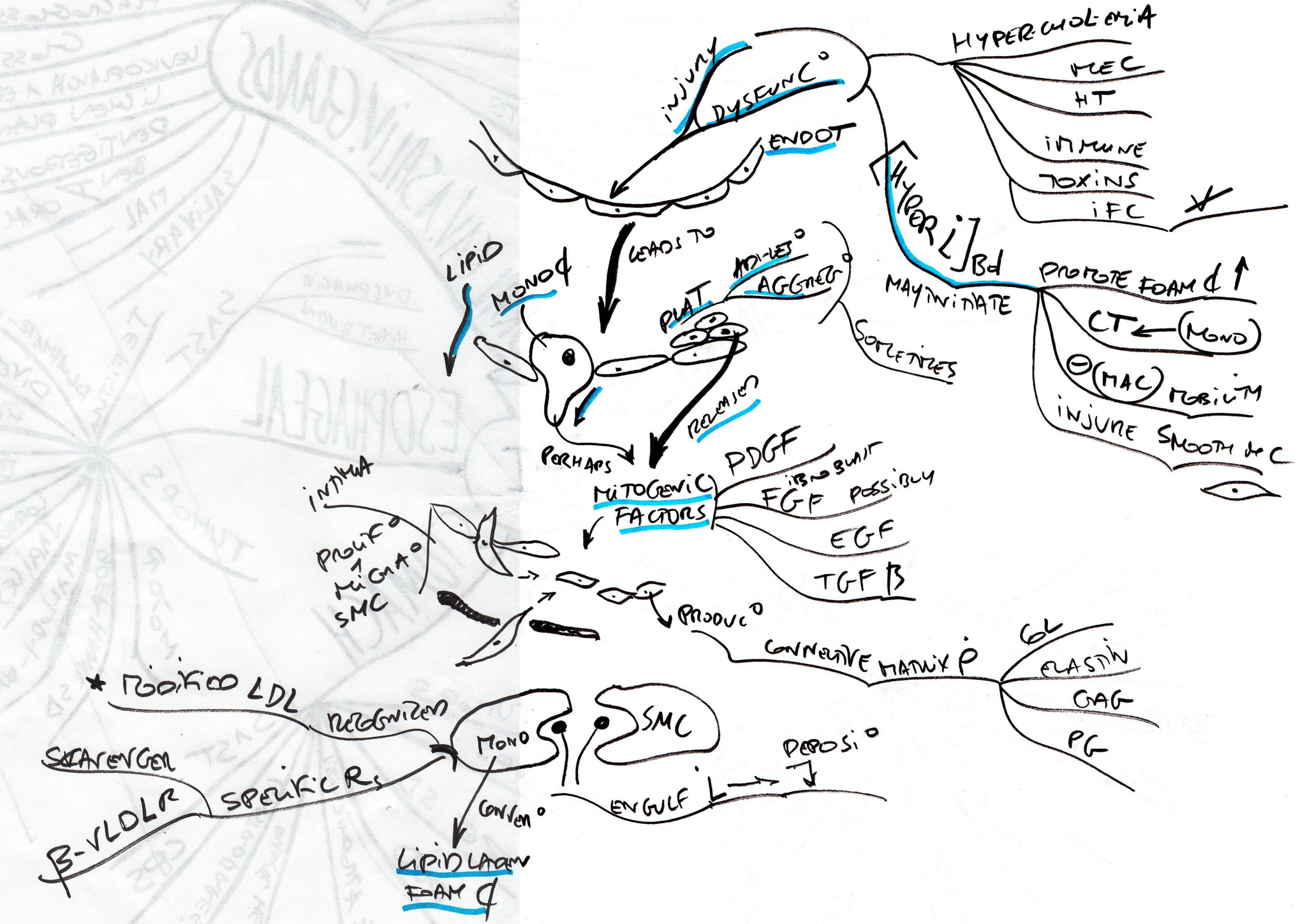

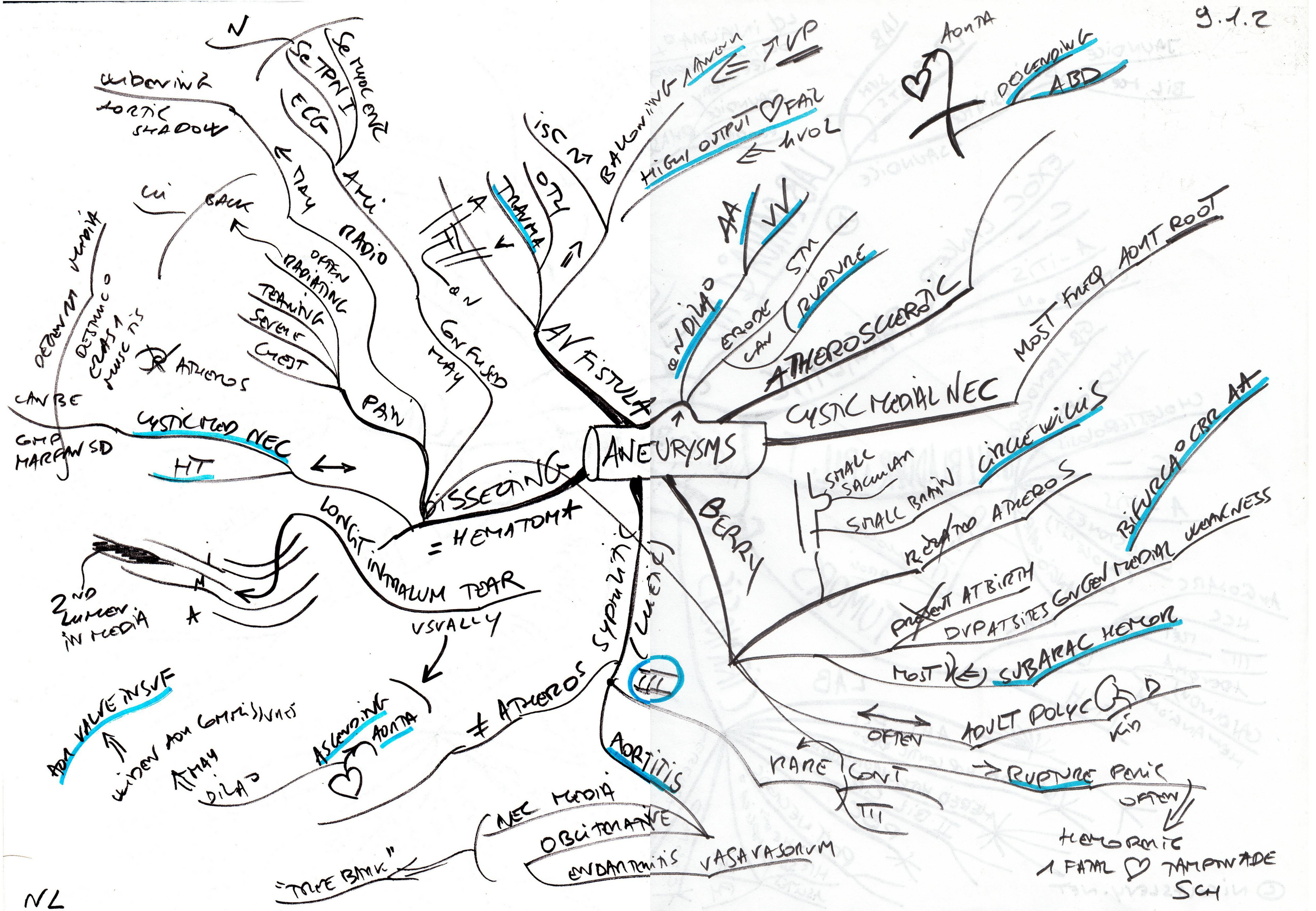
ANEURYSMS
AV FISTULA
ATHEROSCLEROTIC
CYSTIC MEDIAL NEC
MOST FREQ ADVT ROOT
BERRY
SMALL SACCULAR
SMALL BRAIN
CIRCLE WILLIS
RCA O CBR AA
BIFURCATION
RECENT ATHEROS
PRESENT AT BIRTH
DYPATSITES GROEN MEDIAL WEAKNESS
MOST
SUBARAC HEMOR
ADULT POLYCYSTIC KID
OFTEN
RUPTURE PERIC
OFTEN
HEMORRHIC
1 FATAL TAMPONADE
SCH
RARE CONT
III
AORTITIS
VASA VASORUM
ENDARTERITIS
OBLITERATIVE
NEC MEDIA
"TYPE BANK"
DISSECTING
= HEMATOMA
LONGIT INTIMAL TEAR
USUALLY
≠ ATHEROS
SYPHILITIC
(LUETIC)
III
ASCENDING AORTA
AOR VALVE INSUF
WIDEN AOR COMISSURES
ATRAY DILAT
GMP
MARFAN SD
CAN BE
CYSTIC MED NEC
HT
2ND LUMEN IN MEDIA
A
DESTRUCTIVE CHAS A MUSCITIS
ATHEROS
DEGENERATIVE VASCULITIS
CLI
BACK
PAIN
RADIO
OFTEN RADIATING
TRAUMA
SEVERE CHEST
GRF FUSID
MAY
ECG
ST PNT
SEPTIC EMBOL
ATRI
MAY
AORTIC SHADOW
WIDENING
N
OTY
ISC
BALLOONING
HIGH OUTPUT FAIL
HVOL
AORTA
DESCENDING
ABD
AA
VV
ENDITIS
ERODE CAN
STM
RUPTURE

NL

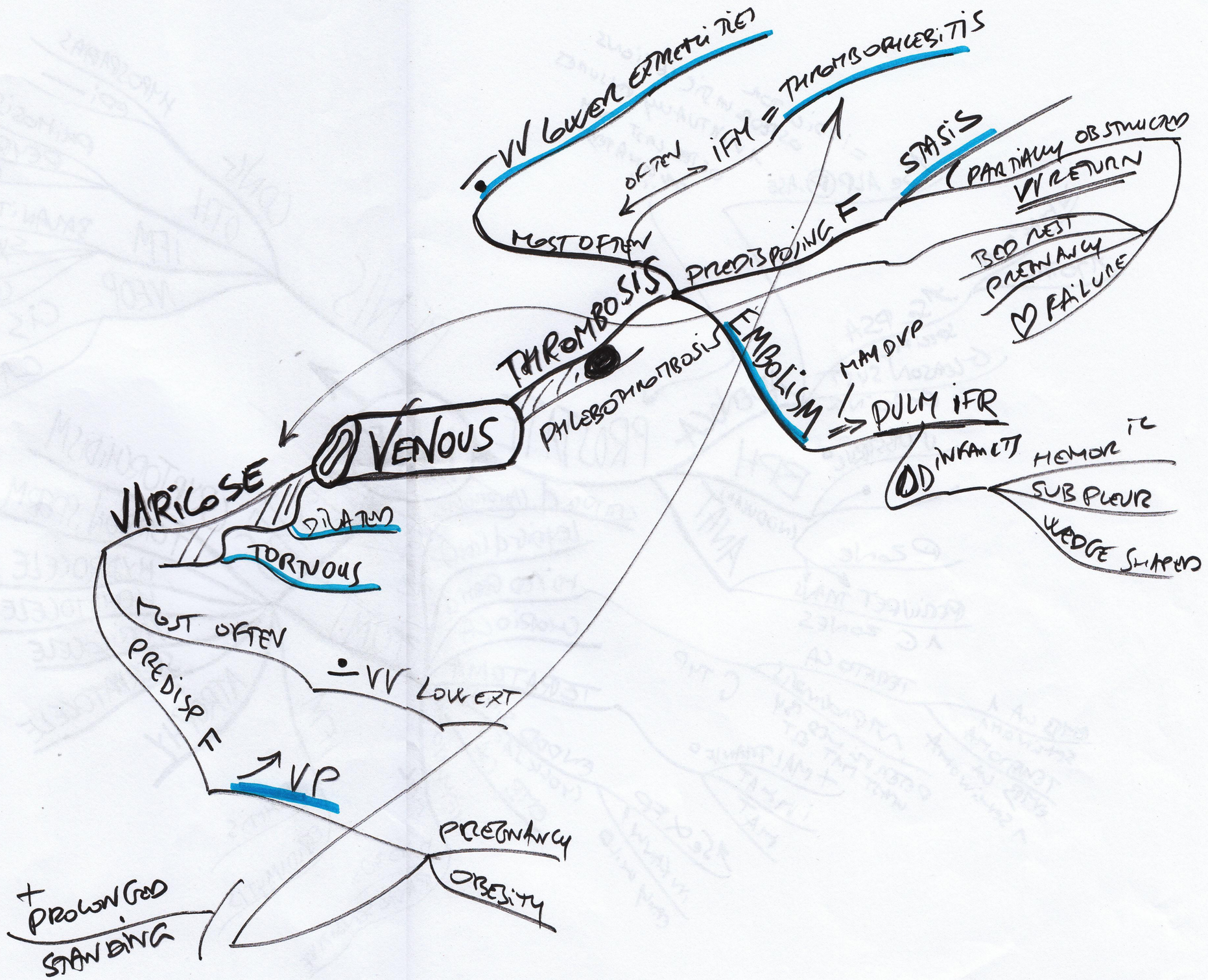
VV LOWER EXTREMITIES
OFTEN
IFM = THROMBOPHLEBITIS
STASIS
PARTIALLY OBSTRUCTED
VV RETURN
MOST OFTEN
PREDISPOSING F
BED REST
PREGNANCY
FAILURE
THROMBOSIS
EMBOLISM
MAY DVP
PULM IFR
PHLEBOTHROMBOSIS
VENOUS
VARICOSE
DILATED
TORTUOUS
INFARCT
HEMORR
SUBPLEUR
WEDGE SHAPED
MOST OFTEN
PREDISP F
VV LOWER EXT
VP
PREGNANCY
OBESITY
PROLONGED STANDING

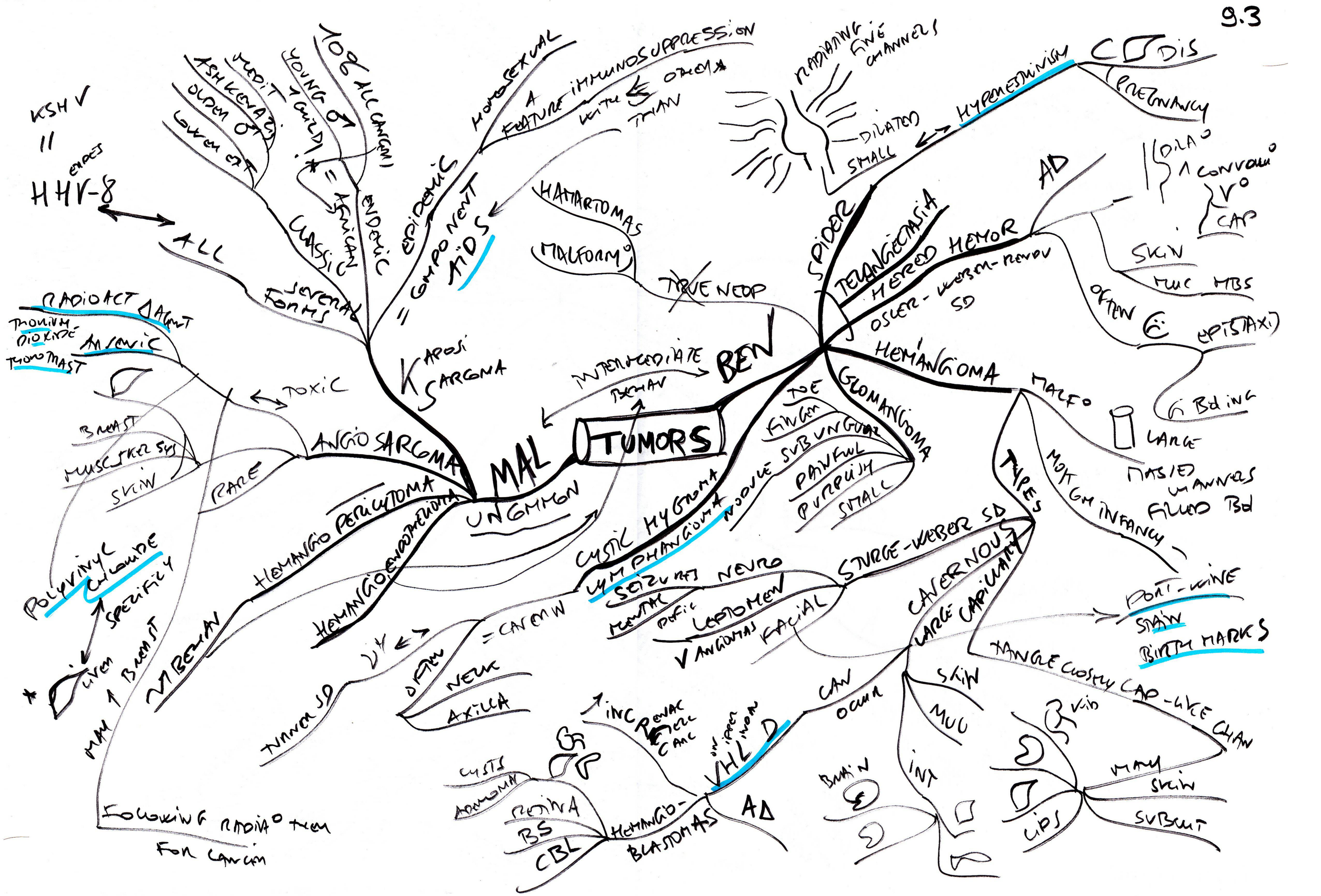
MAL TUMORS
KSHV
HHV-8
ALL
AIDS
KAPOSI SARCOMA
ENDEMIC
EPIDEMIC
CLASSIC
AFRICAN
YOUNG ♂ CHILD
ASHKENAZI
JUDIT
OLDER ♂
LOWER ext
JOG ALL CAN(M)
HOMOSEXUAL
A FEATURE IMMUNOSUPPRESSION
WITH ONCOM
THAN
COMPONENT
RADIOACT AGENT
THORIUM DIOXIDE
ARSENIC
THOROTRAST
TOXIC
BREAST
MUSCULOSKEL SYS
SKIN
RARE
ANGIOSARCOMA
HEMANGIOPERICYTOMA
HEMANGIOENDOTHELIOMA
POLYVINYL CHLORIDE
SPECIFICITY
LIVER
MAN > BREAST
MEDIAN
FOLLOWING RADIATION FOR CANCER
HAMARTOMAS
(MALFORM°)
TRUE NEOP
INTERMEDIATE THERAPY
BEN
SPIDER
TELANGIECTASIA
HEREDITARY HEMOR
OSLER-WEBER-RENDU SD
HYPERESTHESIA
RADIANT FIRE CHANNELS
DILATED
SMALL
CDS
PREGNANCY
AD
DILA°
CONVOLU°
V°
CAP
SKIN
MUC MBS
OFTEN
EPISTAXIS
BLEEDING
HEMANGIOMA
MALF°
LARGE
MASSED MANNERS
FILLED BLD
TYPES
MOST GM INFANCY
TOE
FINGER
SUBUNGUAL
PAINFUL
PURPLISH
SMALL
GLOMANGIOMA
NODULE
CYSTIC HYGROMA
LYMPHANGIOMA
SEIZURES
NEURO
MENTAL
DEFIC
LEPTOMEN
V ANGIOMAS
FACIAL
STURGE-WEBER SD
CAVERNOUS
LARGE CAPILLARY
PORT-WINE
STAIN
BIRTH MARKS
TANGLE CLOSELY CAP-LIKE CHAN
SKIN
MUC
INT
VIB
MANY
SKIN
SUBCUT
LIPS
CAN OCULA
BRAIN
AD
HEMANGIO-BLASTOMAS
VHL D
INCREASE CANC
CYSTS
ADENOMA
RETINA
BS
CBL
GR
NECK
AXILLA
OFTEN
= CARCIN
UV
TUNNER SD

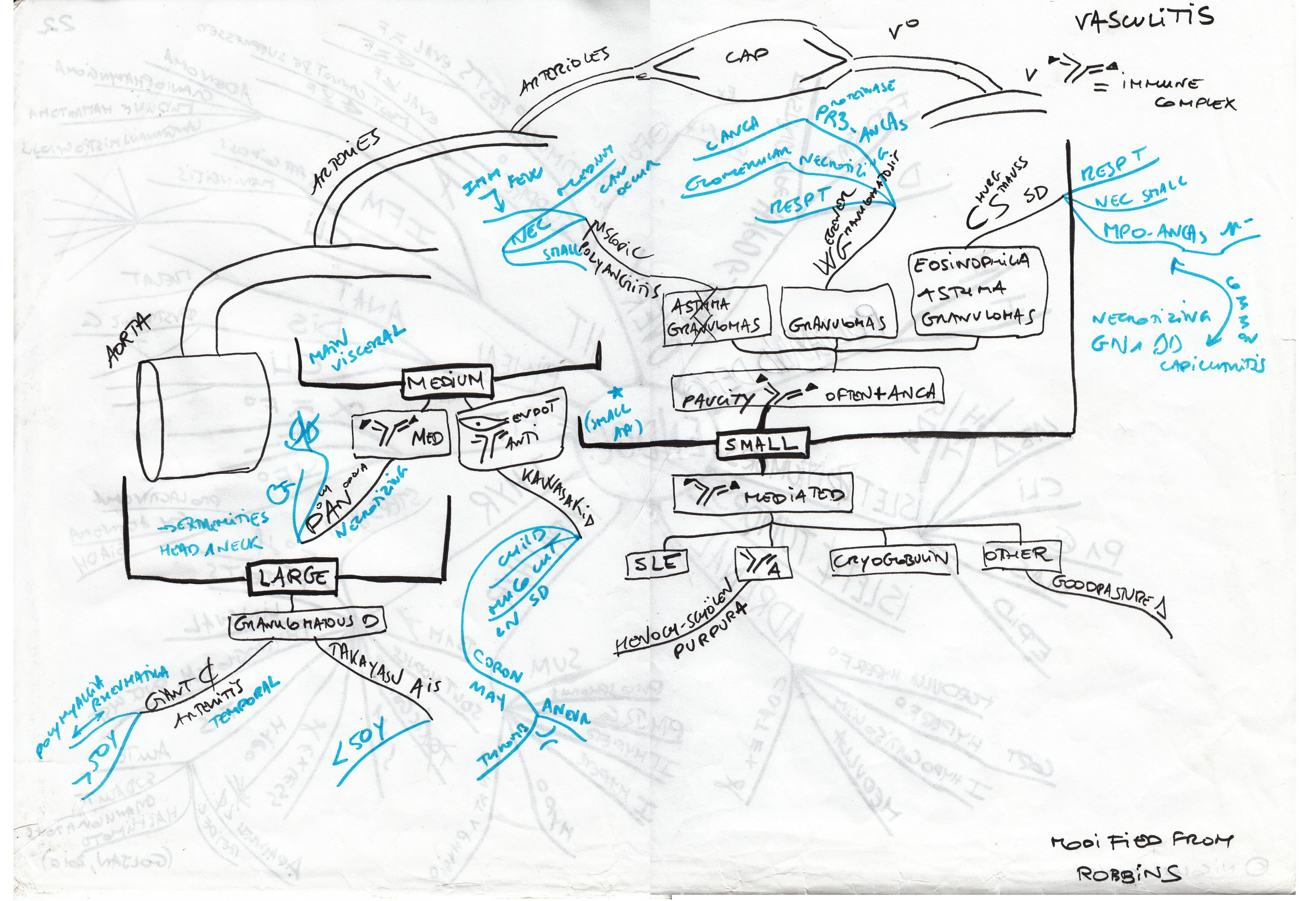

MODIFIED FROM ROBBINS

VASCULITIS
SDS

LYMPHOMATOID GRANULOMATOSIS
RARE
- INFILTRATE
- ATYPICAL LYMPHOMATOID + PLASMACYTOID
- SMOKING
- PAINFUL ISC → GANG
- JEWISH YOUNG → THROMBOANGIITIS OBLITERANS = BUERGER
- EXTREMITIES → VV NN
- Ai SMALL → MED AA
- CNS
- POLYM RECURR
- VISUAL
- PALPABLE NODULES
- TENDERNESS
- HEADACHE
- MALAISE FATIGUE
- BRACHIO ERCHY
- PULSE
- ANTANG SD
- TAKAYASU PULSELESS
- MED LARGE
- GIANT → SYSTEMIC
- TEMPORAL ★ MOST VAS
- GRANULOMA INVOLVE MUSCULOCUTANEOUS
- FIBROID NEC SMALL AV CAUSE INFECTOBY (NEUT) GRANULOMA GIANT
- SOMETIMES
- NEC ING GN
- PARANASAL SINUSES
- ENTERITIS
- IFC ANT UPPER IFJ
- SOMET POST STENOTIC
- HENOCH SCHÖNLEIN PURPURA
- YOUNG CHILD
- VASCULITIS
- EXT ARMS BUTTOCKS
- FEV ARTHALGIA GI + NEW
- ≃ ILIAC WP
- SCM

INFLAMMATORY
- ATYPICAL LYMPHOMATOID + PLASMACYTOID
- SMOKING
- PAINFUL ISC → GANG
- JEWISH YOUNG → THROMBOANGIITIS OBLITERANS = BUERGER
- EXTREMITIES → VV NN
- Ai SMALL → MED AA
- CNS
- POLYM RECURR
- VISUAL
- PALPABLE NODULES
- TENDERNESS
- HEADACHE
- MALAISE FATIGUE
- BRACHIO ERCHY
- PULSE
- ANTANG SD
- TAKAYASU PULSELESS
- MED LARGE
- GIANT → SYSTEMIC
- TEMPORAL ★ MOST VAS
- GRANULOMA INVOLVE MUSCULOCUTANEOUS
- FIBROID NEC SMALL AV CAUSE INFECTOBY (NEUT) GRANULOMA GIANT
- SOMETIMES
- NEC ING GN
- PARANASAL SINUSES
- ENTERITIS
- IFC ANT UPPER IFJ
- SOMET POST STENOTIC
- HENOCH SCHÖNLEIN PURPURA
- YOUNG CHILD
- VASCULITIS
- EXT ARMS BUTTOCKS
- FEV ARTHALGIA GI + NEW
- ≃ ILIAC WP
- SCM

GRANULOMATOUS
- IMMUNOSUPPRESSED
- SKIN
- CNS
- PRIM
- (B) NEOP
- T EPITHELIAL
- (T) RESPONSE

NECROTIZING
- COMMONLY
- IFM
- A MUST ANYONE CAN
- USUALLY MEDIATED BY IMM REC

PAN
- OUTSIDE OF KIDNEY
- VARIANT
- NEC ING → IFM
- SMALL
- MED
- AA
- 30% → HB
- DESTRUCTION
- MEDIA + INTERNAL ELASTIC LAMINA
- → ANEURYSMAL NODULES
- CUI
- OFTEN
- FEV
- CNS PNS
- EYE SKIN
- GI NAUS VOM ABD PAIN
- ARTHRITIS
- MYALGIA
- MUSCLE SKEL
- SITES
- LESIONS
- WEIGHT ↓
- MALAISE
- ABD PAIN
- THROMBOSIS
- MYALG
- HT
- MOST
- A°
- G
- COR ISCHD
- PULM VASC
- EOS
- ASTHMA
- Ai SMALL
- A°
- C
- V°
- MULTIPLE LES SAME AGE
- ≠ PAN
- PALPABLE PURPURA
- PRECIP EXOG
- MAY
- SYST D
- CONNEC
- MALIG
- DRUGS
- FOODS
- IFC
- ANY SITE
- G
- GI
- WHERE INVOLVED SKIN
- NEUTROPHILIC
- ≃ LEUKOCYTOCLASTIC
- ERYTH?
- MOST
- SMALL MEDIUM VEIN + OTHER
- RES
- SICKNESS
- RARE
- SIGNS
- ST
- Se
- CUI
- NL

CS SD
- HUNG MAYS
- NEC ING
- ALLERGIC GRAN ANGIITIS = HS
- ASTHMA
- EOS
- Ai SMALL
- A°
- C
- V°
- PULM VASC
- MULTIPLE LES SAME AGE
- ≠ PAN
- PALPABLE PURPURA
- PRECIP EXOG
- MAY
- SYST D
- CONNEC
- MALIG
- DRUGS
- FOODS
- IFC
- ANY SITE
- G
- GI
- WHERE INVOLVED SKIN
- SCM

DEPOSIT
- MOST OFTEN
- DEPOSIT
- DNA
- HB SFE
- HC RNA
- FREQ Ag

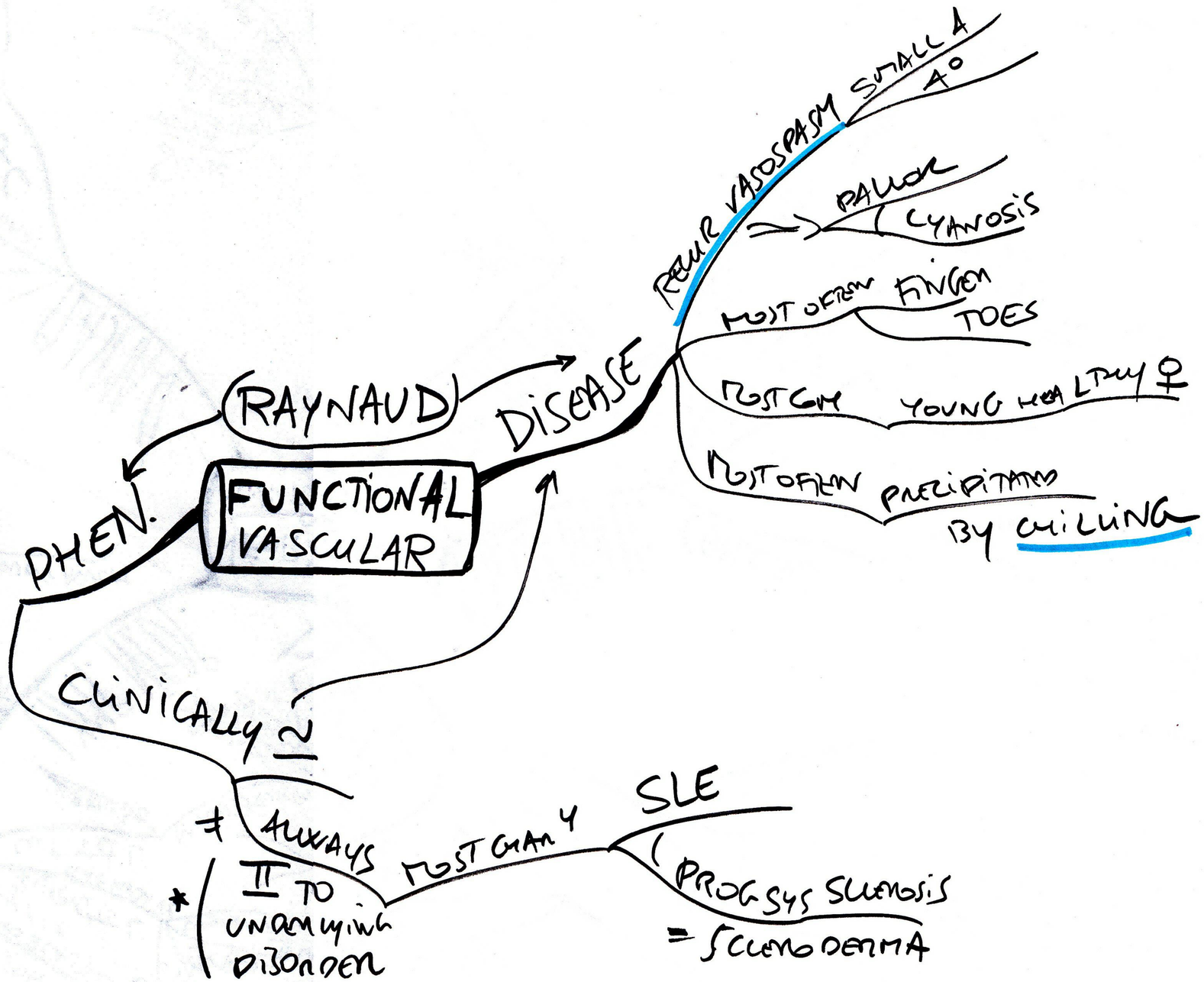
FUNCTIONAL VASCULAR
RAYNAUD
DISEASE
PHEN.
RECUR VASOSPASM
SMALL A
A°
PALLOR
CYANOSIS
MOST OFTEN
FINGER
TOES
MOST COM
YOUNG HEALTHY ♀
MOST OFTEN PRECIPITATED
BY COLDING
CLINICALLY ≃
≠ ALWAYS
MOST CAN'Y
SLE
PROG SYS SCLEROSIS
= SCLERODERMA
* II TO
UNDERLYING
DISORDER

NL

SCH

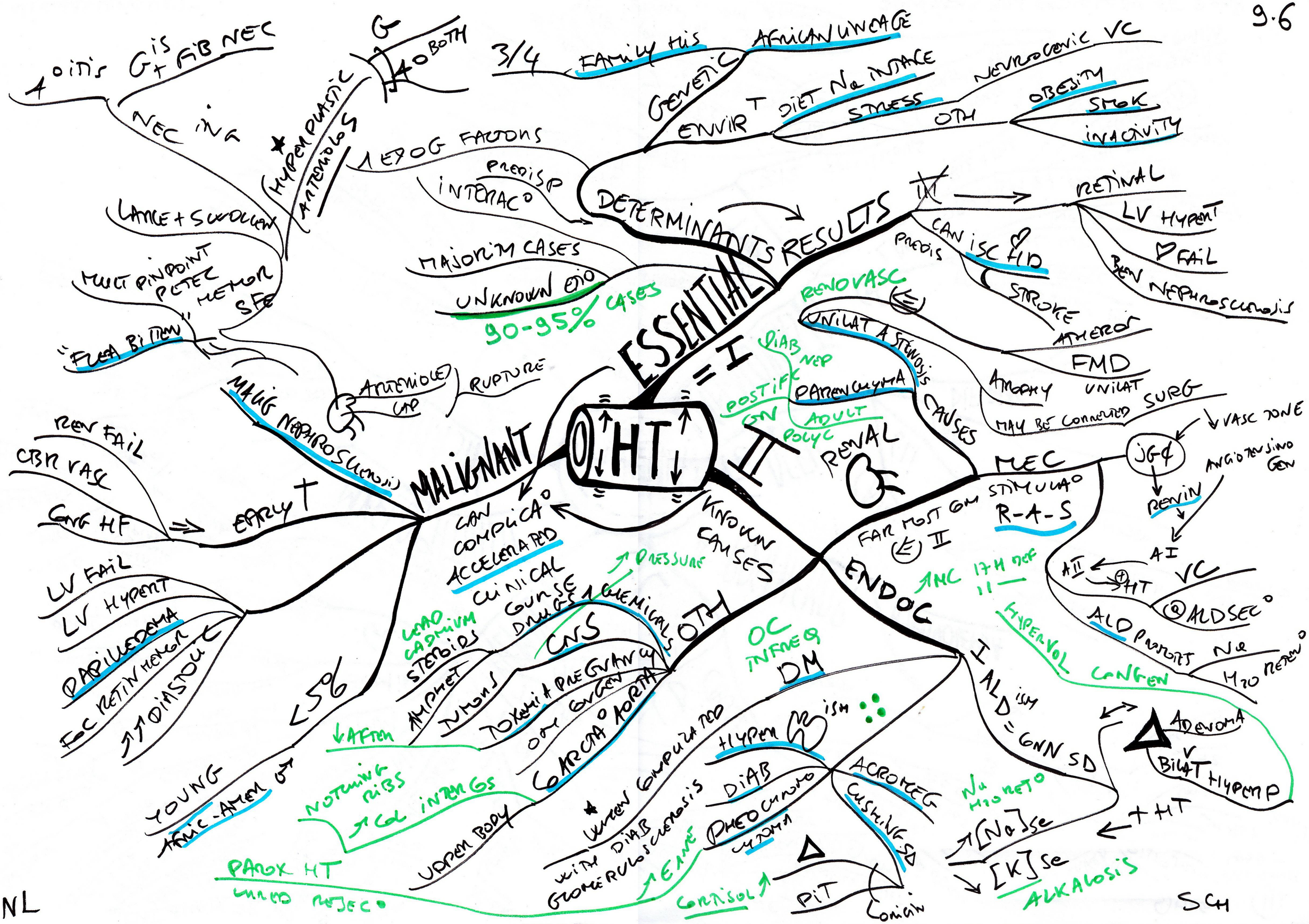
ESSENTIAL HT
DETERMINANTS RESULTS
GENETIC
FAMILY HIS
AFRICAN UNCAGE
ENVIR
DIET Na INTAKE
STRESS
OTH
NEUROGENIC VC
OBESITY
SMOK
INACTIVITY
EPIDEM FACTORS
PREDISP
INTERACT
MAJORITY CASES
UNKNOWN ETIO
90-95% CASES
RETINAL
LV HYPERT
FAIL
REN NEPHROSCLEROSIS
CAN ISCHD
PREDIS
STROKE
ATHEROS
FMD
UNILAT
SURG
RENOVASC
UNILAT A STENOSIS
CAUSES
ATROPHY
MAY BE CONNECTED
PARENCHYMA
DIAB NEP
POSTIF
GN
ADULT
POLYC
RENAL
MALIGNANT HT
ARTERIOLE GAP
RUPTURE
MALIG NEPHROSCLEROSIS
MULTI PINPOINT PETEC HEMOR SFE
"FLEA BITTEN"
LANCE + SCHOLLER
HYPERPLASTIC ARTERIOLOS
4 OITIS
GIS + GB NEC
NEC IN
G
BOTH
REV FAIL
CBR VASC
GNG HF
EARLY
LV FAIL
LV HYPERT
PAPILLEDEMA
FOC RETIN HEMOR
DIASTOLIC
<56
YOUNG
AFRIC-AMER
CAN COMPLICATE
ACCELERATED
CLINICAL COURSE
DRUGS & CHEMICALS
PRESSURE
LEAD CADMIUM STEROIDS
AMPHET
TUMORS
CNS
TOXEMIA PREGNANCY
ORT COARCT
COARCTATION AORTA
AFTER
NOTCHING RIBS
CGL INTERCGS
UPPER BODY
UNKNOWN CAUSES
OC INFECTIOUS
DM
WITH COMPLICATED
WITH DIAB GLOMERULOSCLEROSIS
HYPERTHYROIDISM
DIAB
PHEOCHROMOCYTOMA
ACROMEGALY
CUSHING'S
CORTISOL
PIT
CORTICOIN
ENDOC
FAR MOST COMMON
II
INC 17H DEF
HYPERVOL CONGEN
ALDOSTERONISM = CONN'S
ADENOMA
BILAT HYPERP
MEC
STIMULATES
R-A-S
JGC
VASC ZONE
ANGIOTENSINOGEN
RENIN
AI
AII
HT
VC
ALDSECRETION
ALDOSTERONE
Na
H2O RETENTION
+ HT
[Na]se
[K]se
ALKALOSIS
PAROX HT
UNILAT REJECT
NL
SCH