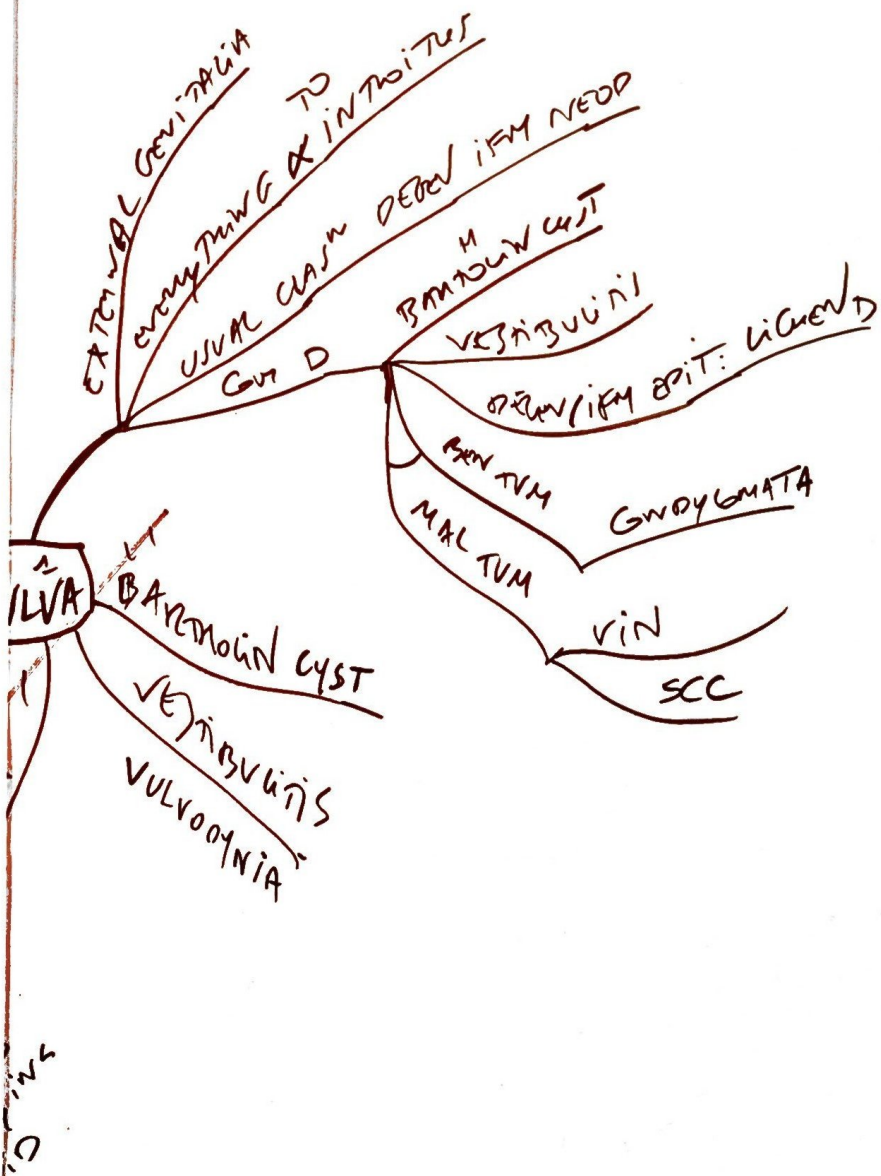


FEMALE



VULVA

US 4
6811
MPV
AGAIN
CONDYLOMATA

EXTERNAL GENITALIA
EXTENDING TO
USUAL CLASH DEEP IFM NEOP
CUT D
BAMBOON CYST
VULVITIS
OPEN IFM BIT: LIQUEN
BEN TUM
MAL TUM
GNOYLOMATA
VIN
SCC

TYPES

SKIN RETURNING AS BEING POTY
MUCOSAL WINGS
WHICH SHOW
HYPERPLASTIC

ITUMF
ON
MUC
INTRA
= LIQUEN

SIMPLE
CHRONIC

SUPPUS

FIBROUS
UNCOMMON
EPID

SKIN
HYPERPLASTIC
ATROPHIC

SKIN
FIBROSIS &
IFM
LILYON
SCAROUS
ATROPHIC

PROLIFER

SKIN

