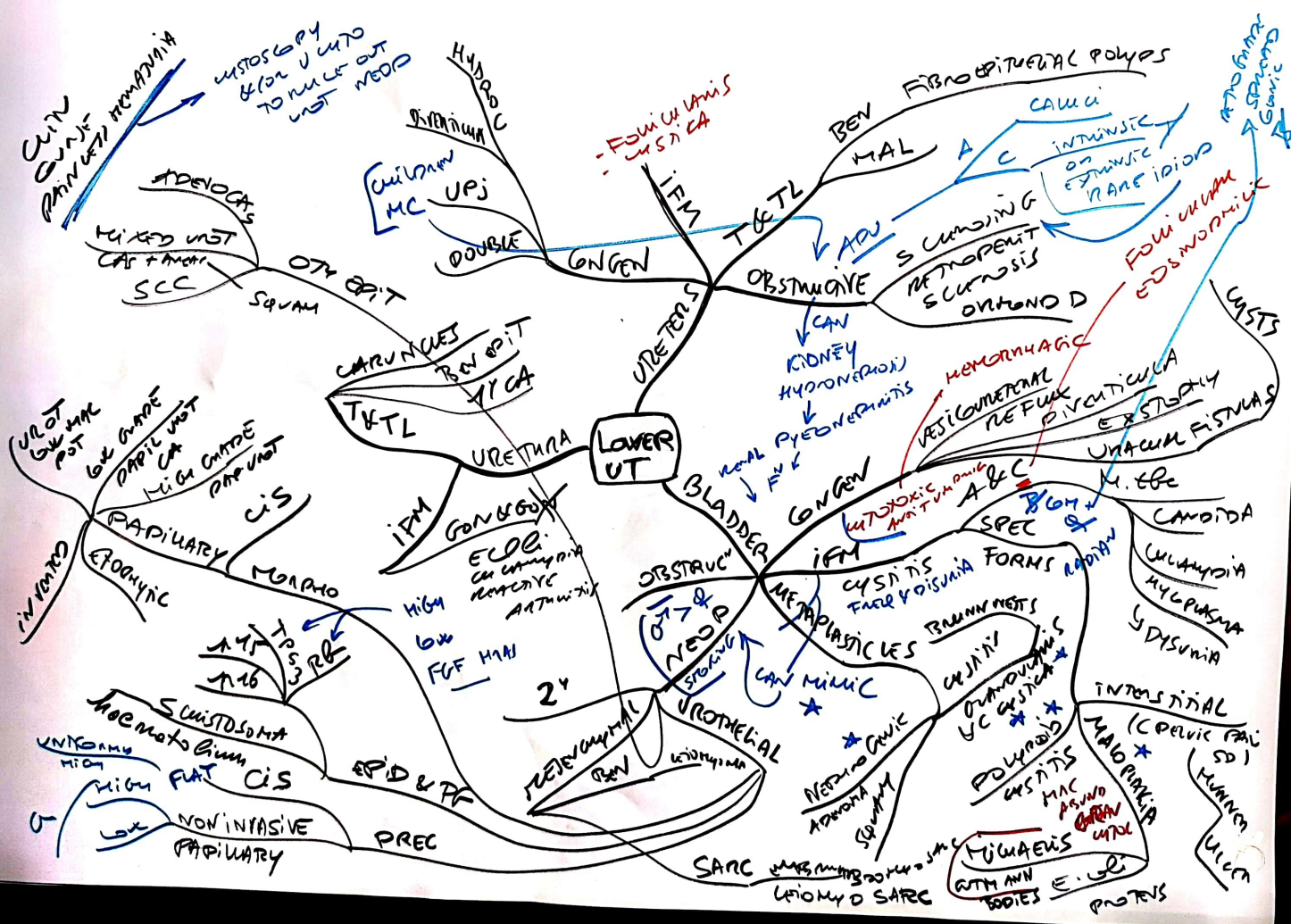

CUTAN  
DUNK  
PAINFUL HEMORRHOID

HYSTOSCOPY  
& FOR UCTO  
TO RULE OUT  
NEOPL

ADENOCA  
MIXED UST  
CAP + MUC  
SCC

OTY EPIT  
SQUAM

HYDRONEPHROSIS

CHILDREN MC  
UPJ

FOLICULAR  
CYSTIC LESIONS

BEN FIBROEPITHELIAL POLYPS  
MAL  
CAUCI

INTRINSIC  
OR  
EXTRINSIC  
RARE IDIOP

FOLICULAR  
EDS (Ectopic Duct Syndrome)

ADENOCARCINOMA  
CYSTIC LESIONS

UROTHELIAL  
LOW GRADE  
PAPIL UST  
HIGH GRADE  
PAP UST  
INVENTED  
EPIDERMAL  
MORPHO  
CIS

URETHRA

IFM  
GONOCOCCAL  
ECOE  
CANCER  
HIGH LOW FGF  
HYCA

LOWER UT

BLADDER

CONGEN  
OBSTRUCTIVE  
IFM  
METAPLASIA  
UROTHELIAL

OBSTRUCTIVE  
CAN KIDNEY  
HYDRONEPHROSIS  
RENAL PYELONEPHRITIS

HEMORRHAGIC  
VESICOURTERAL  
REFLEX  
PICTICULAR  
ERECTILE  
URACUM FISTULAS

UROTHELIAL  
UROTHELIAL  
UROTHELIAL

INTERSTITIAL  
MALIGNANT  
UROTHELIAL  
UROTHELIAL

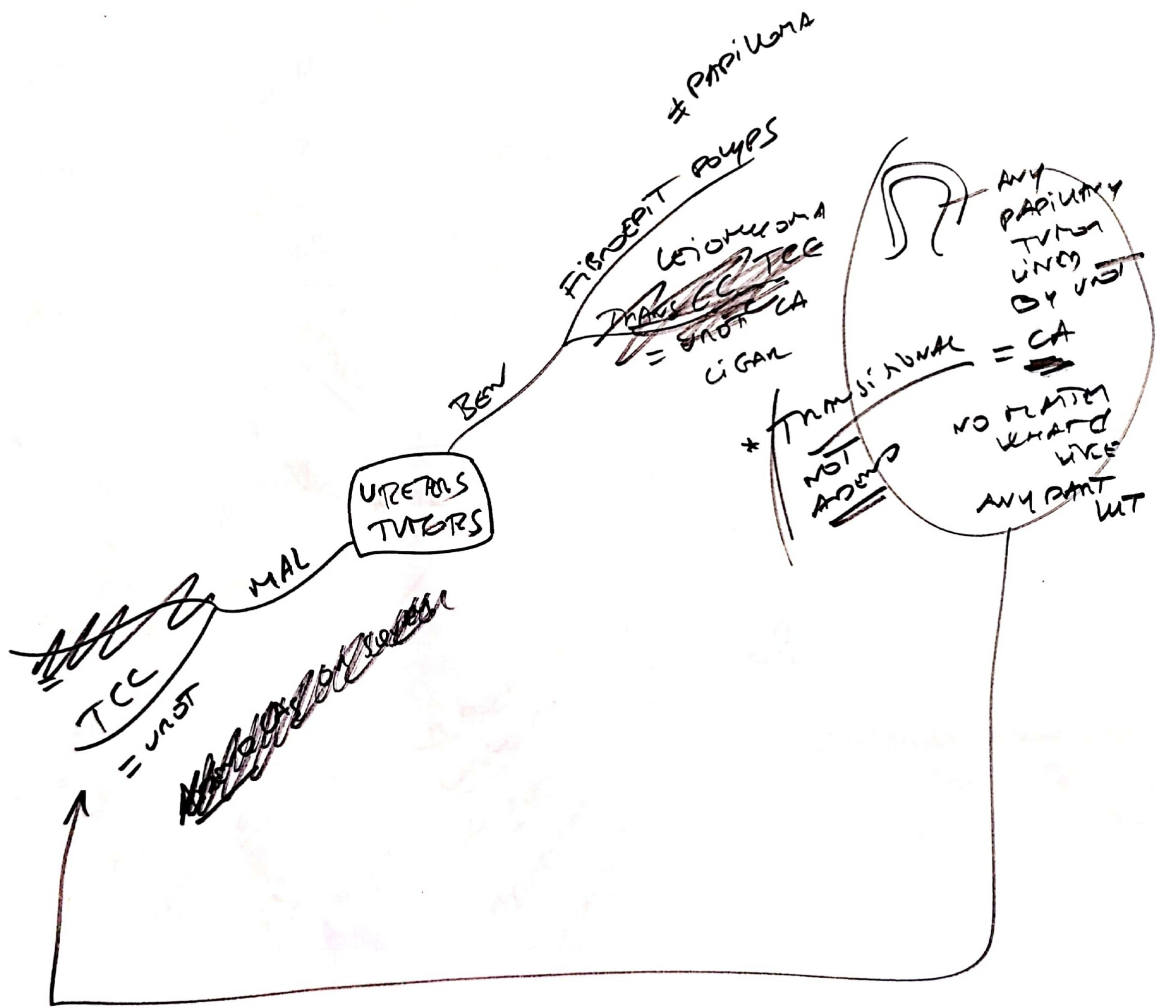
SCISSORIFORM  
HOMOGENEOUS  
HIGH FAT CIS  
NON INVASIVE  
PAPILARY  
PREC

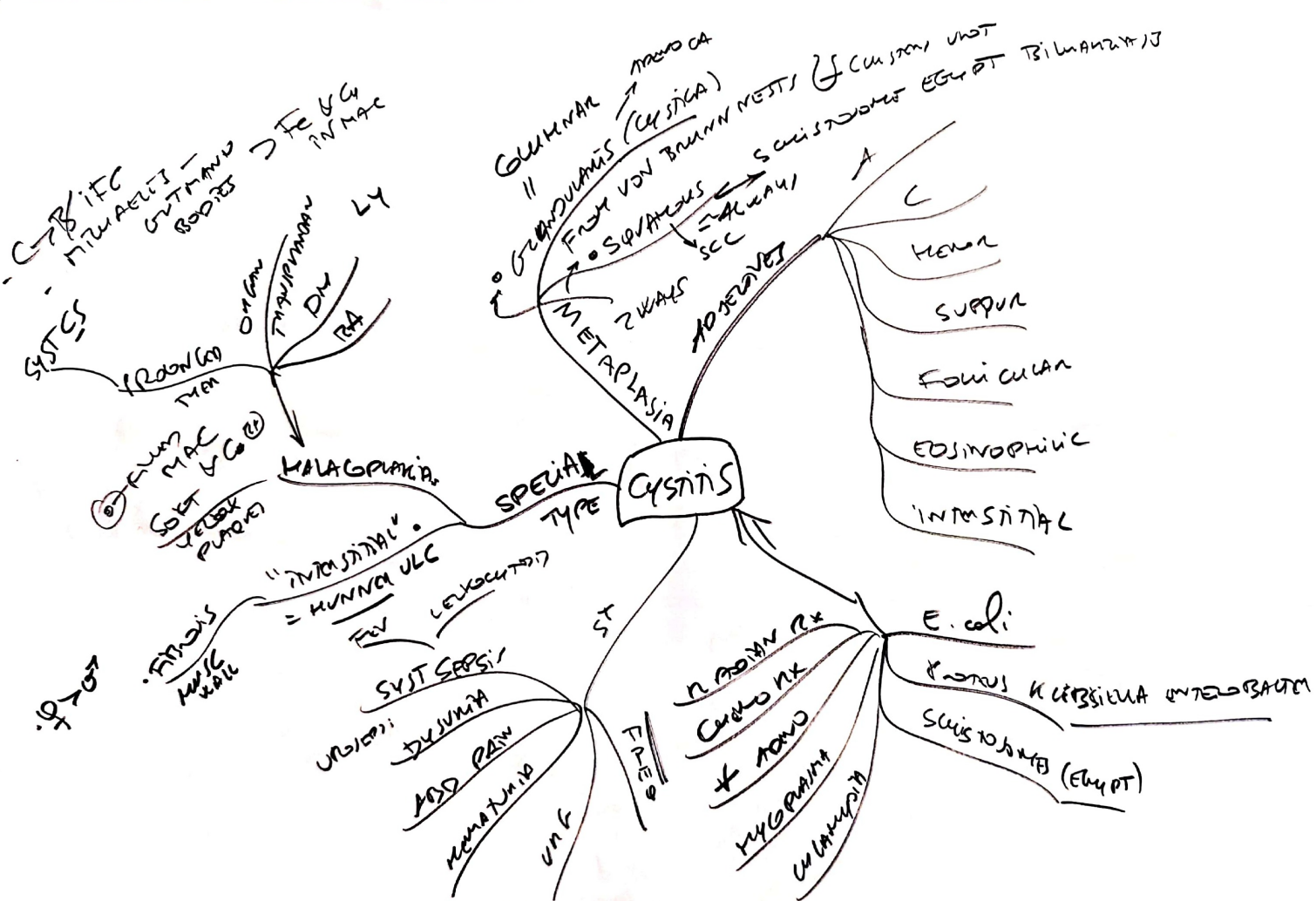EPIDERMAL

UROTHELIAL

UROTHELIAL  
UROTHELIAL  
UROTHELIAL

UROTHELIAL  
UROTHELIAL  
UROTHELIAL





TUBULAR GLANDS

PAPILLARY  
UJOT  
NEED  
LOW  
MALIGNANCY  
POT

COLICAMP  
HIGH  
TCC  
TCC

85% EPIT (UJOT)  
50% PRESENCE → METAPLASM  
JUSTY SM

TUMOR (MIAL)

1% UJOT or TRANS

FEW SQUAM ← METAP

FEW ADENOCAS ← GLANDULAR METAP

PAPILLOMAS  
VS  
CAS

TUBULAR GLANDS

MC NSAIDS  
NSAIDS

ULCEROPATHY  
RADIATION  
CUCURBIT  
LONG STANDING  
ANALGETIC  
ANALGETIC  
NSAID-PIARY  
DRUGS  
SCHISTOSOMIASIS

CAUSE / RISK TCC  
F

CIGARETTES  
MAY CAUSE (ANILINE DYE)

TCC

MULTIPLE  
"SOIL THEORY"

PAPILLOMAS VS CAS

SHAPING WEN  
I I I I I

RULE

PAPILLOMAS  
CANCER  
ON POT  
CANCER


STAGING  
TUM

BIOPTIM

NOT ONLY  
BASED  
ON ANAT

SQUAMOUS PAPILLOMA  
VIA

PAPILLOMA → CARCINOMA



TNM

- EX T<sub>0</sub> NON INV ORAL  
T<sub>1</sub> CIS FLAT  
T<sub>1</sub> LP  
T<sub>2</sub> MP  
T<sub>3a</sub> MICROSCOPIC BILAMINAR ULC  
T<sub>3b</sub> GROSSLY  
T<sub>4</sub> INVADES

