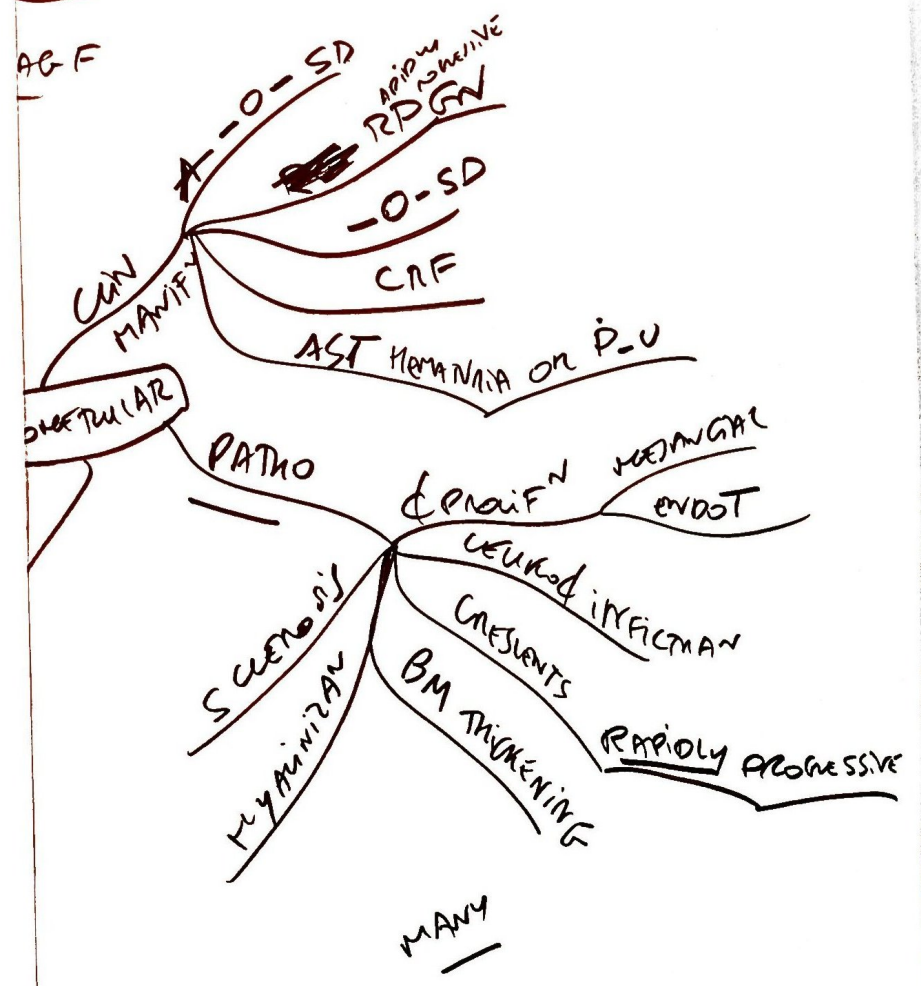
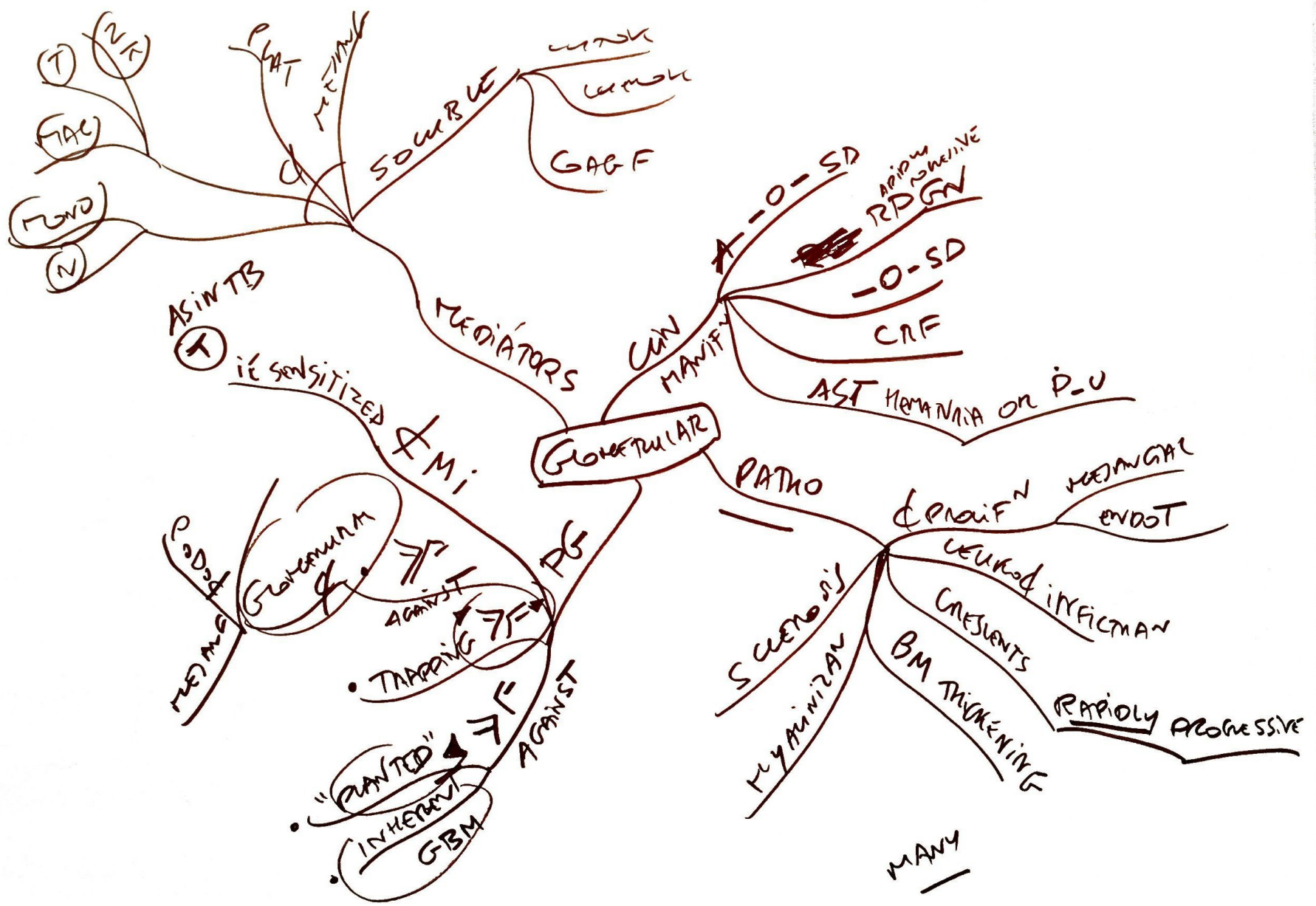
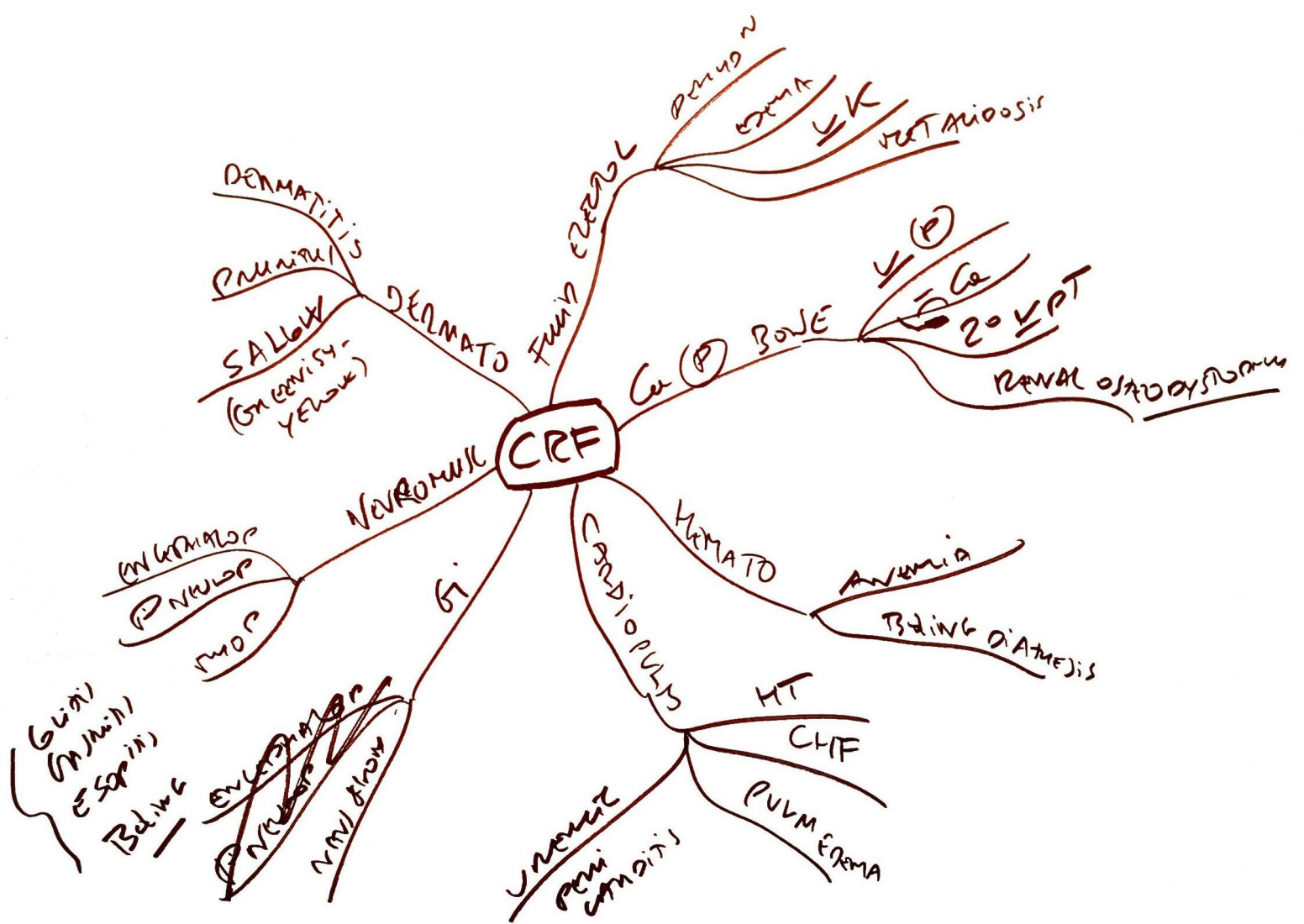


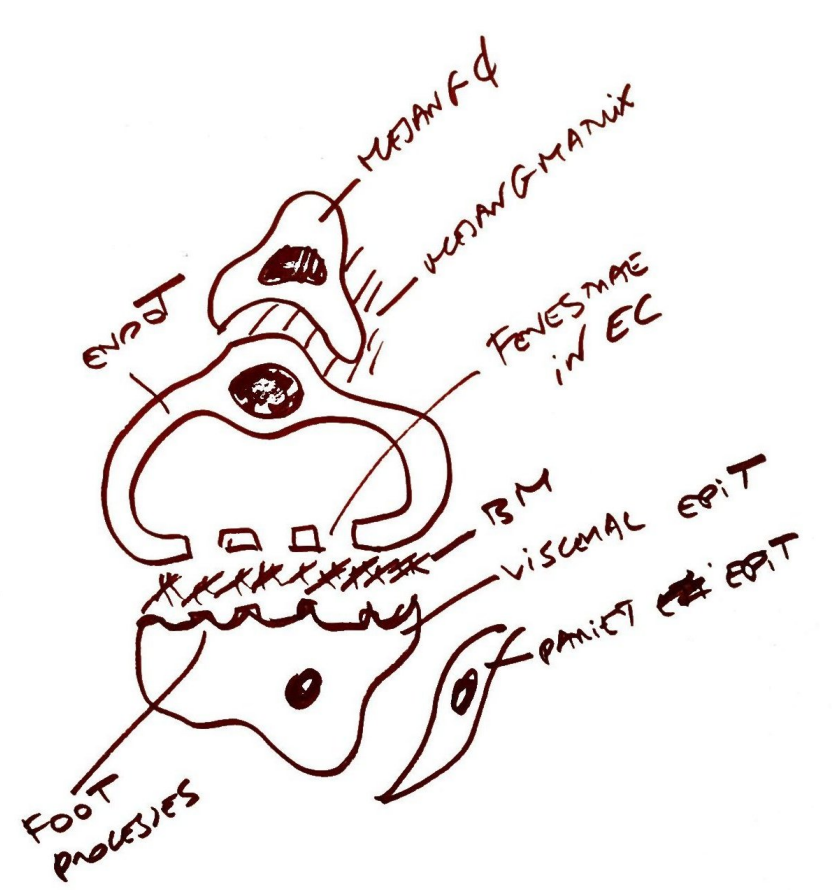
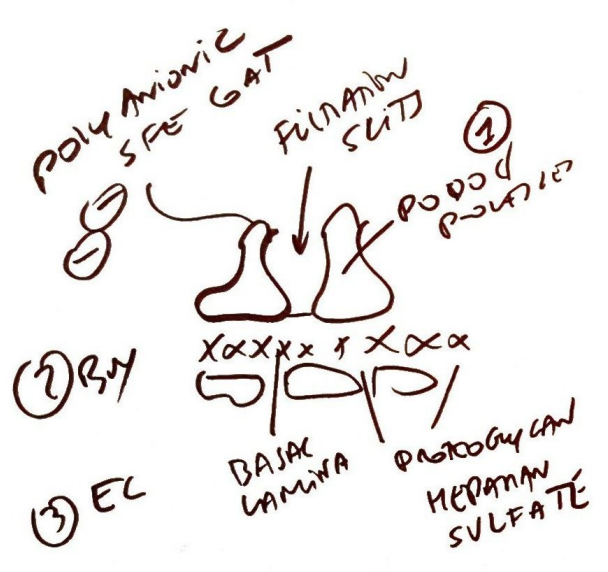
NSK
URINE
AGF

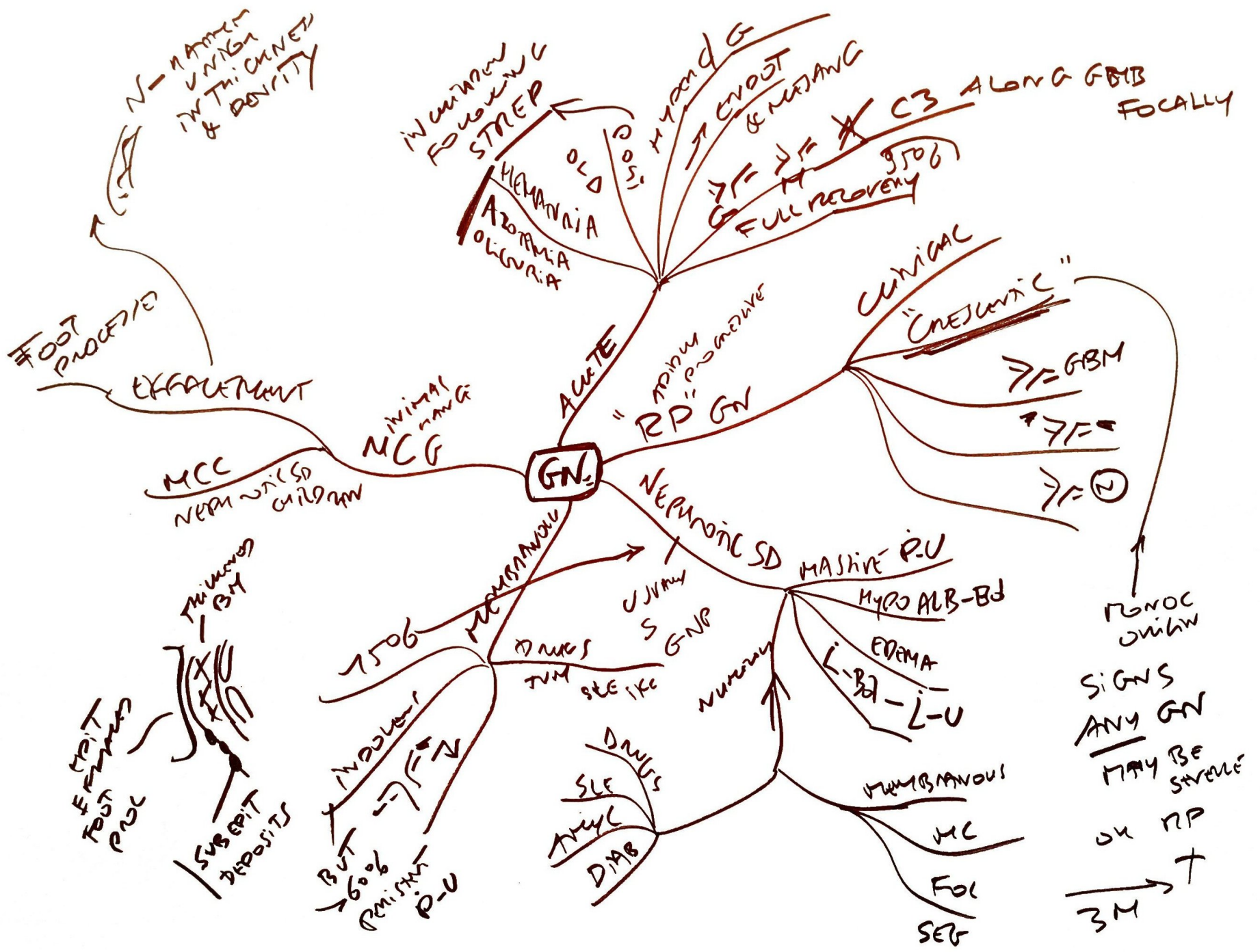


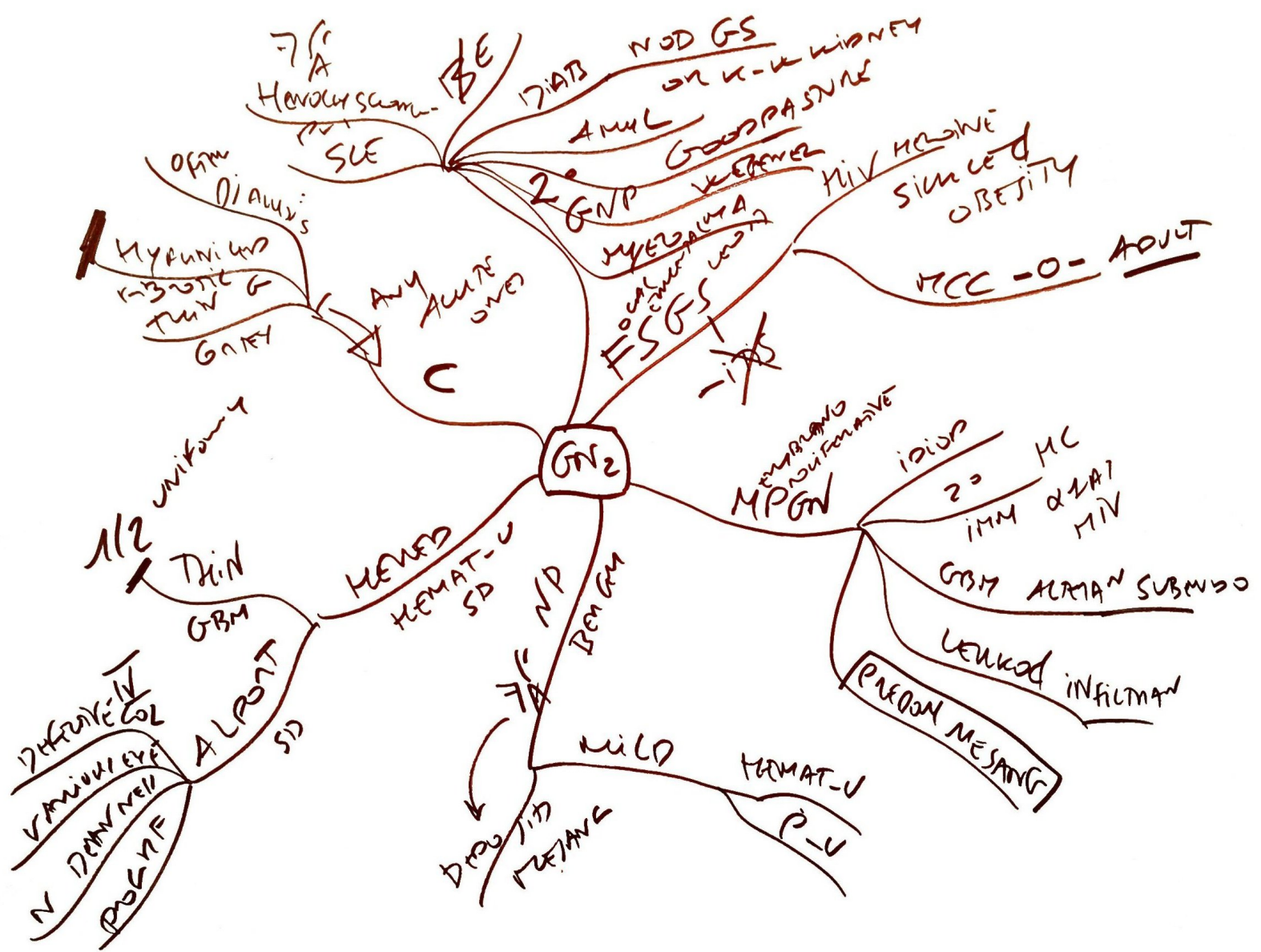
KIDNEY

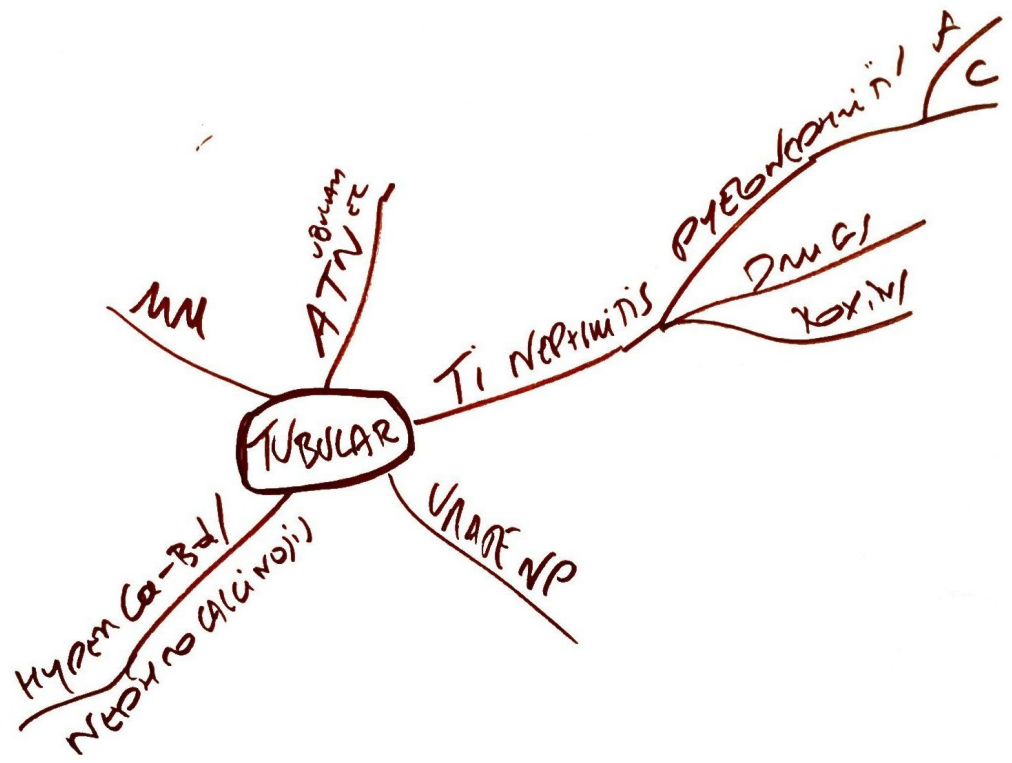


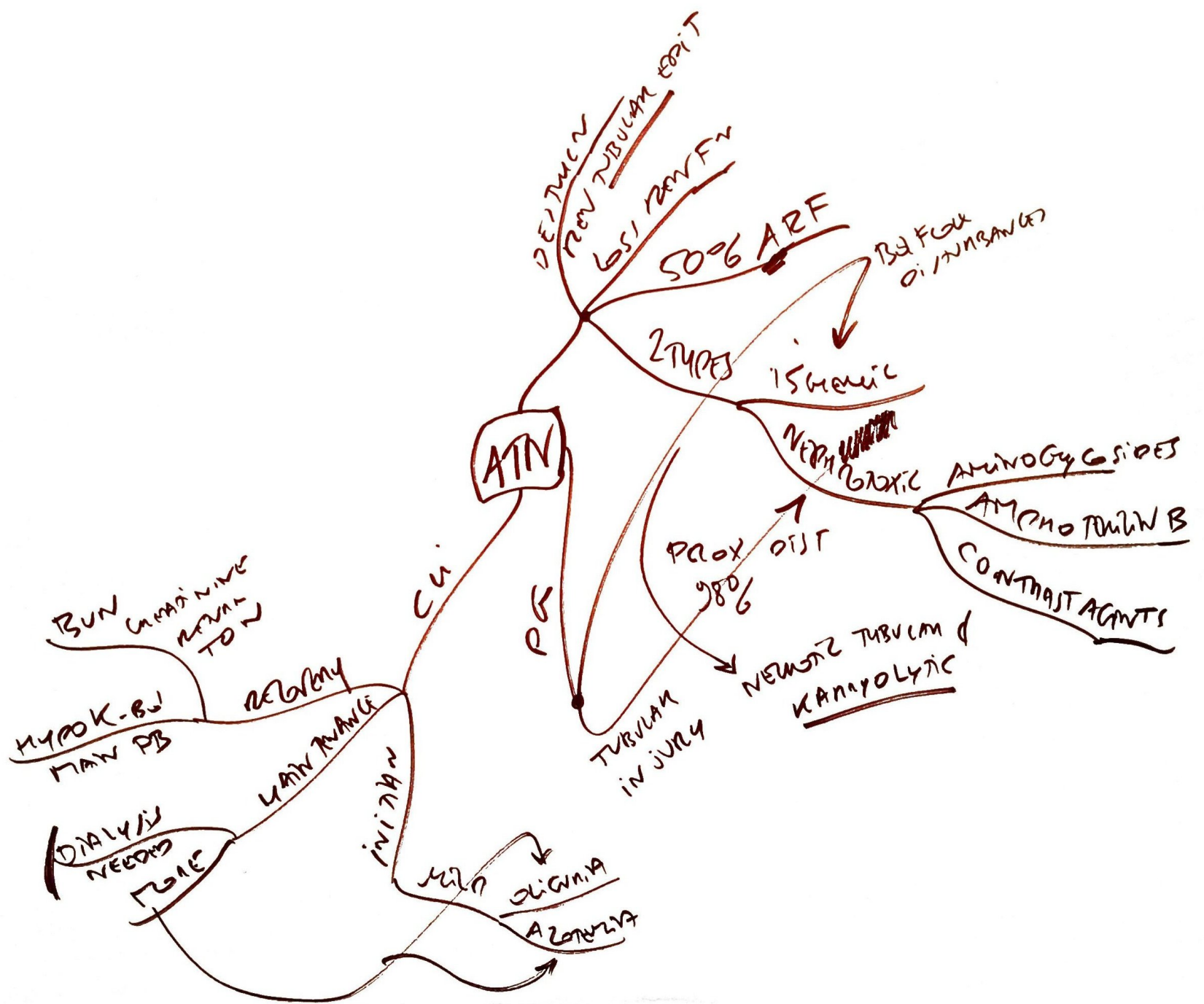

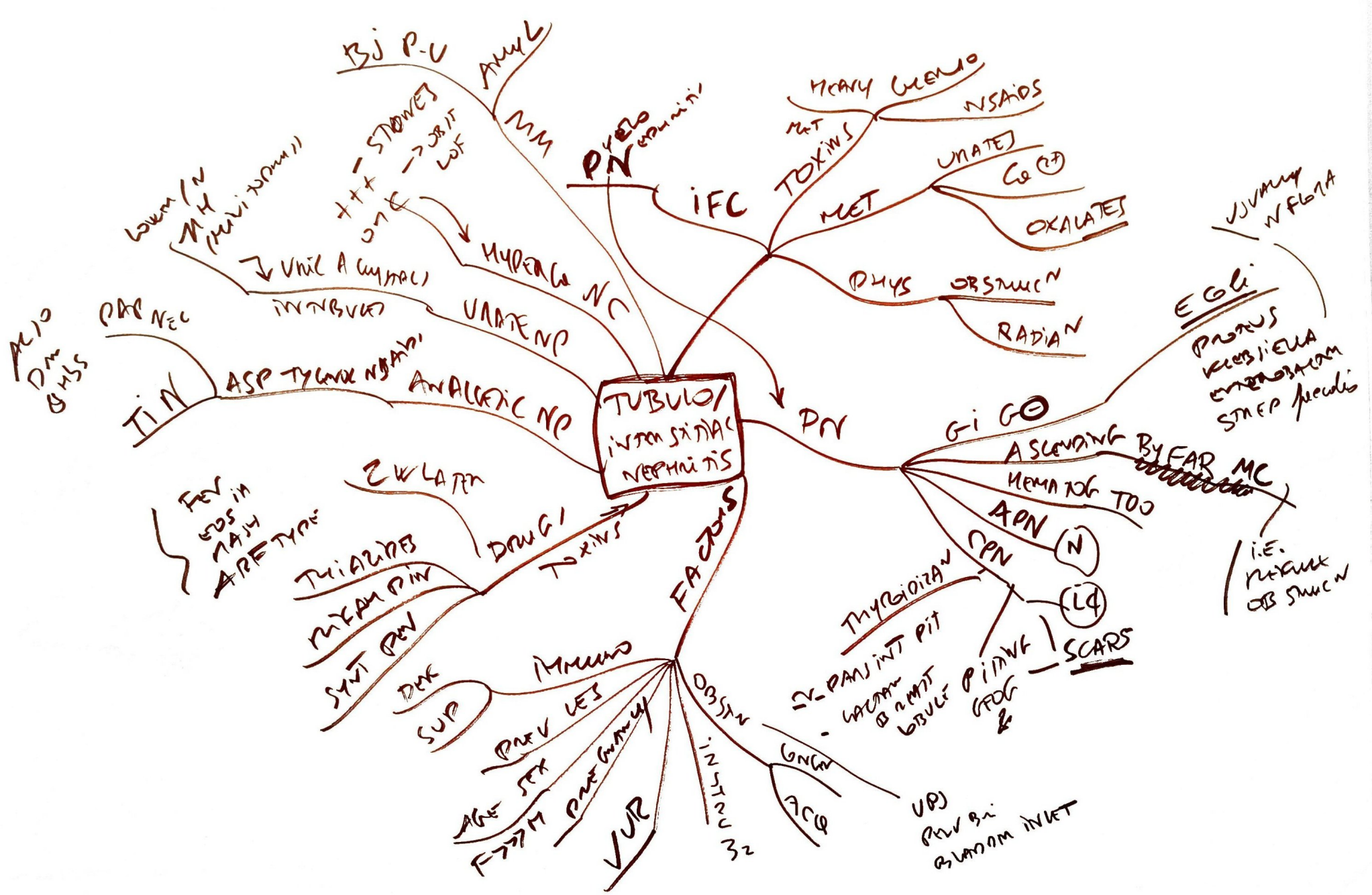












VASCULAR

ALL TO VASC
O → MIGHT

HYPERLIPIDEMIA
AA & SIALIC ACID
PANT ROUTINE AMENOS
A
VERY VERY VERY GM

ARTERIO 6-

NEPHROSCLEROSIS
MAL = MAL HT

NOT
RAPIDLY PROG HT 1-2° HTN
BY DEF
VASC DAM
FIBRINOID NEC
"MIBW SKINNING"
SILMI FILM WM NARROWING

RARE HTN
SMALL KIDNEY

PLAQUE
JUVENILE
NEW OR
OLD AMENOS

FMD

YOUNG
A ♀
M ♀

THROMBOTIC
MICROANGIOP
- MUS
CHILD ADULT

MULT
CNS
PAIN

TRIMBI
EMBOLI
INFARCTS

SPAIN
- FIBRIN PLUGS
- THROMBOCYTOP
- GAG PAT
- TOXIC FOR CAP
- HEMOLYSIS

OTHER VASC
- AMENOS
- SILK E &
- DCN
- RARE
- JUVENILE
- TWICE

GLAT
CINCH

ANEMIC
WHITE

PERMI
VITRE
HELOX

WELL DELIMITED
WEDGE SHAPED
MEM
SCAN

