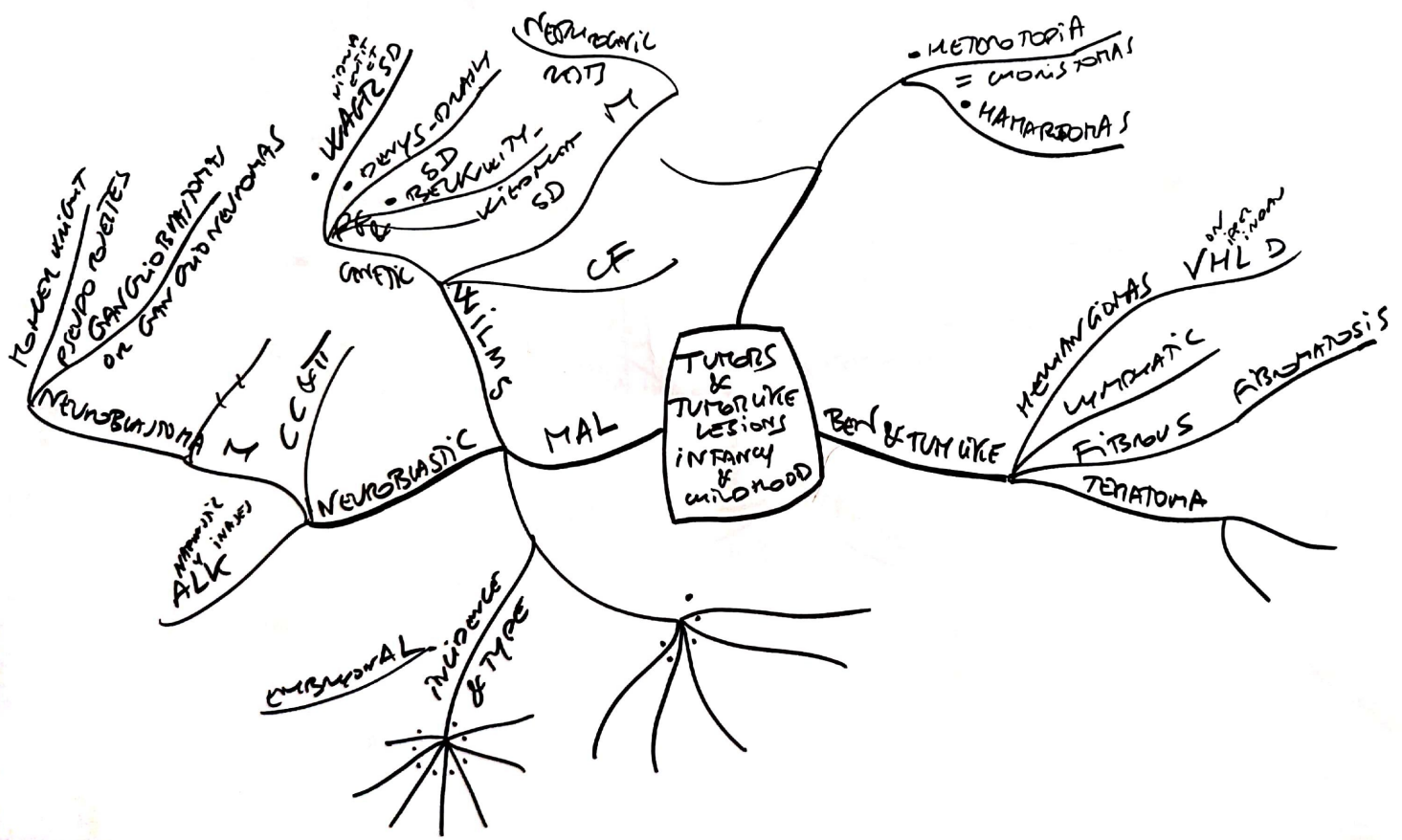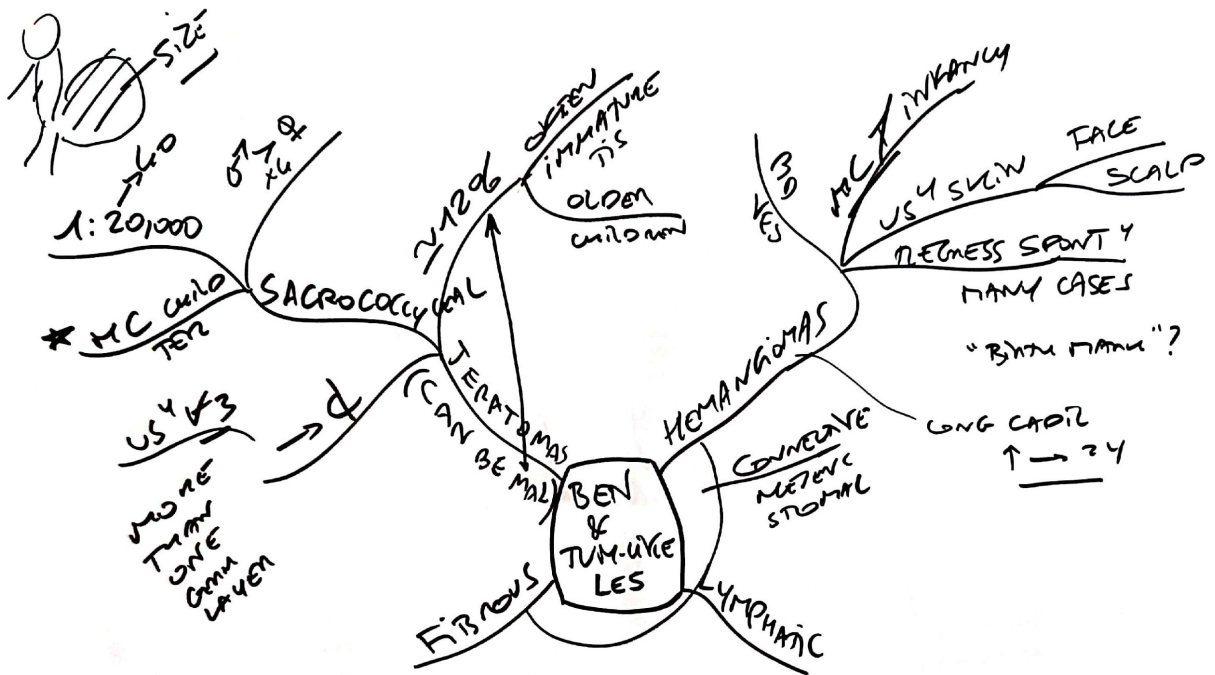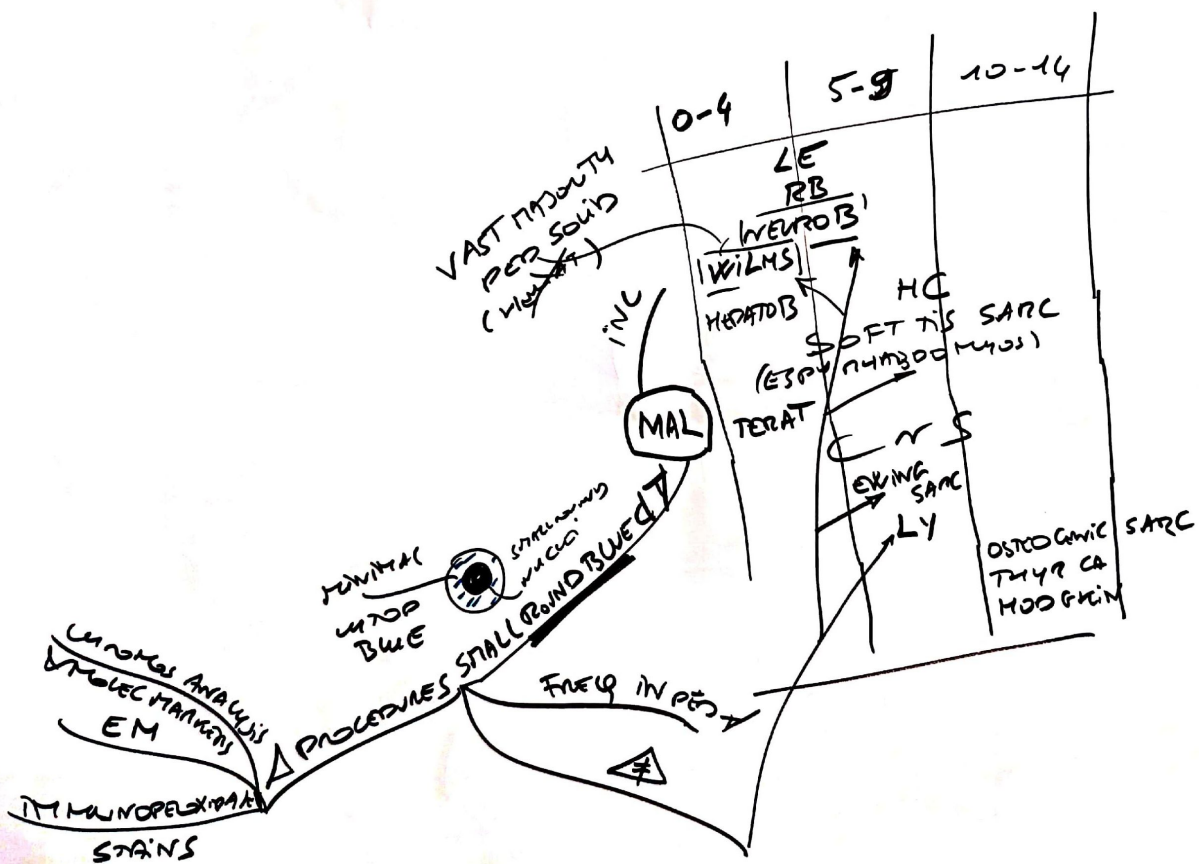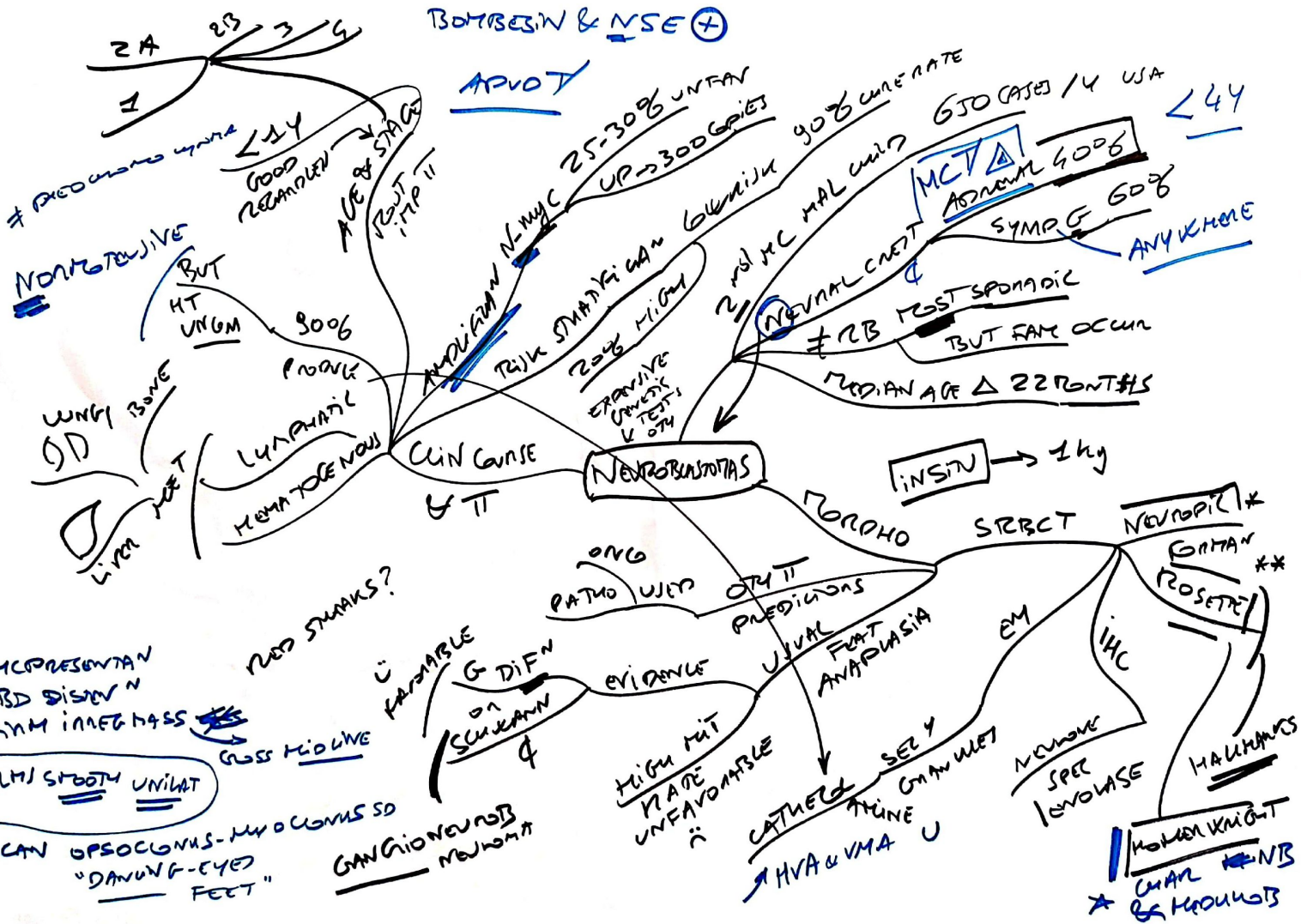


BOMBSIN & MSE (+)



2A 2B 3 4
 ≠ PROGNOSIS UNFAV
 GOOD RELAPSE
 AGE & STAGE
 POST-OP II

NONTREXIVE
 BUT
 HT
 UNGM
 8006
 PROGN
 LYMPHATIC
 HEMATOGENOUS
 WING BONE SD
 LIVER
 MET

RED STUMPS?
 MCDRESORTAN
 ABSD DISTEN N
 TUM INREG MASS
 WILMS SYNDROM UNILAT
 CAN OPSOCOMUS-MYOCLONUS SD
 "DANUNG-EYED FEET"
 GANGLIONEVROB
 NEURONIA

APVOT
 AMPLIFIKAN N-MYC
 25-30% UNFAN
 UP 300 GPIS
 TUMOR SUPRACRANIAL
 60% MLOM
 ERANJIVE
 UPREK
 TESTIS
 K OTH
 2% MCL MAL UNID
 90% CURE RATE
 MCTV
 ABNORMAL 4006
 SYMPT 60%
 ANYWHERE
 MEDIAN AGE Δ 22 MONTHS
 ≠ RB
 POST SPORADIC
 BUT FARE OCCUR

NEUROBLASTOMA
 MORPHO
 INSITU → 1kg
 STRCT
 EM
 IHC
 NEUROPIK
 GIRIAN
 ROSETTE
 HALLMARKS
 MONOKLONAL
 CHAR
 NEURIS
 KROUNTS
 EVIDENCE
 HIGH MIT
 MADE
 UNFAVORABLE
 CATHETER
 THINE
 HVA & VMA
 SER 4
 GAMMALET
 NEURON
 SPER
 LEWYASE

PATNO
 ONG
 UJER
 OTY II
 PREDICTIONS
 UJUAL
 FURT
 ANAPLASIA

