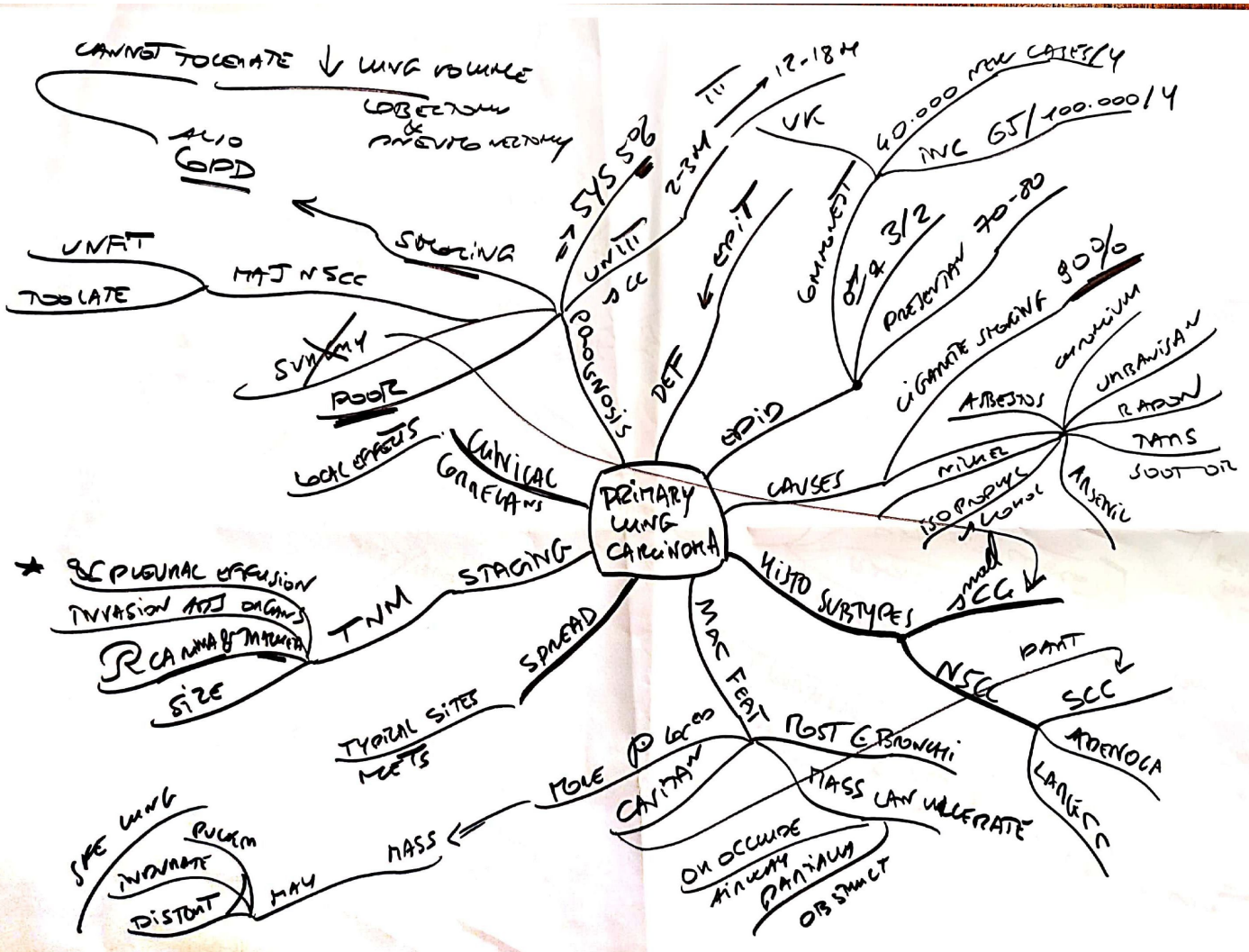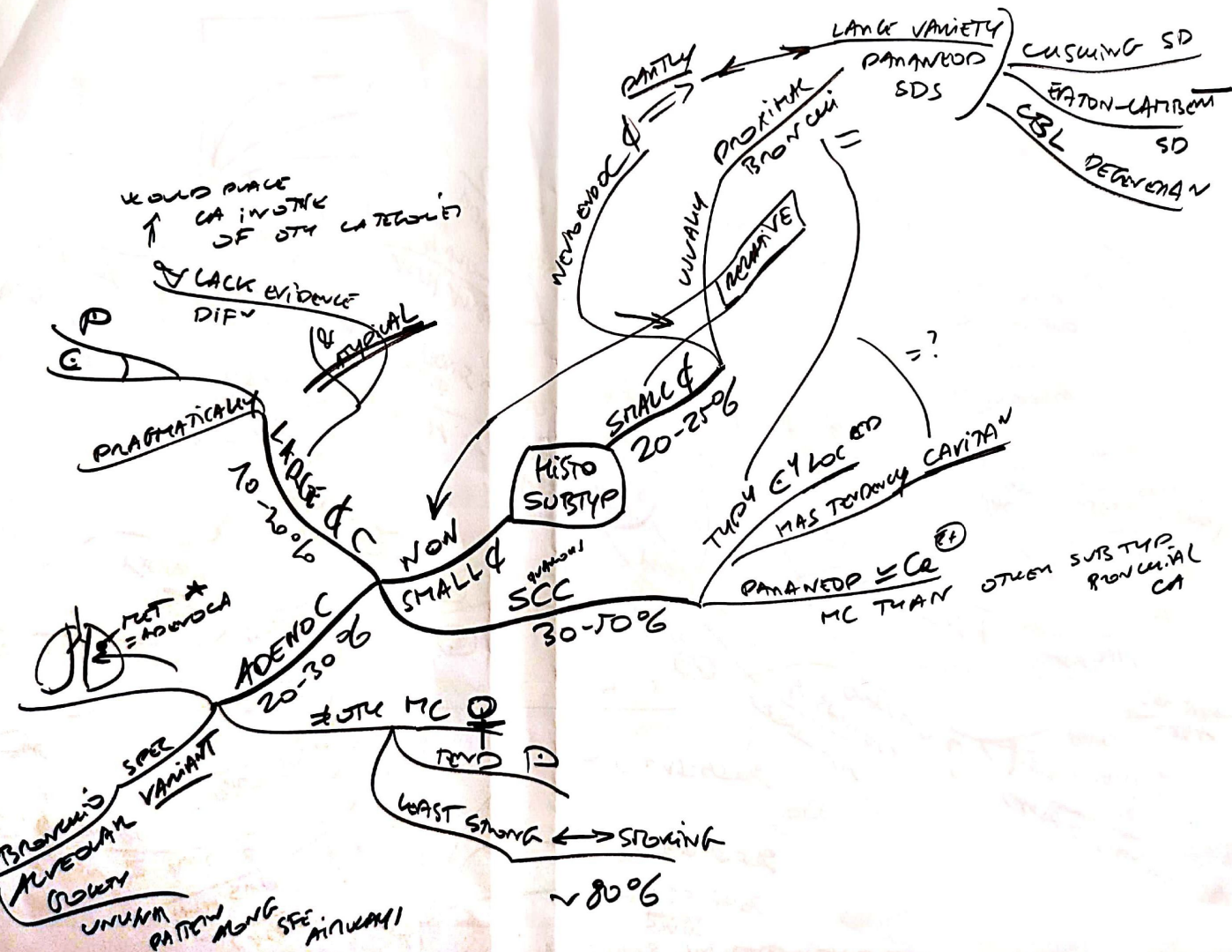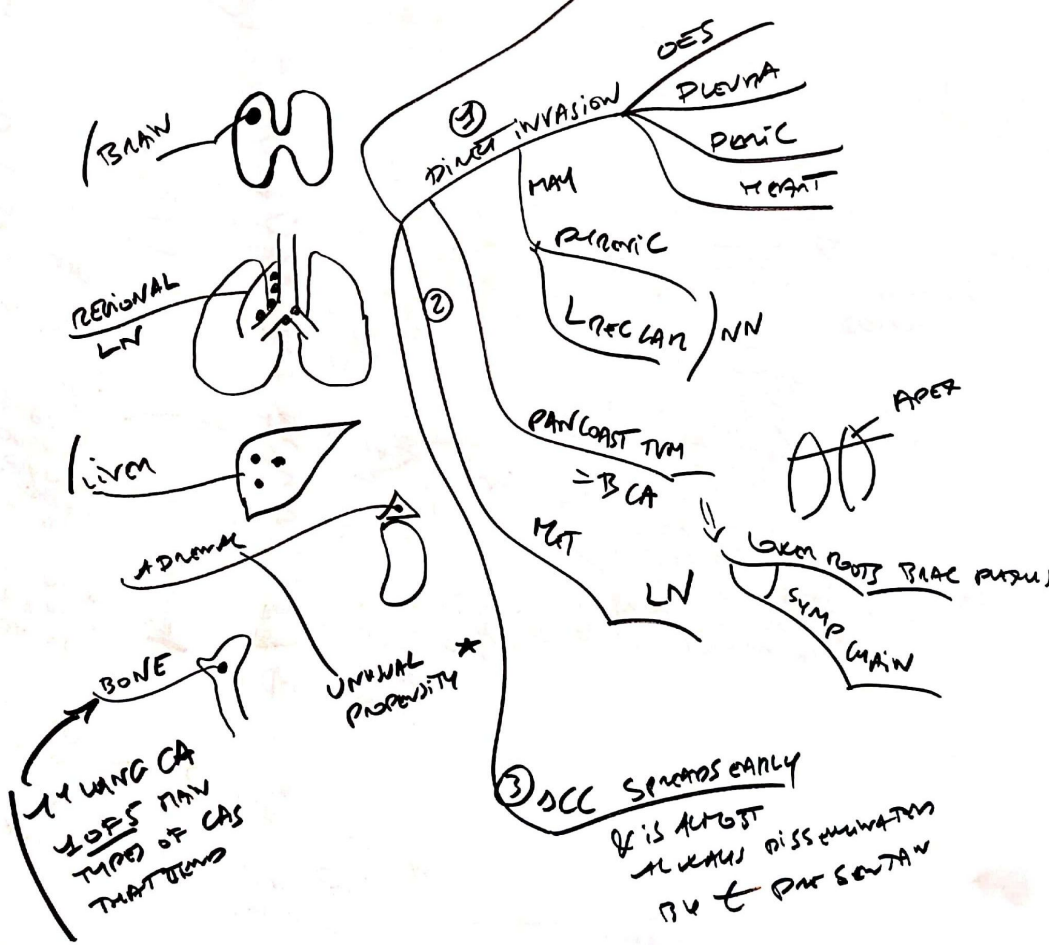
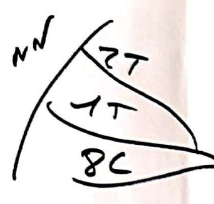


SPREAD  
TYPICAL SITES METS




Clinical Correlates  
Local Effects

Shoulder Pain  
↓  
Radiating in an ulnar distribution  
Down arm  
= Pancoast SD

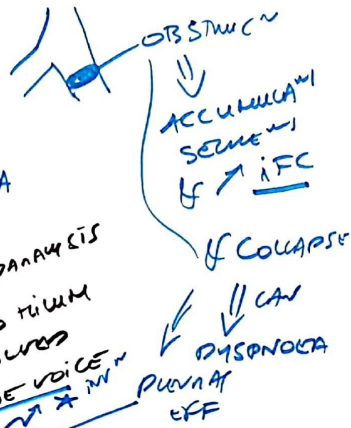

Pancoast T1  
Apical



⇒ Hemoptysis  
⇒ Dysphagia

Local Pain  
⇒ Vocal cord paralysis  
⇒ Runs close to trachea  
& can be involved  
⇒ Hoarse voice



Obstruction  
↓  
Accumulation of secretions  
& ↑ IFC  
↓  
& Collapse  
↓  
Cyanosis  
↓  
Dyspnoea  
↓  
Pulmonary Eff

Prevents venous return  
From upper body

SVC Obstruction

Can encase aortic vessels + great vessels opening over chest wall, sometimes herniate

Invasion LA can be invaded  
⇒ Pericardial effusion ⇒ Cardiac tamponade  
⇒ ST elevation  
⇒ AF  
Chest X-ray

Paravertebral  
Pain ⇒ Unilateral  
paralysis & raised hemidiaphragm

Symp N infiltration

with ipsilateral face

HORNER SD  
MAY OCCUR

ENDOPHTHALMIC MYOCLONUS  
PTOSIS  
DIPLOPIA  
UPPER EYELID  
MIOSIS (PUPIL CONstriction)  
SWEATING



