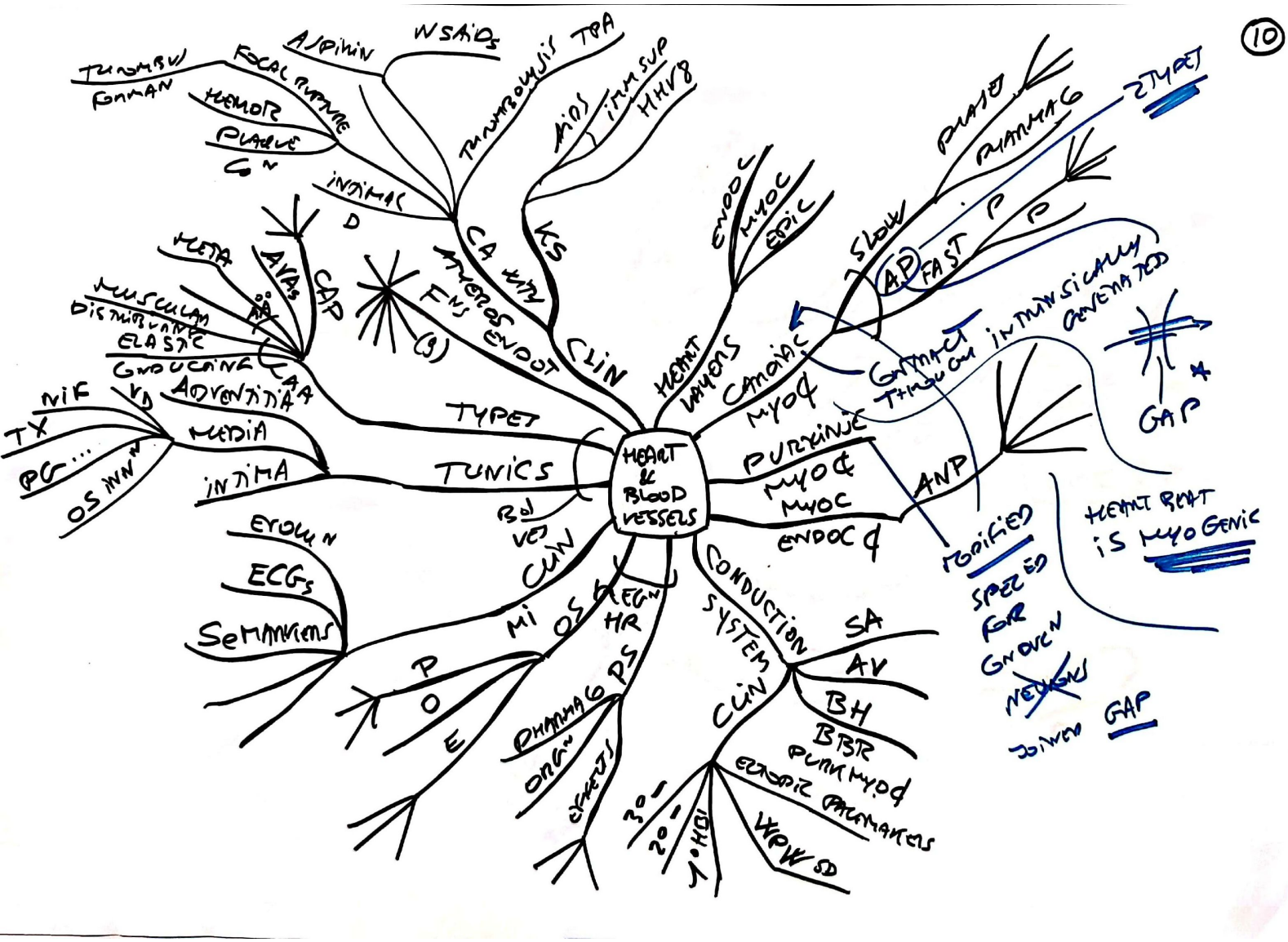

Scanned by CamScanner

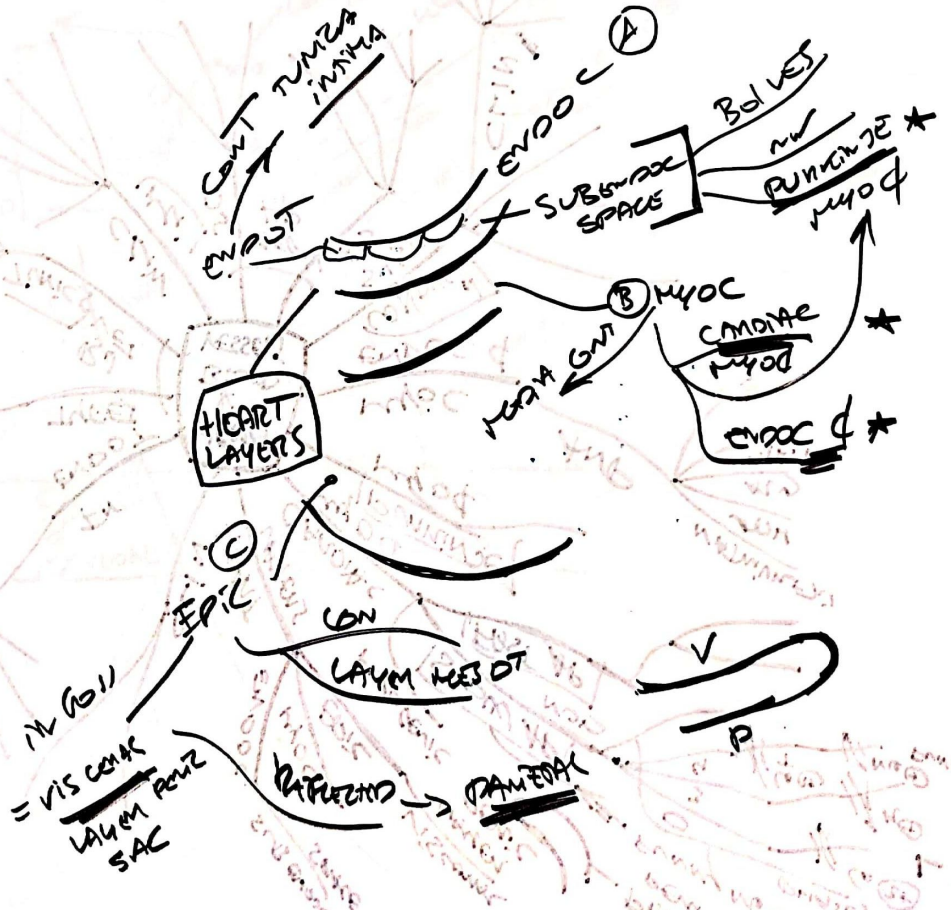

Scanned by CamScanner

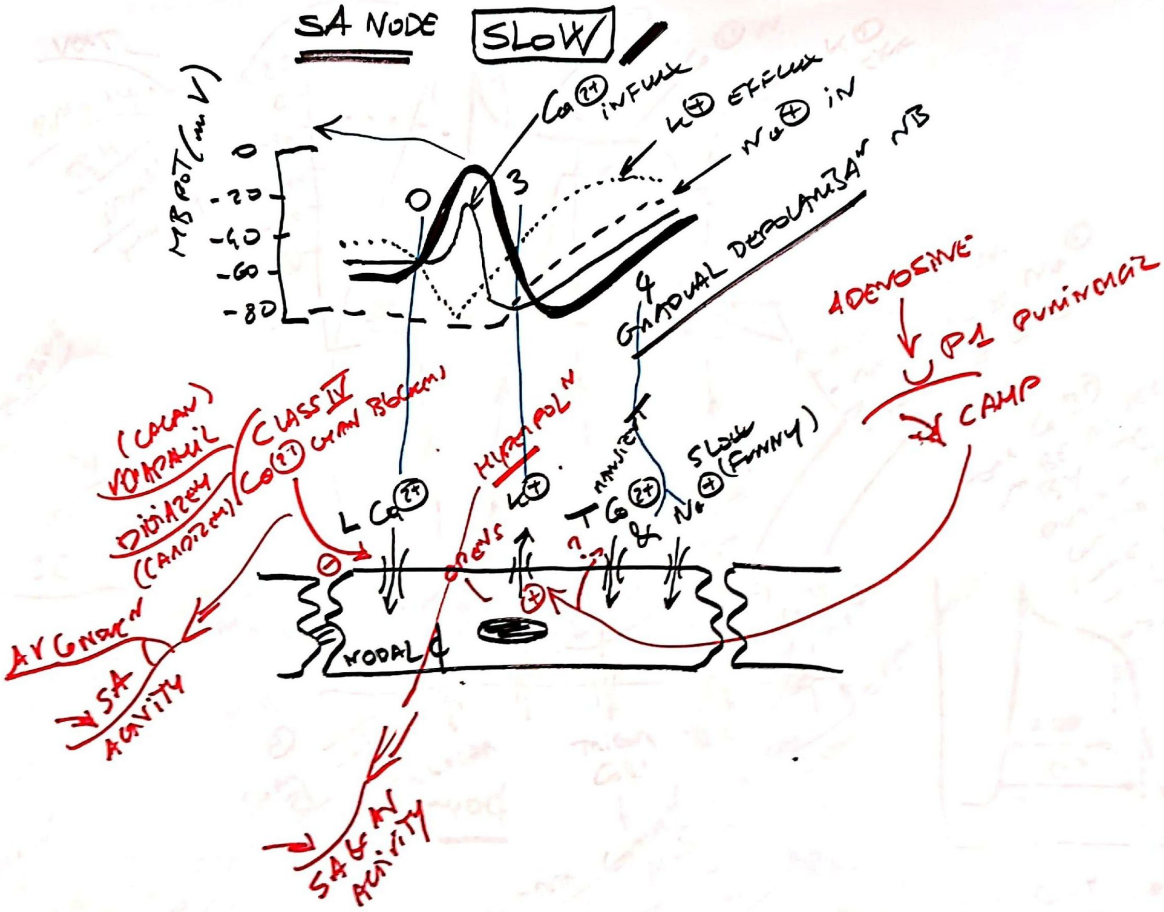

Scanned by CamScanner

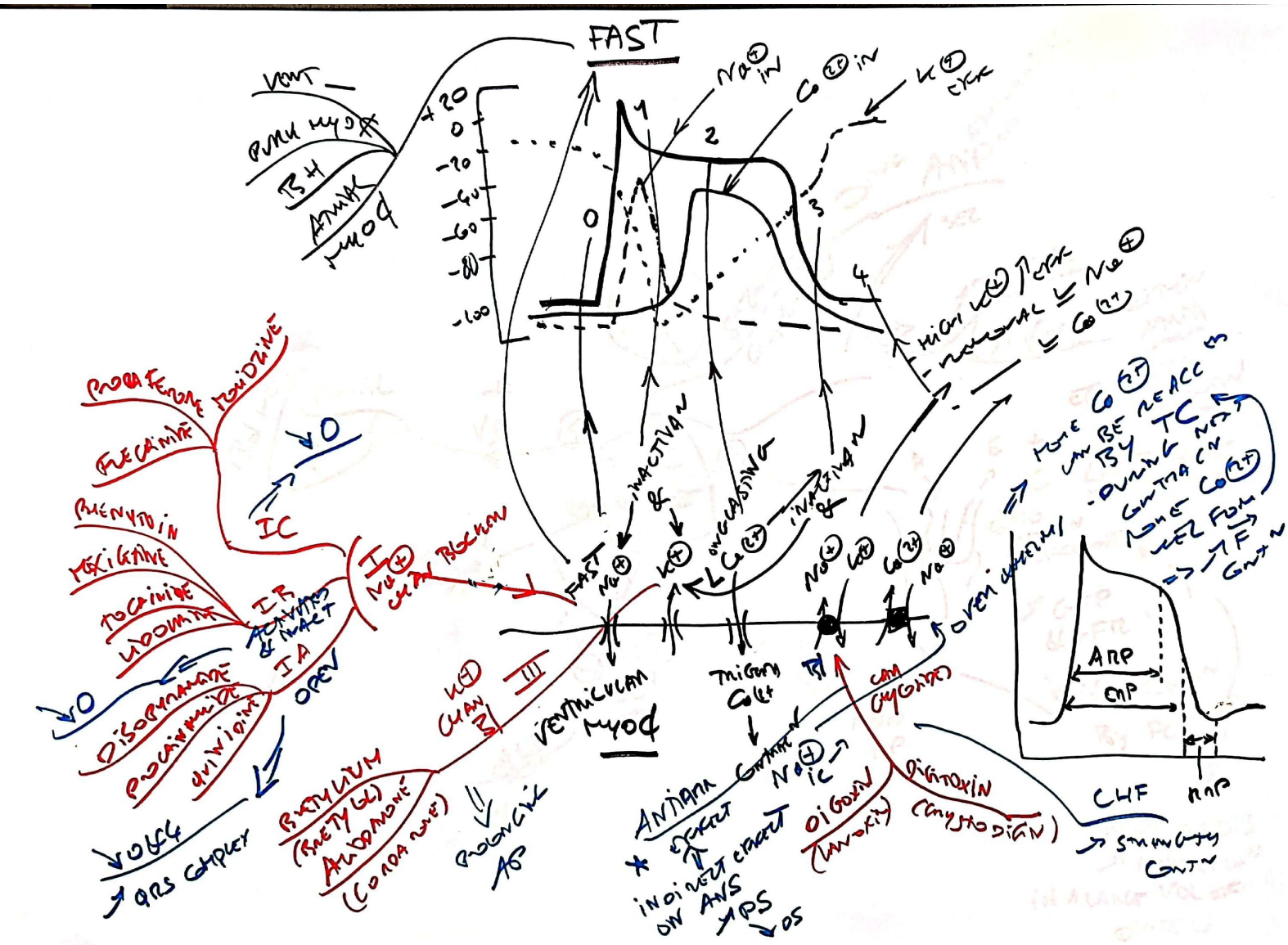

Scanned by CamScanner

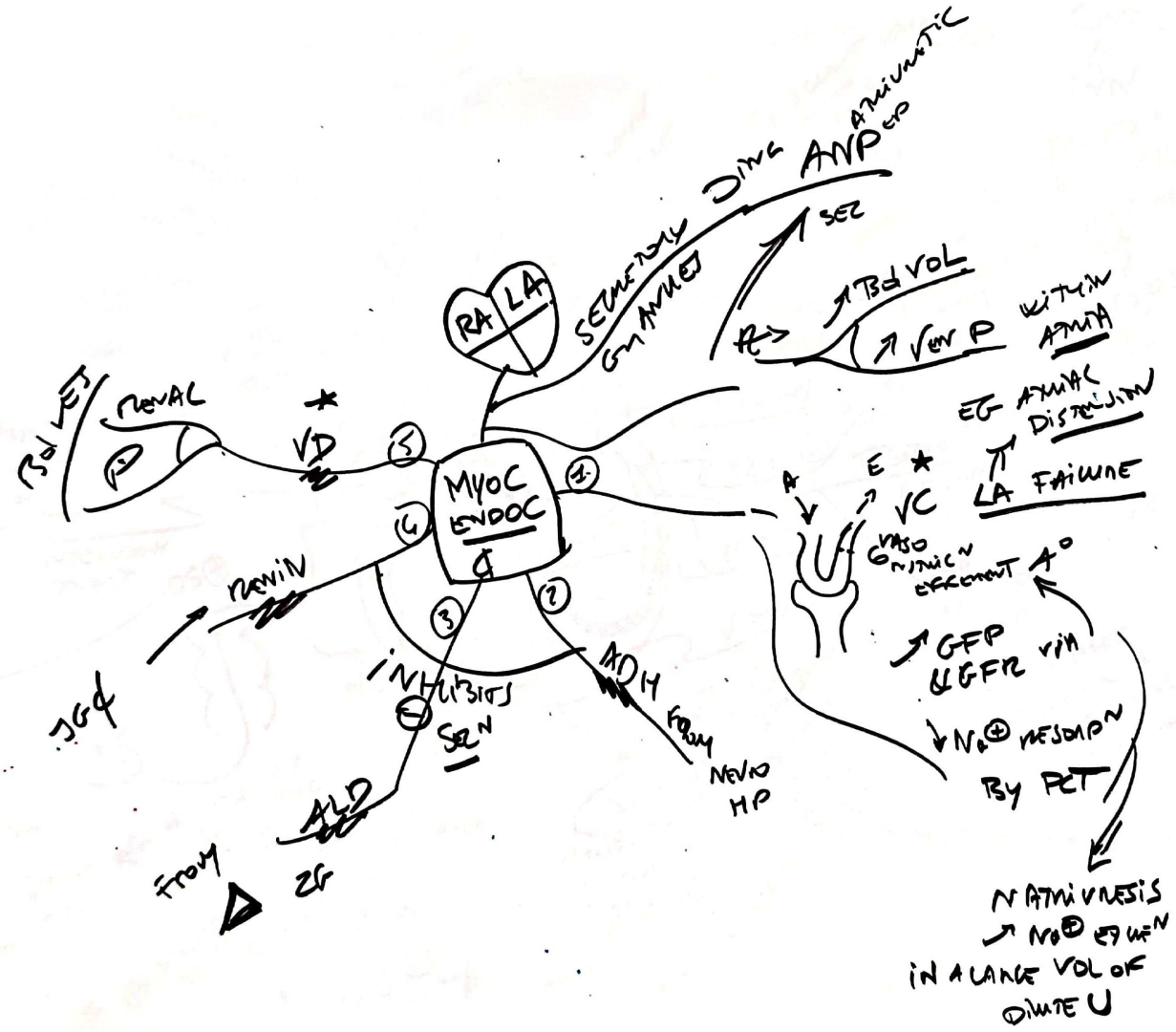

Scanned by CamScanner

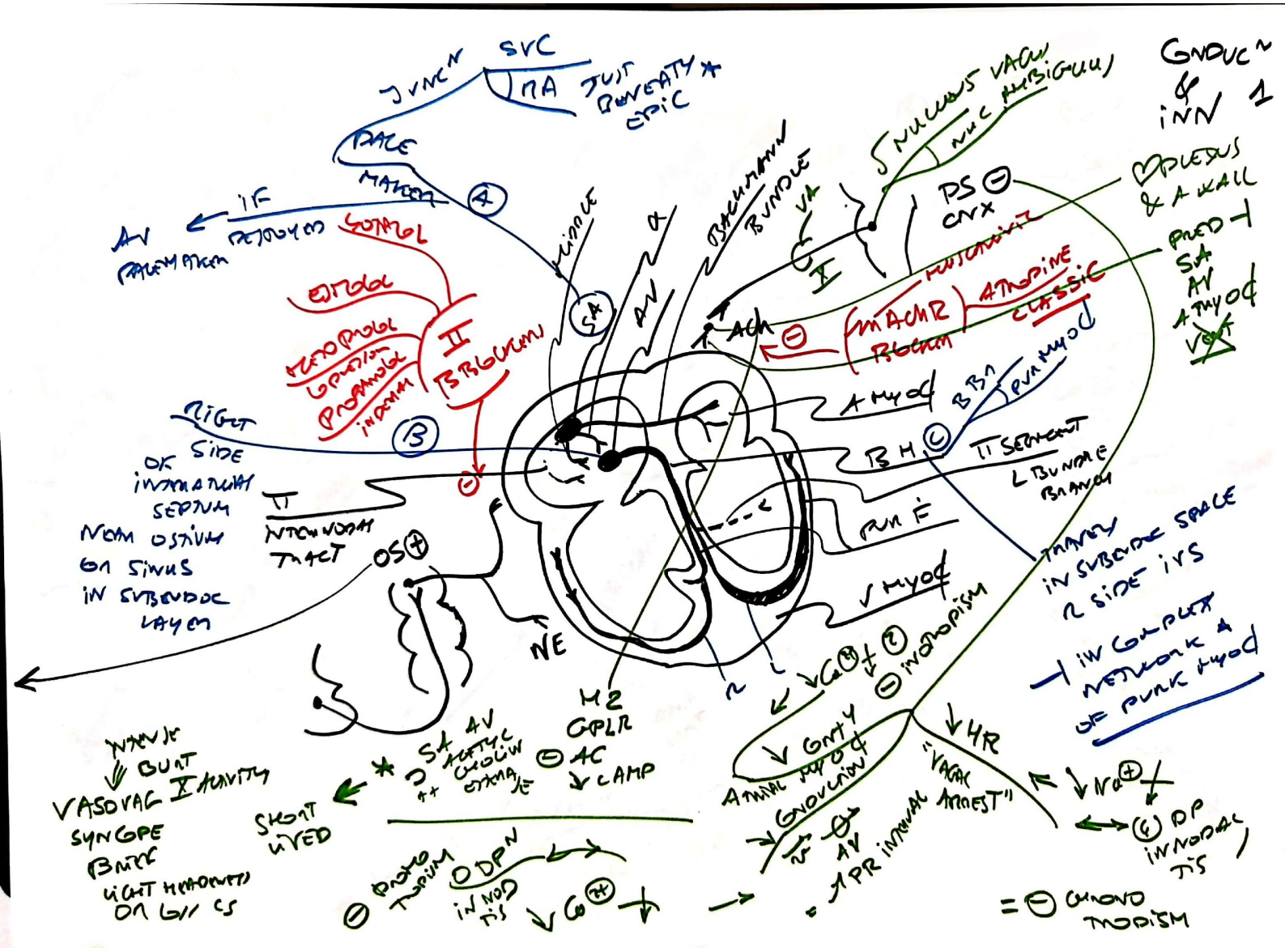
SVC
RA
JUNC^N
JUST BELOW ATRIA EPIC
RACE
MAZE
IF
PACEMAKER
SYMPATHETIC
CONTROL
II
β BLOCKERS
NODAL
PRE-NODAL
OPERATION
PROPANOLOL
INDIAN
RIGHT SIDE
OF INTERATRIAL SEPTUM
NEAR OSTIUM
OF SINUS
IN SUBENDOCARDIAL LAYER
II
INTERNODAL TRACT
OS
NE
SA
AV
BUNDLE
BACHMANN BUNDLE
VA
NUCLEUS VAGUS
NUC AMBIGUUS
GANGLIA
PS
CNX
PLEXUS
& A WALL
PRED
SA
AV
A MYOC
VENT
I
ACh
m ACHR BLOCKER
HYOSCYAMINE
ATROPINE
CLASSIC
A MYOC
BBR
PURKINJE
B H
II SEPTUM
L BUNDLE BRANCH
PUR F
V MYOC
M2
GPLR
AC
↓ CAMP
↓ Ca
↓ GRAD
↓ AUTOMATICITY
↓ HR
"VAGAL ARREST"
↓ Na
↓ DP
IN NODAL TIS
= CHRONOTROPISM
↓ AV
↑ PR INTERVAL
↓ Ca
↓ DPN
IN NOD TIS
PROPRANOLOL
↓ Ca
↓ GRAD
↓ AUTOMATICITY
↓ AV
↑ PR INTERVAL
↓ Na
↓ DP
IN NODAL TIS
↓ HR
↓ Ca
↓ GRAD
↓ AUTOMATICITY
↓ AV
↑ PR INTERVAL
↓ Na
↓ DP
IN NODAL TIS

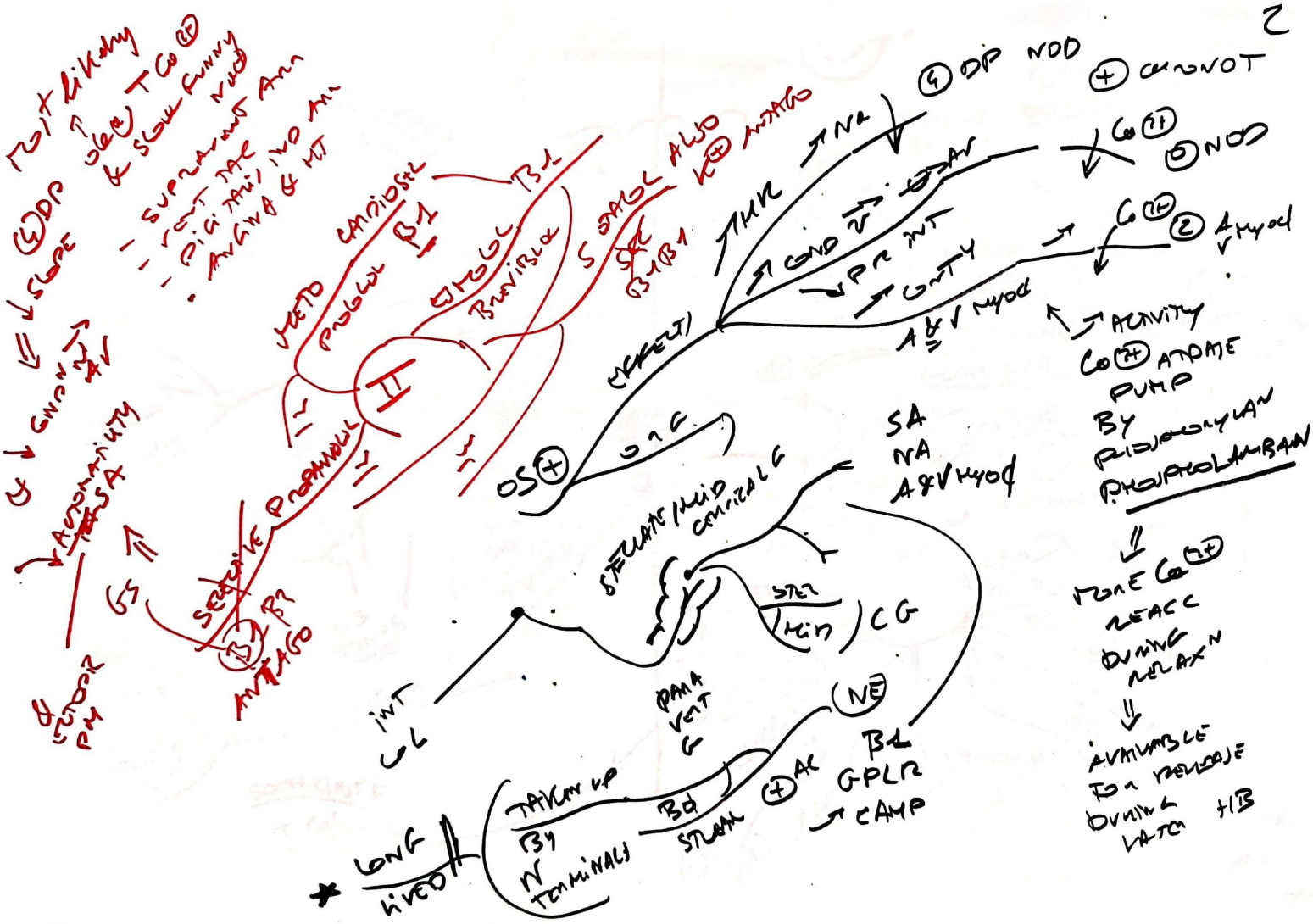

Scanned by CamScanner

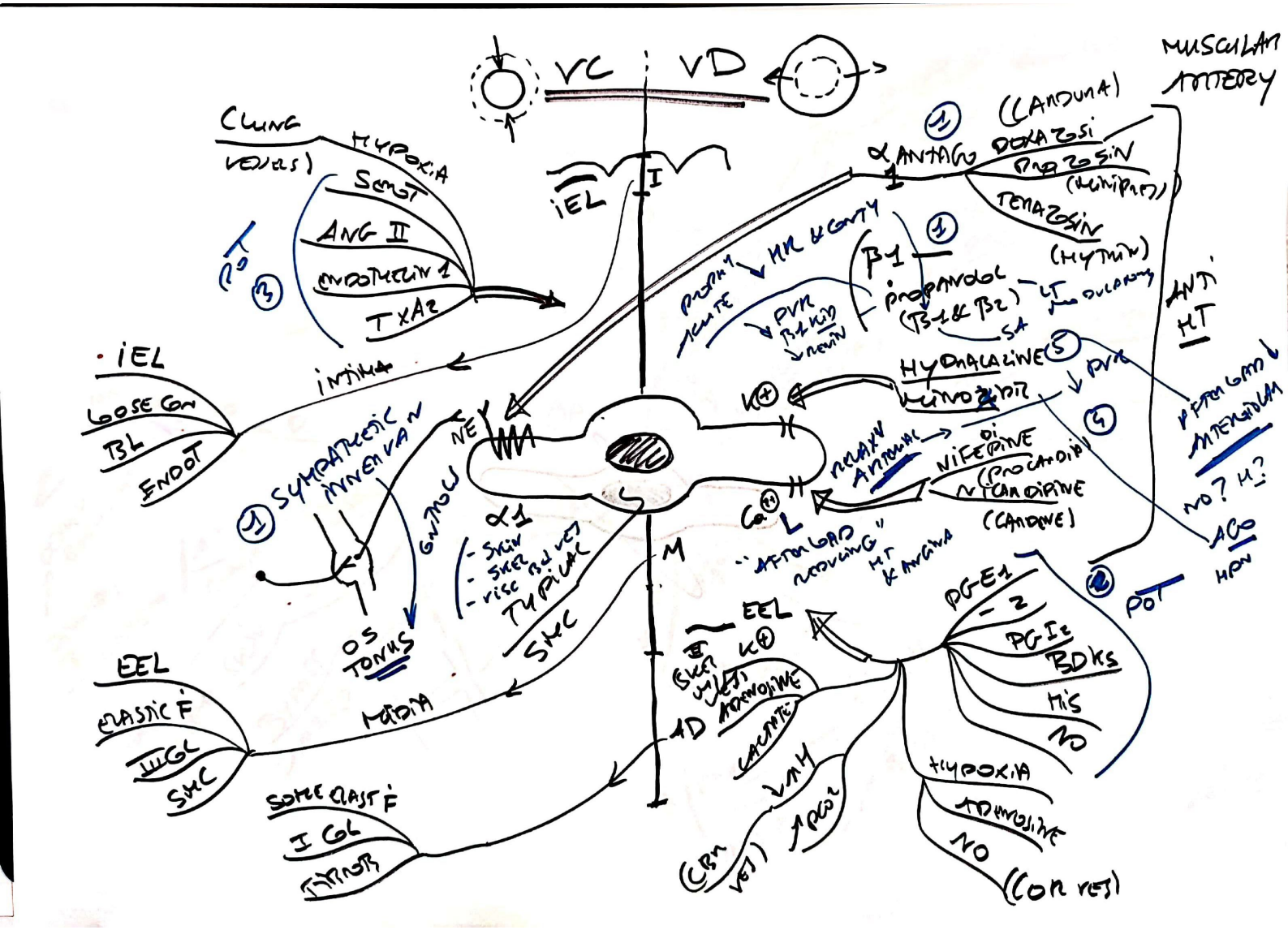
VC
VD
MUSCULAR ARTERY
CLING
VENUS)
HYPOXIA
SEMST
ANG II
ENDOTHELIN 1
TXA2
iEL
I
α ANTAGO
(CLANDINA)
DOXAZOSIN
PRAZOSIN
(MINIPRES)
TERAZOSIN
(HYTRIN)
ANTI HT
β1
PROPANOLOL
(β1 & β2)
SA
HYDRALAZINE
MINOXIDIL
K+
NIFEDIPINE
(PROCARDIA)
NICARDIPINE
(CARDENE)
Ca++
L
"AFTERLOAD REDUCING"
HT & ANGINA
PGE1
PGI2
BDKS
HIS
NO
HYPOXIA
ADENOSINE
NO
(CGMP VEJ)
(CAMP VEJ)
iEL
LOOSE CT
BL
ENDOT
INTIMA
SYMPATHETIC INNERVATION
NE
GANGLIA
OS TONUS
α1
- SKIN
- SKEL
- VISC
TYPICAL
SMC
MEDIA
EEL
ELASTIC F
IIIGL
SMC
SOME ELAST F
I GL
FIBROB
M
EEL
SKEL
K+
D
VASODILATOR
CALCITE
VAH
PGI2
PO
ANTI HT
PATHOLOGY INTERMITTENT
NO? H?
ACO
HPN
POT
Scanned by CamScanner

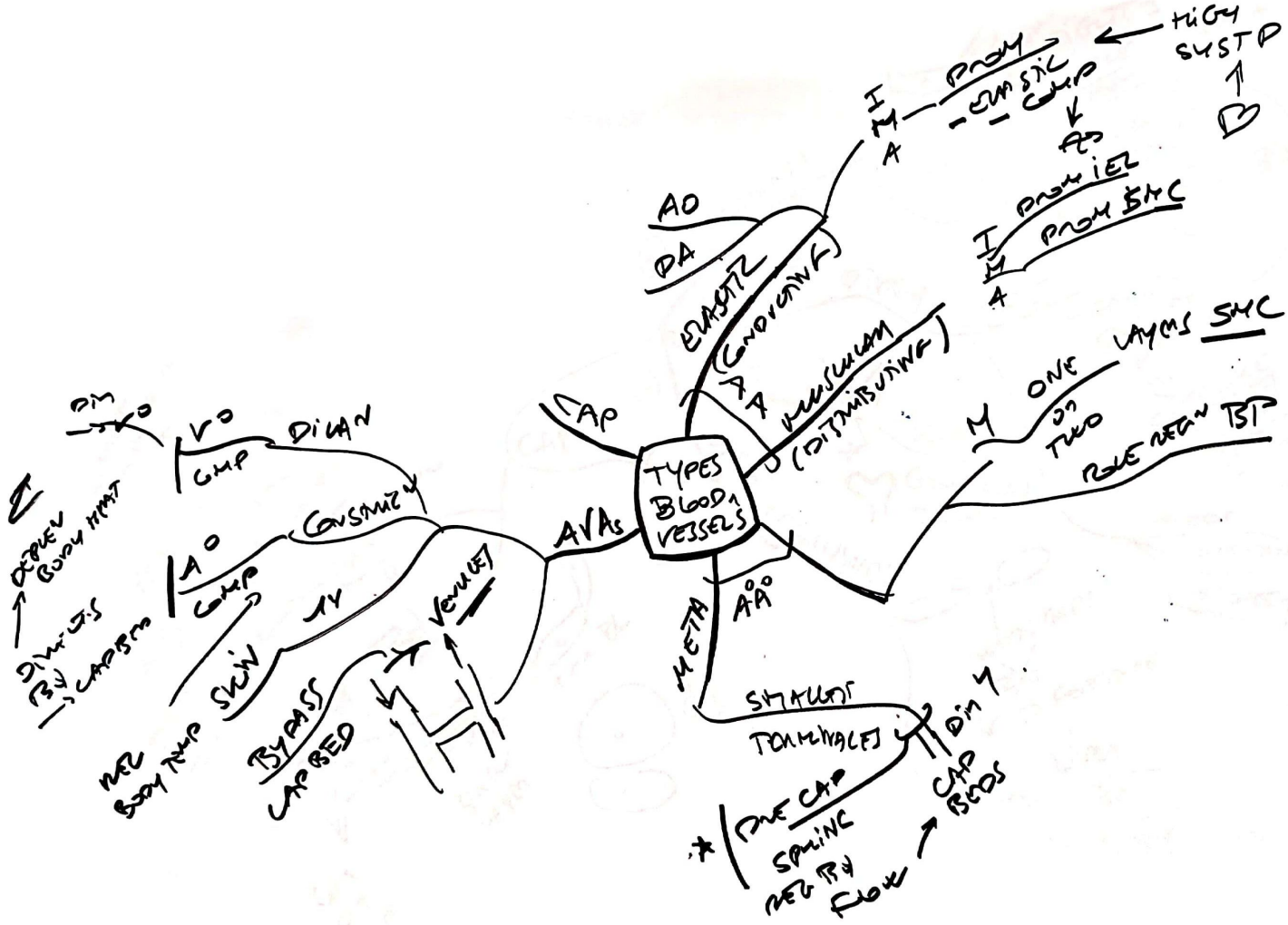

Scanned by CamScanner

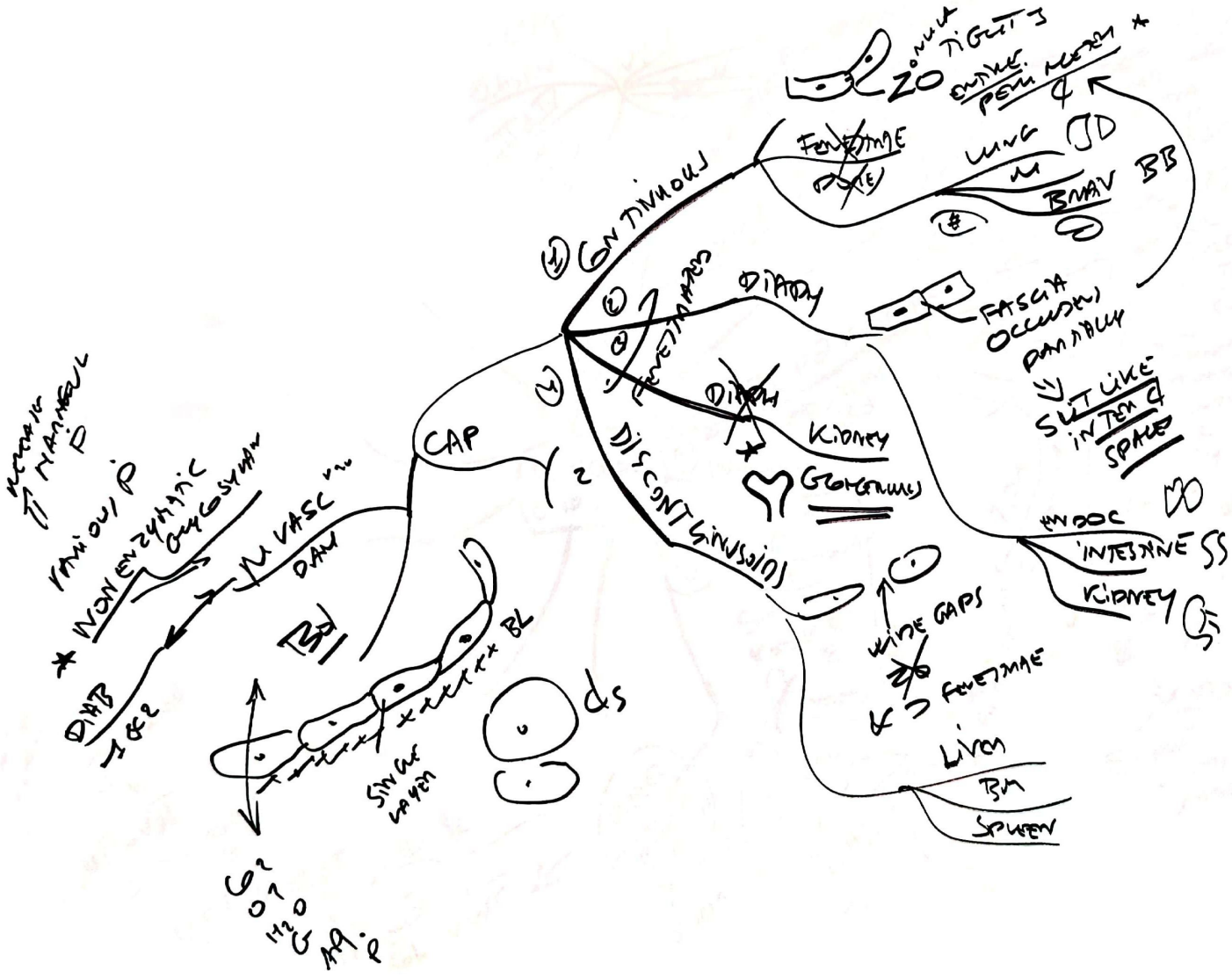

Scanned by CamScanner

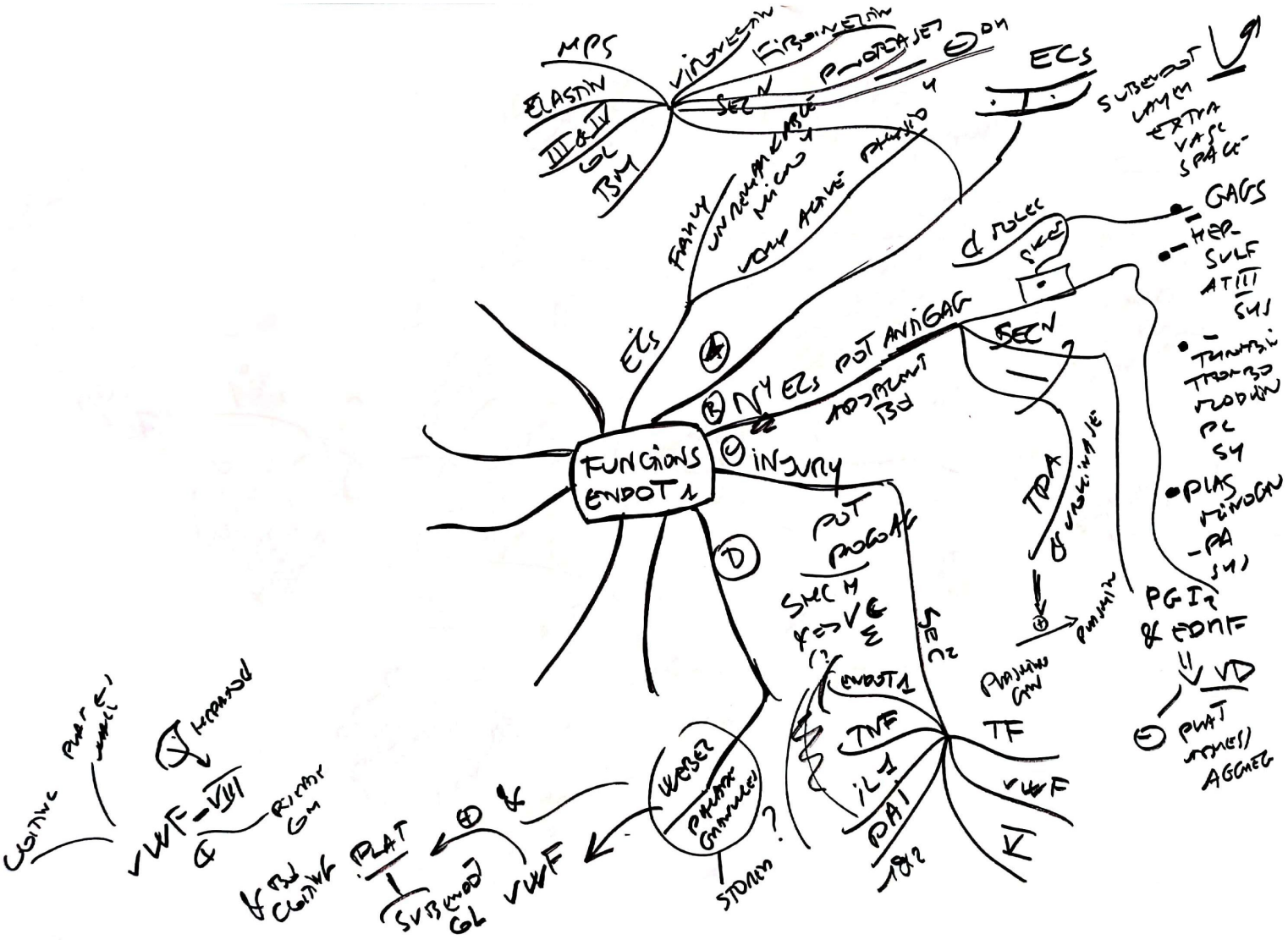

Scanned by CamScanner

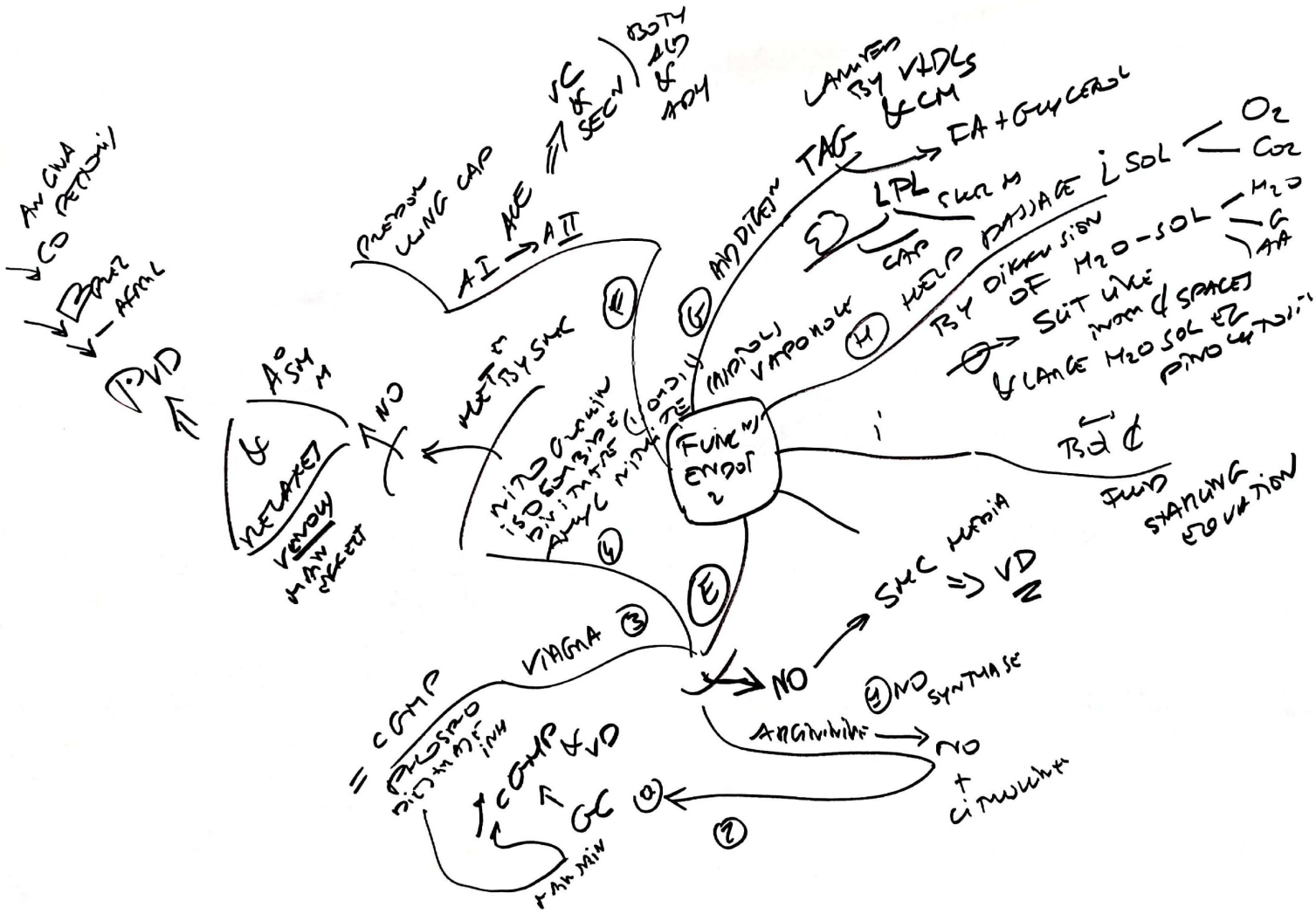

Scanned by CamScanner