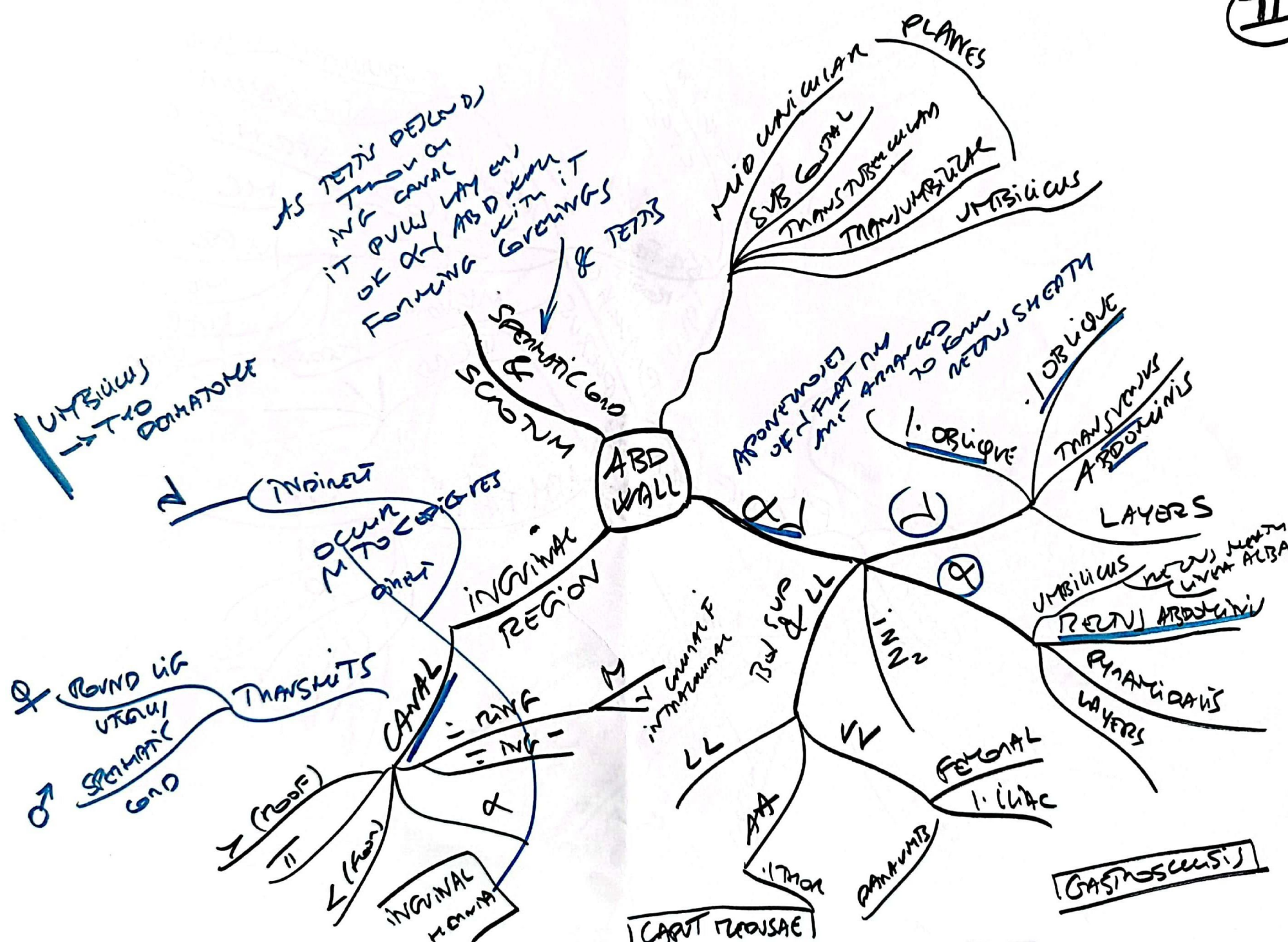
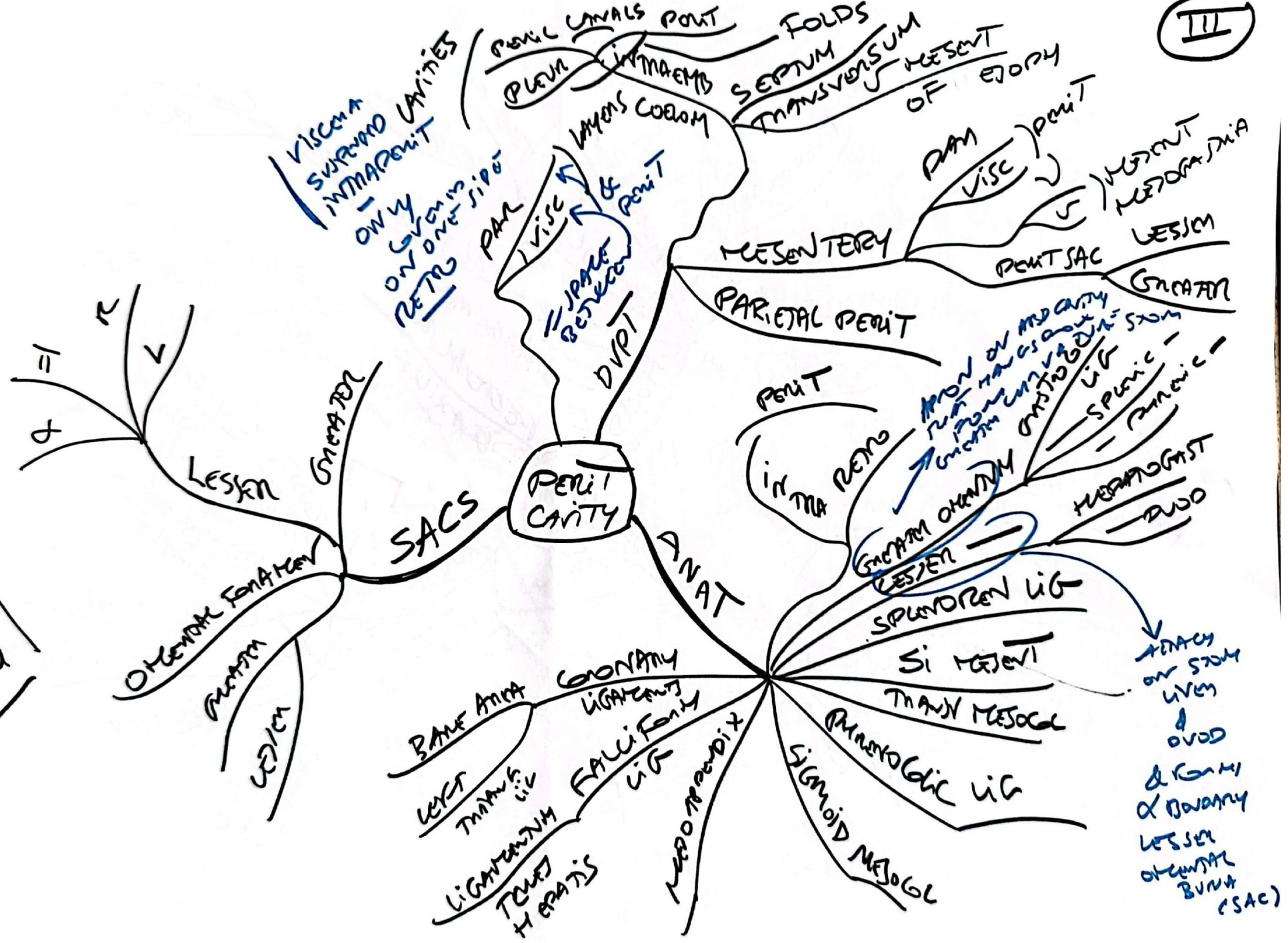


PERITONEUM



Visceral
 Superior
 Inferior
 Only
 on
 one
 side
 Retro

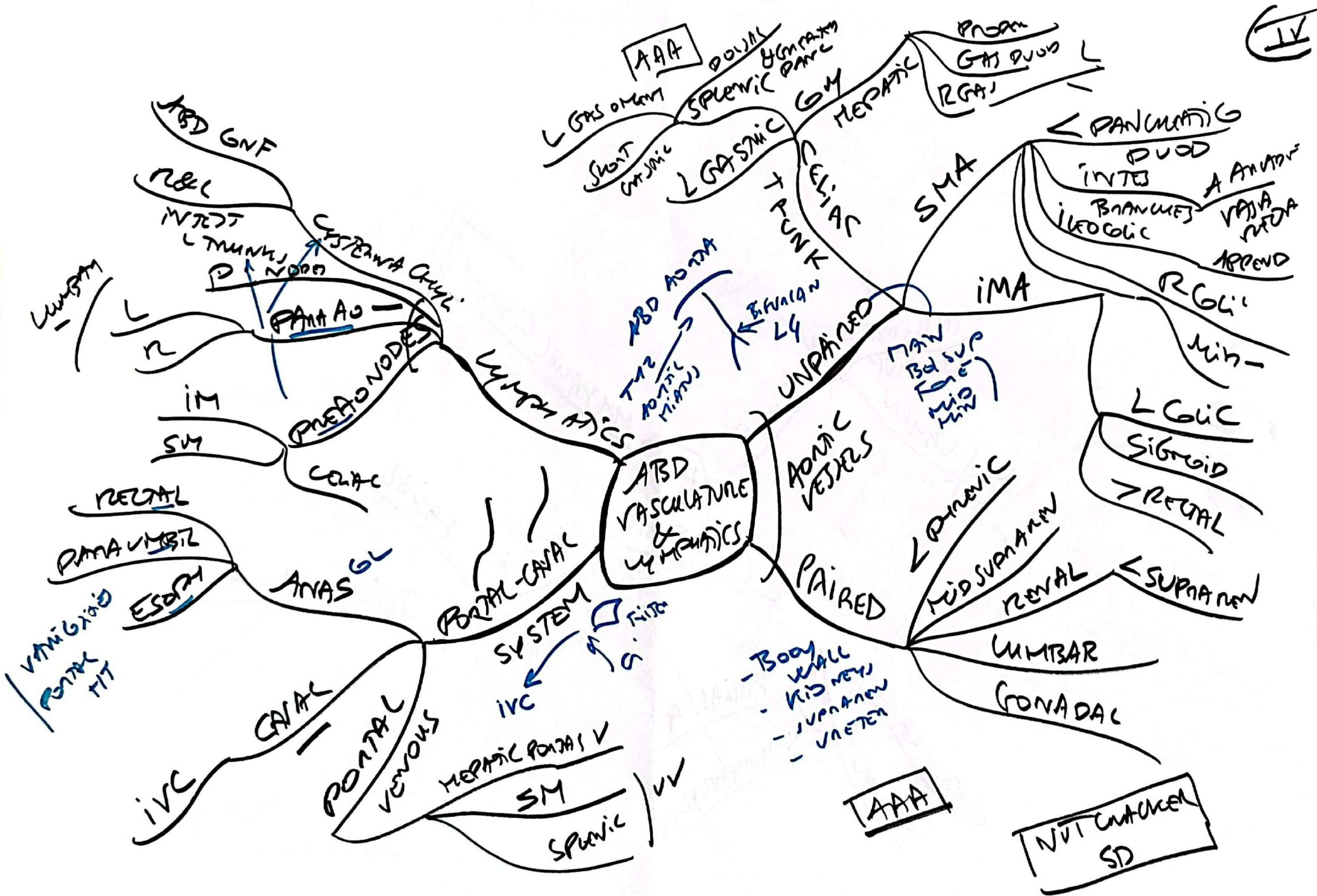
PLEURAL
 CAVITIES
 PLEURA
 MEDIASTINUM
 MYOGENIC COELOM

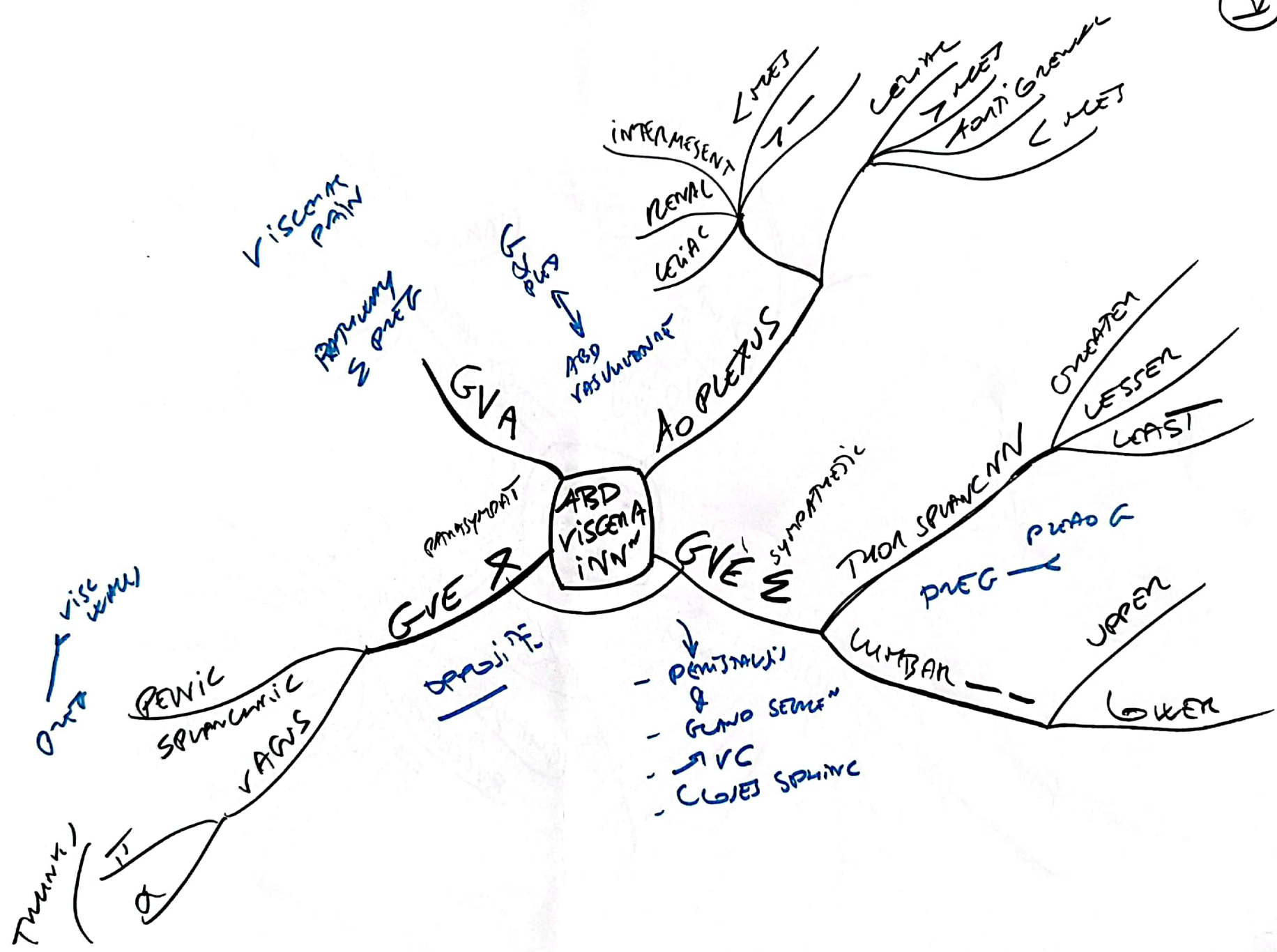
FOLDS
 SEPTUM
 TRANSVERSUM
 OF
 PERITONEUM

PERITONEUM
 LESION
 METASTASIS

PERITONEUM
 LESION
 METASTASIS
 SPINDLER
 PANCREAS

ATTACH
 ON
 STOMACH
 LIVER
 &
 OVID
 &
 Ovary
 LESSER
 OMENTUM
 BURSA
 (SAC)

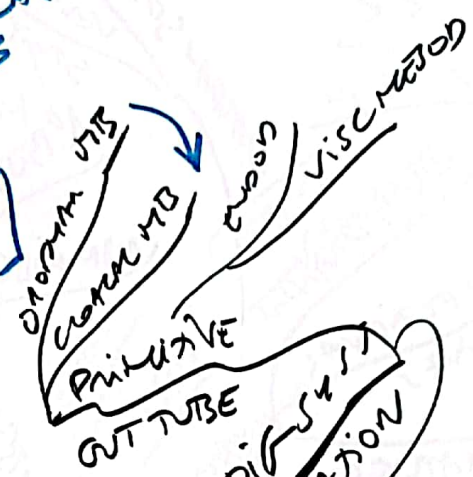




- COACA PARTITIONED BY UTERINE SEPTUM & UNG CON SINUS
FUSES WITH UTERUS AT FUNDUS SIZE OF PERINEAL BODY

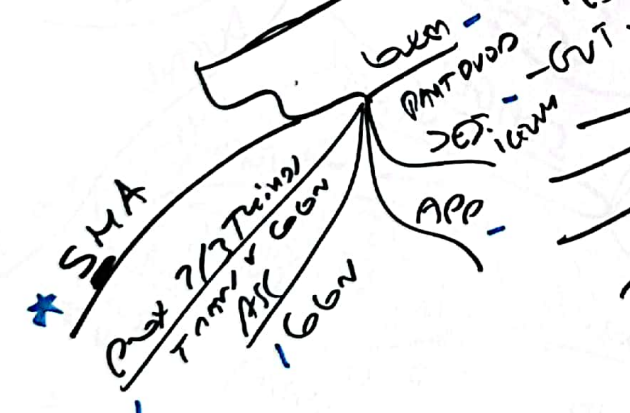


(2) HINDGUT

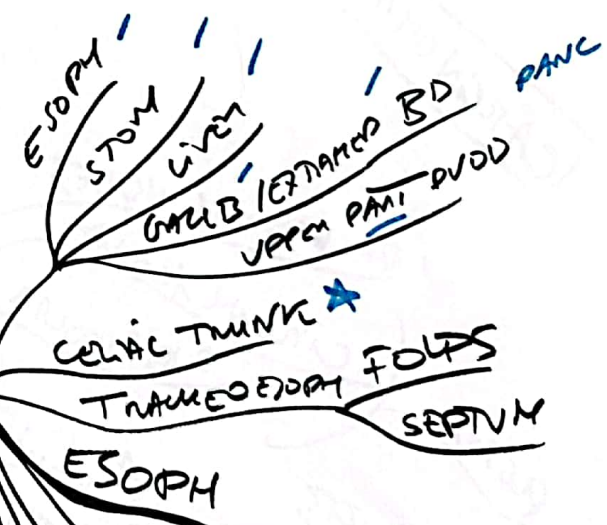


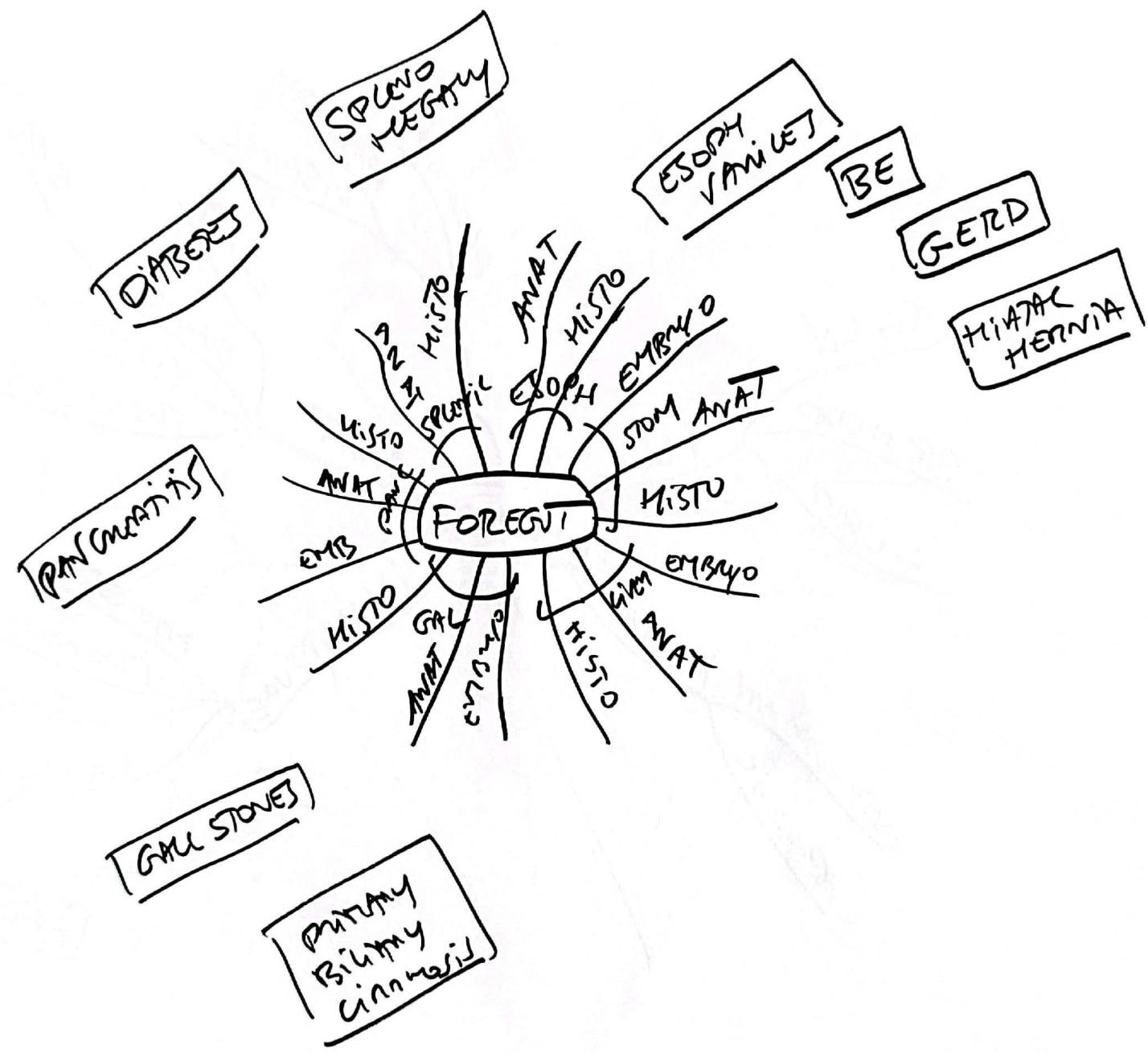
ABDOMINAL VISCERA

(3) MIDGUT



(4) FOREGUT





SEND - M DAM FILES

UPPER
INNER AN
OUTER AN
DISTAL SOB
MIDDLE SOB
UPPER SOB

CRANIOS
MM
MM

EXTENDS
ABOUT 2mm INTO ORN
GET J
BE
SIMP COL e
MAGNIFYING 2 LINES
AT LEAST 3um
INTO
START INTO SPINNING + GET BET 4

A(S)

HISTO ESOPH

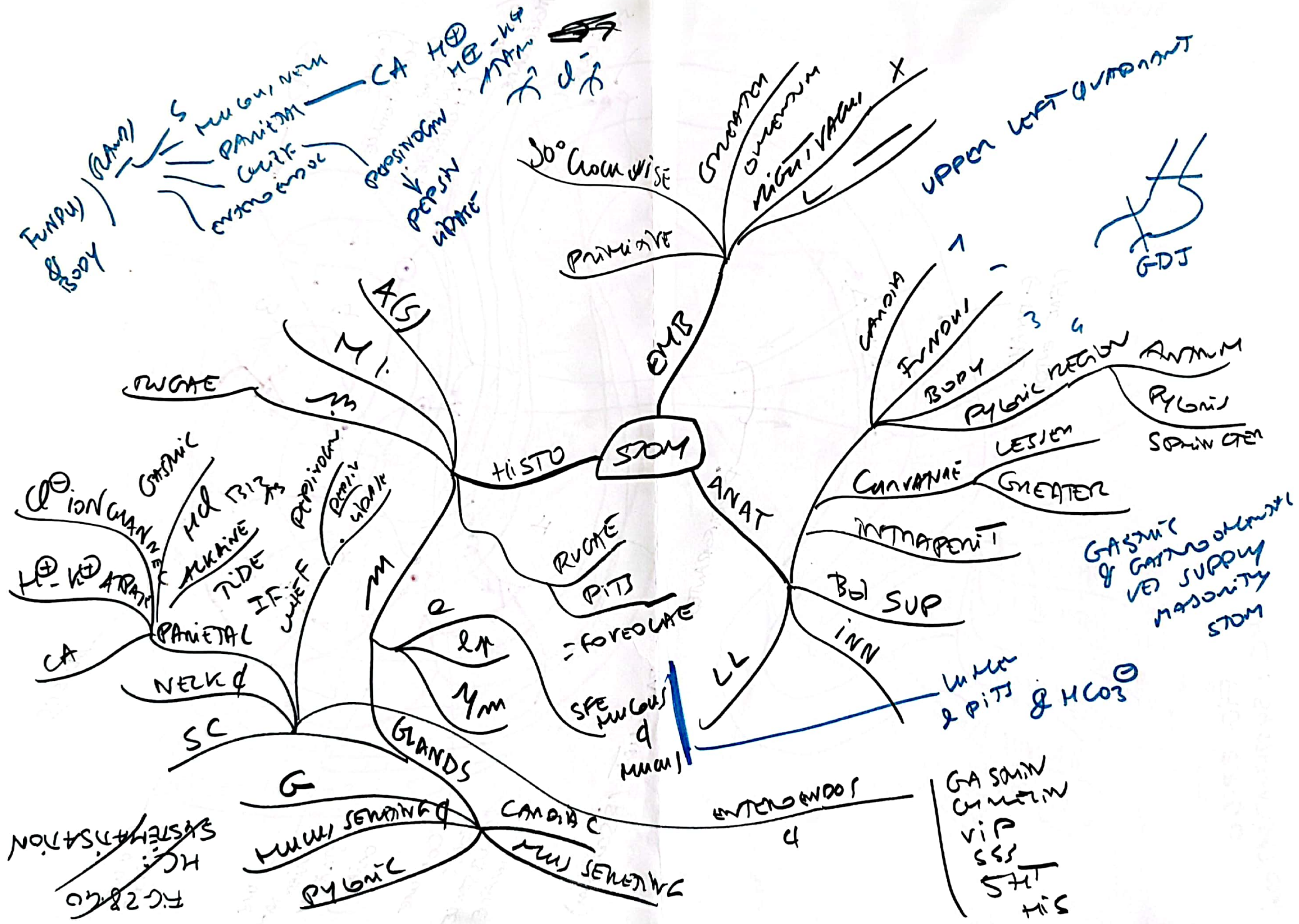
ANAT
BD SUP
INN
LL

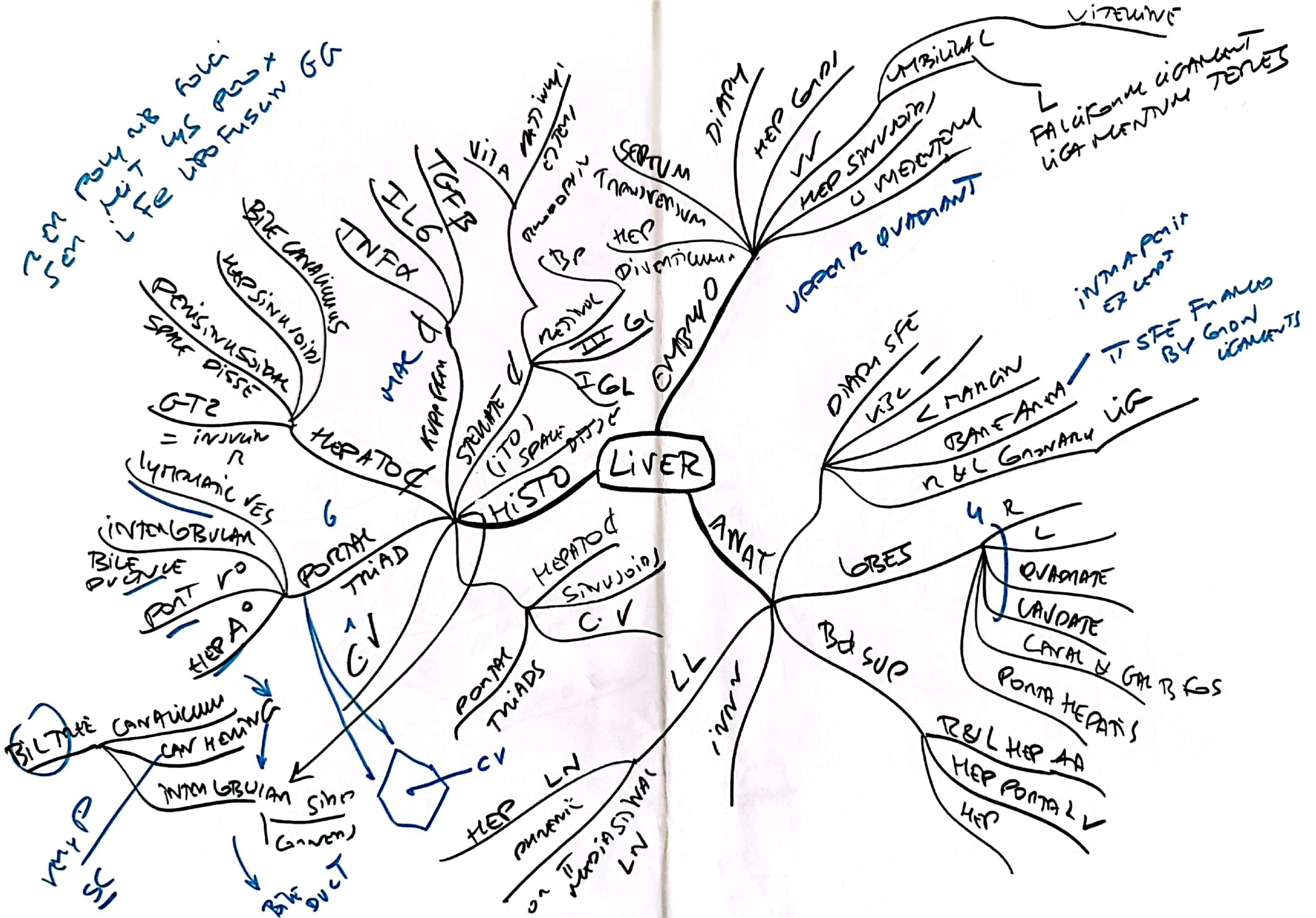
START SEQUAM
EQUOT DISTAL 2um AT GET
LIPRO
SIMP COL

T10
UNIC EPDM M
ESOPHINTUS
GET W
CHANGE NOTCH
LES

e
SIMP COL

MM
LN
MARGIAL GRANOS
= CAROTIDE





GALLSTONES
 Green
 Black pigment
 Brown pigment
 BILE SALT & LECITHIN OVERLAPPED BY CHOL

FOSSA UPPER 2/3
 CYSTIC DUCT
 COMMON BILE DUCT

EMBRYO
 PRIMA BILE DUCT
 INDEFINITE CYSTIC DUCT
 COMMON BILE DUCT & COMMON BILE DUCT

GALLBLADDER

A
 MI
 M
 P
 X
 Y

HISTO

ANAT

Bd SUP

INN

LL

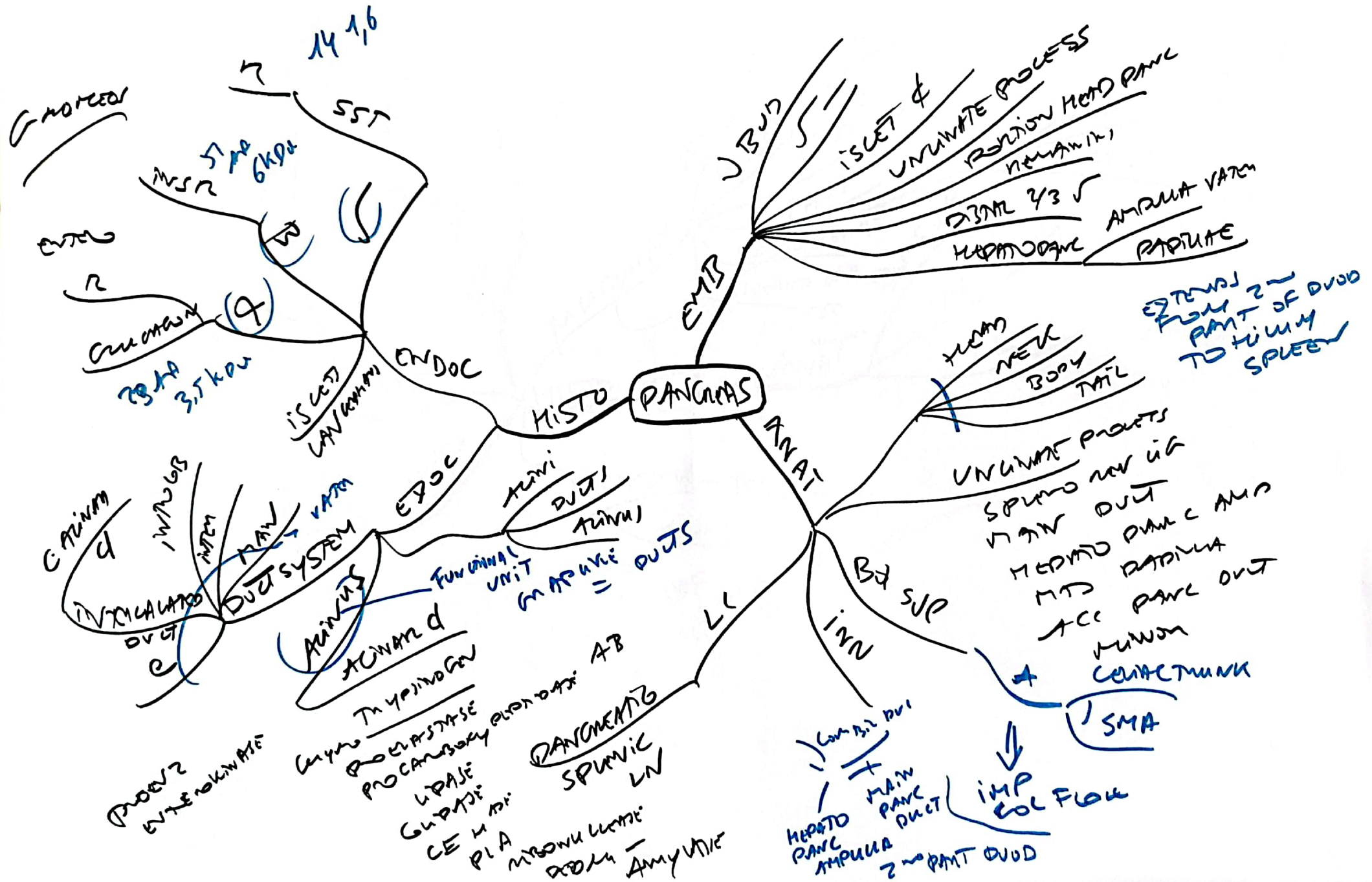
CYSTIC DUCT
 ✓✓

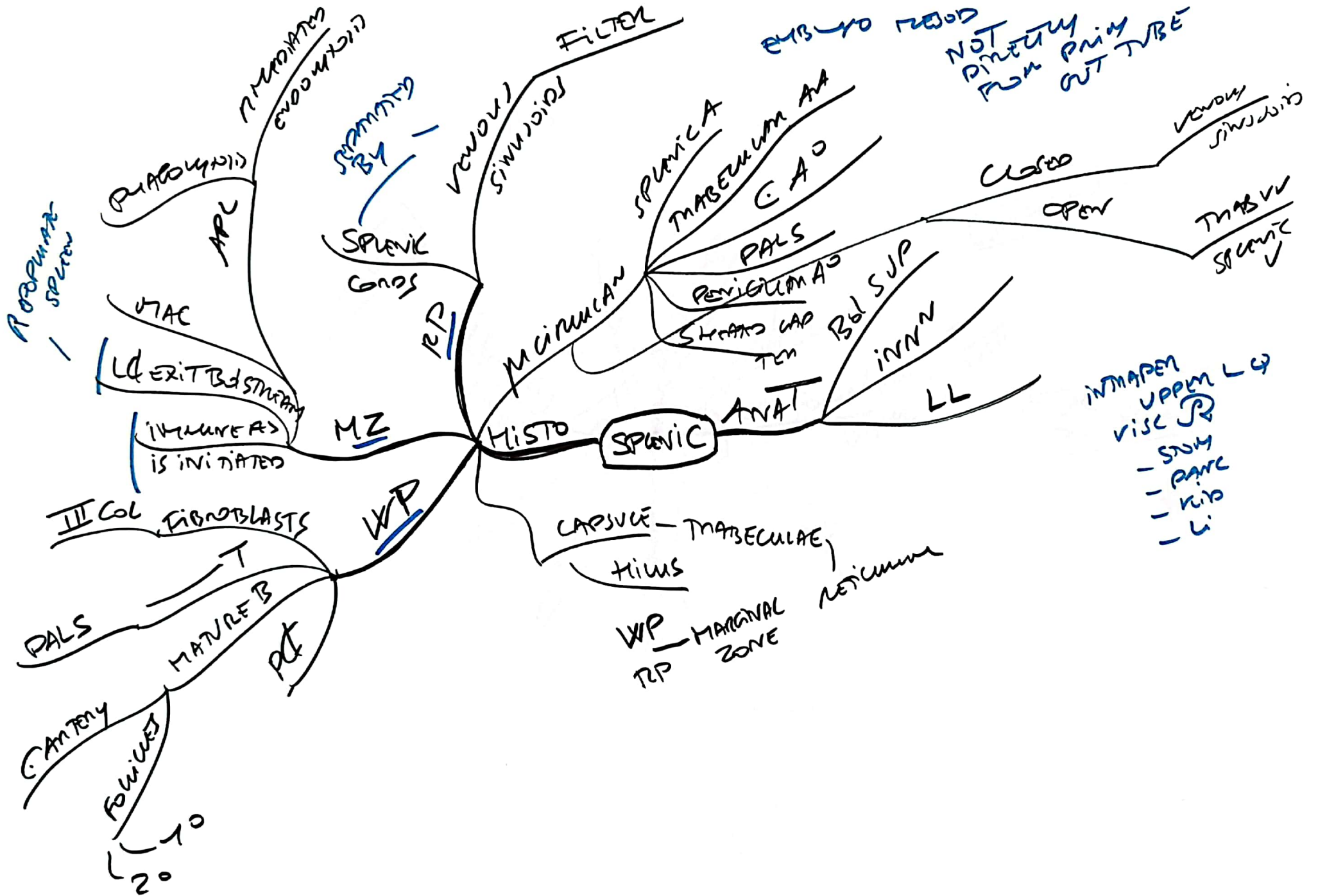
REGITIMUNY -
 ASCUSORP
 SINUSIT

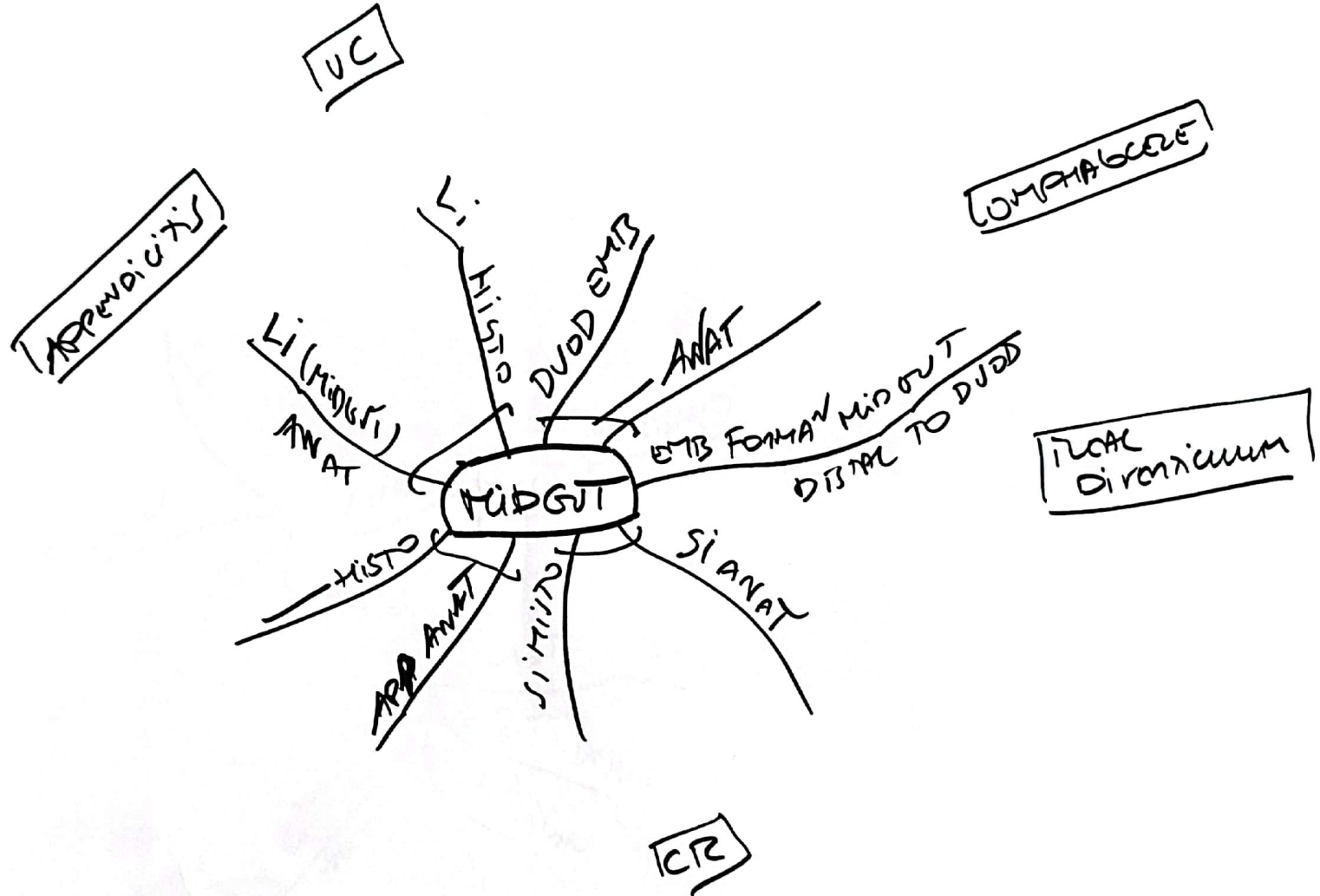
SMP GL
 Mvilli
 20

C in the dig...
 Nut + H₂O + Fats
 40
 40 P1
 8

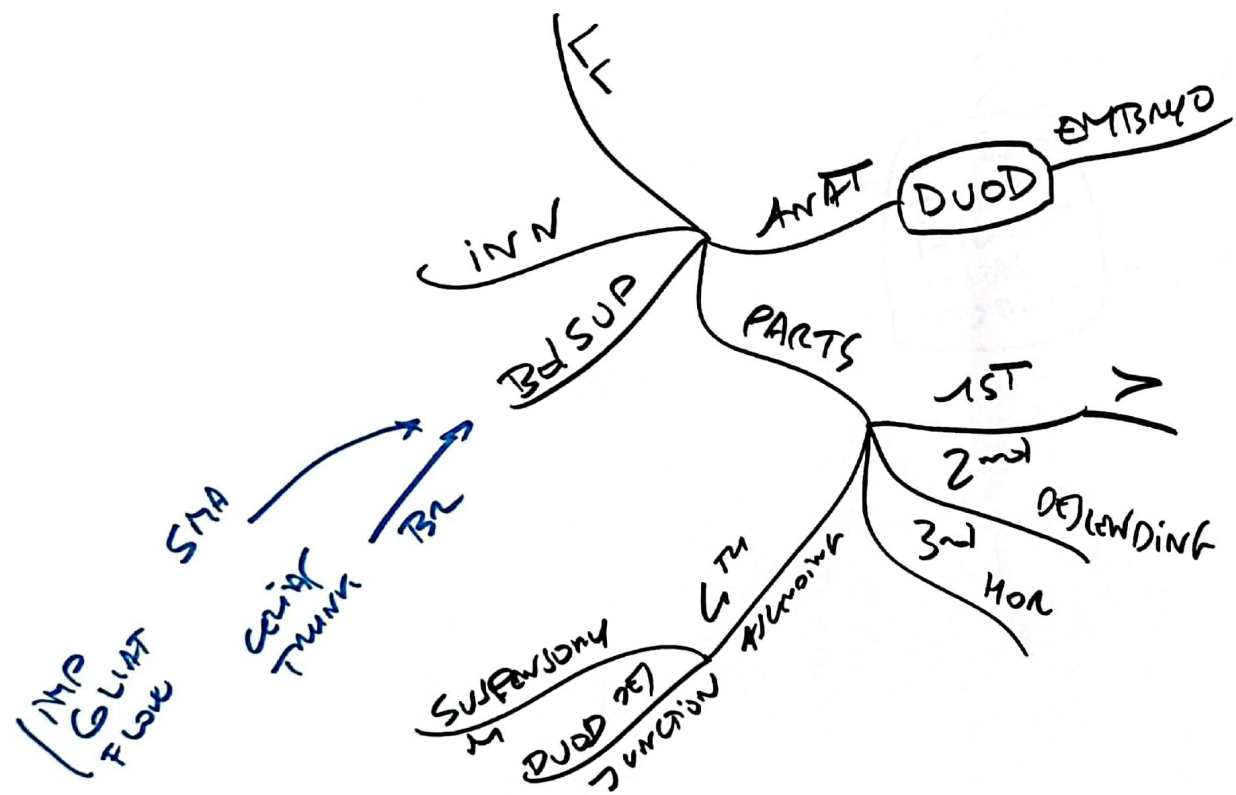
SER Mucus
 WHITE Bile
 FULLY COMPOS

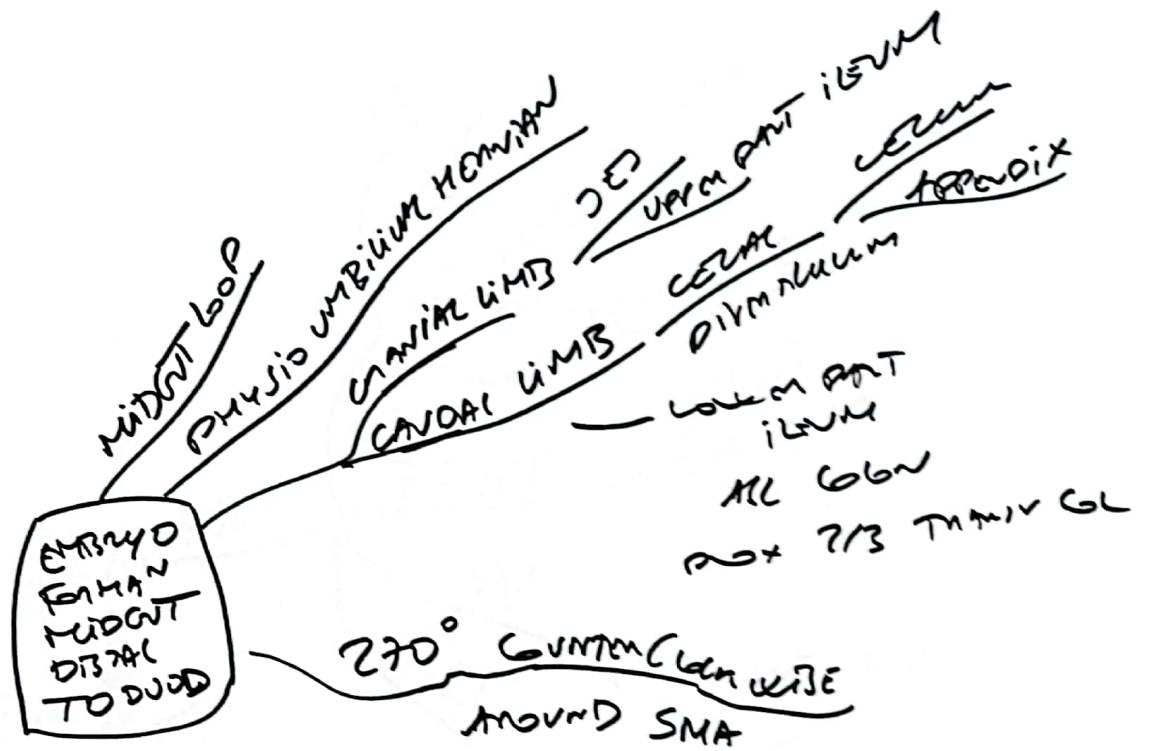


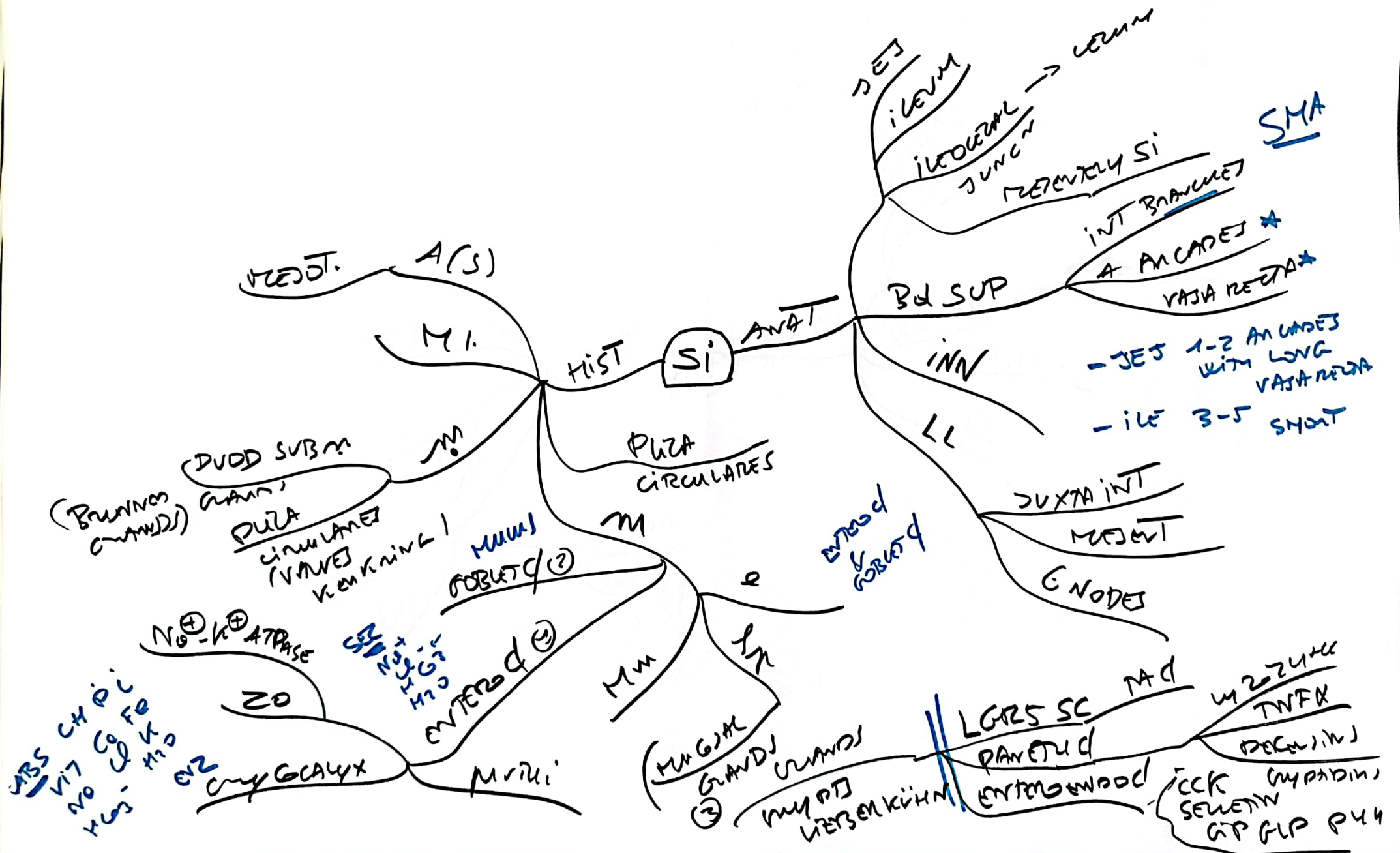


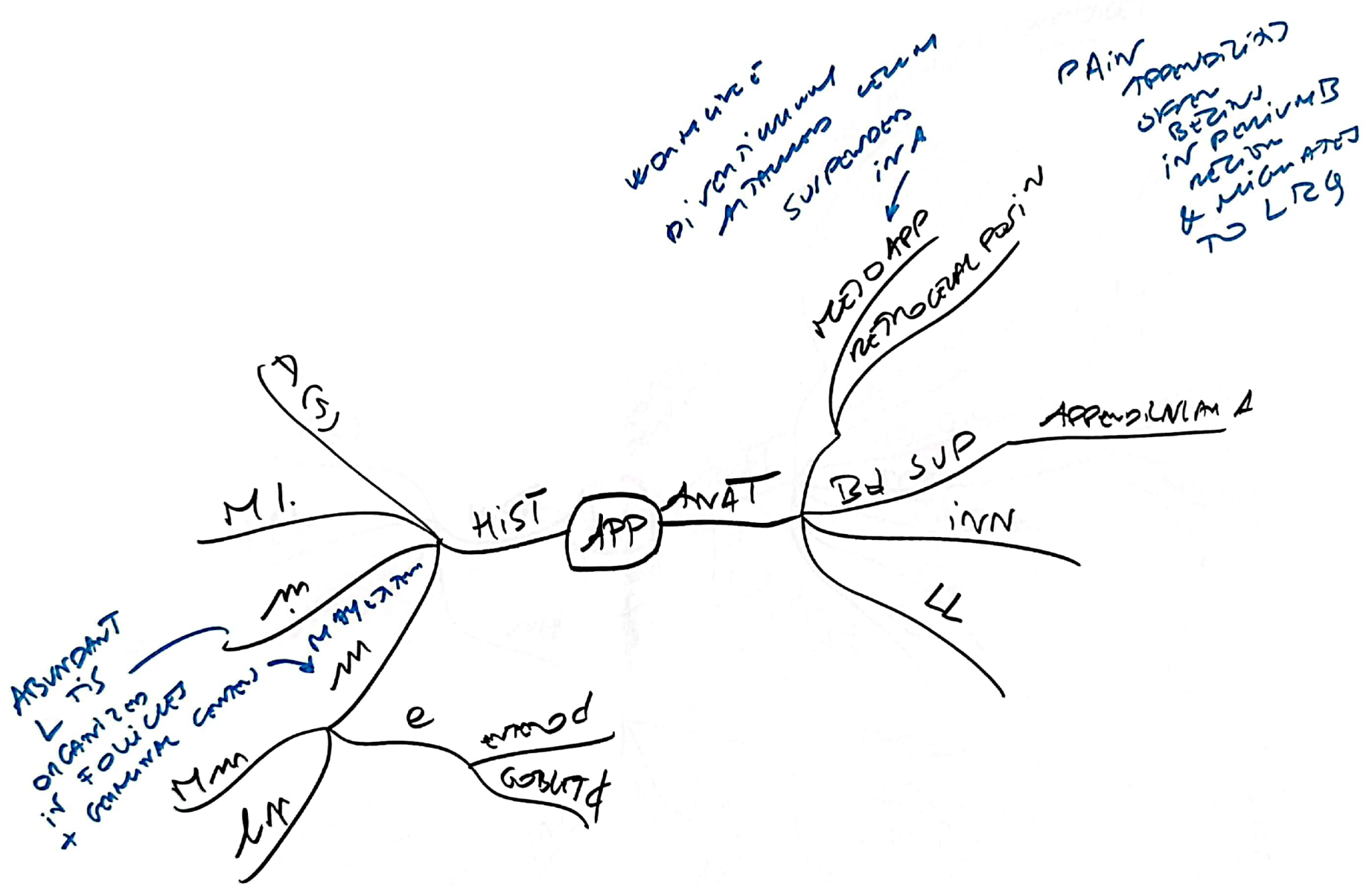


Si ——— PROS
 CONS
 (LEVEL) CY









24L
GUT
FLEXURES

= HAVING
VALVES

3 + Features
- Cecal Appendix
- Tenia coli
- Haustra

