

ACCESSING INTERCOSTAL SPACE

PARVICN MUSC & SENSORY INNERVATION  
 SUBCOSTAL FN

INTERCOSTAL NN  
 AXIL BRANCHES  
 MM SKIN  
 X RARI INTERCOSTAL SPACES

THORACIC WALL

VASCULATURE  
 INTRACOST AA  
 INTRACOST VV  
 SUBCOST AA  
 INTRACOST VV

OSTEOLOGY  
 12 ribs STAMPEL + MVT

STERNUM  
 RIBS  
 XIPHOID PROCESS  
 ANGLE  
 BODY  
 MANUBRIUM

MOVEMENT  
 X/TI PLANE  
 Y PLANE  
 Z/K PLANE

LAYERS

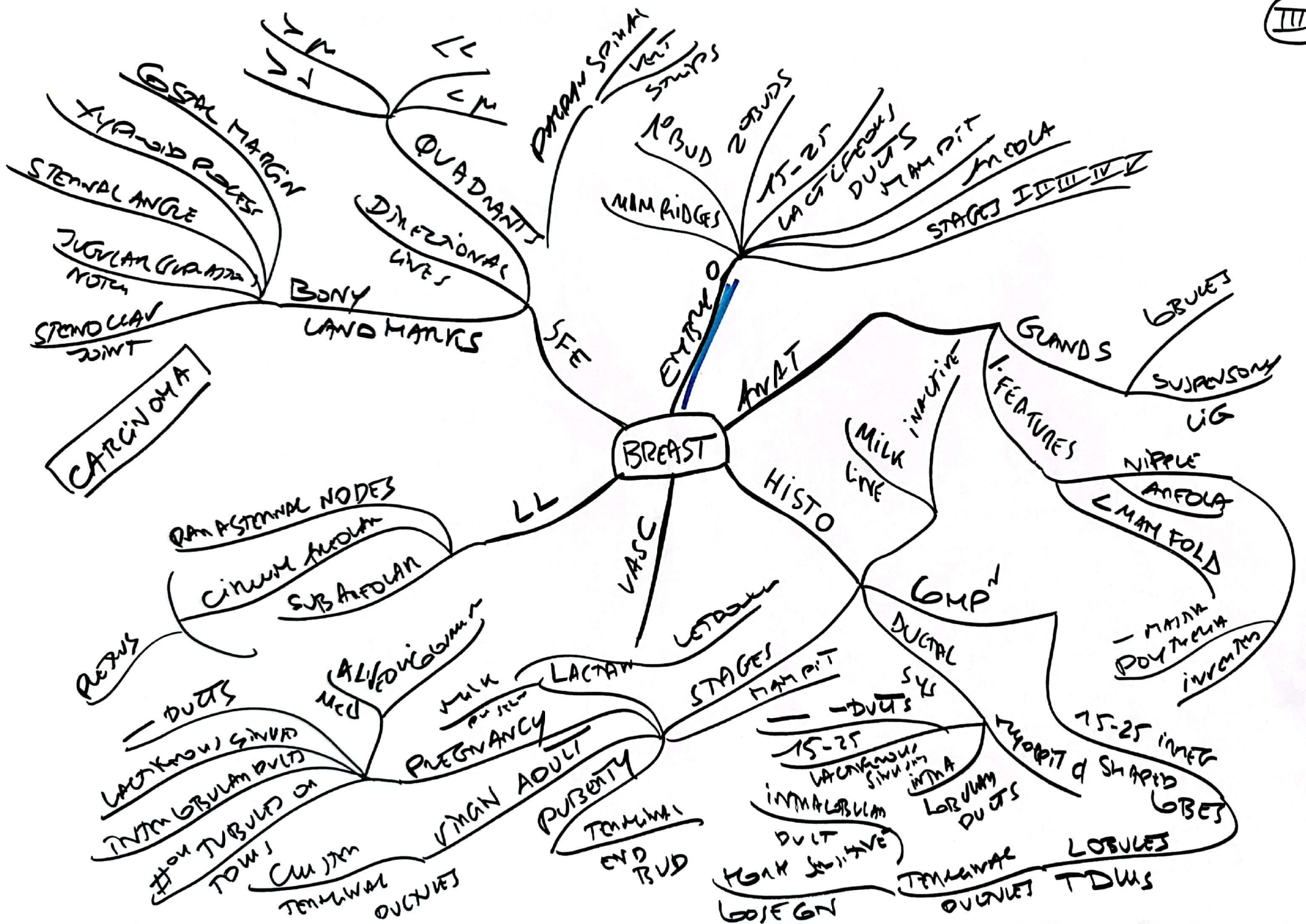
INTMGST EX-IN  
 IN-EX  
 INTRMGST INTMGST & TRANSVERSE

AXIO APPEND NECK & ABD  
 ACC RESP

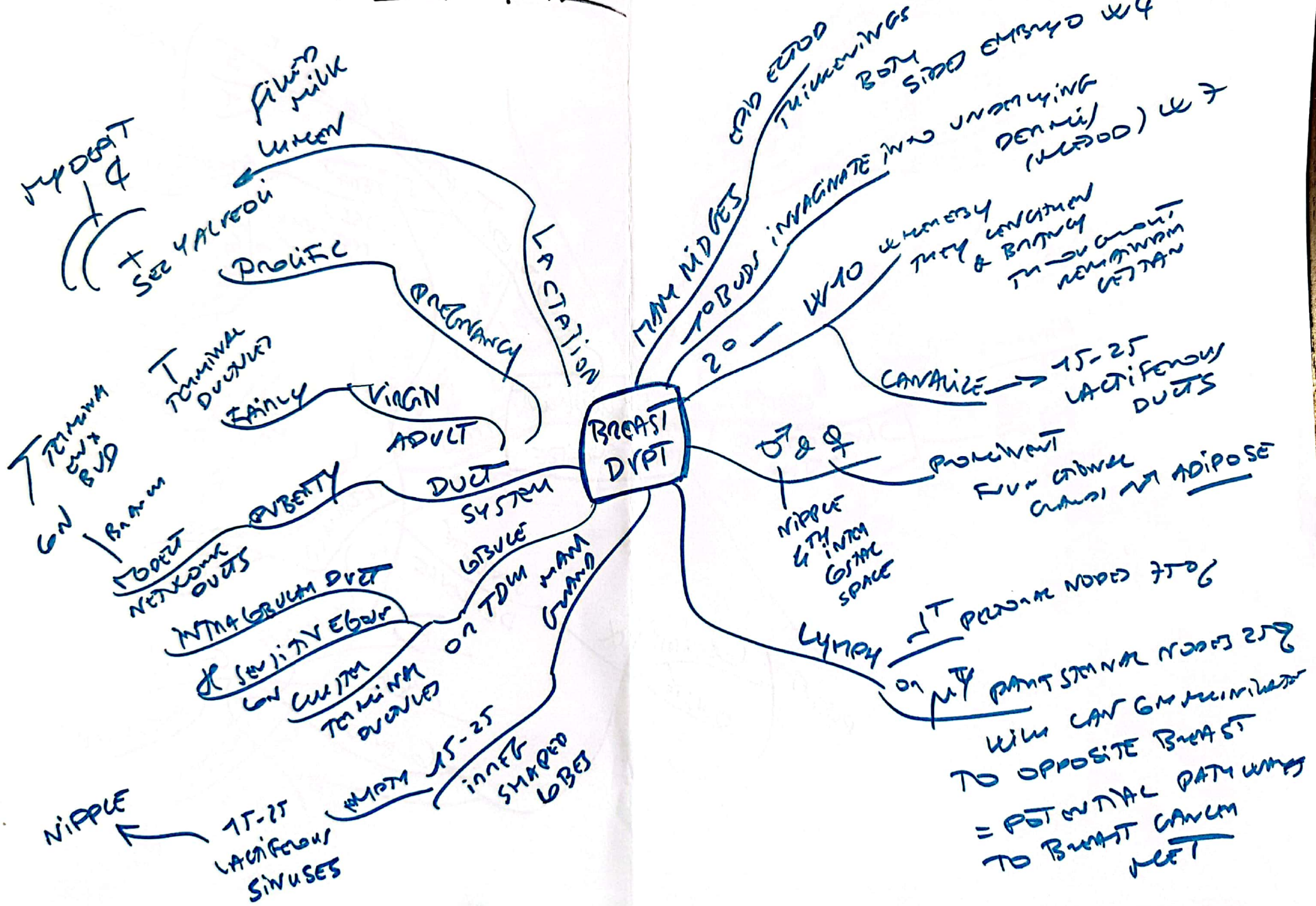
DIAPHR  
 IVC  
 C3 C5  
 MAN VESTIB

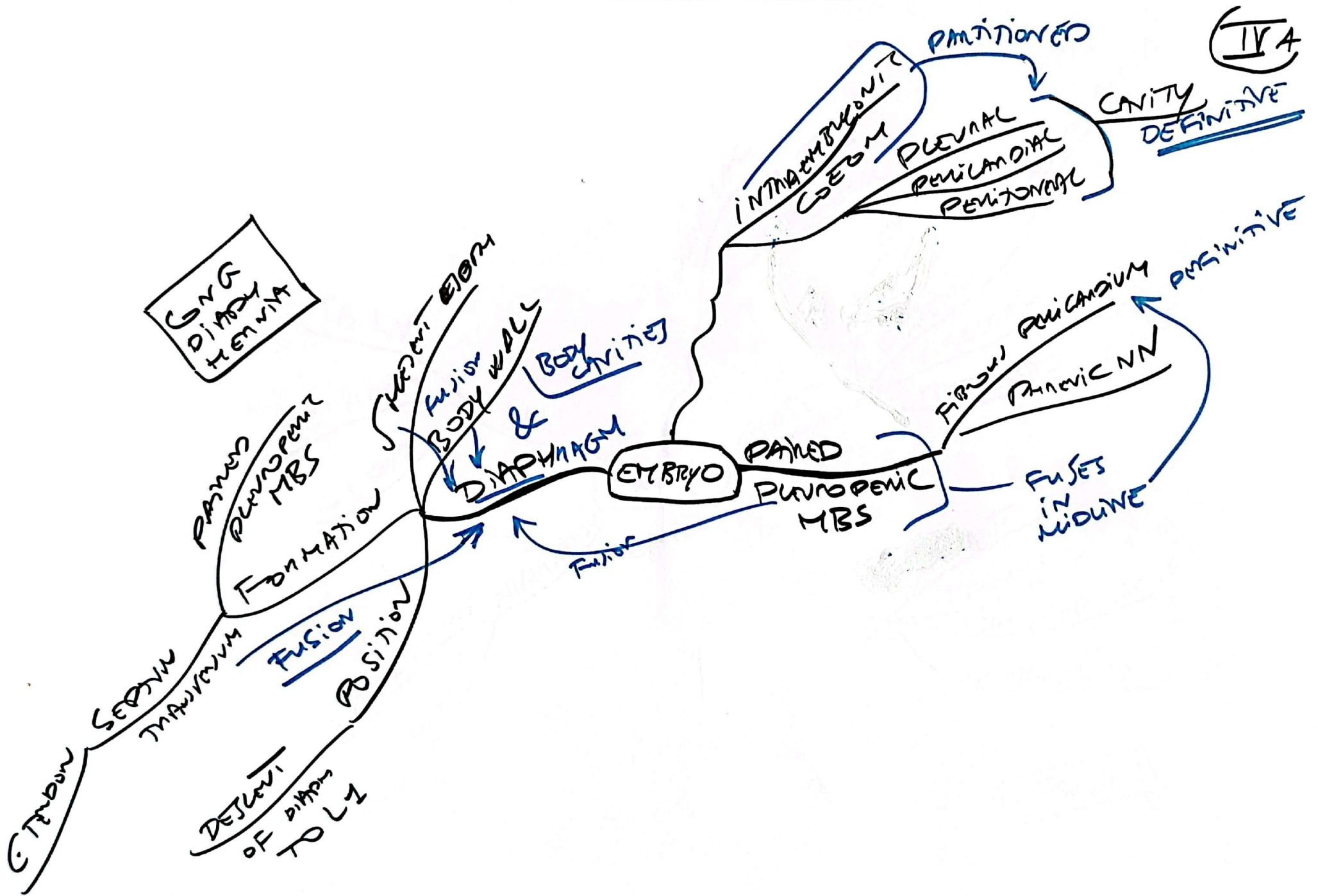
HEAT APPLD AT 3, 10 & 12 C  
 SOPY

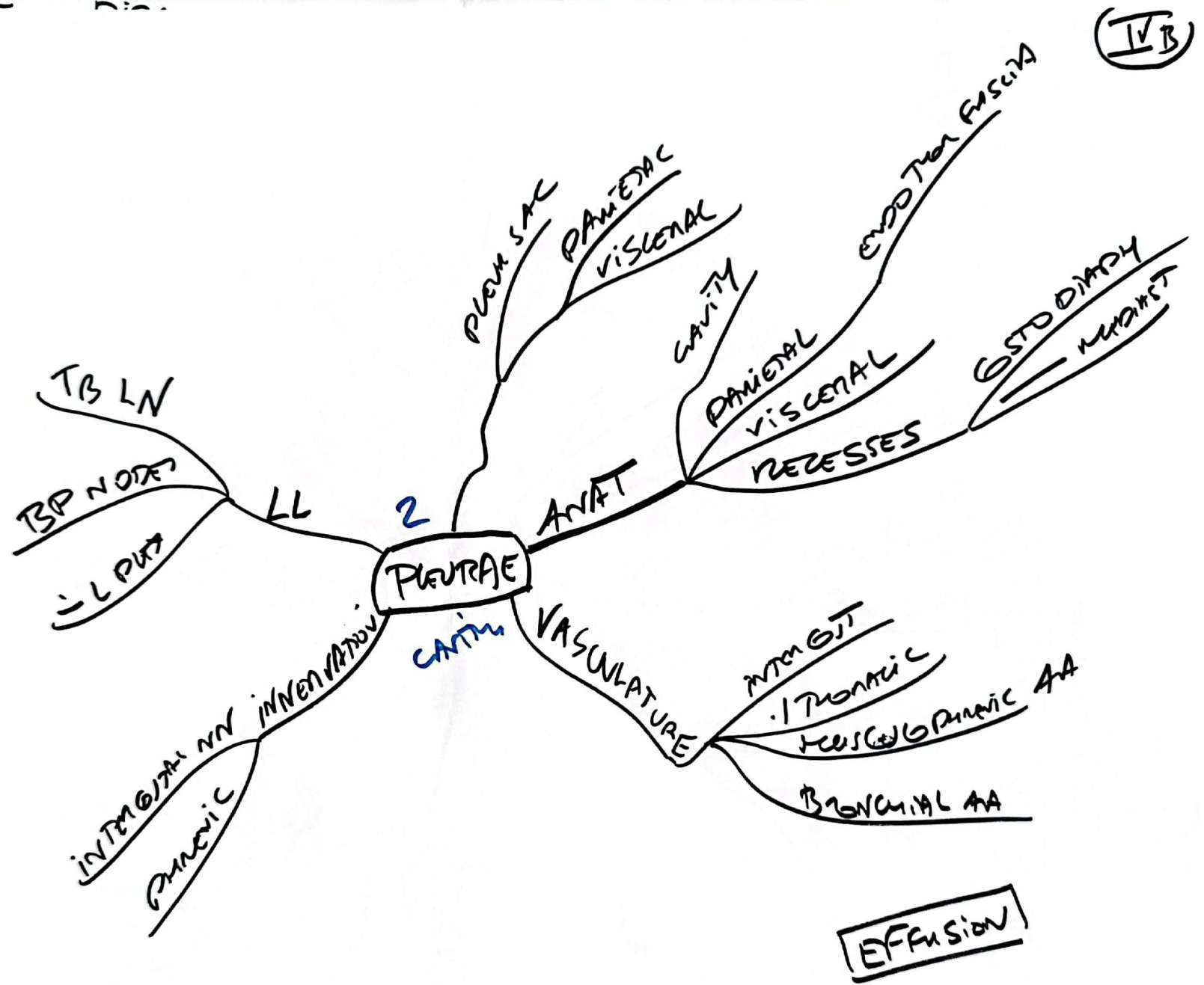
HEAD  
 NECK  
 TUBER CUL  
 BODY  
 AN CUR  
 GROOVE  
 RIB FRACTION



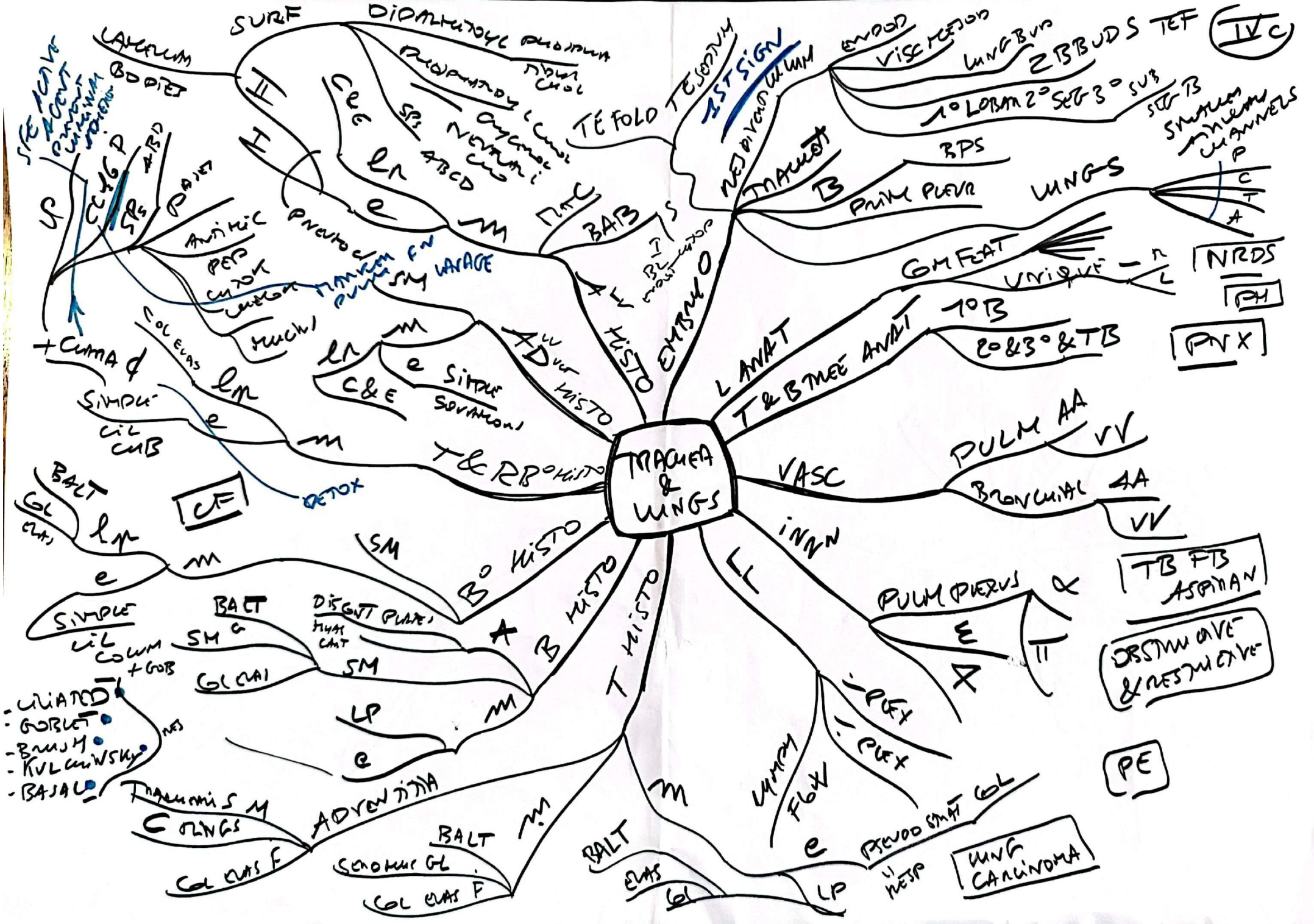


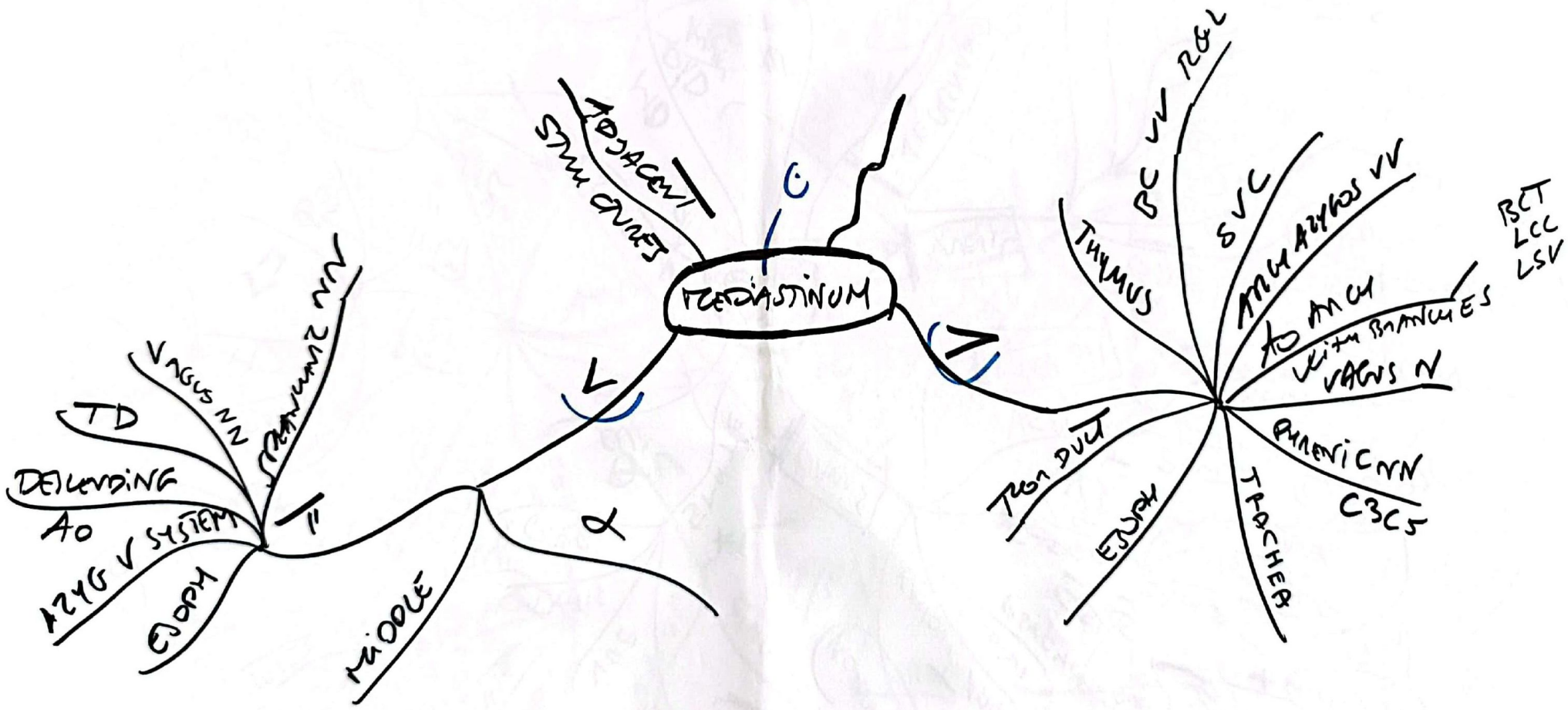




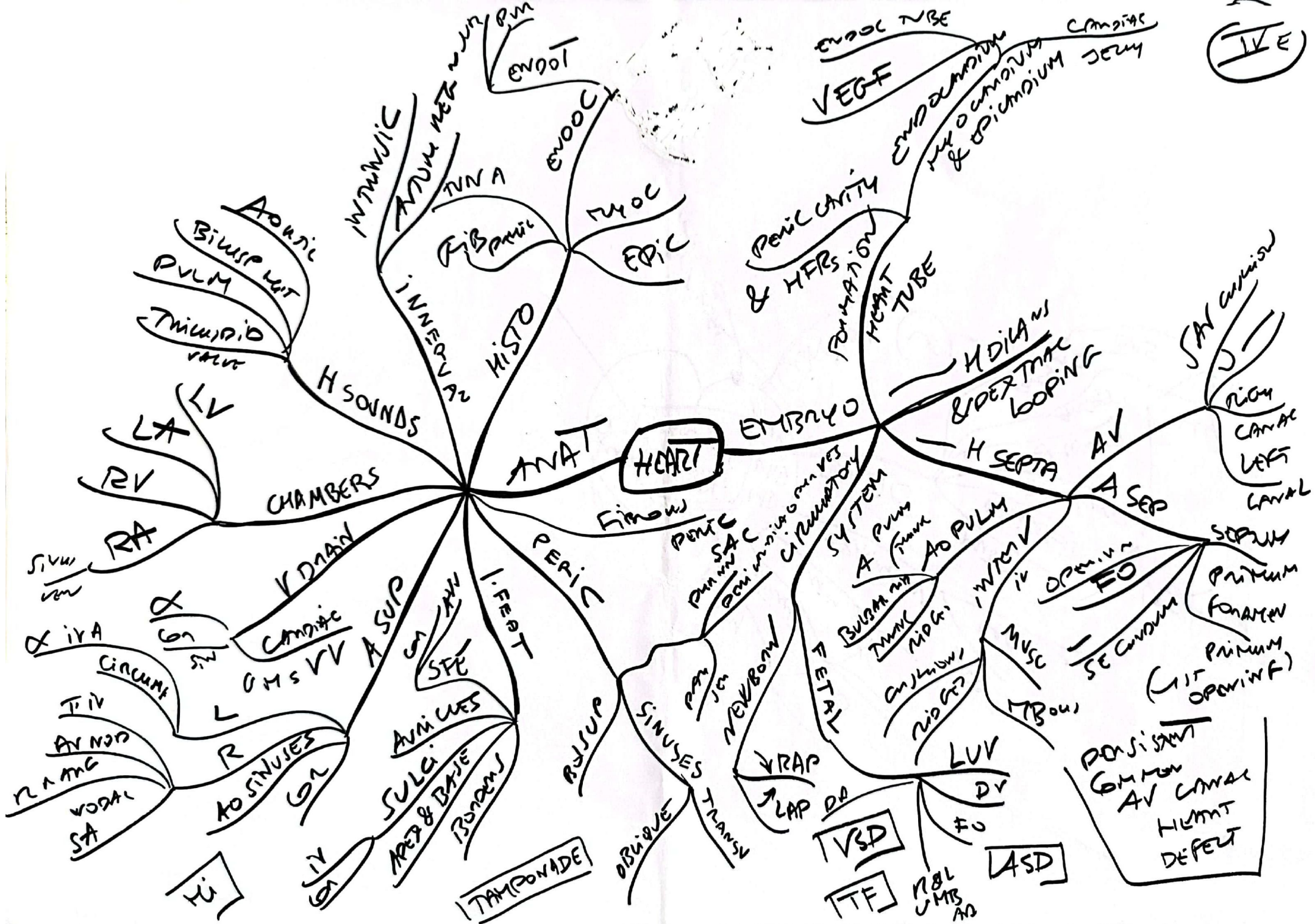












(IVE)



II  
THOR  
WALL

THOR  
IMAGING