1

SHOULDER MVT

2 MM OVERLAP

SHORTEN TENDOS TO VE DEEPEN

CLASSIFICATION MVT → A B C

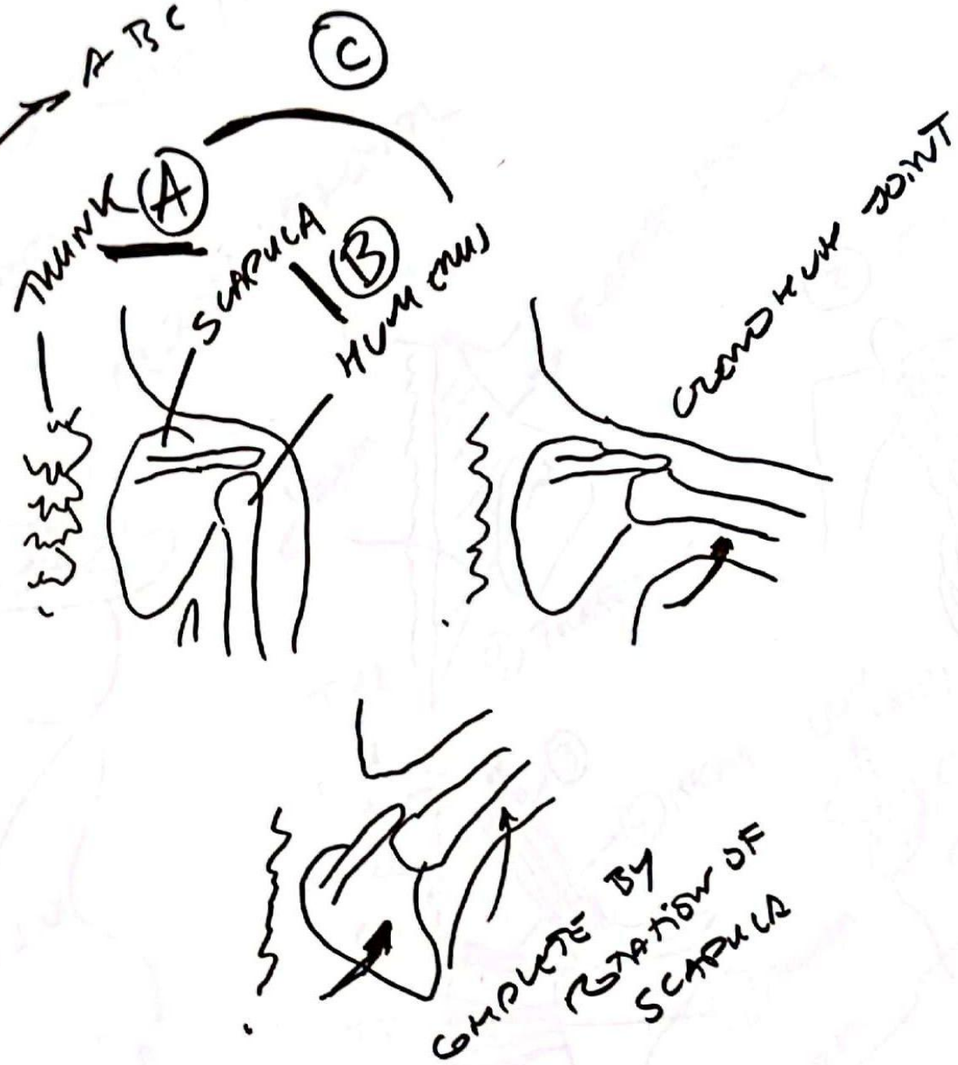

83 PAGES!

TRUNK 2

RIGHT SCAPULA

BULLFIGHT

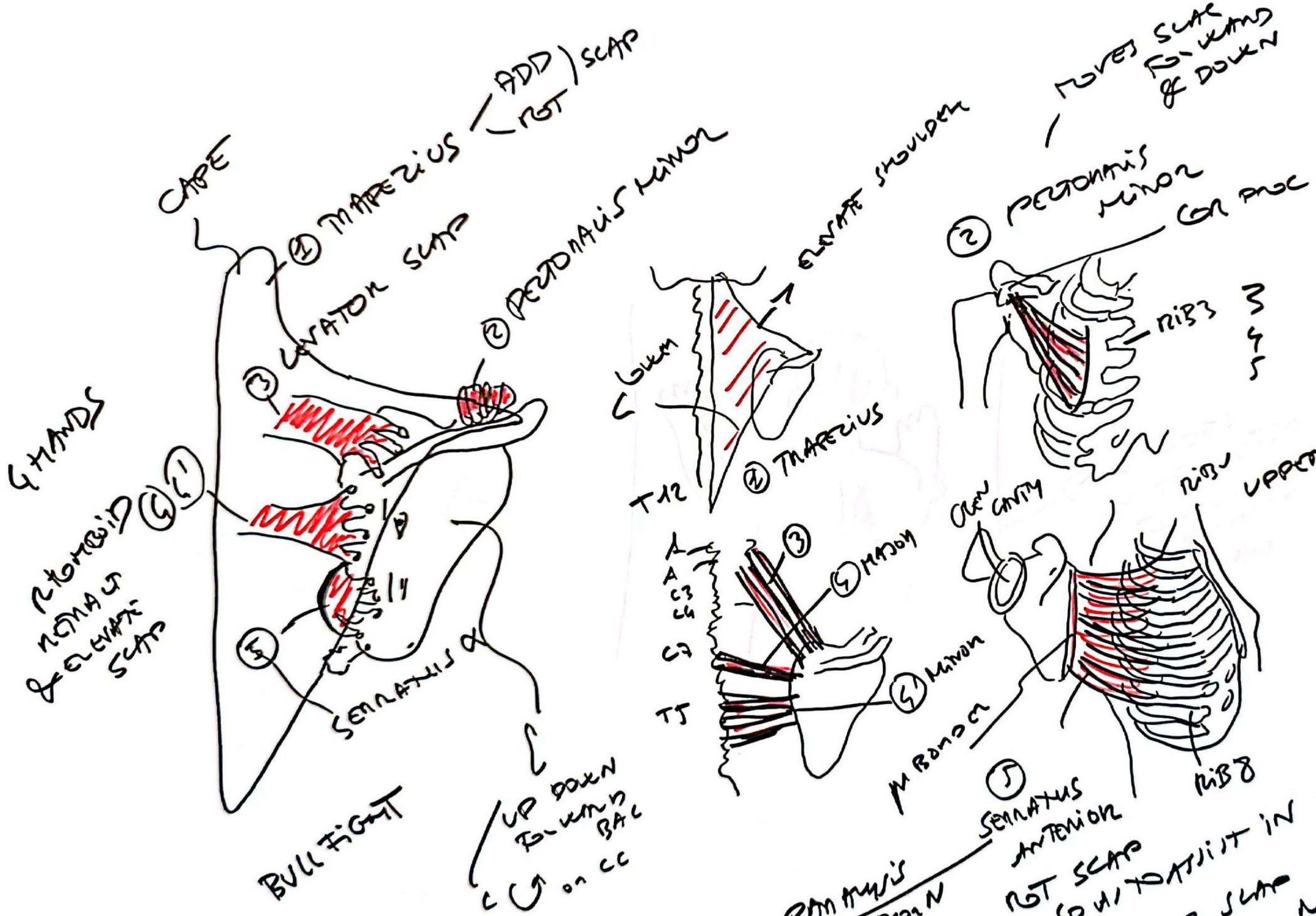

"SCAPULAR WINGING" — PARALYSIS LONG THORACIC

- ROT SCAP SO W/ TOTALLY IN ABD UPPER LIMB
- ALSO MOVES SCAP FORWARD
BOXER M
- HOLDS SCAP CLOSE RIB CAGE

3

SCAPULAR WINGING ON RIGHT

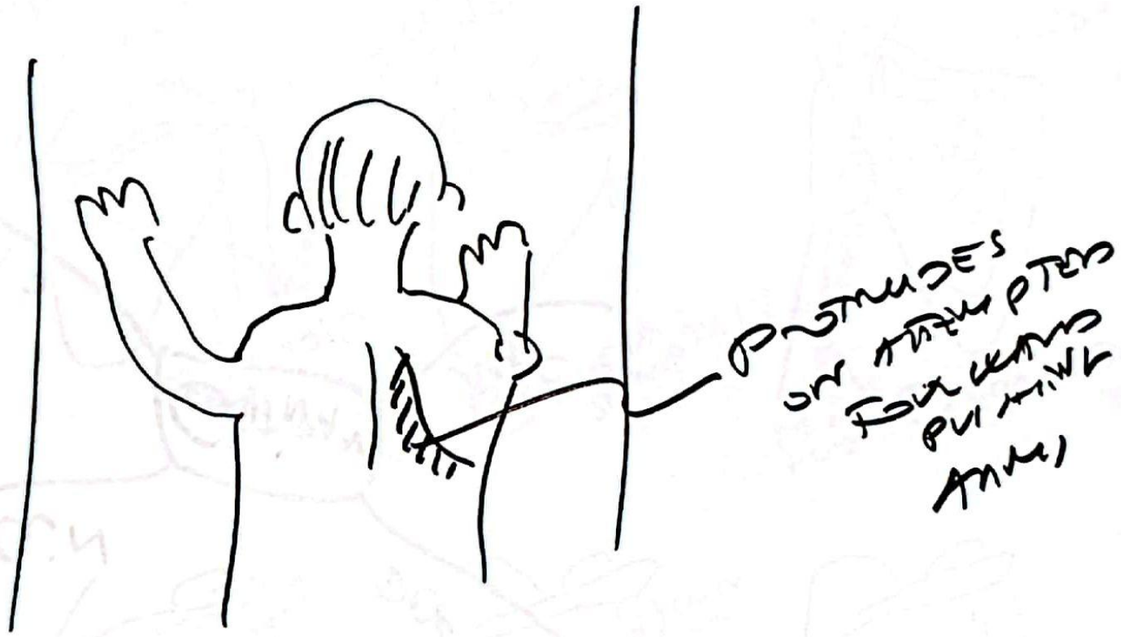

S — H

BUU HANNESSEN

ROTATOR CUFF MUSCLE

S-FS

TENDONS FUSE WITH CAPS SHOULDER JOINT & HELP STABILIZE

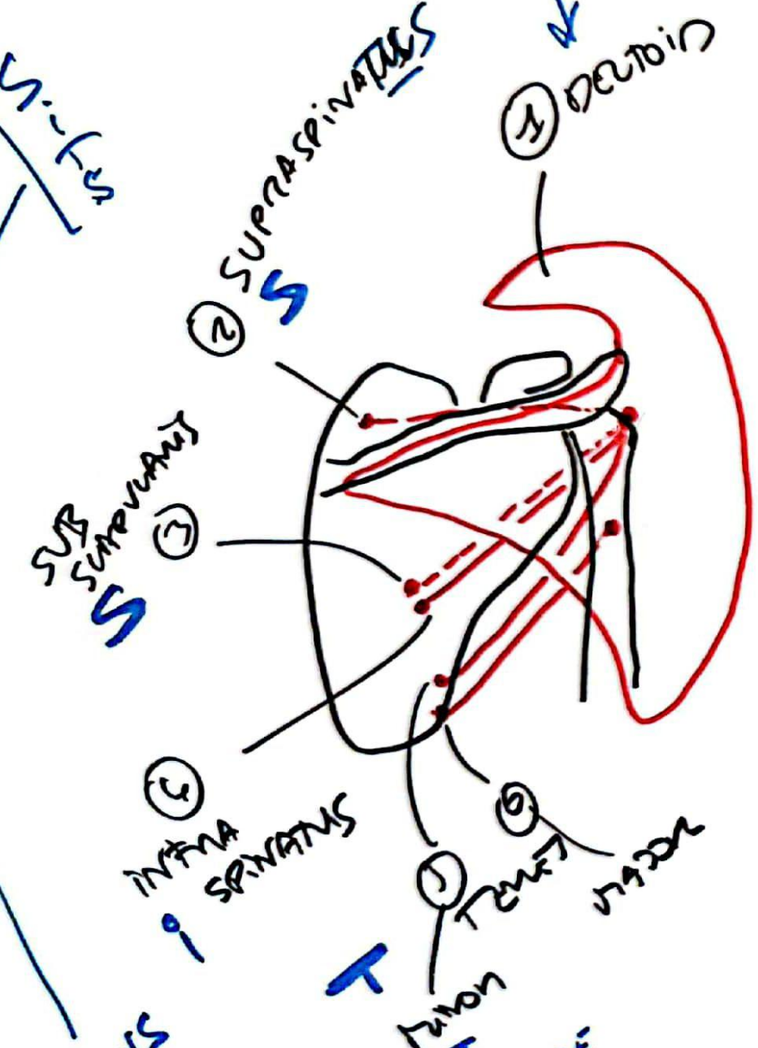

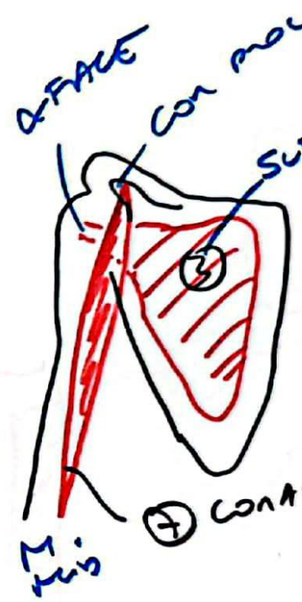

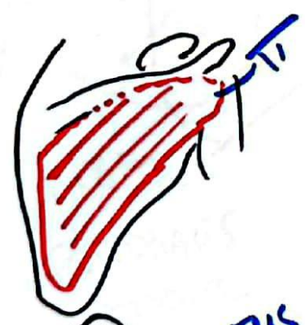

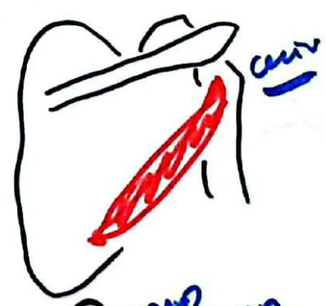

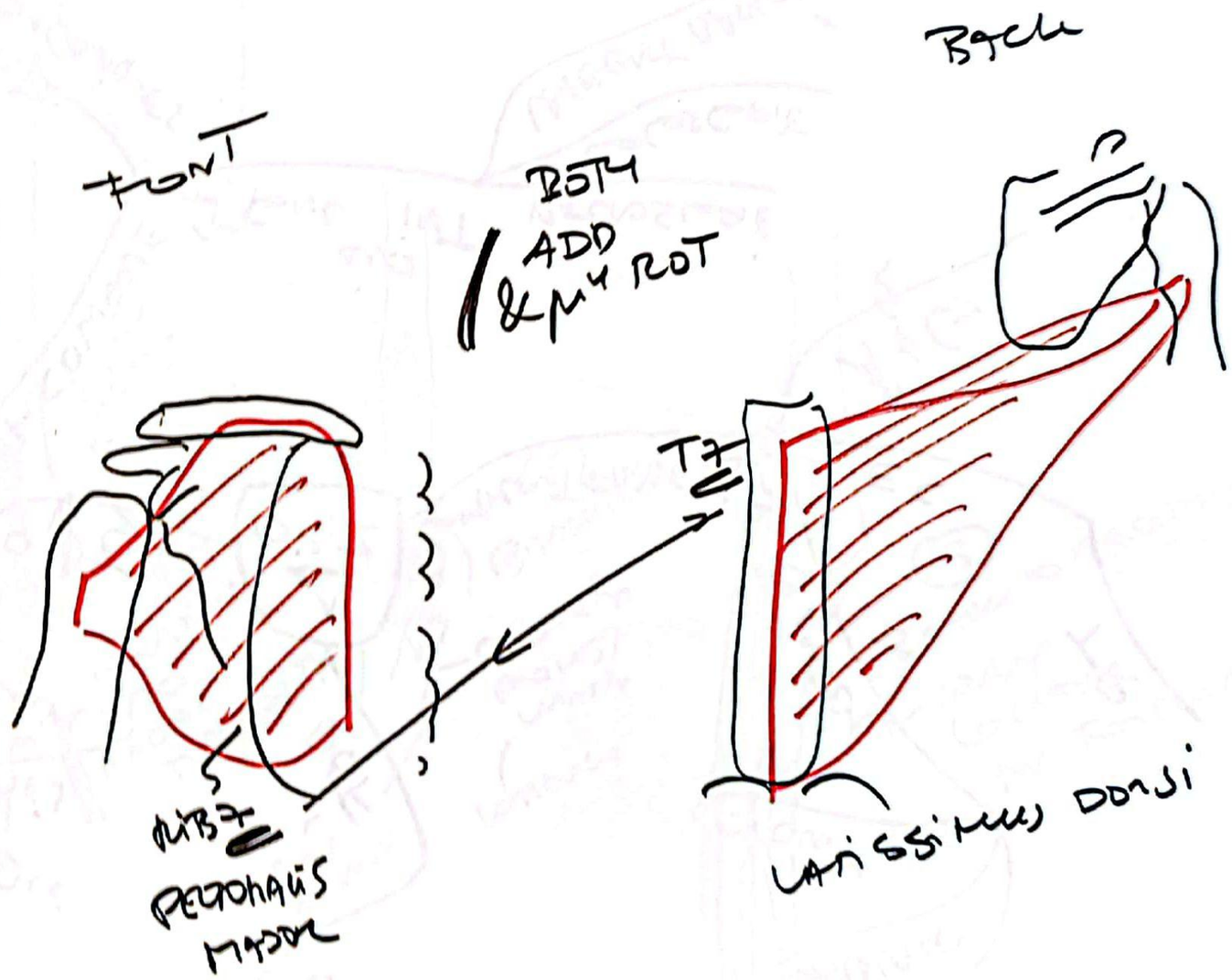
BACK
FRONT
BOTH
ADD
& MY ROT
T7
LATISSIMUS DORSI
PECTORALIS
MAJOR

PREDOMINANTLY FLEXING ELBOW

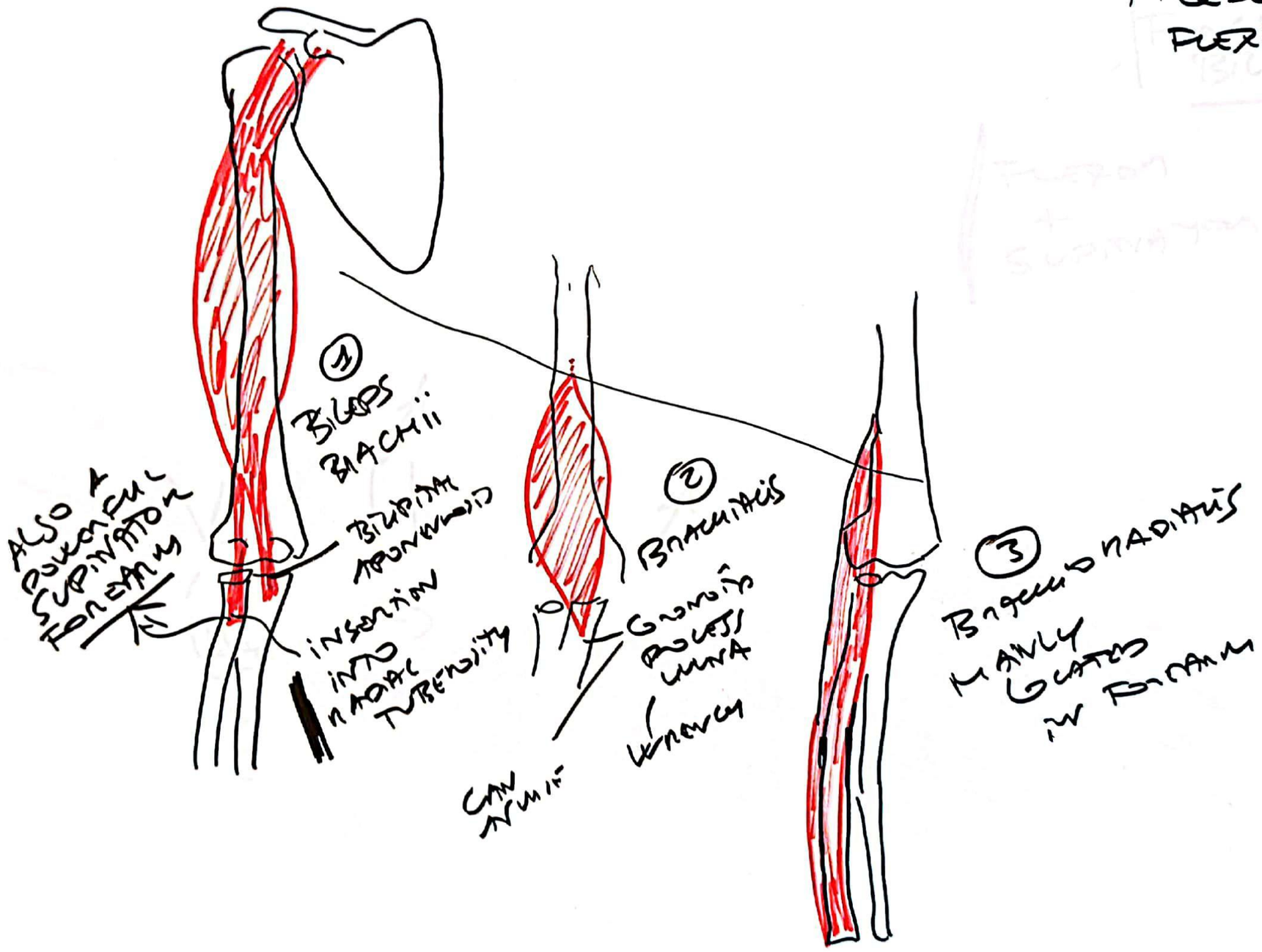

Q-4

Func Bldgs

Lotus

+

Sarvatos

7

PREDOM 4

EXTENDING

ELBOW

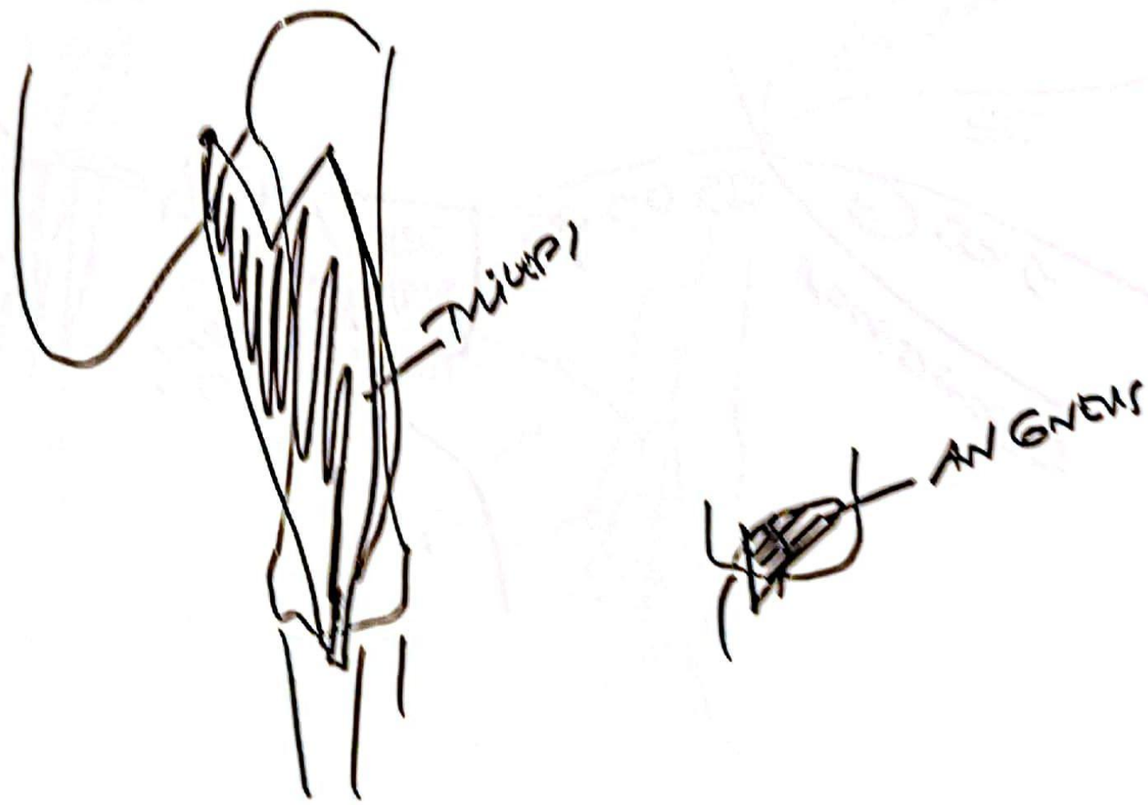

MM MOVE WRIST — FOREARM
FINGERS / EXTRINSIC
SMALL INTRINSIC HANDS

FOREARM
MM THAT
FLEX
/ \ WRIST
FINGERS

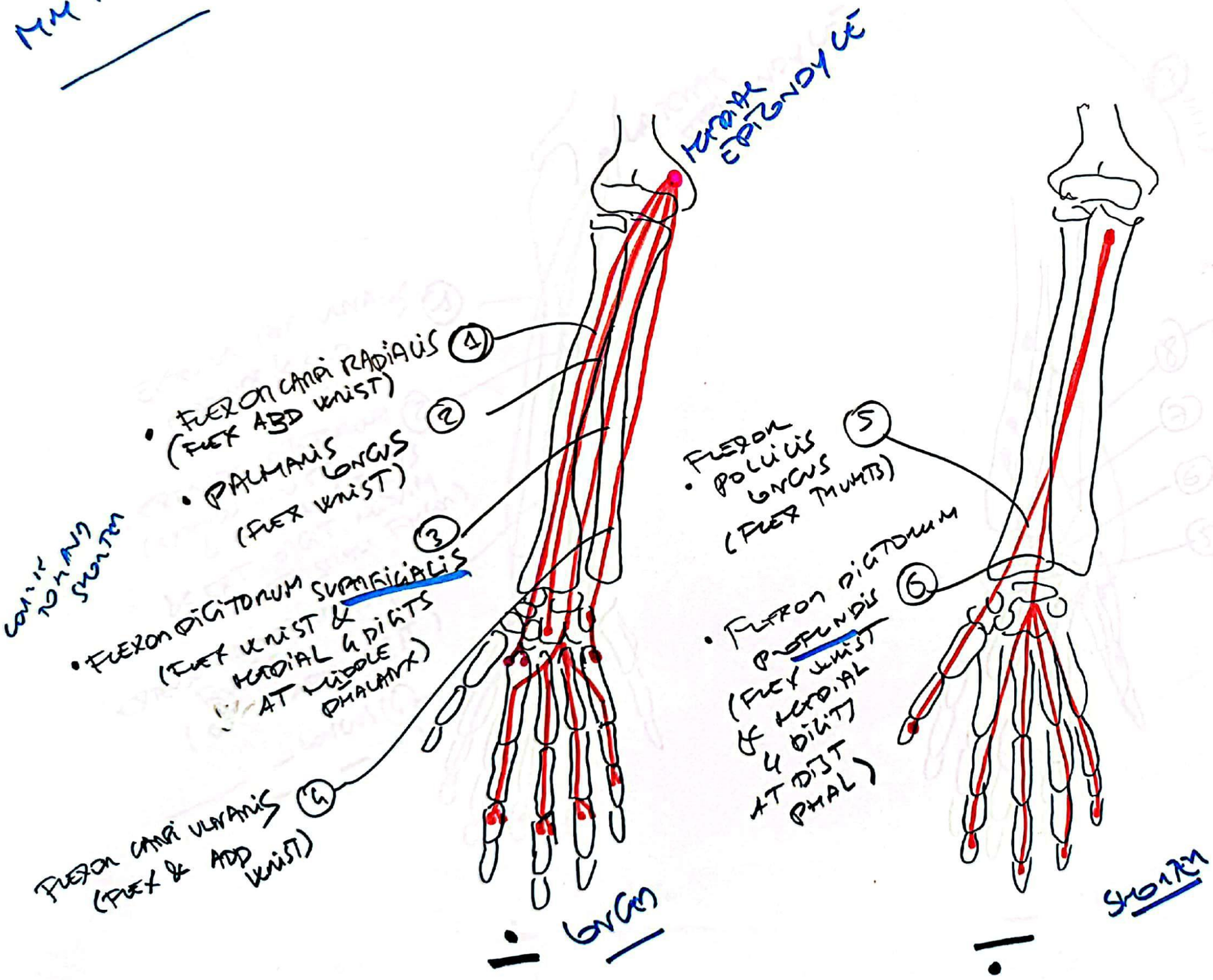

+ INTEROSSEUS MEMBRANE & RADIUS

WRIST ROTATION SHORTER

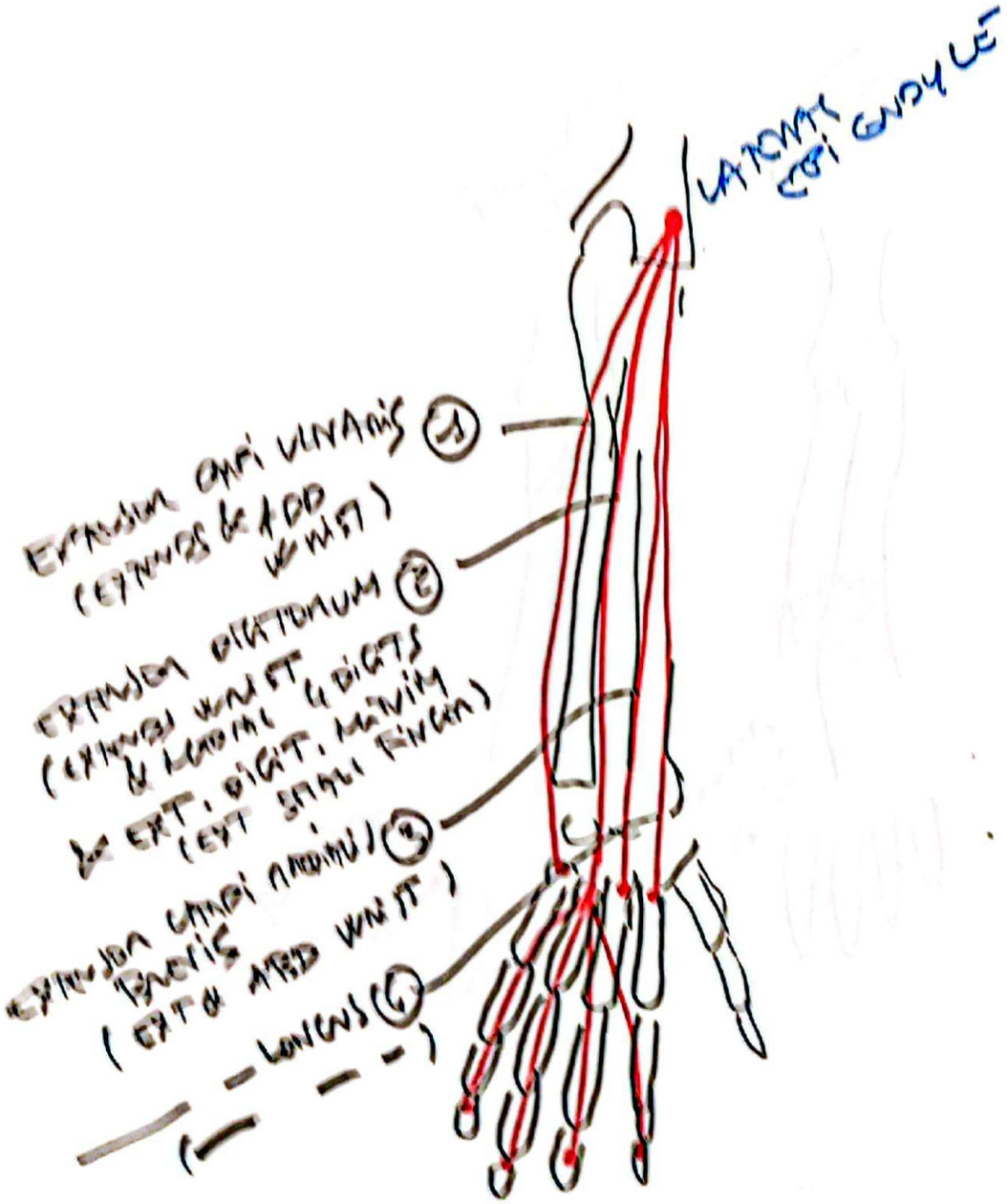
LATERAL EPICONDYLE
EXTENSOR CARPI ULNARIS (1)
(EXTENDS & ADD WRIST)
EXTENSOR DIGITORUM (2)
(EXTENDS WRIST & MCP & DIGITS & EXT. DIGIT. MINIMI (EXT SMALL FINGER))
EXTENSOR CARPI RADIALIS BREVIS (3)
(EXT & ABD WRIST)
LONGUS (4)

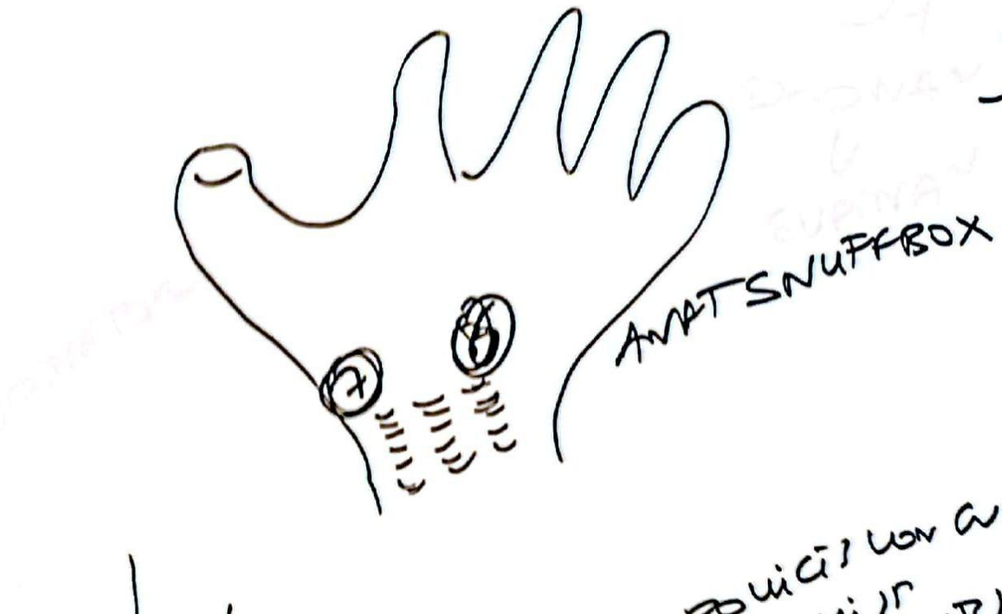
ANAT SNUFFBOX
(7)
(8)

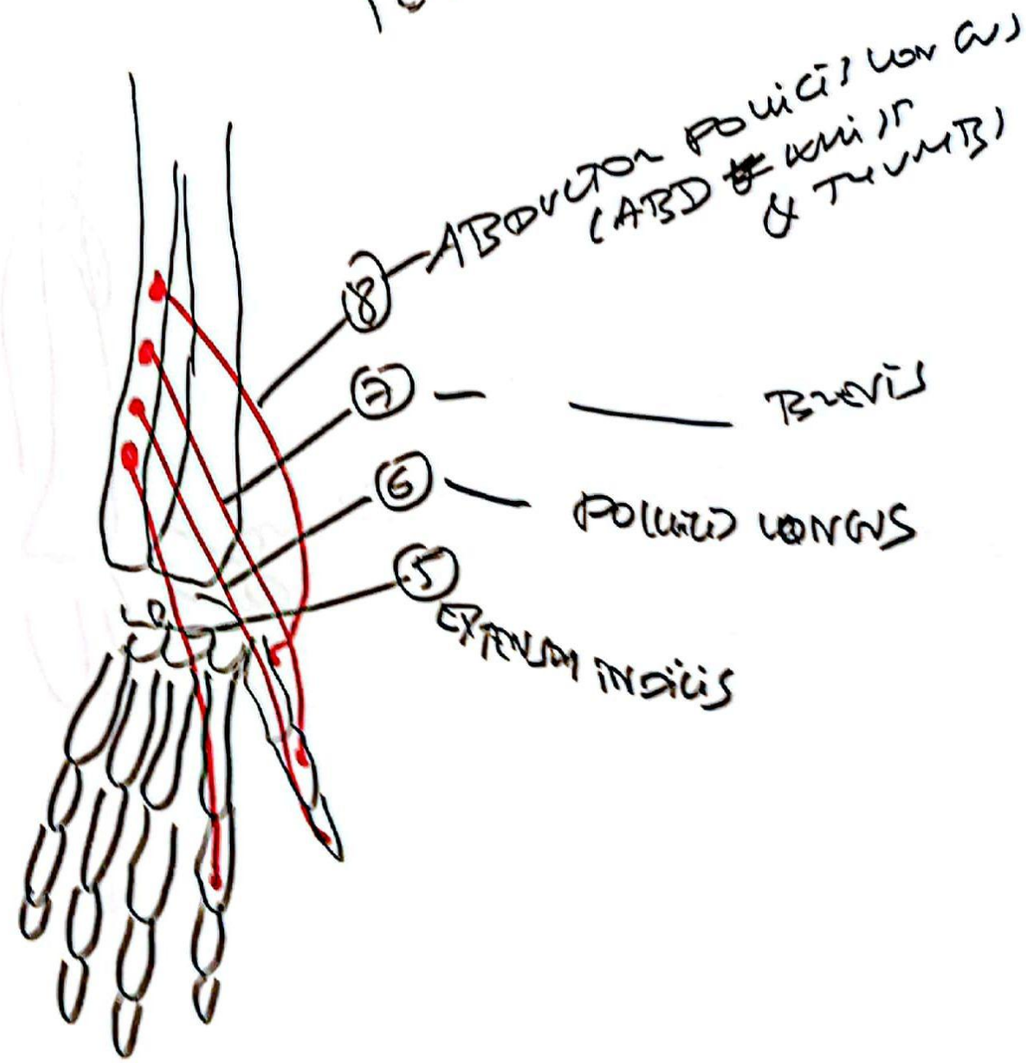
(8) ABDUCTOR POLLICIS LONGUS (ABD & EXTENDS WRIST & THUMB)
(7) BREVIS
(6) POLLICIS LONGUS
(5) EXTENSOR INDICIS

J1
PRONATION
&
SUPINATION

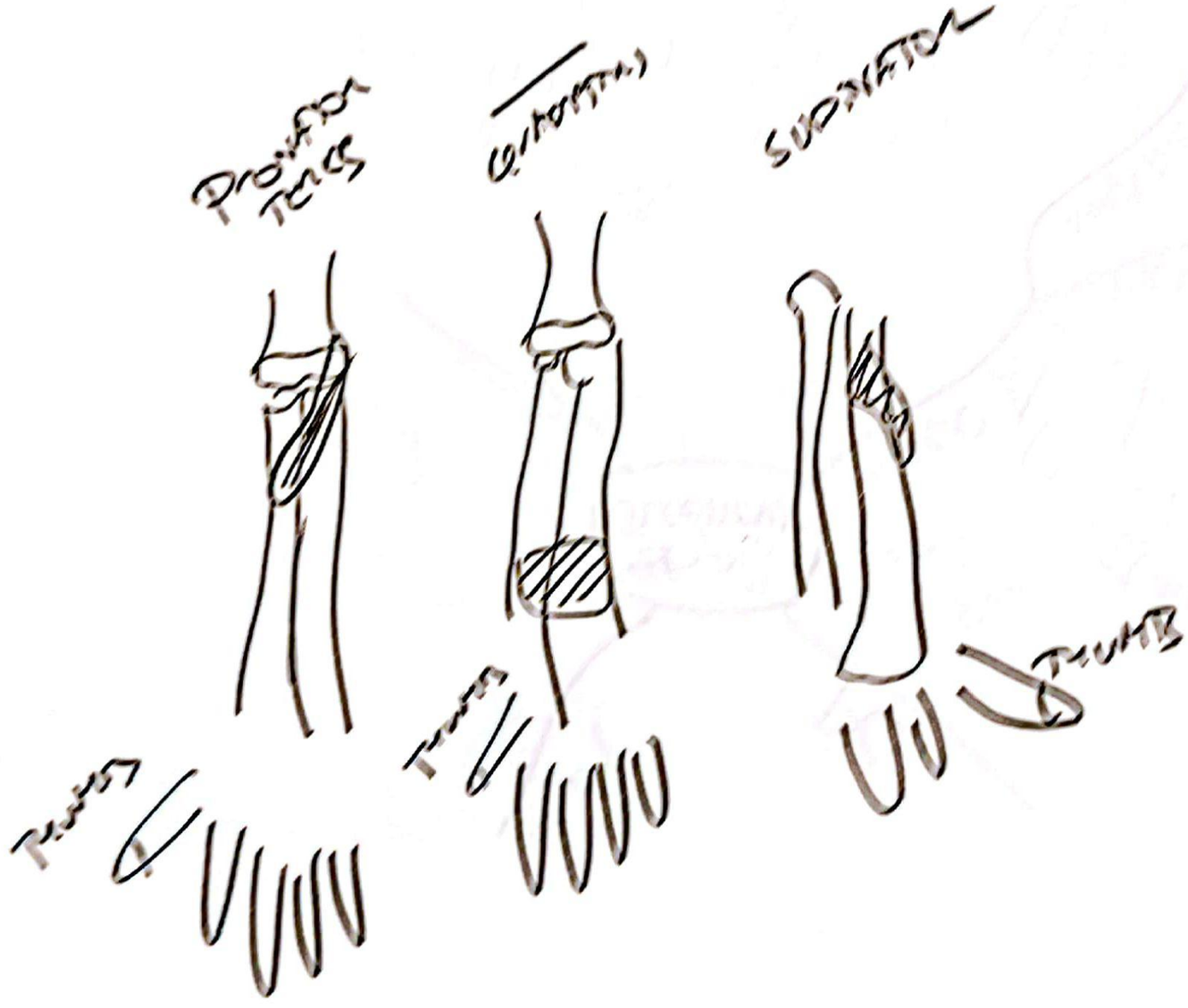

INTRINSIC HAND

POLICIS

POL 8 — FORARM → HAND!

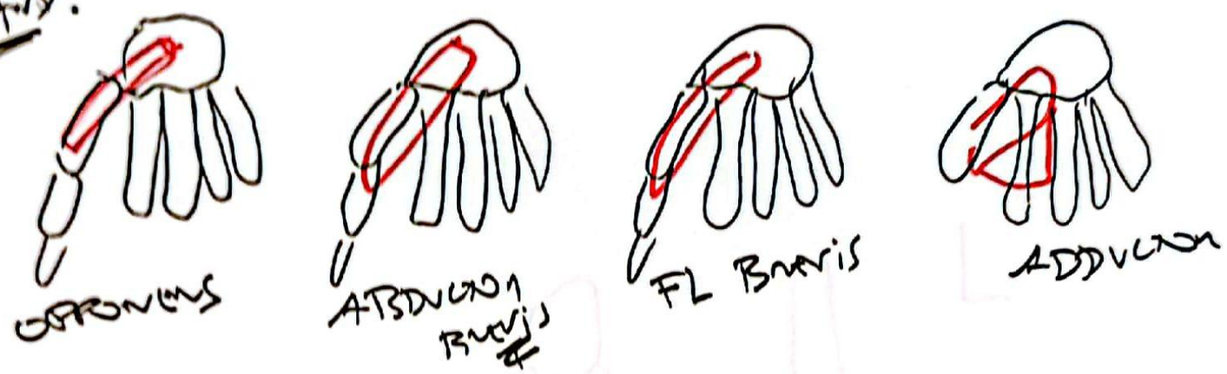

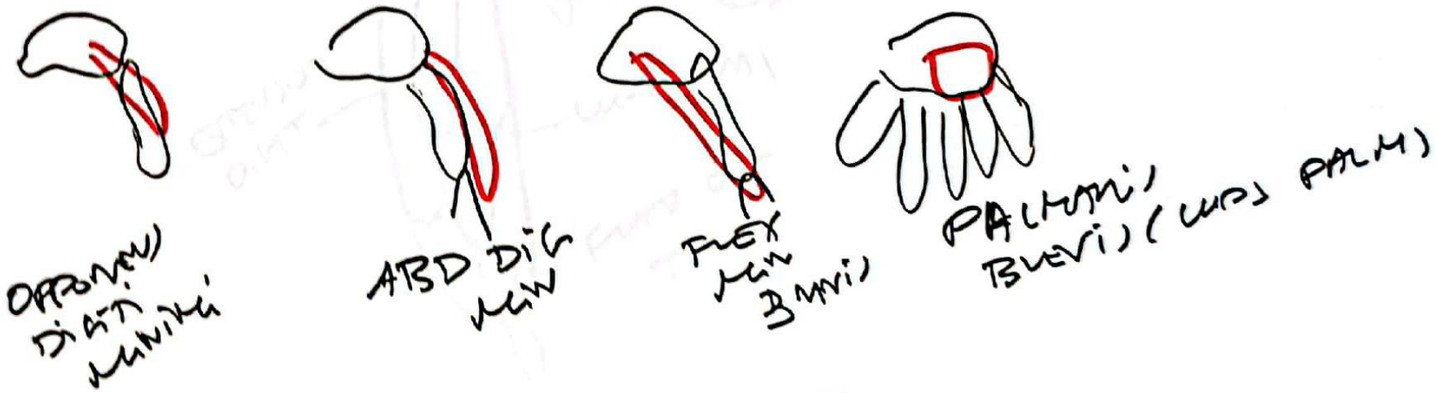

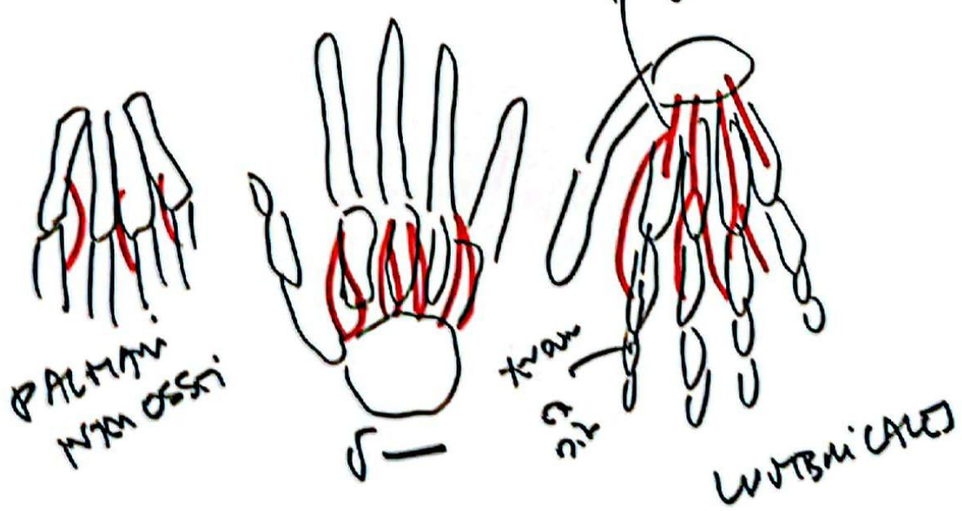

INTEROSSI LUMBRICALS ~~AB~~ ON THUMB


الأسمنت
رأس مدبب
ثقب
مدخل الهواء

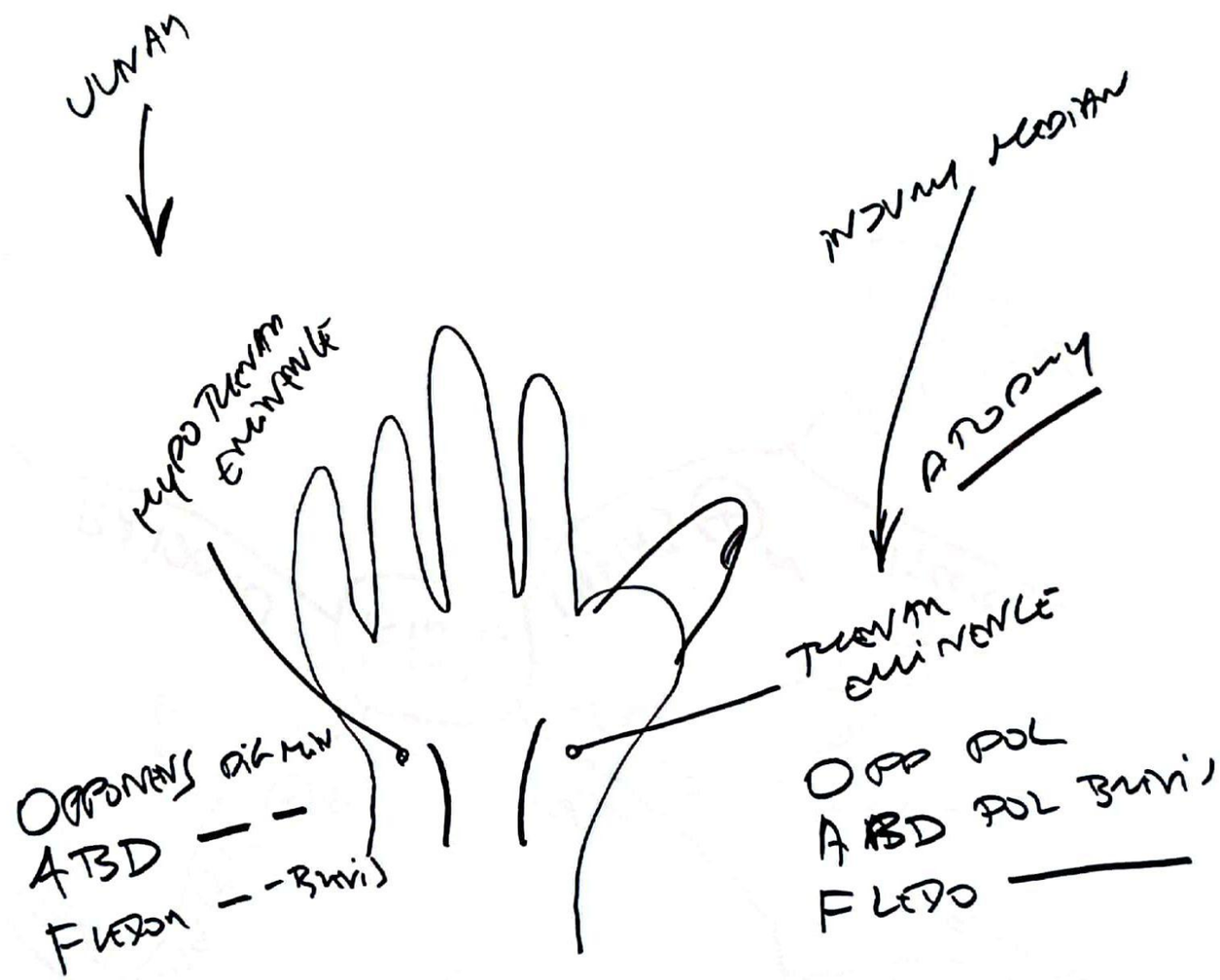
ULNAR
INTERNAL MEDIAN
ATROPHY
HYPOTHENAR EMINENCE
THENAR EMINENCE
OPPONENS DIGITI MIN
ABD
FLEXOR BREVIS
OPP POL
ABD POL BREVIS
FLEXO

EXTEND SPINE

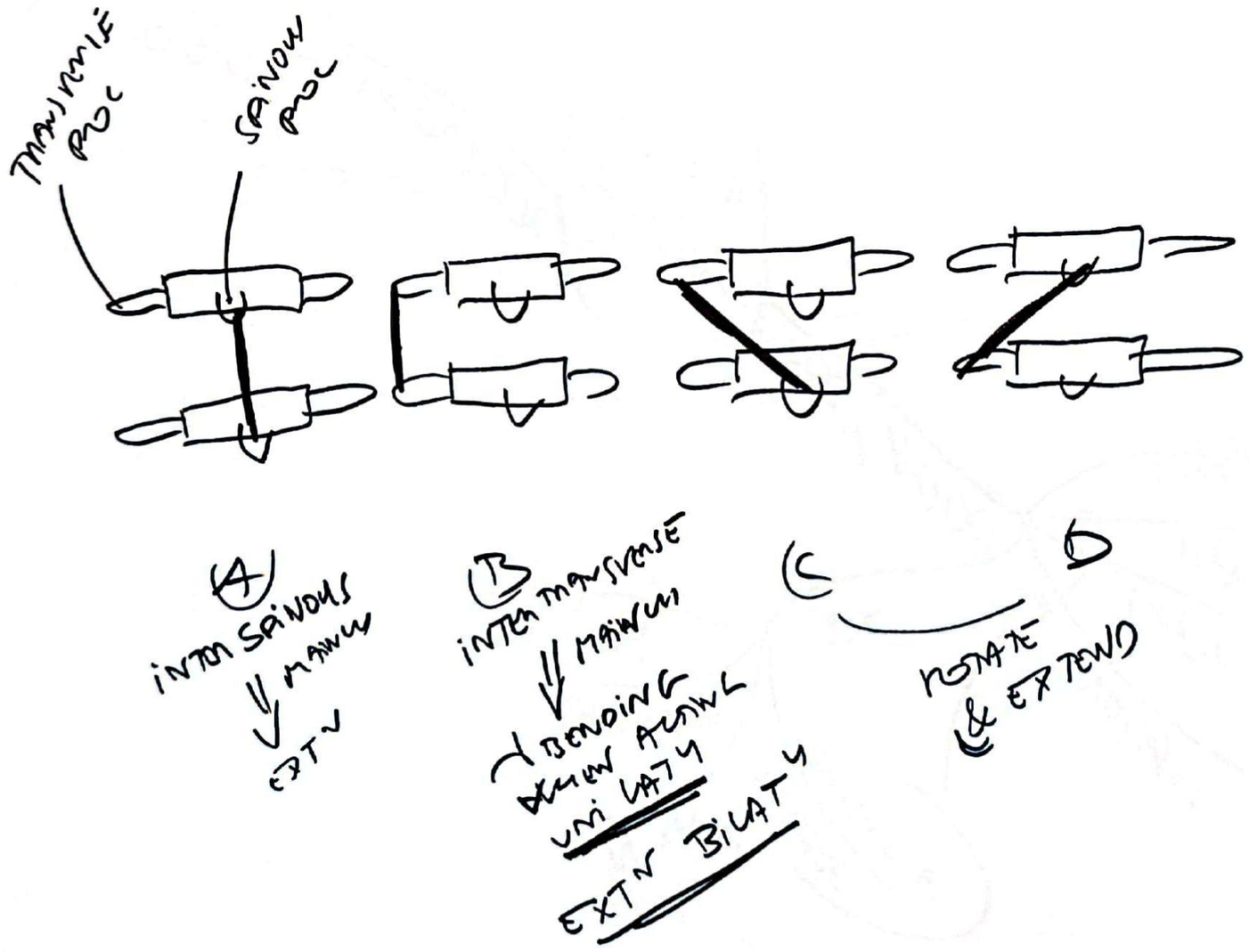

VARIATIONS IN SC CONNECTIONS

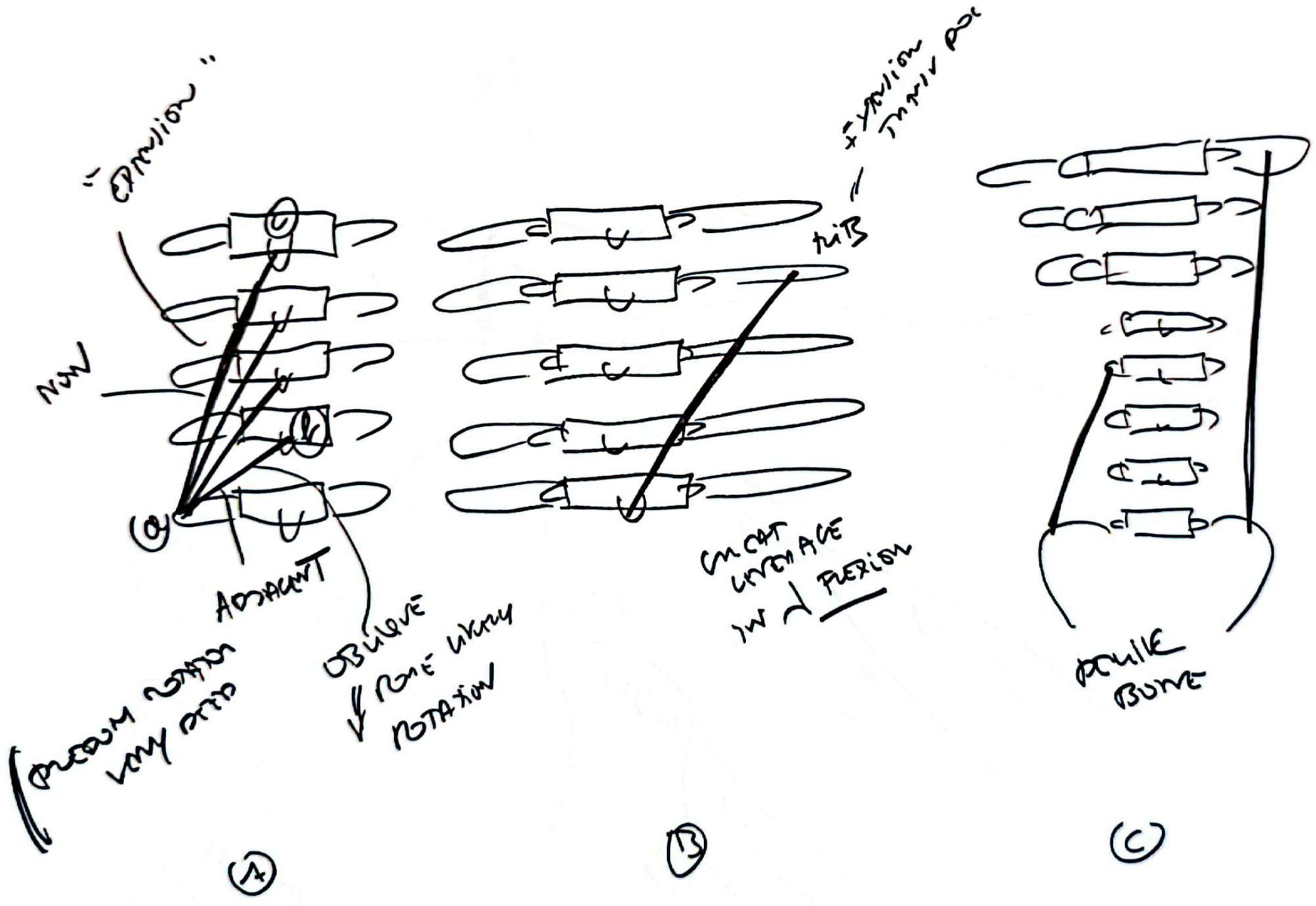

3 MUSCULOUS THAT EXTEND SPINE

1. SPLENIUS CERVICIS & CAPITIS — LOST & EPT
2. ERECTOR SPINAE — INTERMEDIATE
3. TRANSVERSOSPINALIS — OBLIQUE TRANSV-SPIN

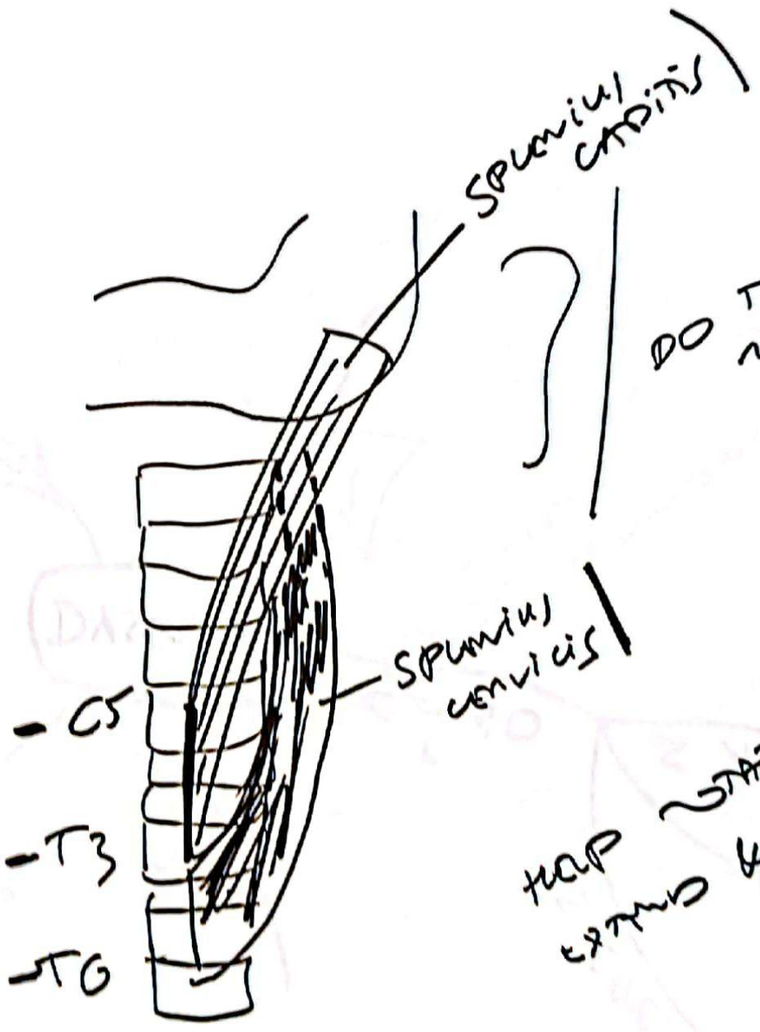

DO THE MUSCLE

S → SITUATION OF A SKULL

HEAD ~STATE HEAD CAPAC UNILAT EXTEND & NECK BILAT

TRANSV SPIN

T

S

ERECTOR SPINAE = S I L O

SPINALIS
ILIOCOSTALIS
LONGISSIMUS



PRED EXTEND SPINE

INCLUDING SKULL — TRANSV

SPINALIS
INFIRMLY
INTER CONN
SPINES
80 % VC
UPPER

ILIOCOSTALIS
AT LEAST ONE END
ATTACHES TO RIB

LOWER — RIB
— TRANS
SACRUM

EXT BILAT
ABDOMINAL
LOWER 80 % UNILAT
INCLUDING SACR & ILIAC

PRED TRANSV

UNILAT → ABDOMINAL
BILAT — EDP
SACRUM → SKULL

TRANSVERSO SPINALIS

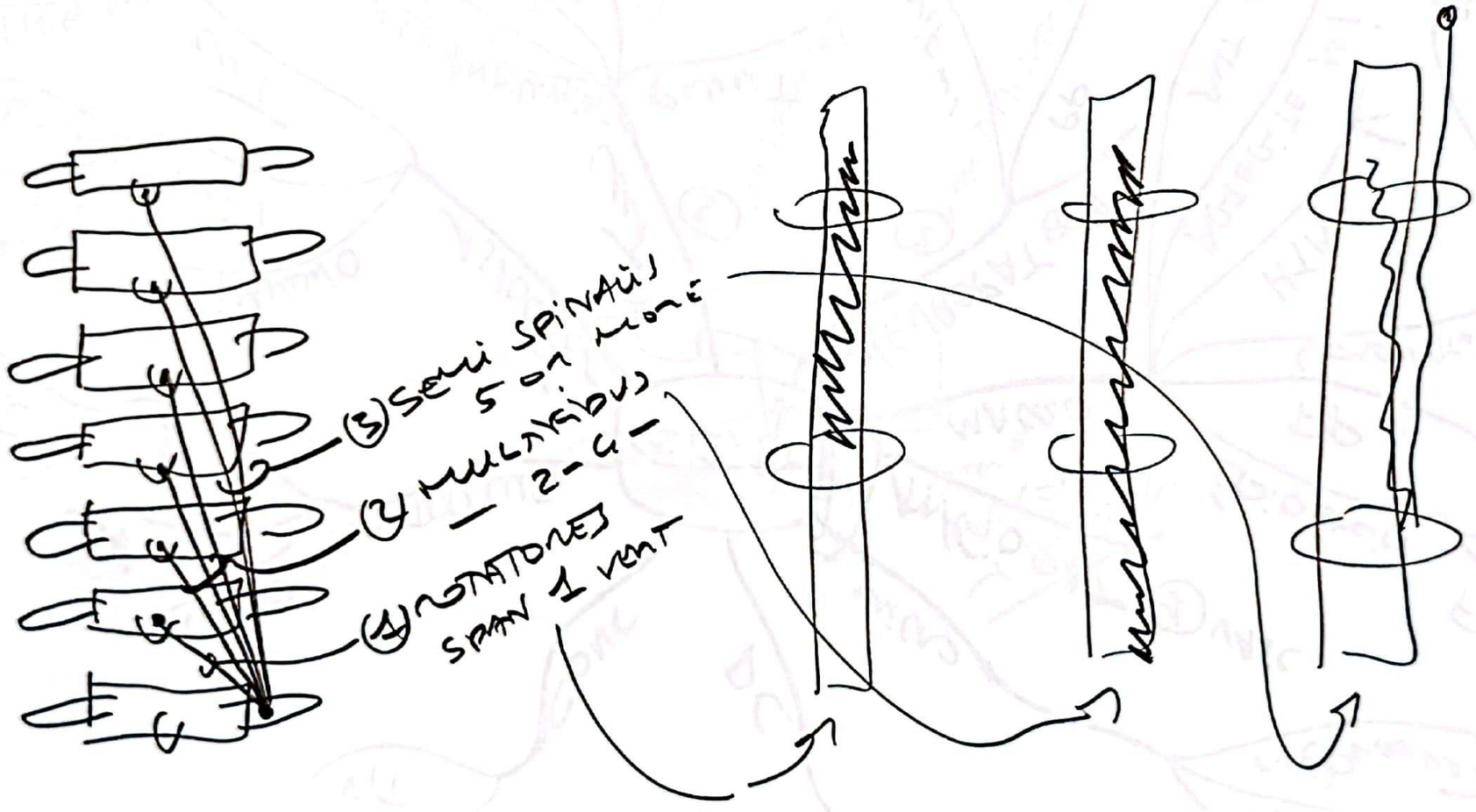

DIFFICULT TO CARTILAGE

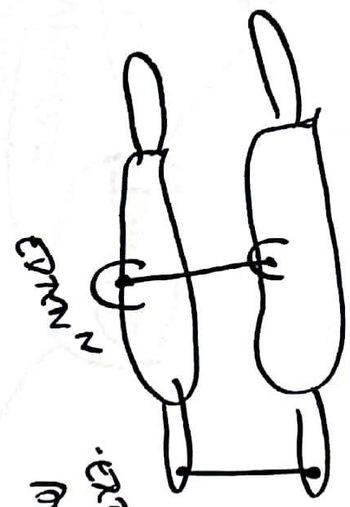

BENDING
NO / OK
EXAMS

DESCRIBE
ORIGIN

FLEXORS
NECK

FLEX
- NECK
- LOWER BACK & ABDOMEN

LONGUS COLLI CAPITIS
A α
M M
P II

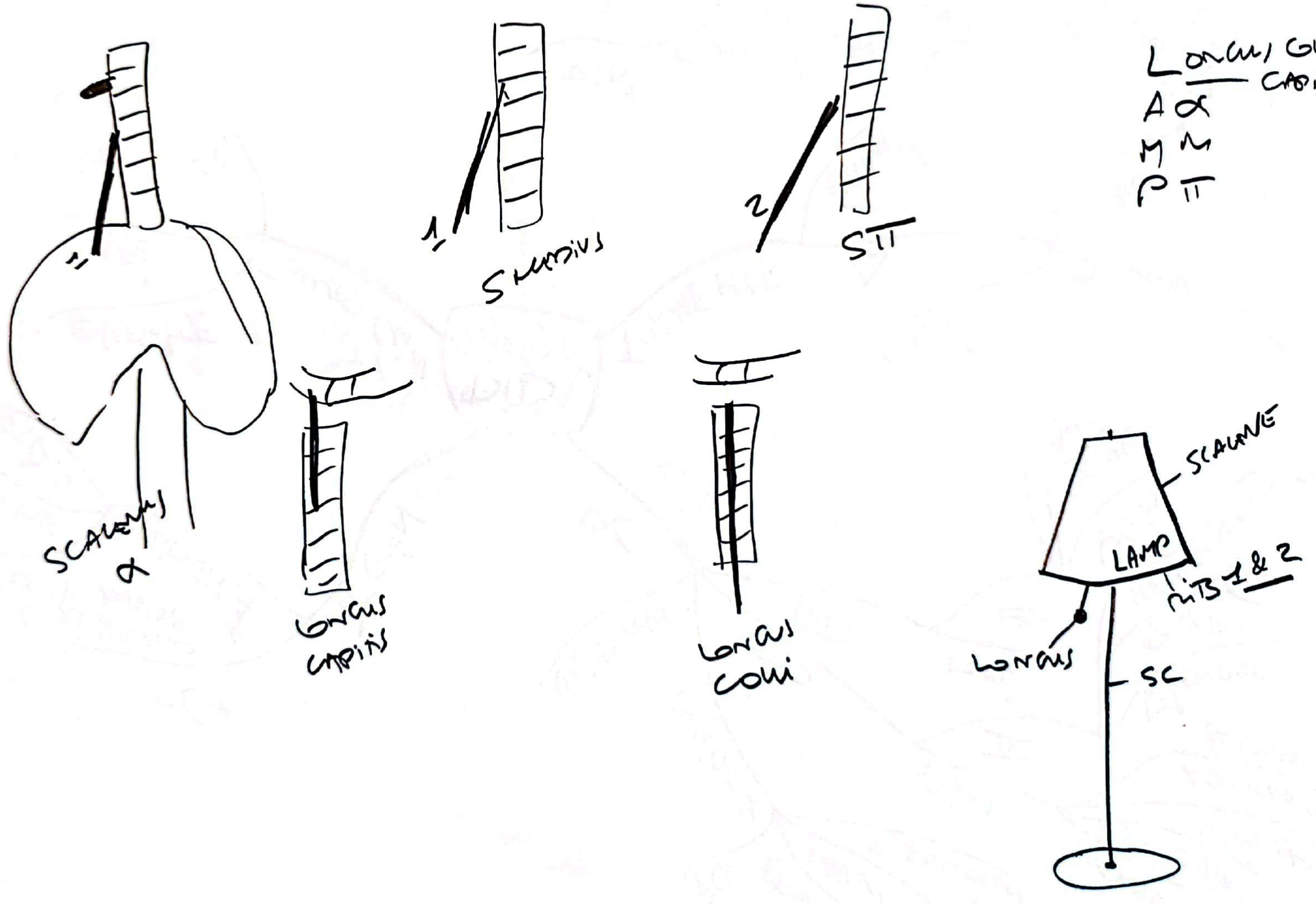

22

PULLDOWN LOWER BACK

PQR

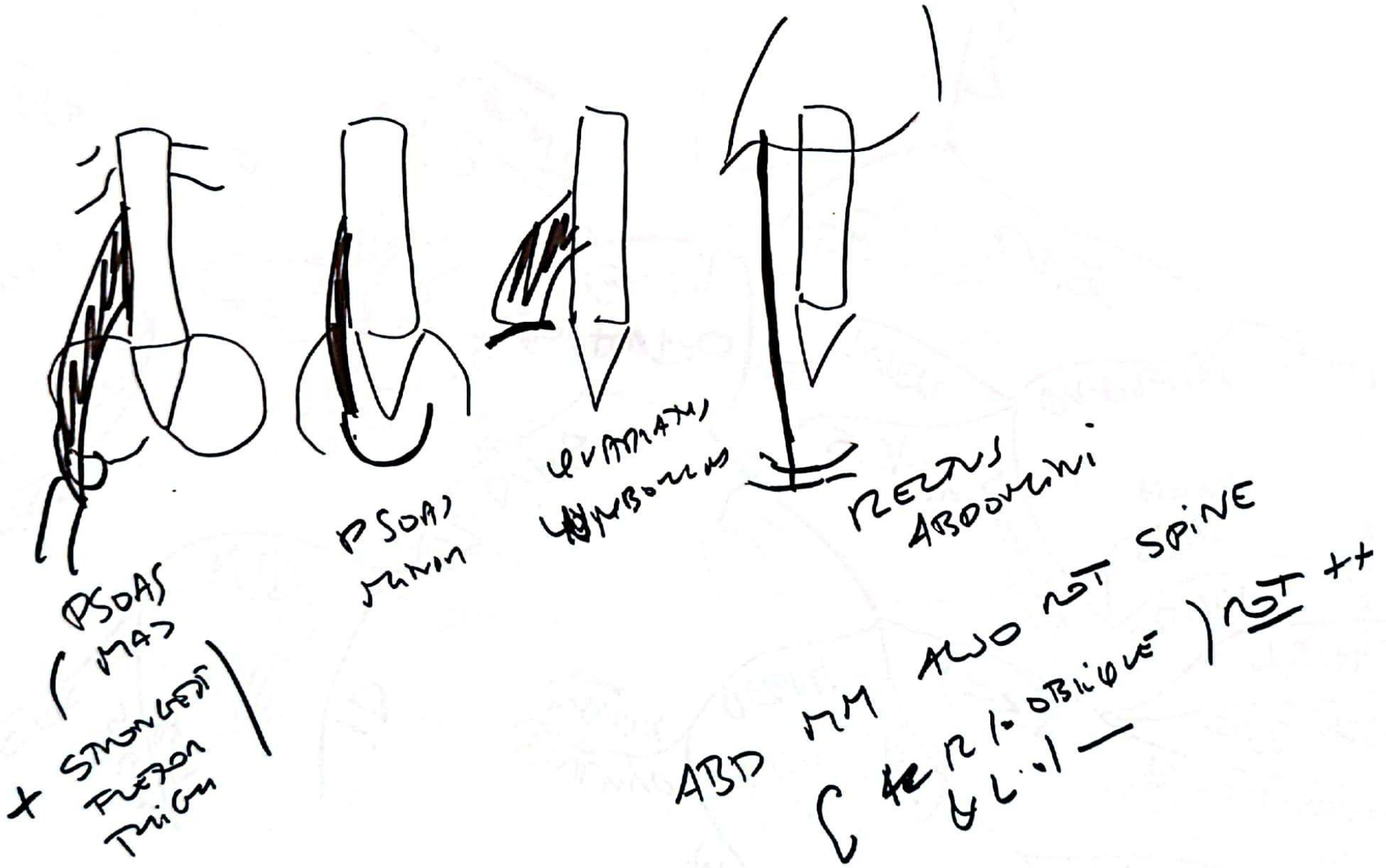

SMALL THAT MOVE SKULL

- LITTLE TINY MM THAT ATTACH TO & MOVE SKULL
- EXTENSORS AUTONOMY
- ATLAS
- ATLAS

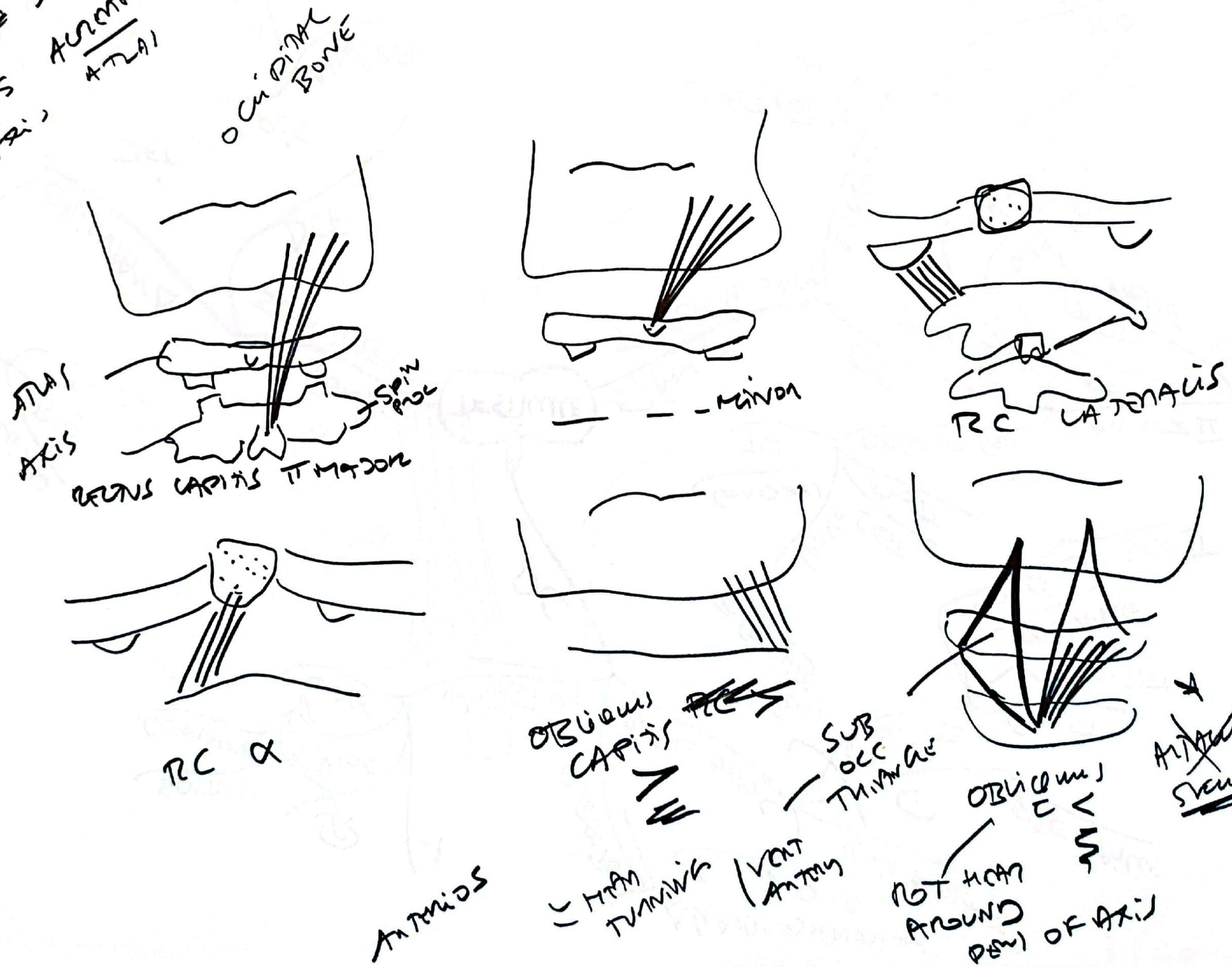

SCM

BOUNDARIES SUPG △

ROTATORS

↓

SPINE ROTATE

SPLENIUS

ERECTOR SPINAE

SEMISPIN

MULTIFIDUS

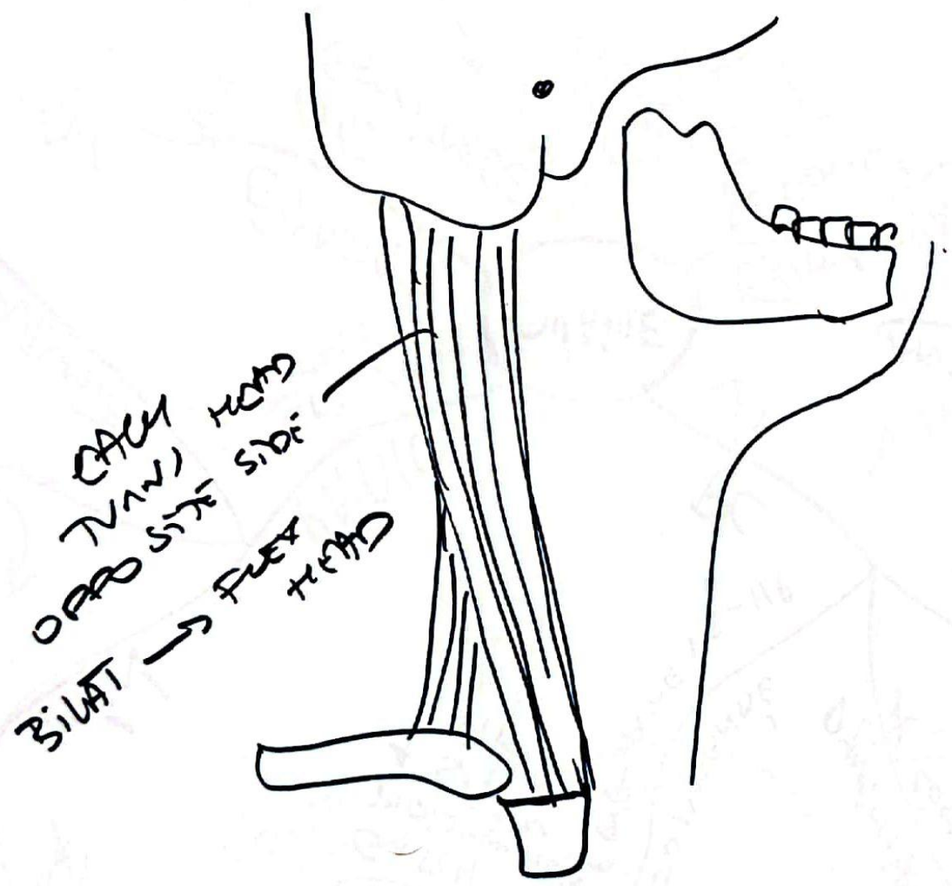

DIAPHRAGM


SEMI CIRCULAR LINE
THE MORGAGNI
AND PERITONEAL
DIVIDES
BY 7 CRIS VET
(MORE
VERT)
VC → α γ
POSTERIOR
ATTACHED
LOWER
6 RIBS
1
2
MC SIDE
TERMINATION
EDGE
& VACCAL
TERMINAL
POST
INP
DURING
INSPIRATION
→ LUNGS
& LUNGS
& CHEST CAVITY
EXPAND
4
H H
A O
& TD
SOMEE
AZYGOS, AN
3
PSOAS M
5
6
VERTEBRO
COSTAL Δ
⊖ P TUMOR
BE
PRODUCED
IN
RIB 12
AGAINST
VC
FOR BOCH DAGER
IN VERTEBRAL
VERTEBRAL ARD RISCERA
L
L LUMB
E3
MID AXILLARY
AT NIPPLE LINE
CITY ALL ALL
BY ELEVATING
RIBS
→ FIG 26
GRAVITY
DUE VERTS
• RIGID
PLEURA
AIR
R
C RIDGE
FUSED
WITH
FIBROUS PERIC

BUCKET & PUMP HANDLE MODELS OF INSPIRATION

A



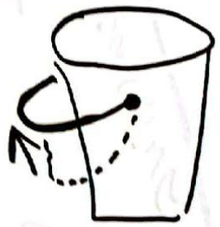

ELEVATING BUCKET HANDLES
↑ ASPECT RIBS
↑ DISTANCE BETWEEN HANDLES
↑ ↓ DIAMETER

B

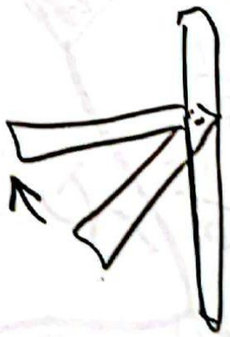

HANDLE CHANGE = STERNAL MOVEMENT
↑ ∝ π

- INSPIRATION ↑ CHEST CAVITY THROUGH C DIMENSIONS
& B&P MEC

27

ELEVATING RIBS
B & P NEC

LEVATORES COSTARUM

SERRATUS TI

PECTORALIS MAJ
MIN

SERRATUS α

SCM

SCALENE

EMERGENCY

CLAVICULAR DIS

Min Motor

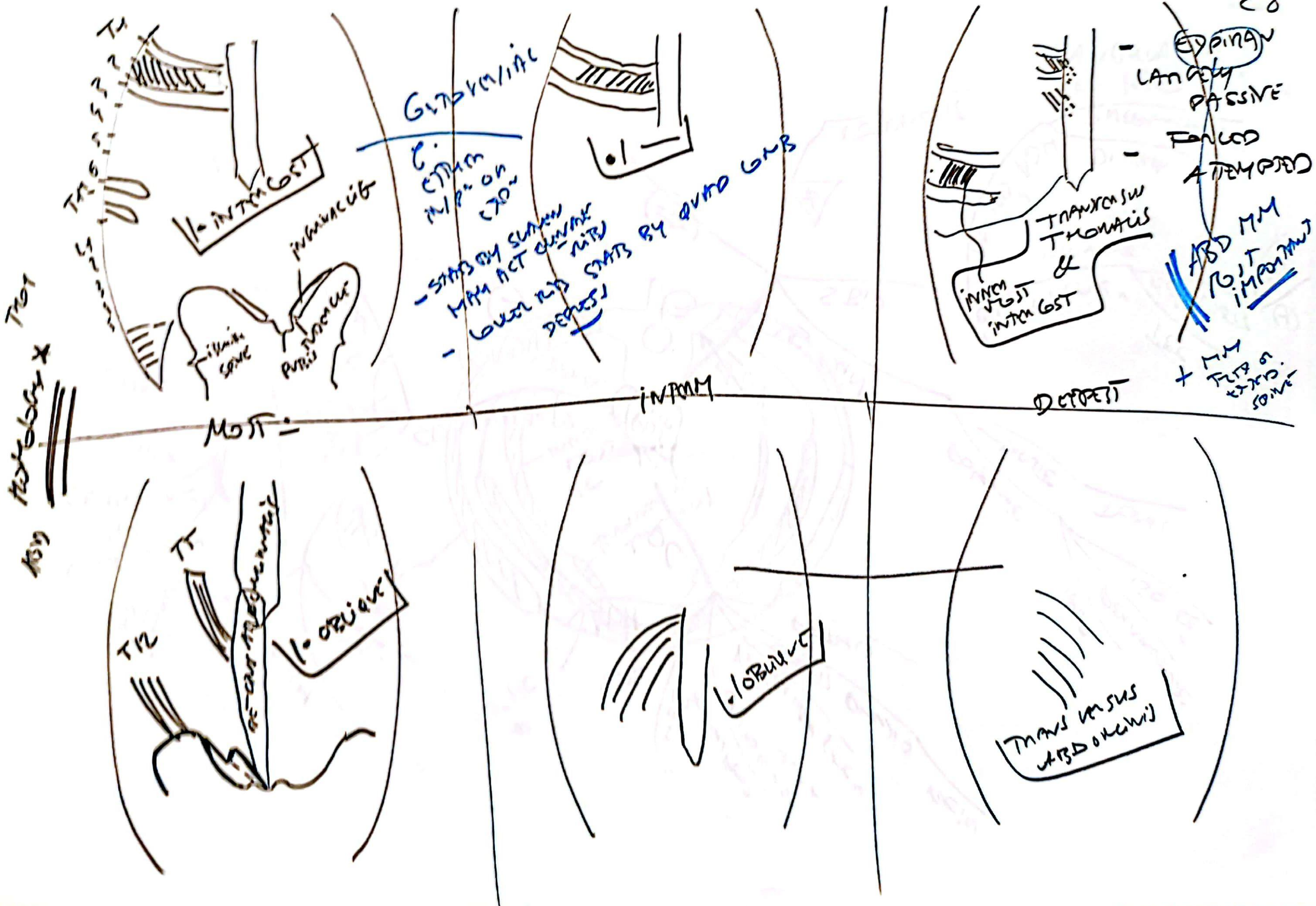
TRANSVERSUS
T12
INTERCOST
INTERNAL OBLIQUE
ILIOINGUINAL
PUBIC TUBERCLE
GLIDERMAIRE
C. ETHICAL IMPLICATION
- STABS BY SURGEON MAY ACT DURING NERVE
- LOWER RIB STABS BY QUADRATUS LUMB
DEPRESS
INTERNAL
MOST
- EXPIRATION
LARGELY PASSIVE
- FORCED ATTEMPTED
TRANSVERSUS THORACIS &
INTERCOST
ABD MM
MOST IMPORTANT
+ MM FLEX & EXTENS. SPINE
DEPRESS
EXTERNAL OBLIQUE
T12
T11
INTERNAL OBLIQUE
TRANSVERSUS ABDOMINIS

ANGULATION OF IOIC ...

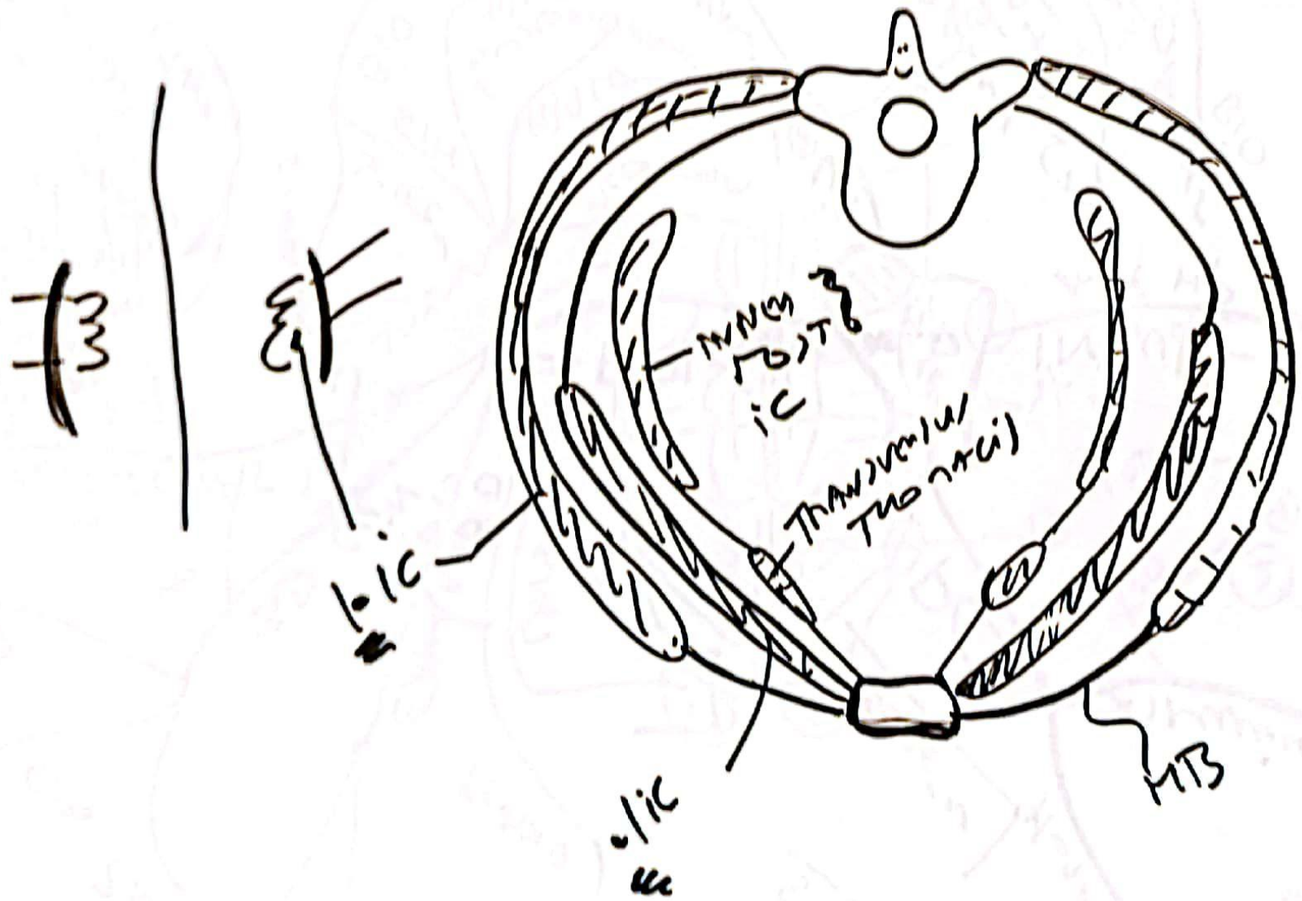

R

RECTUS ABDOMINIS & OTH ABD MM

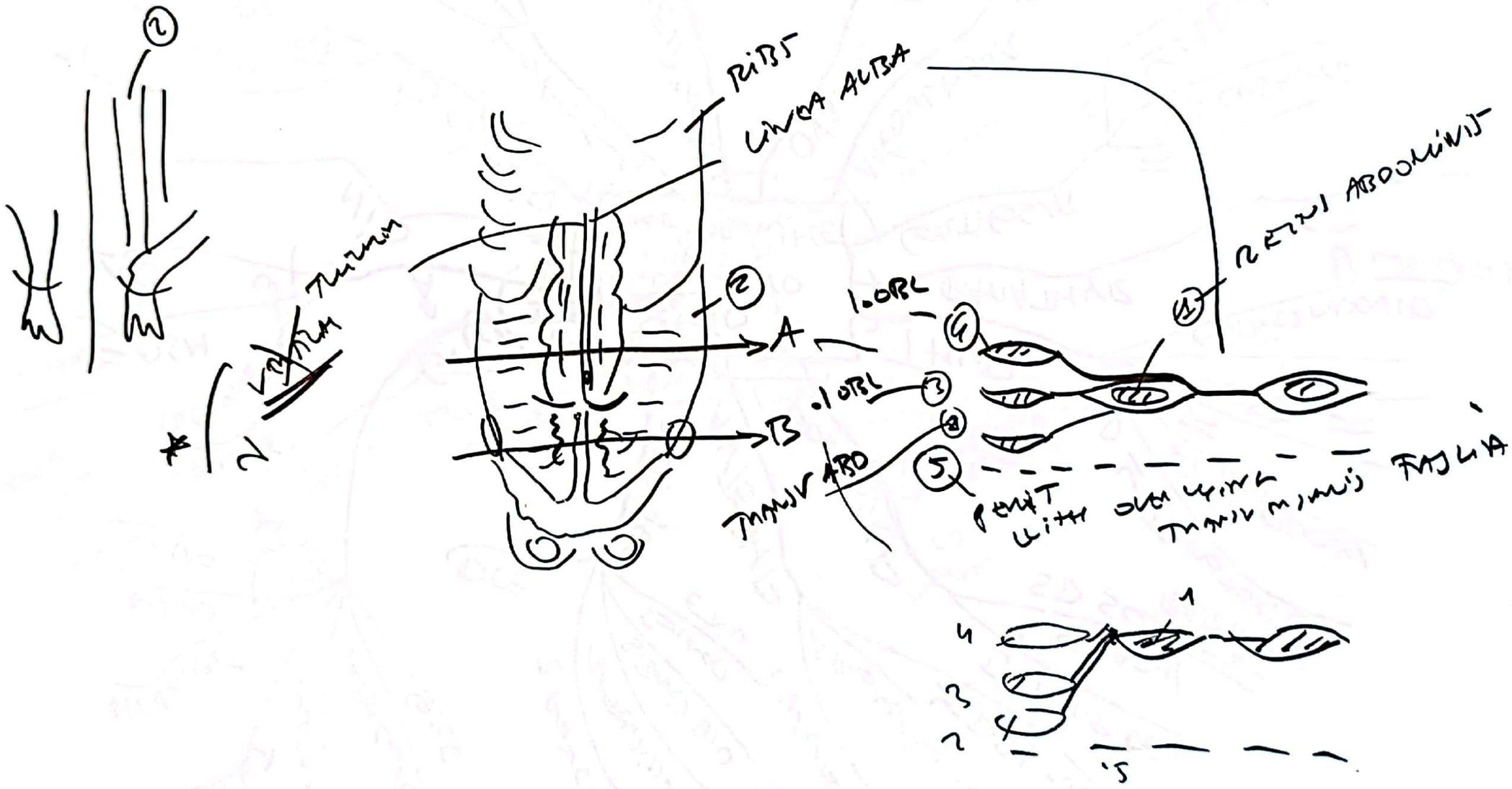

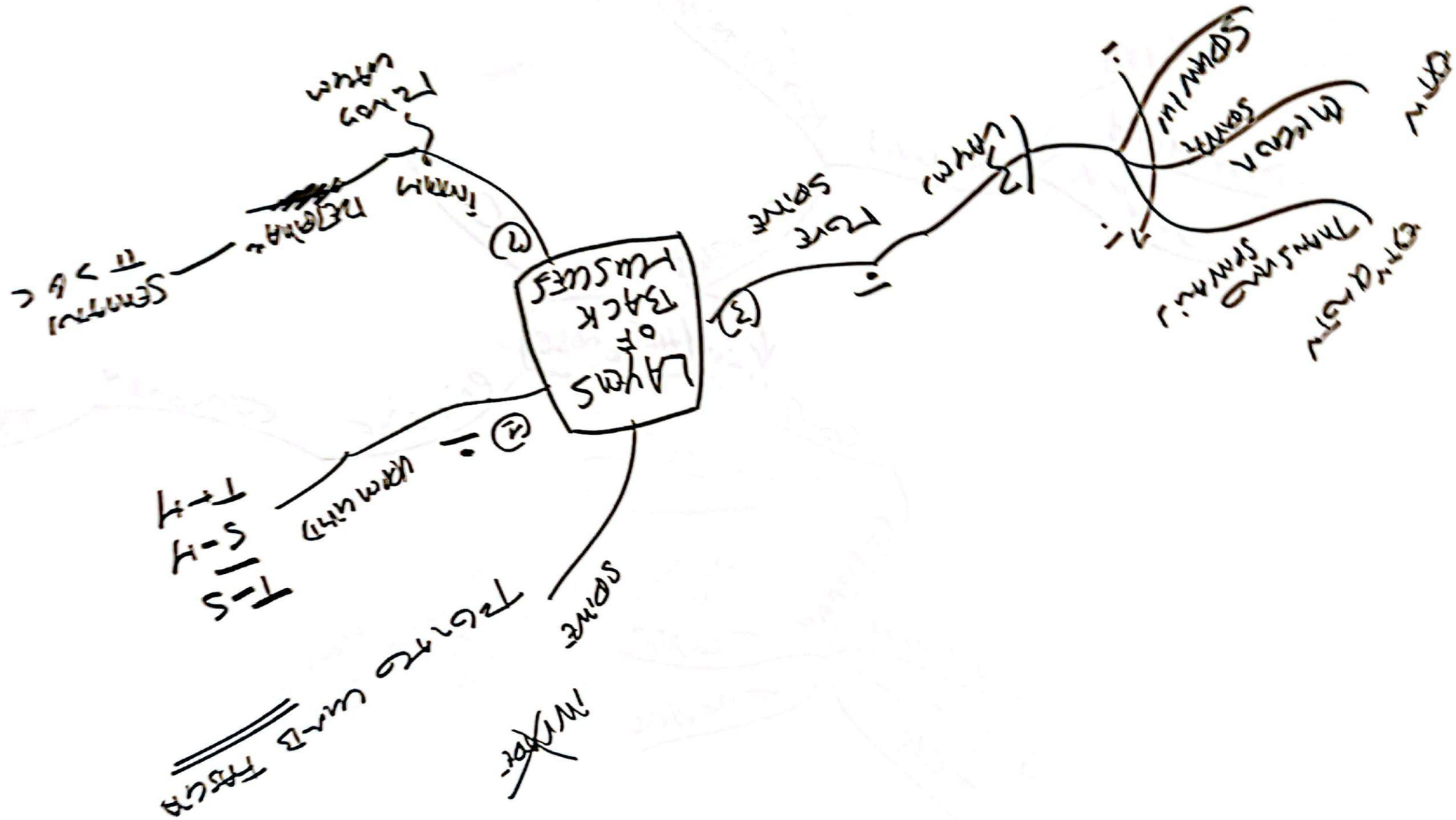
LAYERS OF TRACK FAULTS
SPINE
TRACK WIDE FAULTS
T-S
S-Y
T-Y
(1)
(2)
(3)
(4)
SPINE
TRANSVERSE SPINAL
DIAGONAL SPINAL
SPINAL
TRACK SPINE
SPINAL
FAULTS WITHIN
FAULTS BETWEEN
SEMITRAL
T > S

SUBCLAVIUS

? PUBIC CLAV DUCT & GREEN MAY BE

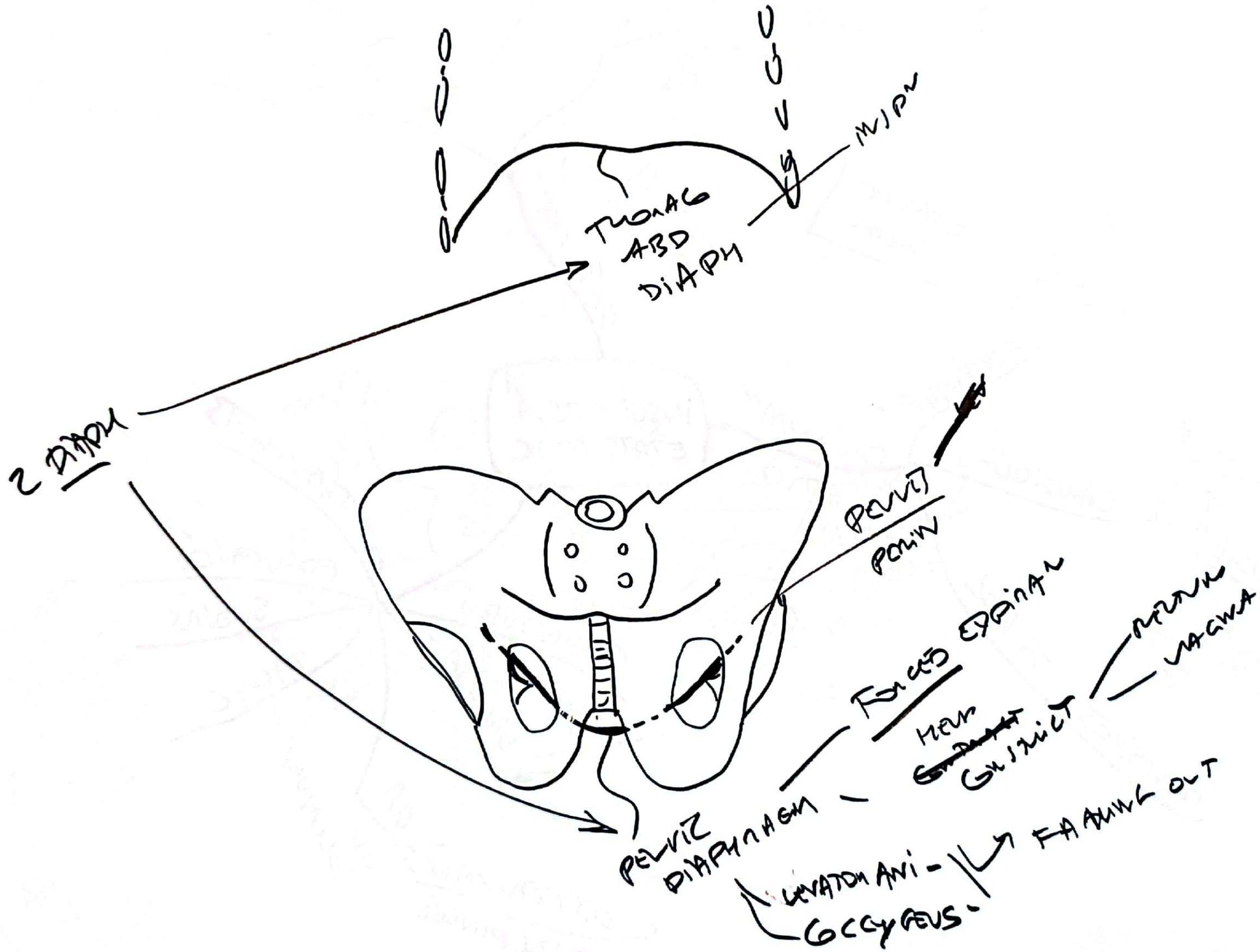
2 DIAPH
THORAC
ABD
DIAPH
MJPN
PELVIC
PERIN
FORCES EXPIRATION
HEAR
GUJRIET
RECTUM
VAGINA
PELVIC
DIAPHRAGM
LEVATOR ANI -
COCCYGEUS.
FALLING OUT

PELVIC DIAPH
> VIEW OF
LEVATOR & COCCYGEUS
ANI

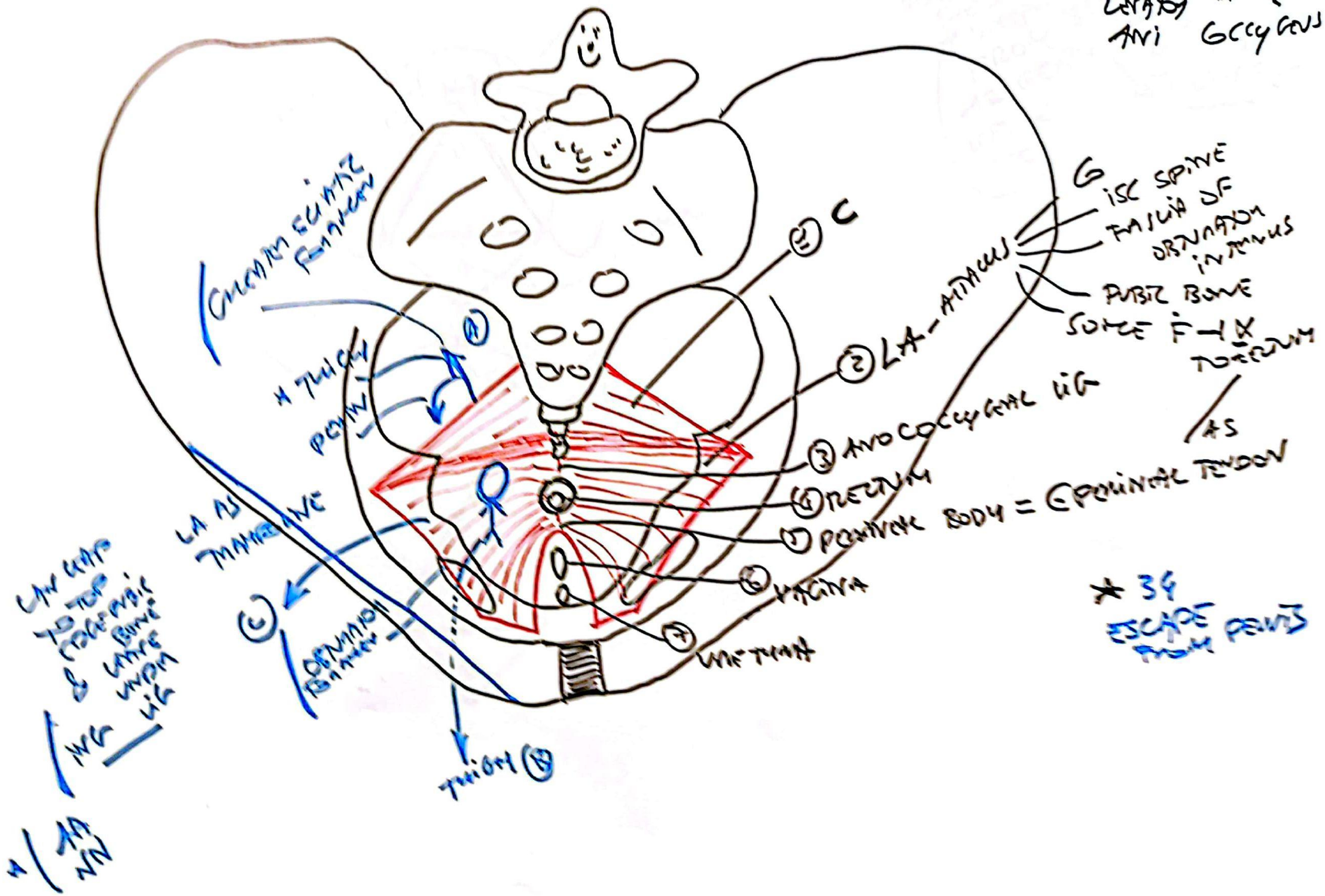

~~PELVIC DIAPH~~
~~FROM ABOVE~~
PELVIC DIAPH FROM BELOW AS PERIN → ANAL & UROGEN TRIANGLES
USED TO

♂

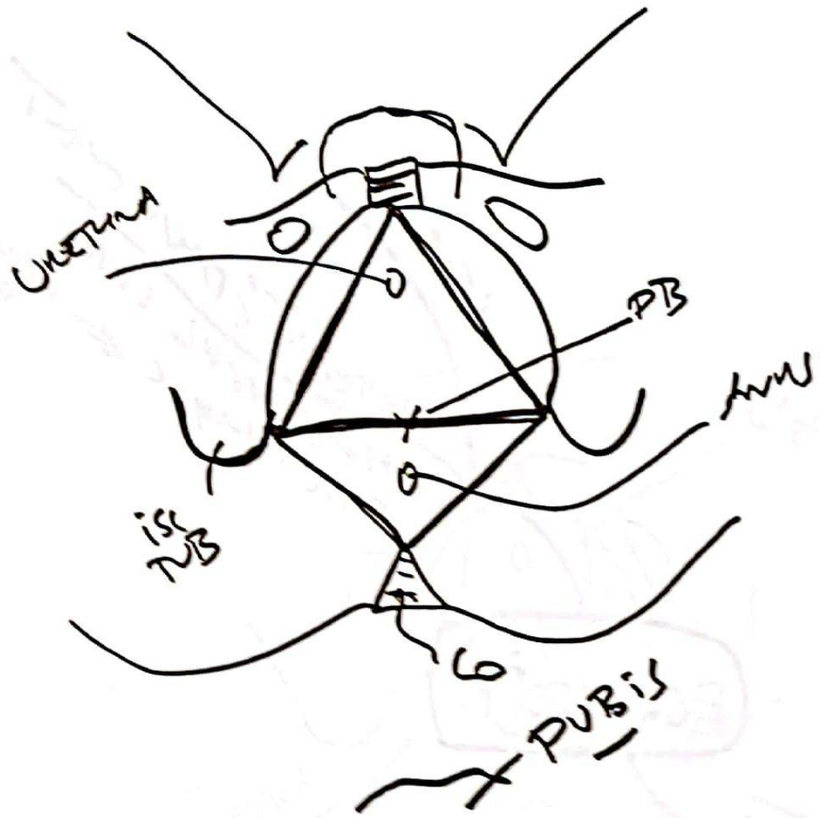

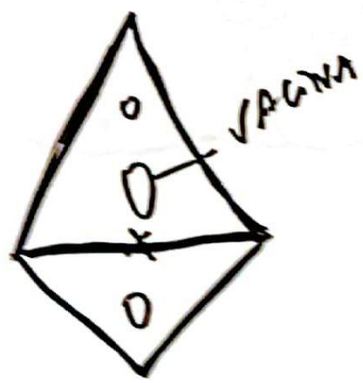

♀


GAP AROUND URETHRA & VAGINA
SEAL → UNOGAV DIAPH
GAMETE DIAPH
LA
C
VAGINITIS, GAMETY VAGINA
SPAYM

PERIN

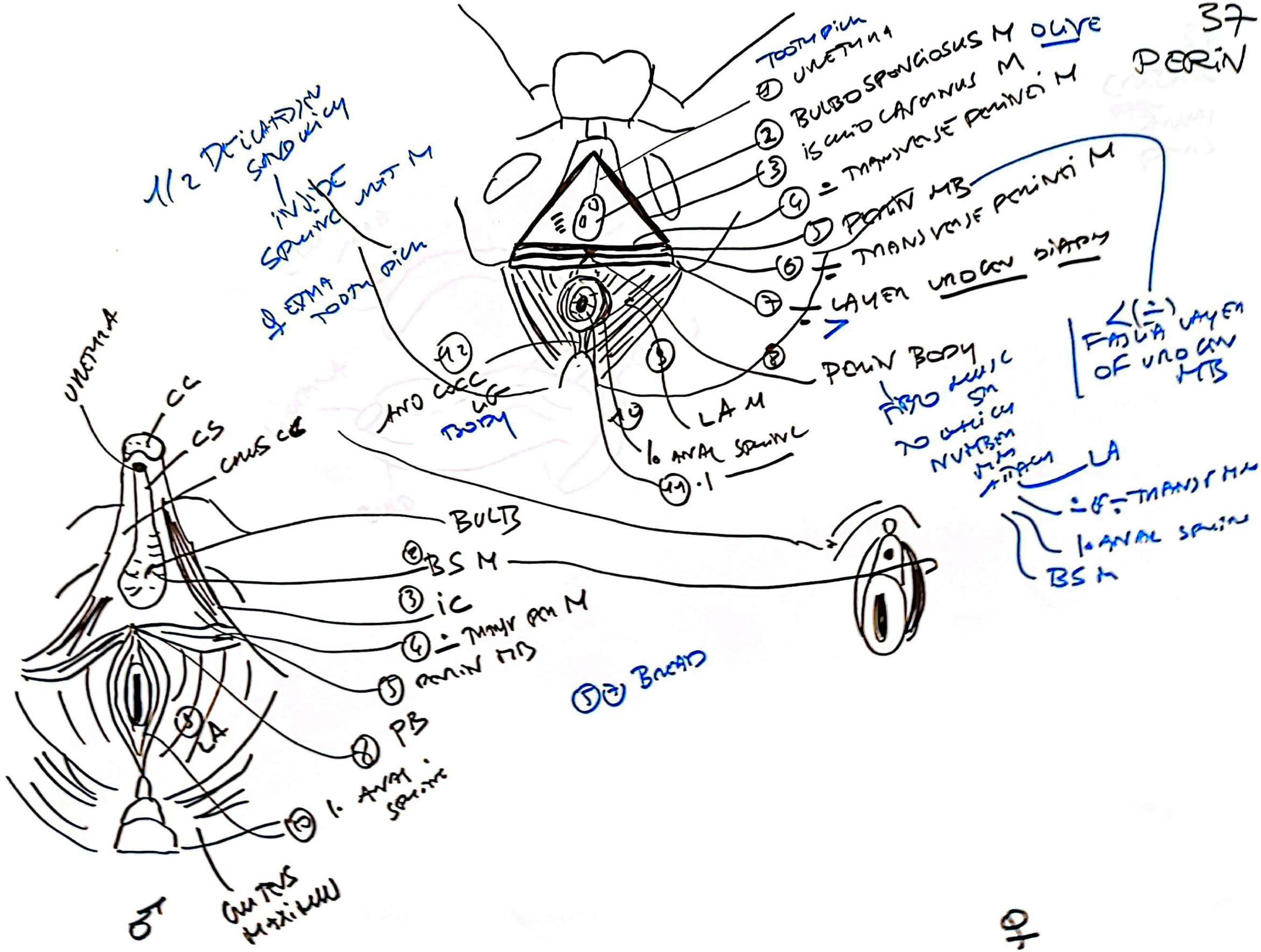
TOOTH PICK
1 URETHRA
2 BULBOSPONGIOSUS M OLIVE
3 ISCHIOCAVERNUS M
4 ÷ TRANSVERSE PERINEI M
5 PERIN MB
6 ÷ TRANSVERSE PERINEI M
7 ÷ LAYER UROGEN DIAPH
8 PERIN BODY
FIBRO MUSC SP TO ANUS NUMBER MUS ATTACH
FASCIA LAYER OF UROGEN MB
LA
÷ ÷ TRANSV MUS
1. ANAL SPHINC
BS M
9 LA M
10 ANAL SPHINC
11 ·1
12 ANO COCC LIG
TOOTH PICK
1/2 DEEP PERINEAL SPACE
INVIDE SPHINC MUS M
TOOTH PICK
URETHRA
CC
CS
CRUS CC
BULB
2 BS M
3 IC
4 ÷ TRANSV PER M
5 PERIN MB
6 PB
7 LA
8 1. ANAL SPHINC
CRUS MAXILLA
♂
5 6 BACKS
%

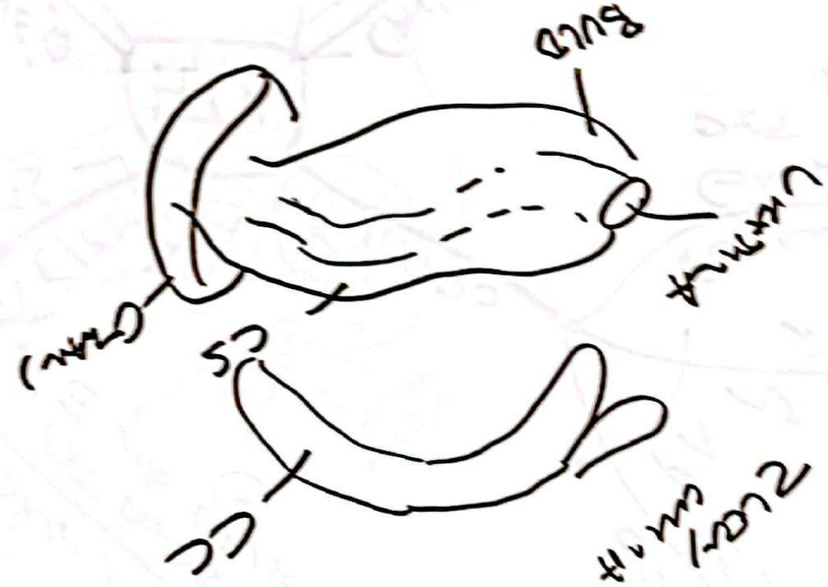
ovary
cs
cc
ovary wall
placenta
ovule



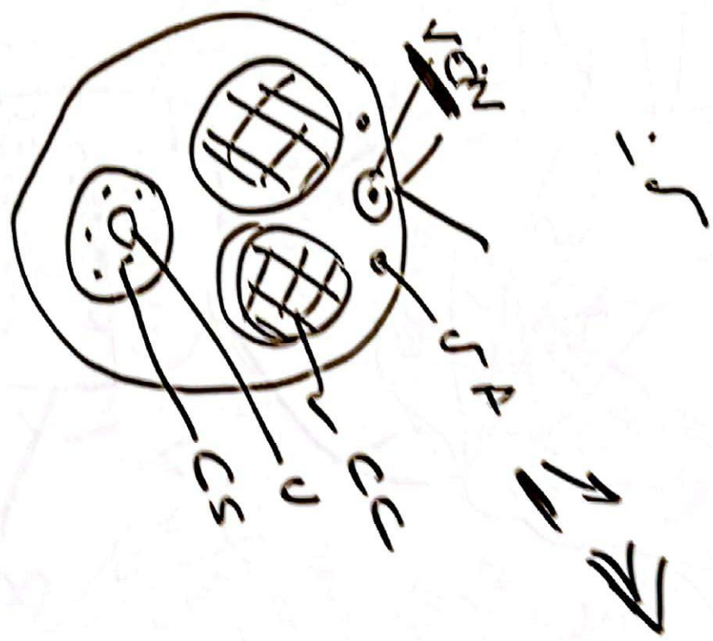

ج: ١

40

GONAL PERIN

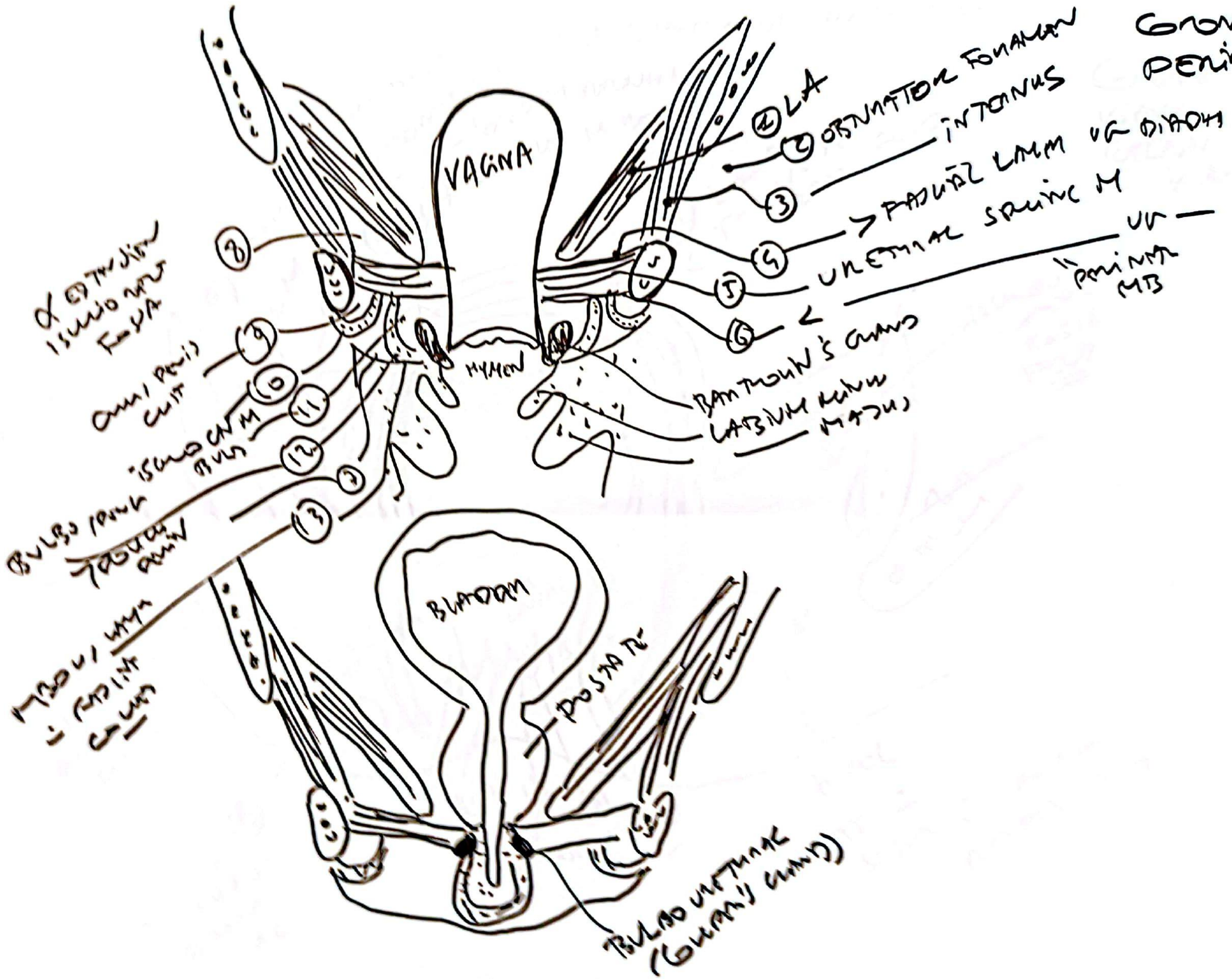

♀

♂

GIONAL VIEWS RECTUM & ANUS

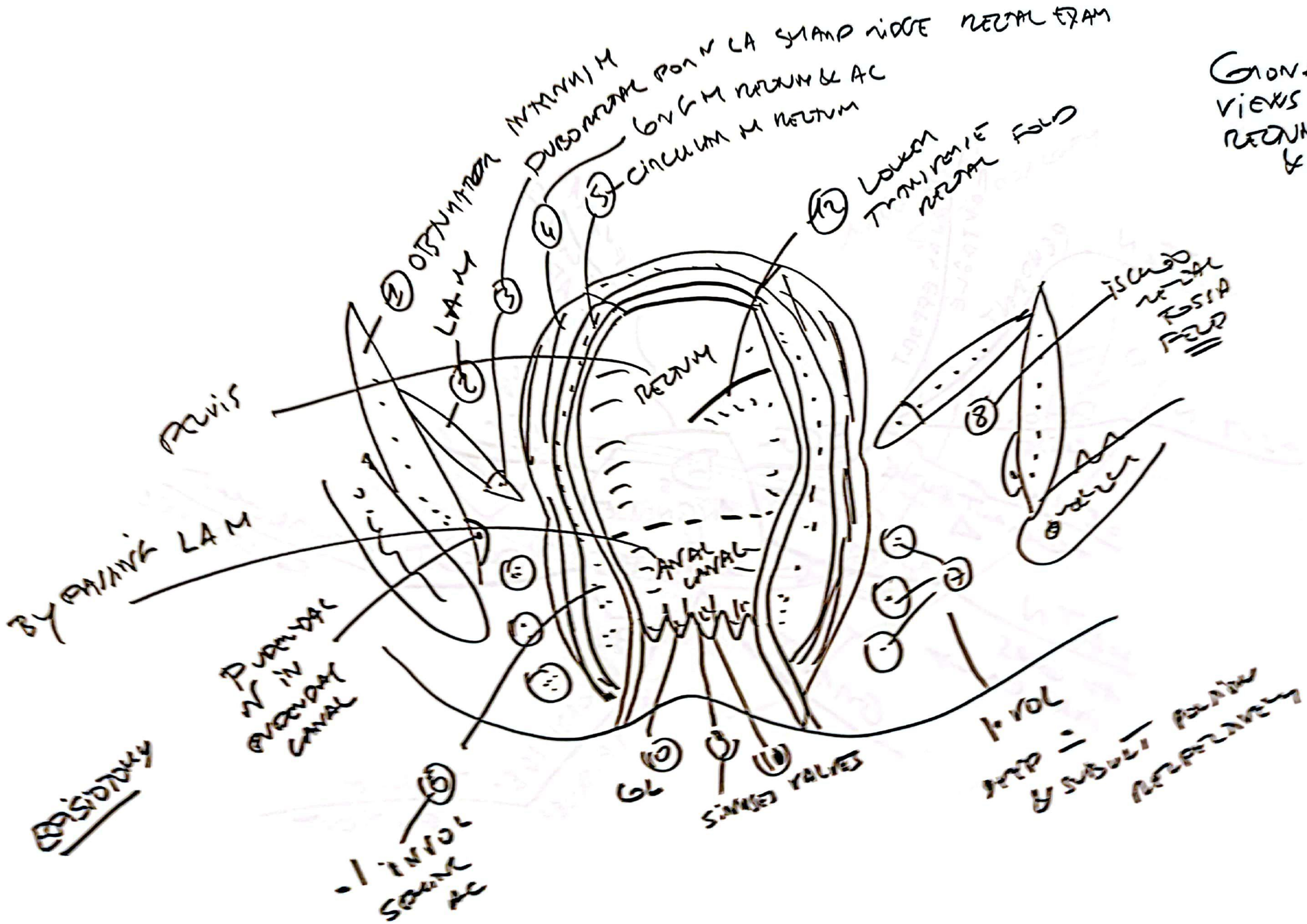

ANGIOGRAPHY
SIGMOIDOSCOPY

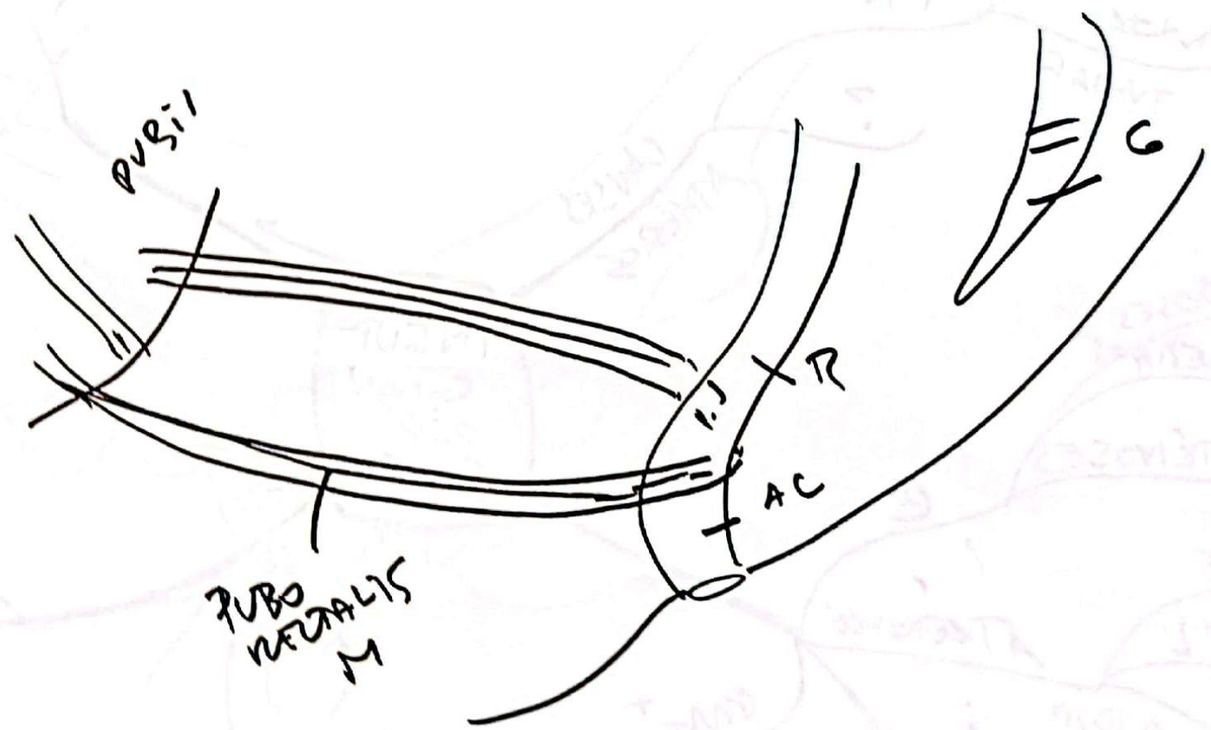

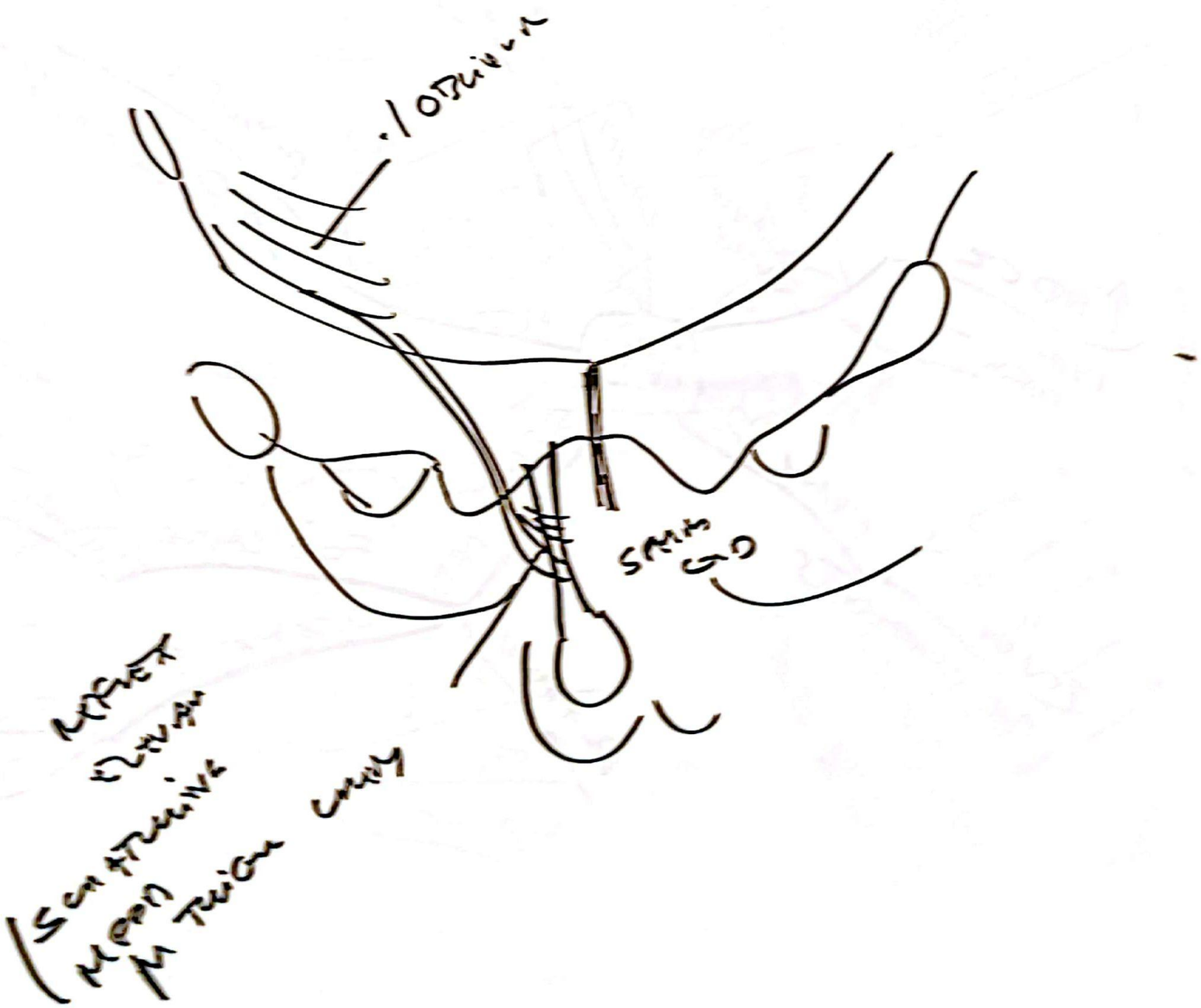
OBTURATOR
SMALL GLUTEAL
SCIATIC NERVE
MEDIAL TRIGONE
CONJUGATE M
EXTERNAL OBLIQUE M


Hip
ABD
ADD
EXT
FLEX
Knee
EXT
FLEX
Ankle
Foot
Rectus Femoris
Vastus Medialis
Vastus Lateralis
Gluteus Maximus
Gluteus Medius
Gluteus Minimus
Tensor Fascia Lata
Piriformis
Obturator Internus
Gracilis
Sartorius
Bic Fem
1/2 Mem
1/2 Tend
Gastroc
Soleus
Tibialis Anterior
Peroneal
Psoas Major
Iliacus
Pectineus
Adductor Longus
Adductor Magnus
Gluteus Maximus
Gluteus Medius
Gluteus Minimus
Tensor Fascia Lata
Piriformis
Obturator Internus
Gracilis
Sartorius
Rectus Femoris
Bic Fem
1/2 Tend
1/2 Mem
Broken Extremity
Motions
1. Isometric
2. Isometric
3. Motion
4. α
5. π

ILIAC

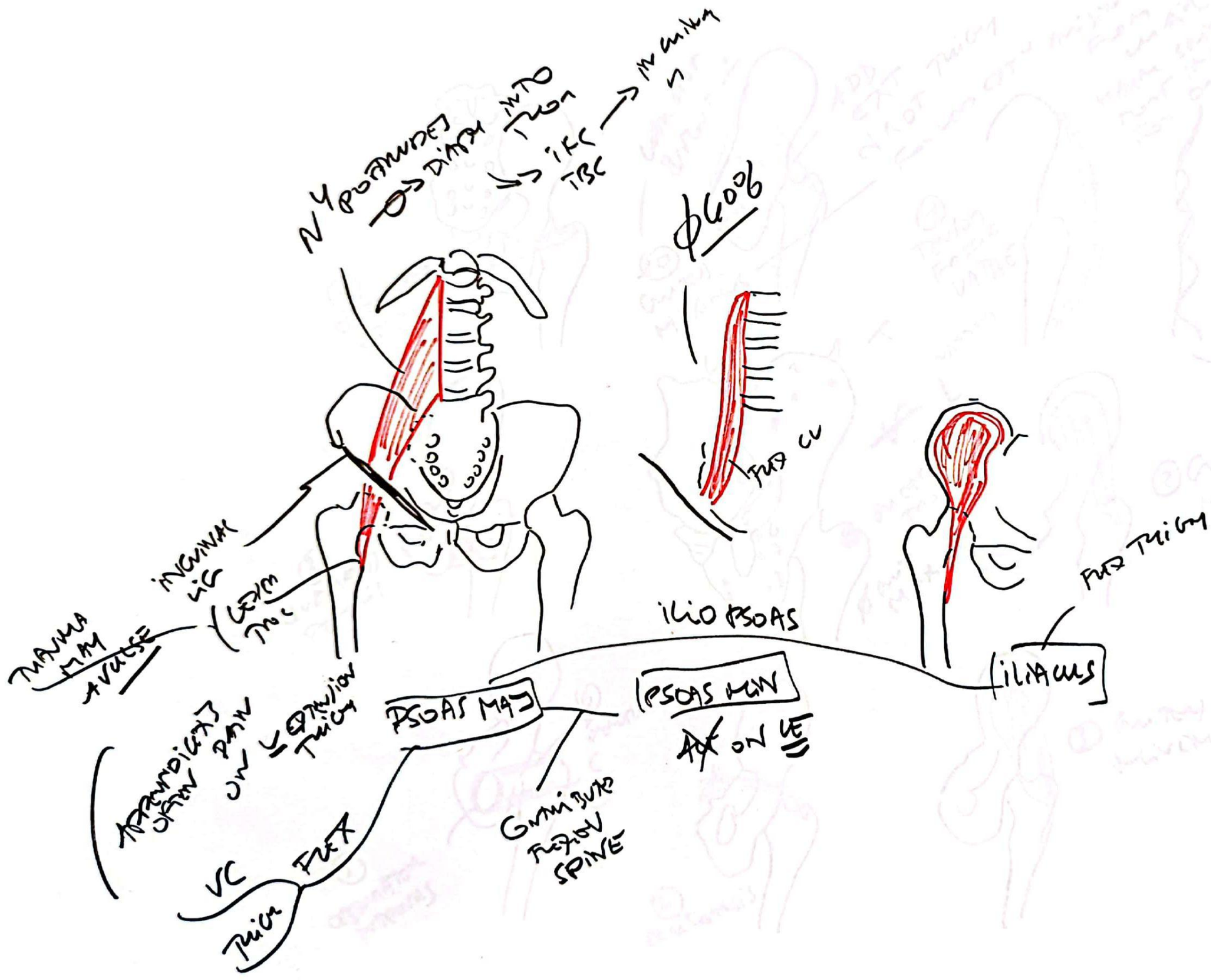
N HYPOGASTRIC
DIAPH
INTO THIGH
ILC
TBC
INGUINAL LIG
LEAN TOC
MANNA MAY AVULSE
ILIO PSOAS
ILIACUS
PSOAS MAJ
PSOAS MIN
AX ON LE
GLUTEUS FLEXION SPINE
VC
THIGH
FLEX

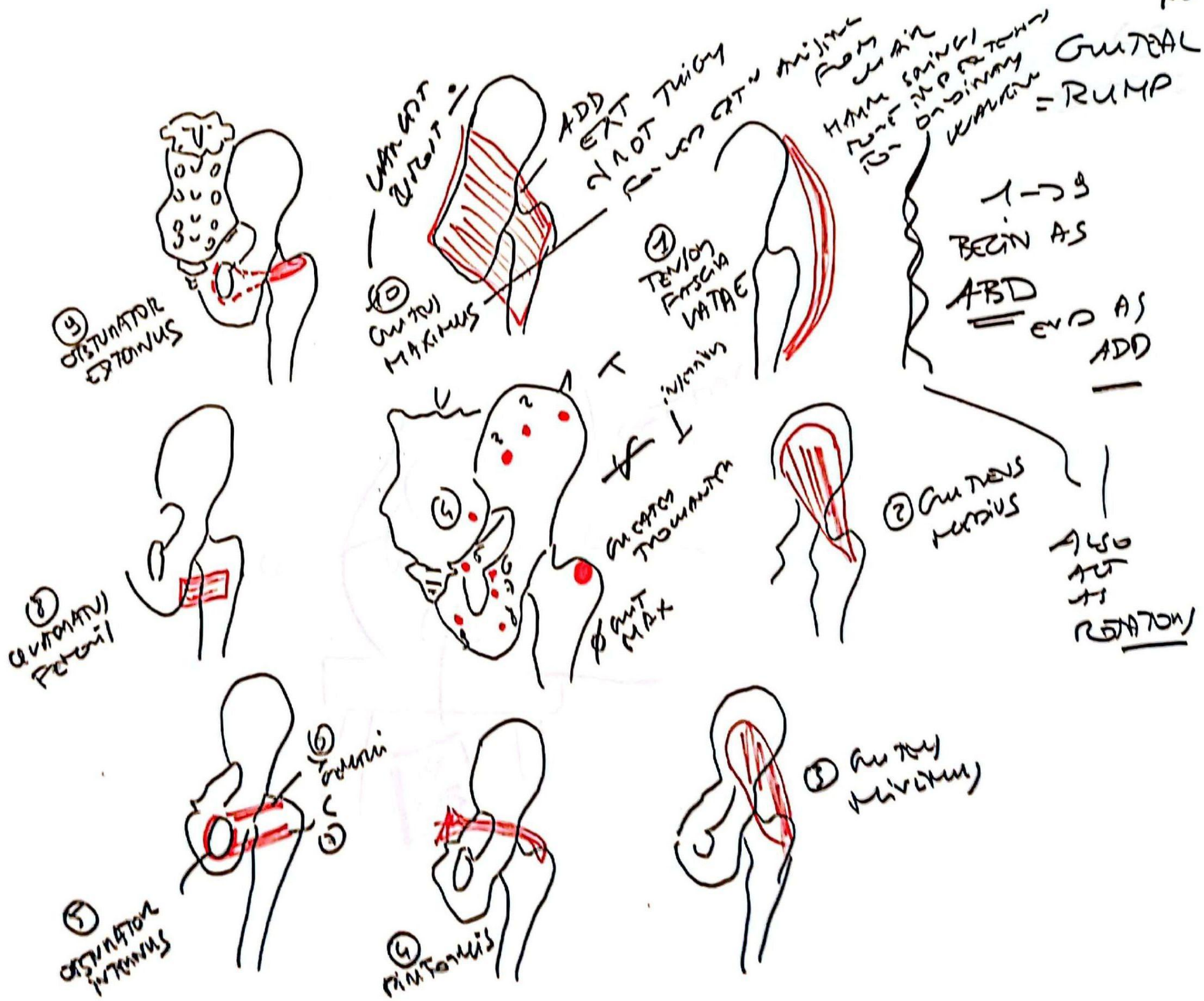
GLUTEAL = RUMP
1 → 3 BEGIN AS ABD
END AS ADD
ALSO ACT AS ROTATORS
(9) OBTURATOR EXTERNUS
(10) GLUTEUS MAXIMUS
(1) TENSOR FASCIA LATAE
(2) GLUTEUS MEDIUS
(8) QUADRATUS FEMORIS
(4) PIRIFORMIS
(6) GEMELLI
(5) OBTURATOR INTERNUS
(3) GLUTEUS MINIMUS

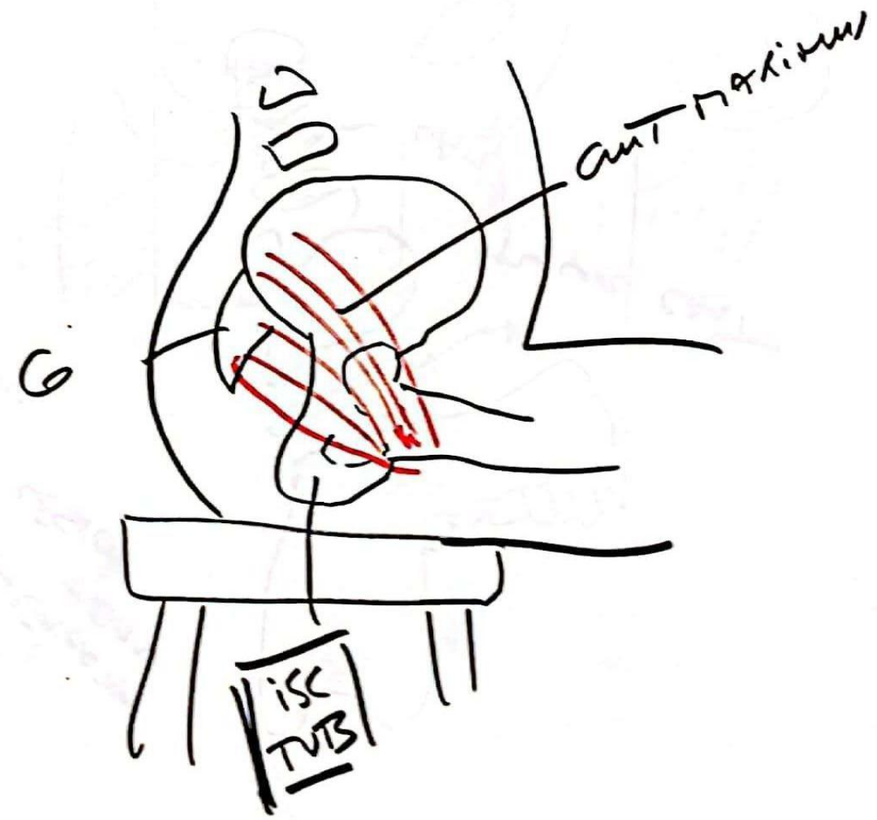
AUTOMATISM
6
ISC
TVB

M THIGH

ADD & FLEX THIGH

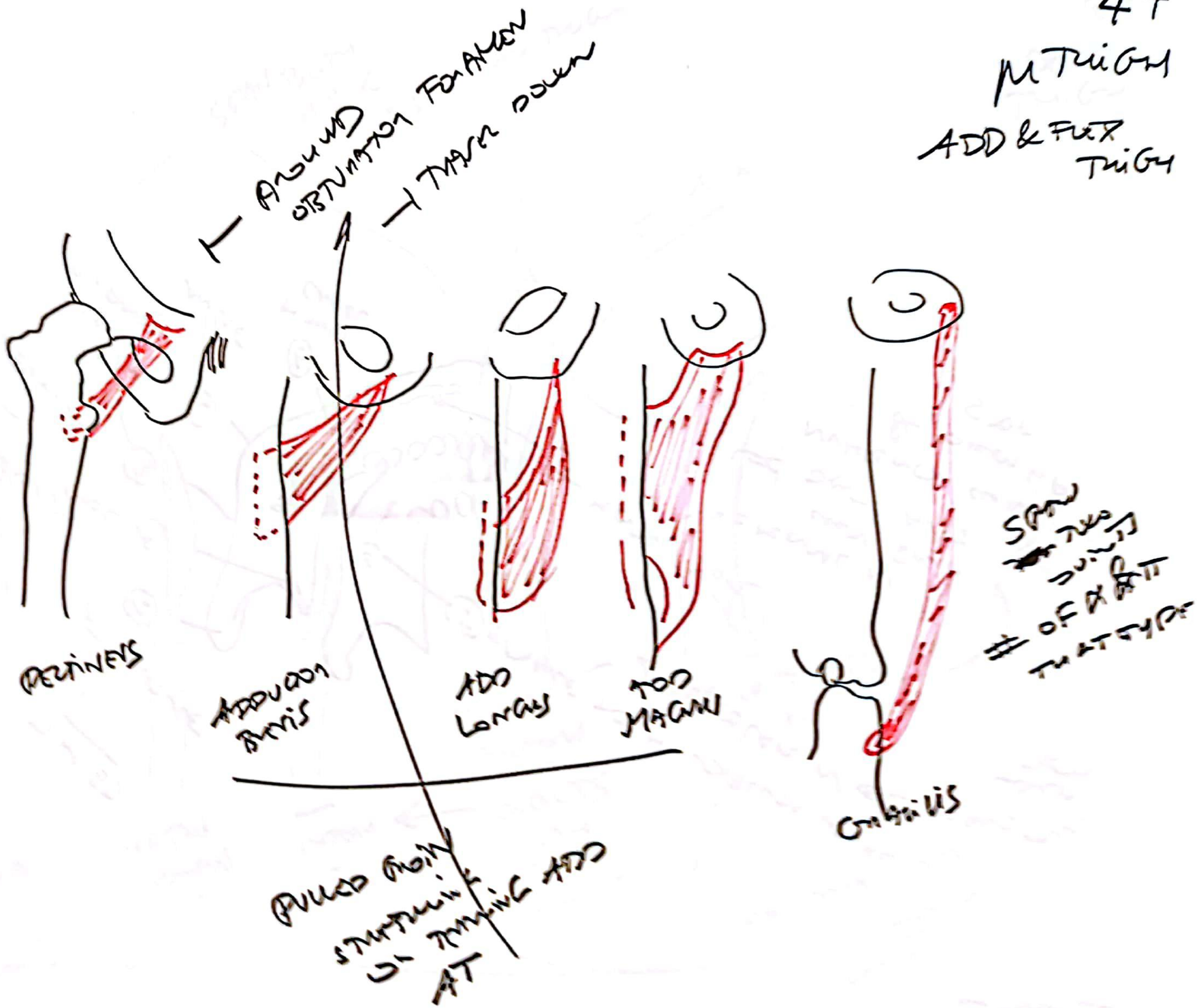

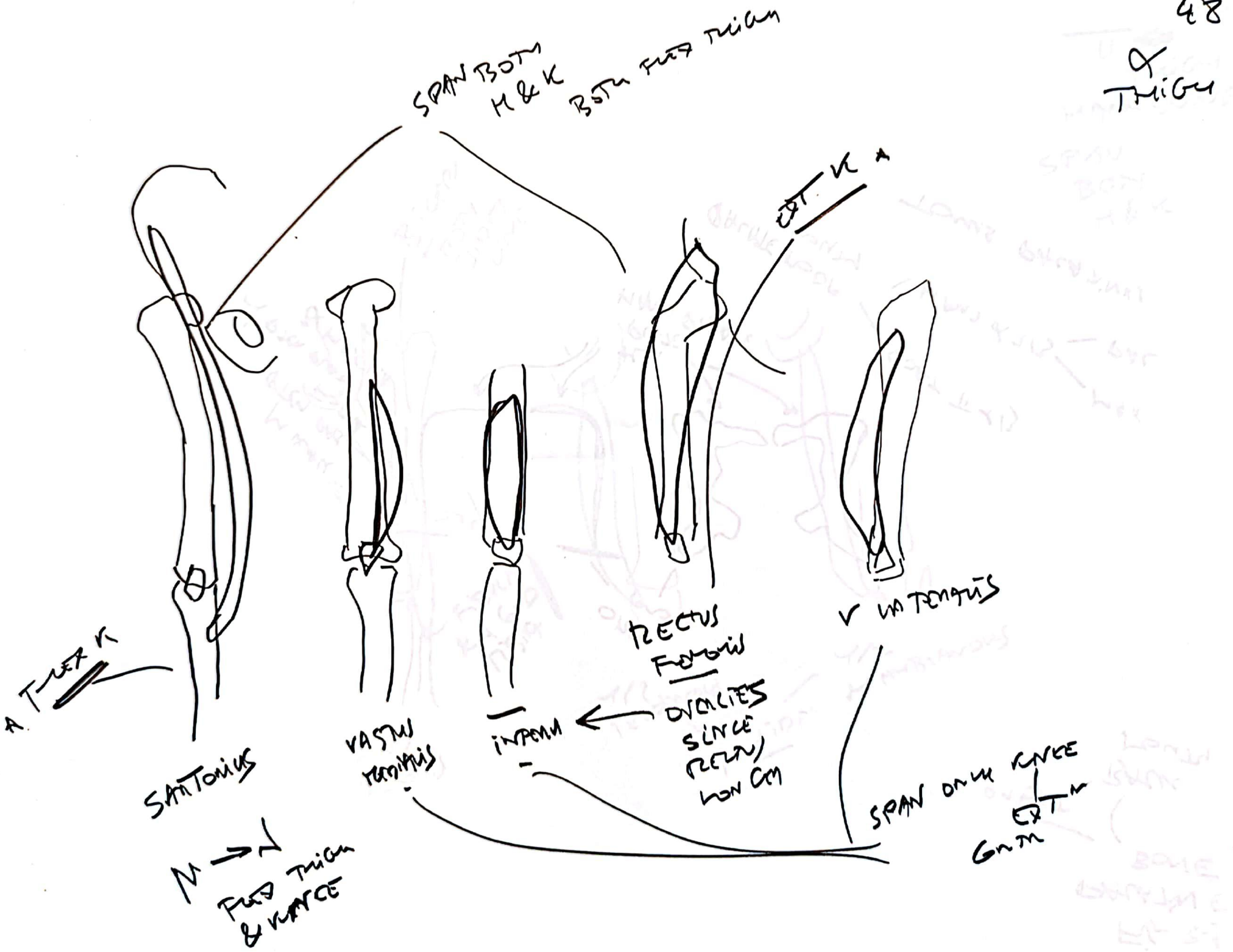
SPAN BOTH H & K
BOTH FLEX THIGH
α THIGH
EXT K
A TIBIA K
SARTORIUS
VASTUS MEDIALIS
INTERM
RECTUS FEMORIS
OVERLIES SINCE REFLN LOW CM
V LATERALIS
SPAN ONLY KNEE
EXT K
GRM
M → L
FLEX THIGH & KNEE

11 THIGH HAMSTRINGS

SPAN BOTH HIP

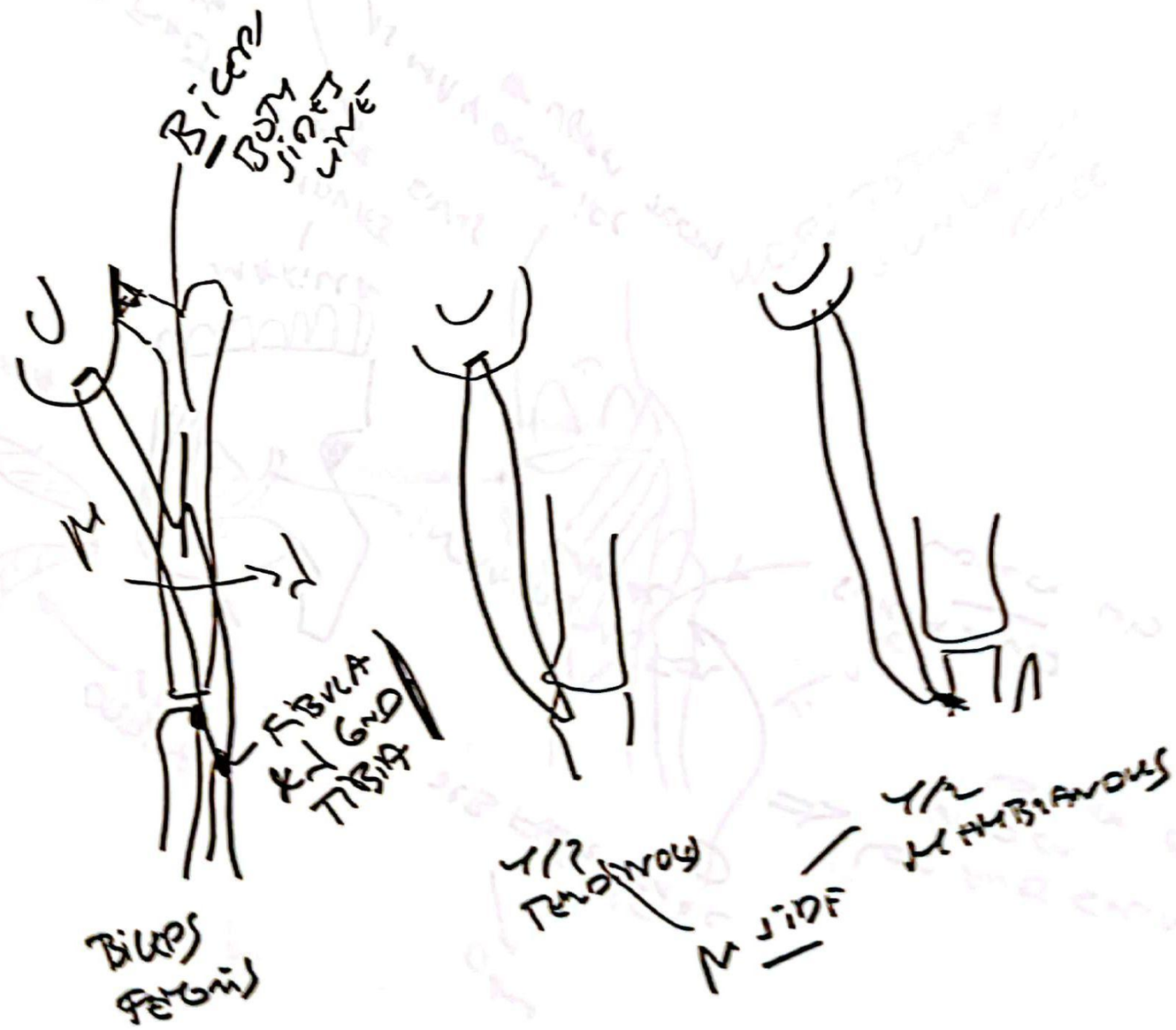

TO
POPLITEUS

PRIMARILY
PLANTAR FLEX
(= STANDING ON TIPTOE)
STRONG

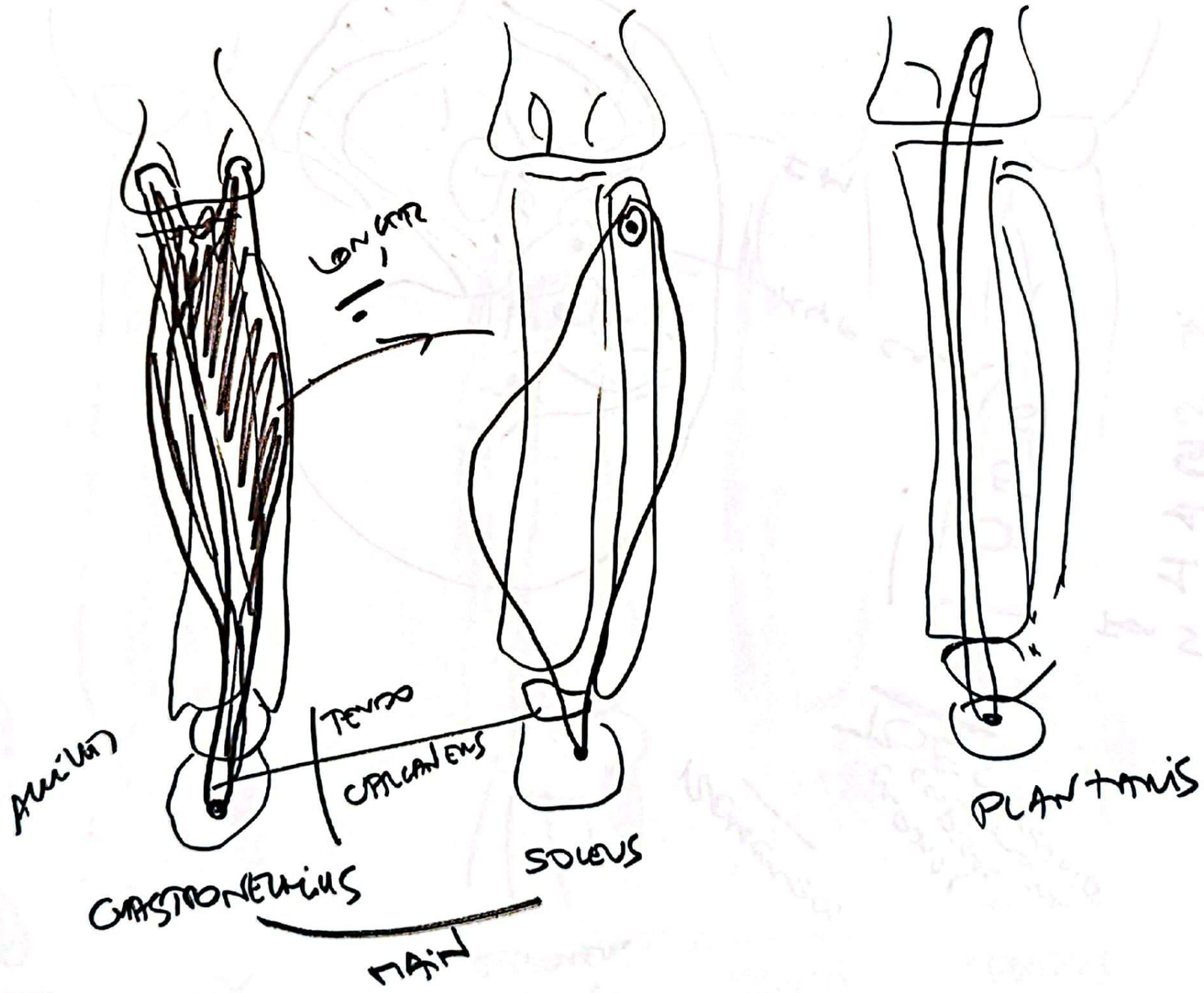

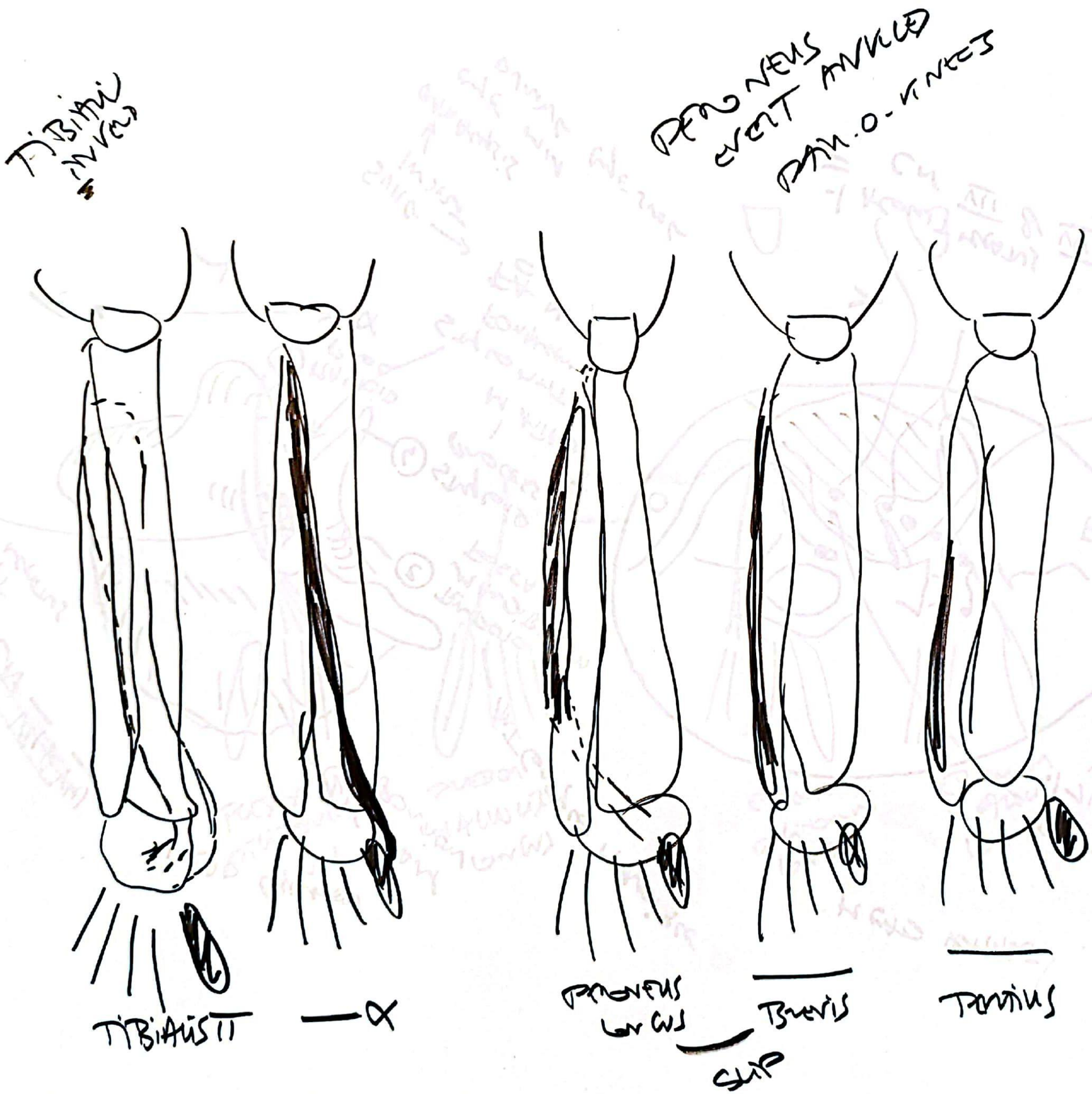

- PRIMARILY INVERTOR EVERT ANKLE
  = BOTH FOOT
- ALSO FUNC IN FLEX & EXTN ANKLE

	PLANTAR FLEX	DORSI FLEX
INVERT	TT	TA
EVERT	PL PB	DT

√ FLEXION PLANTAR

(α ON ∥ TO MALLEOLUS)

104

FLEX OR EXTEND TOES

ALSO ASSIST IN ANKLE PLANTAR FLEXION & DORSI FLEX

Dancing Camel
M Gastrocnemius
aka "Tom Hick Thumb"

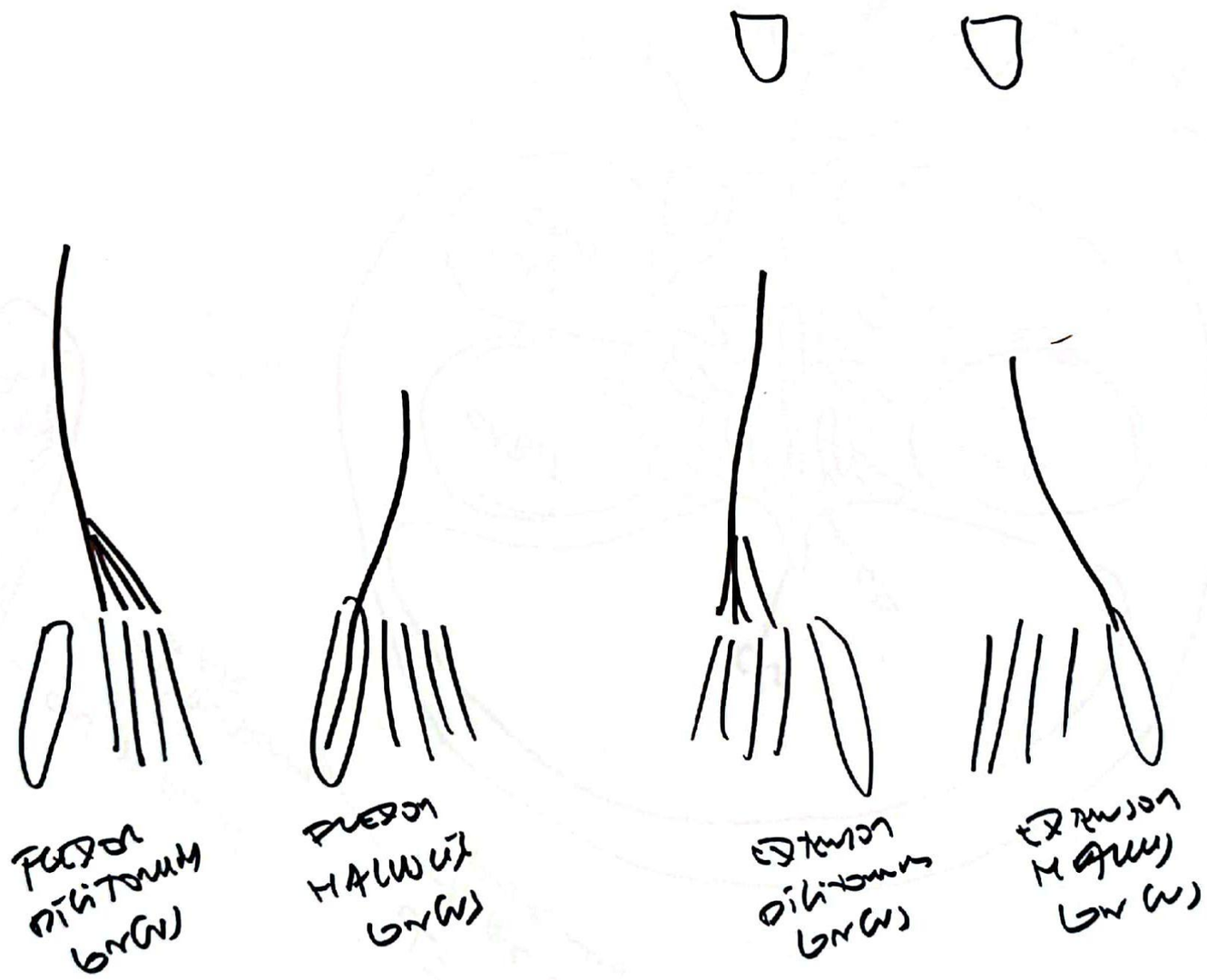

54
INTRINSIC
FOOT
~~OPPOSITION~~

FLEXOR DIGITORUM BREVIS

ABD MINIMI

FLEXOR MINIMI BREVIS

ADD HAL

EXT DIG BREVIS

FACE

UPPER FACE



OCCIPITO FRONTALIS (SUPERIOR)



GLABELLA (FROWN)

LEVATOR PALPEBRAE SUPERIORIS

ORBICULARIS

FA

VII "HOOK" CROSS

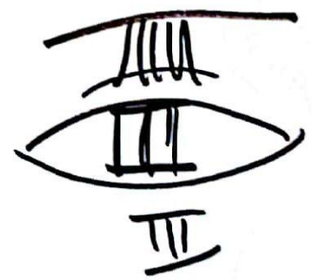

III

KEEPS OPEN


PROCERUS
(SUPERIOR
UP NOSTRIL)
COMPRESSOR
NARIS
(LOWER NOSTRIL)
DILATOR NARIS
OPEN
DEPRESSOR SEPTI
(LOWER NOSTRIL)
LEVATOR LABII SUPERIORIS
ALAEQUE NASI
(LIFTS UP, OPEN
NOSTRIL)


Chapter
Business
Dari kuliah ini
Mengenal
Pengertian
Kesimpulan dari
Contoh
Pengertian
Kesimpulan dari
Contoh
Pengertian
Kesimpulan dari
Contoh



FACIAL → VII
CLUST

59
CHEWING
TRI I

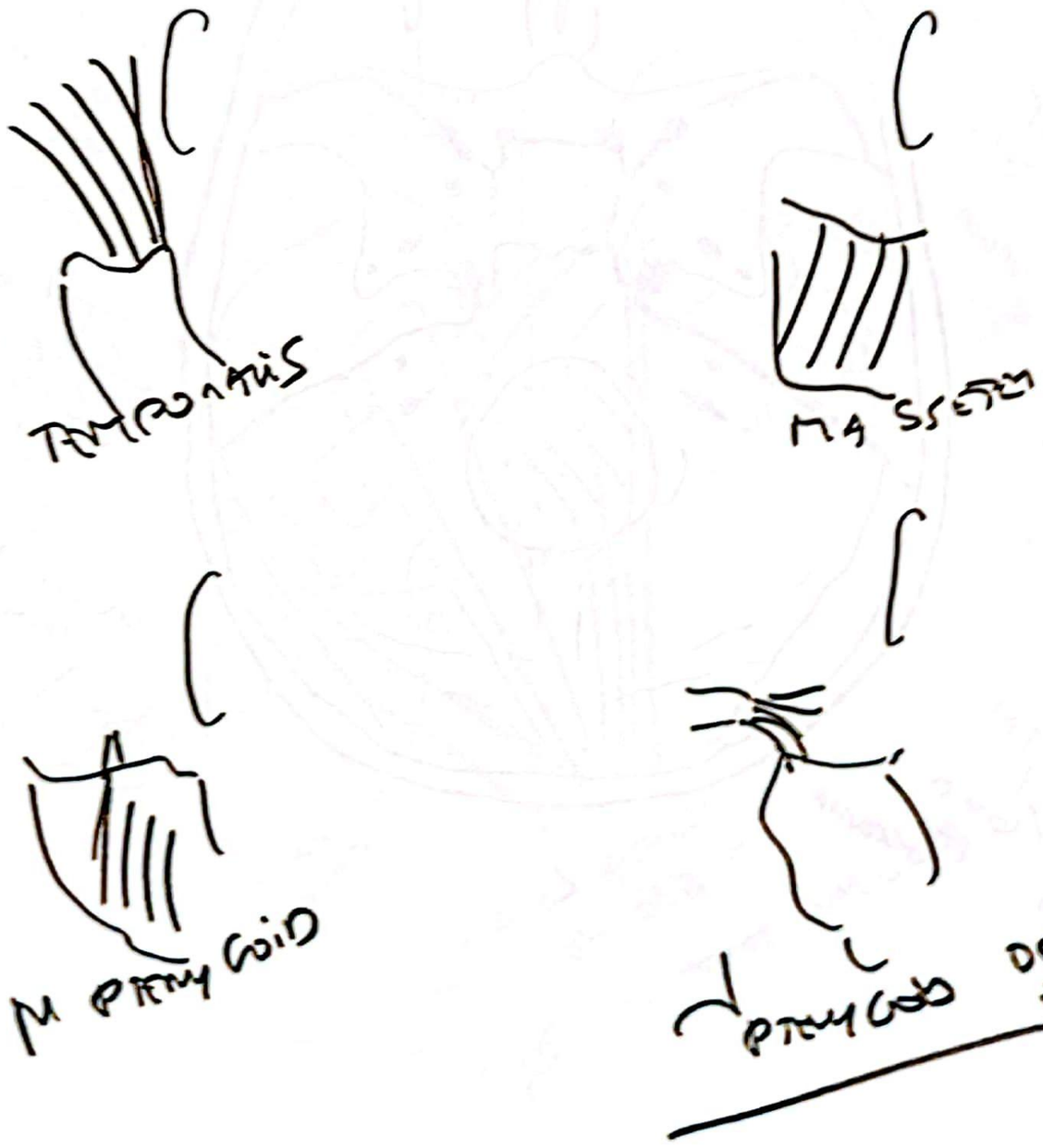

EYE 60

LR6 SO4

OTH 3

DEFICIT

HORNER'S SYNDROME

ELEVATES UPPER LID

MILD PTOSIS

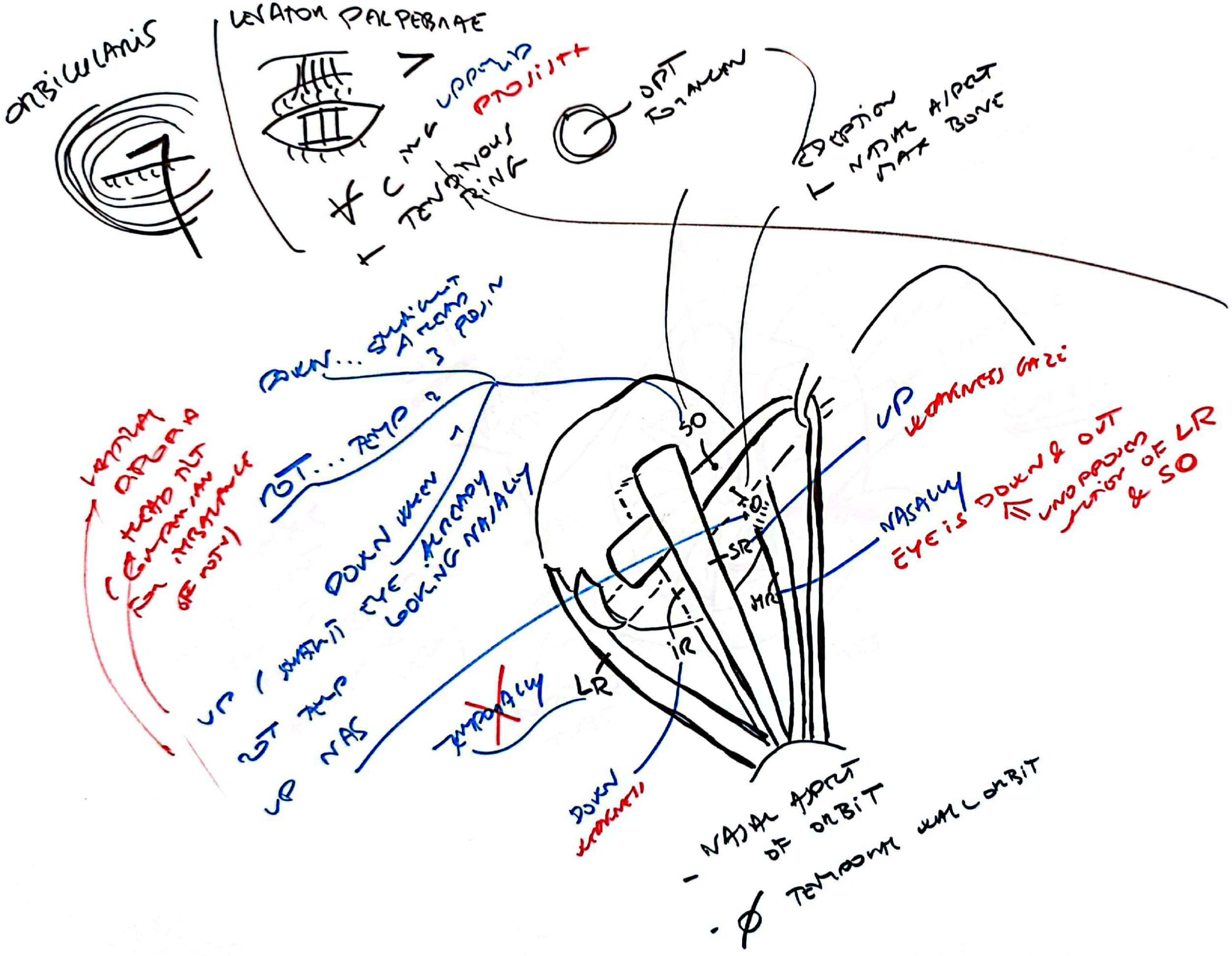

HEARING

AS SEEN FROM MIDDLE EAR CAVITY

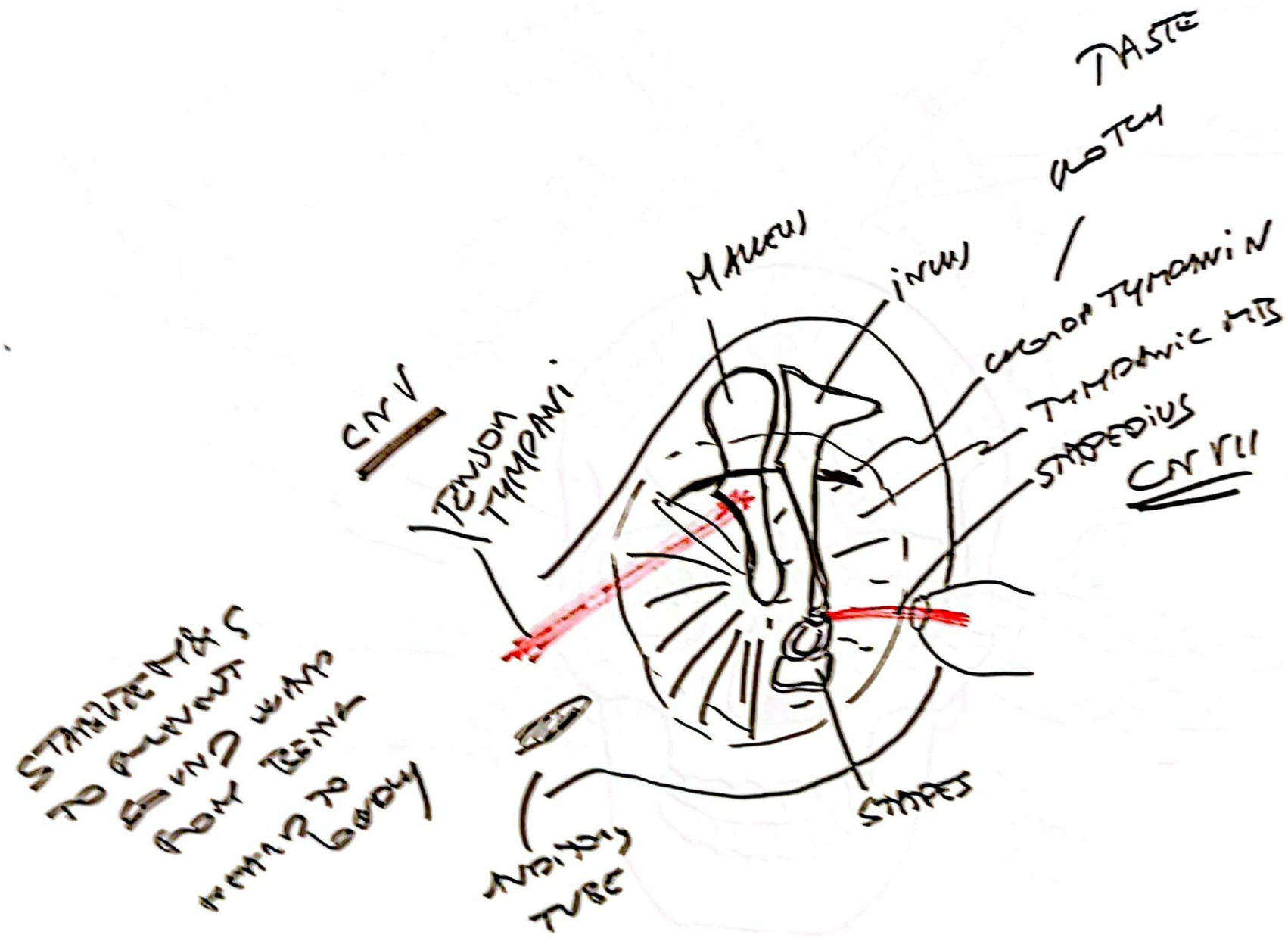

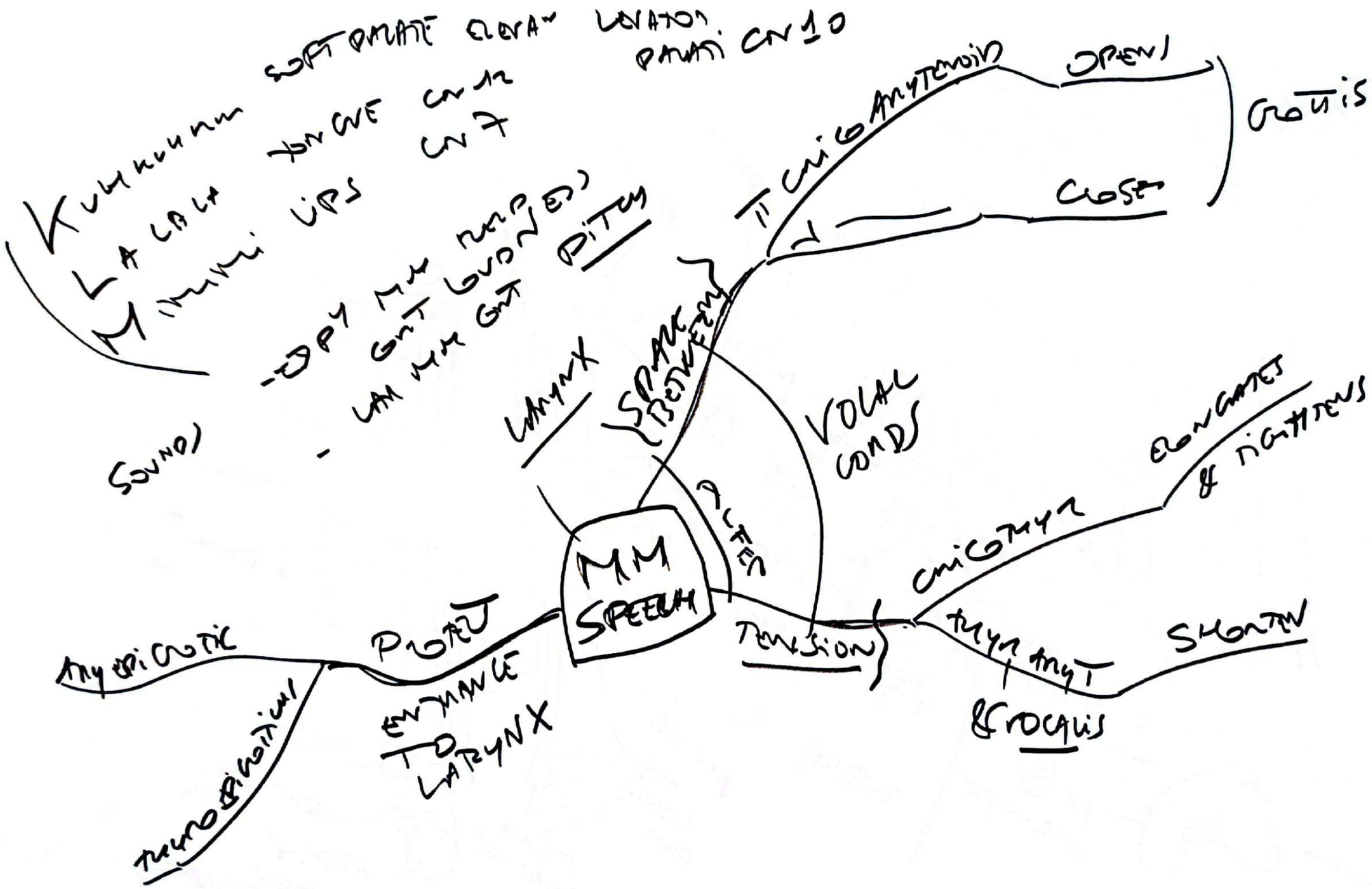
KUMKUMUM SOFT PALATE ELEVATOR PALATI CN 10
LALALA TONGUE CN 12
MMMMM LIPS CN 7
-OPY MM MMP
GNT GOUNDED
- UM MM GNT
SOUND
PITCH
LARYNX
SPACE BETWEEN
VOCAL CORDS
PLATES
MM SPEECH
TENSION
PROJECT
ENTRANCE TO LARYNX
HYPOGLOTTIC
THYROHYOIDEUS
THYROARYTENOID
OPEN
CLOSE
GLOTTIS
CRICOTHYR
ELONGATES & TIGHTENS
THYROARYT
SHORTEN
& GLOTTIS

64

COMPONENTS
LARYNX
&
TRACHEA

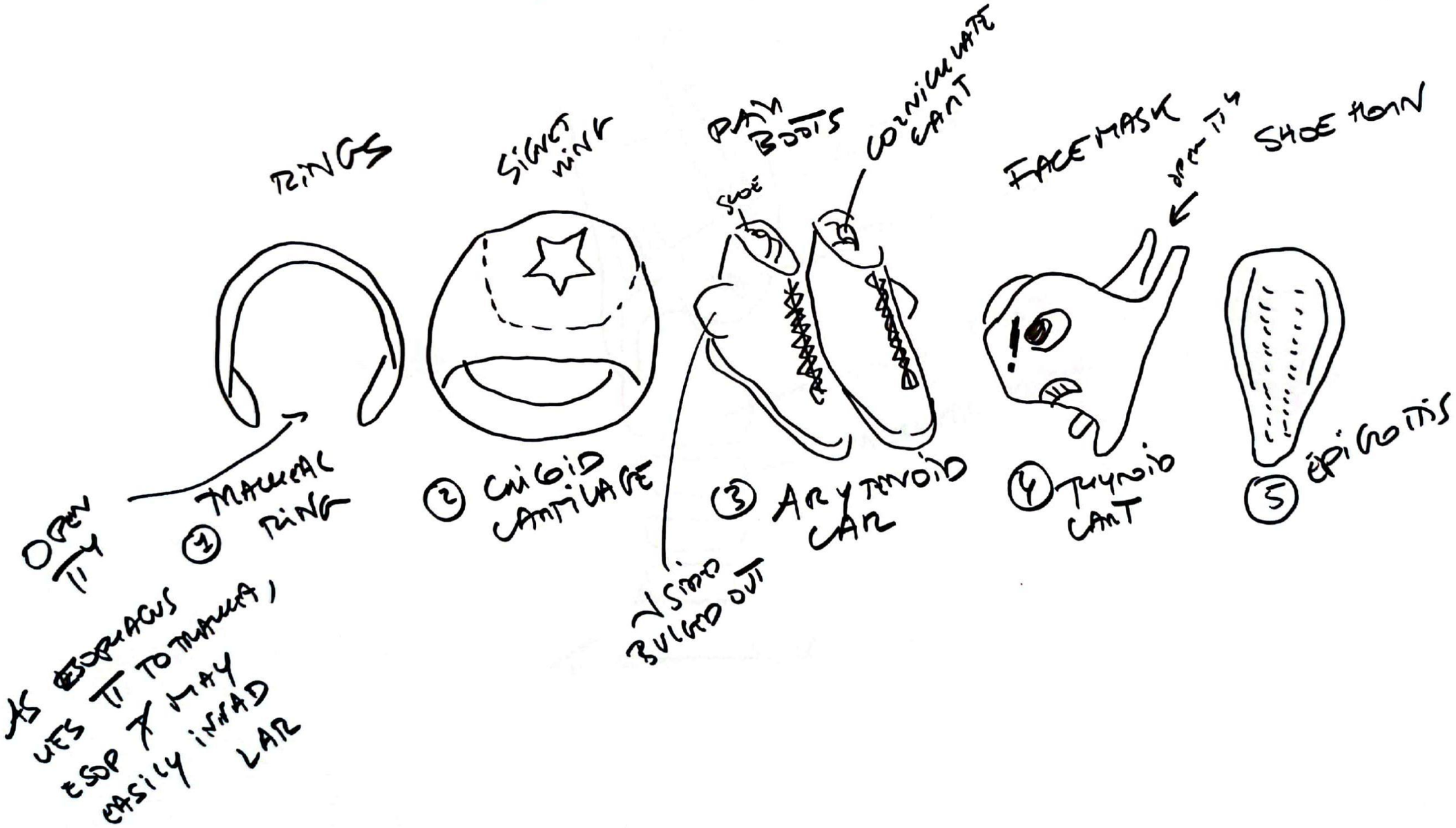

ORGAN LAM & MAC

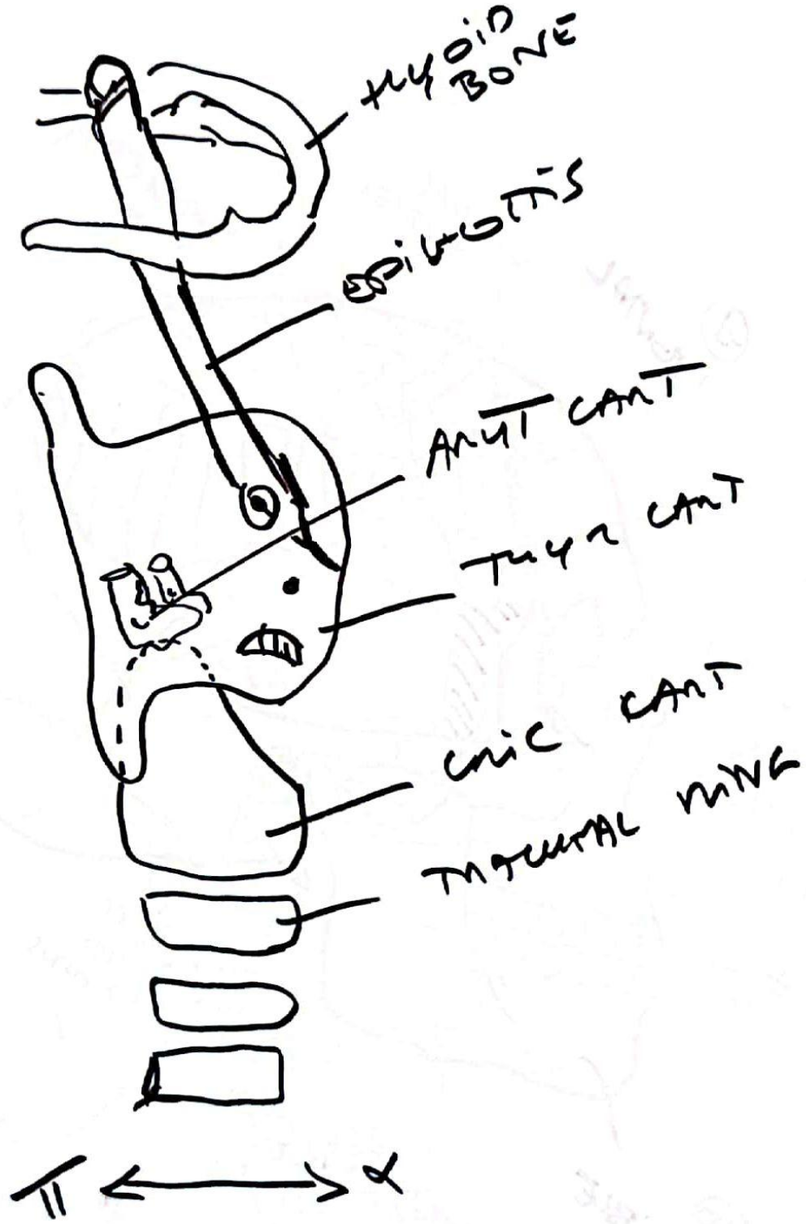

LIGAMENTS LARYNX

HYOEPIG
THYR THYR
EPIG
CRICOTRAC

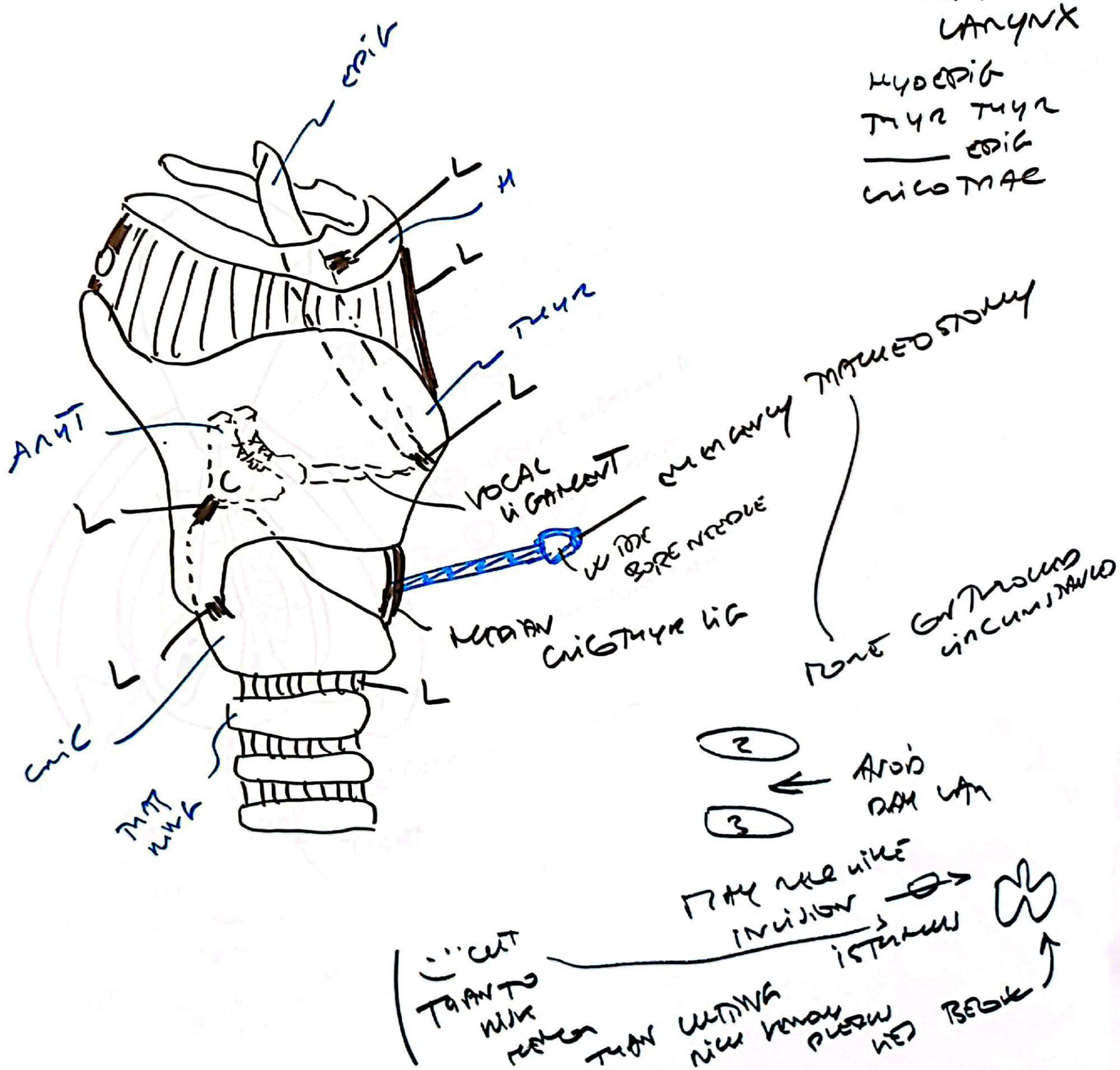

→ view
VOCAL LIGAMENT

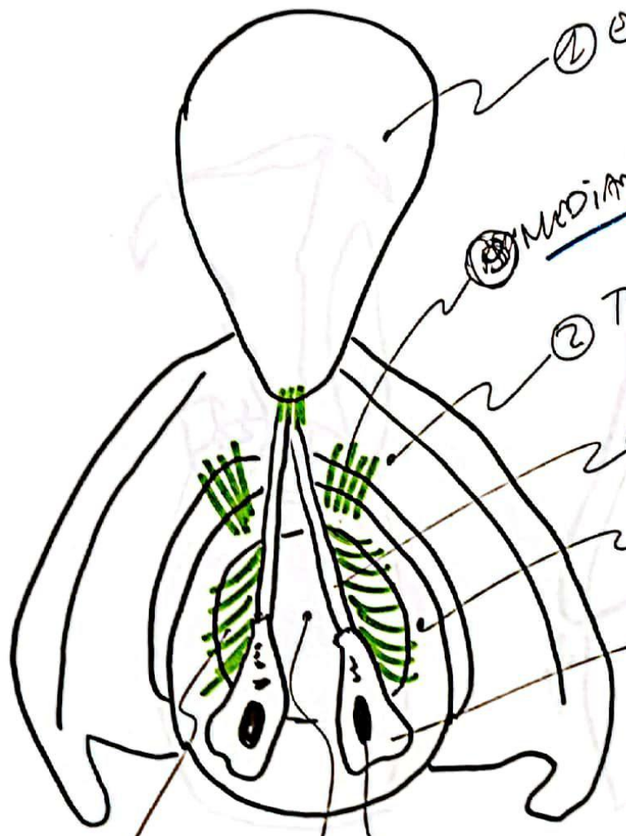

① EPIGLOTTIS
② MEDIAN CRICOTHYR LIG
③ THYROID CARTILAGE
④ VOCAL LIGAMENT
⑤ CRICOID CART
⑥ ARYTENOID CART
⑦ CONVEX CONDYLUS
⑧ GLOTTIS

CLOSED

FIBROMUSCL MB

PVP TENT Y GVE

ROOF CLOSED WHEN

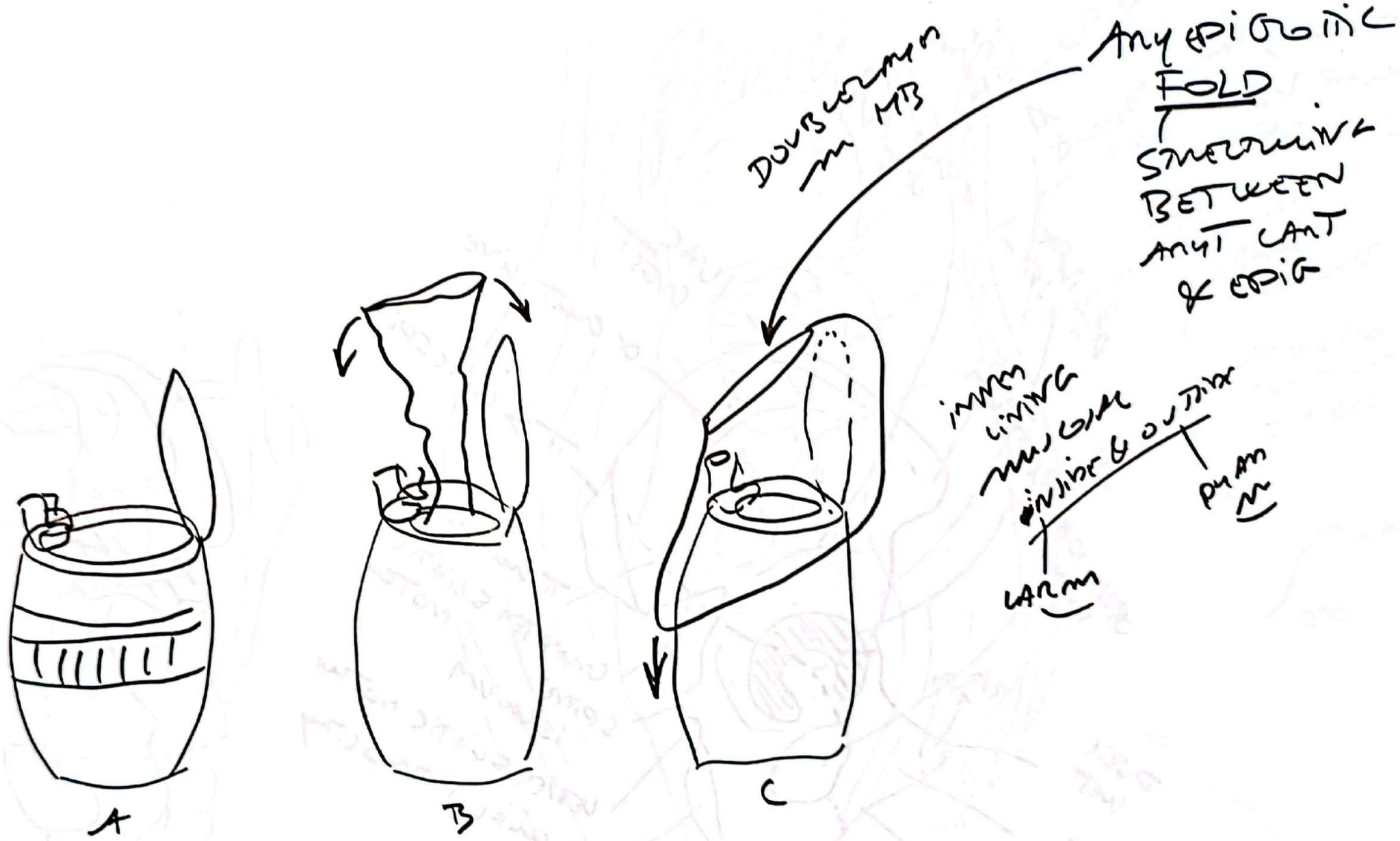
DOUBLEMAN
m MB
Any epicrotic
FOLD
SPREADING
BETWEEN
ANT CANT
& EPIC
inner
lining
muscle
inner & outer
pyam
m
LARm
A
B
C

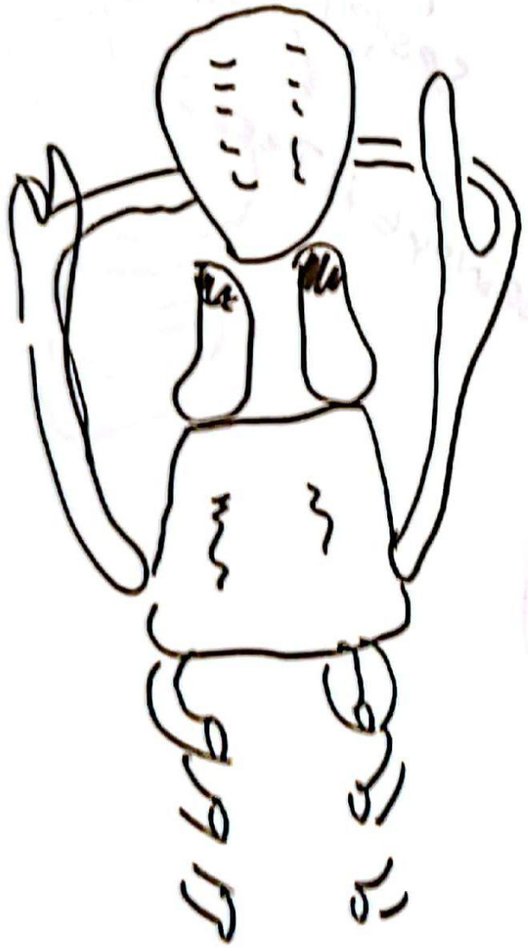

A

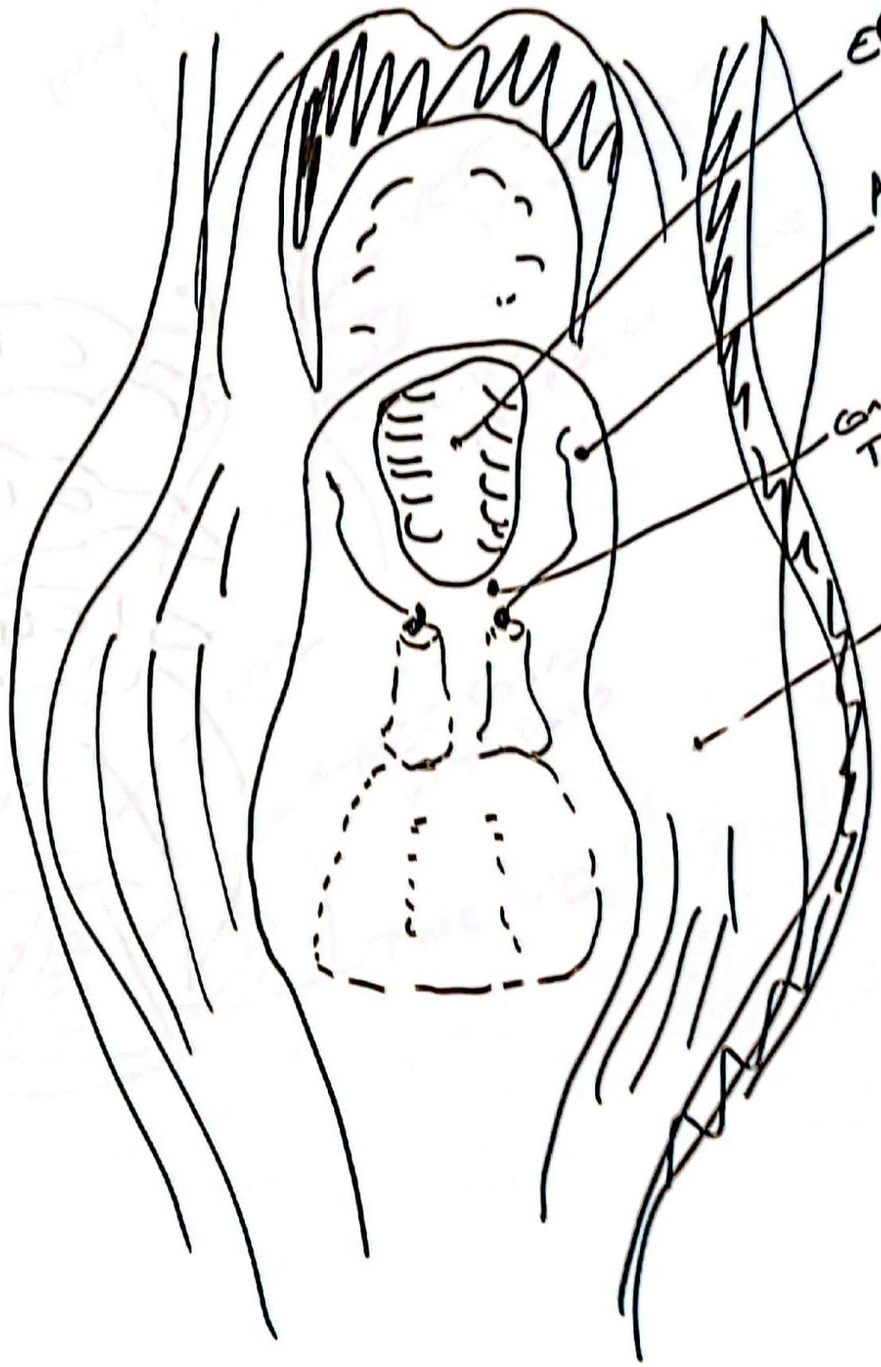

LAR CART SEEN FROM BEHIND

LEV

VOCAL CORD PARALYSIS

LARYNGO PHARYNX = HYPO -

MASS

B

VESTIBULAR LIG

"FALSE VOCAL CAD

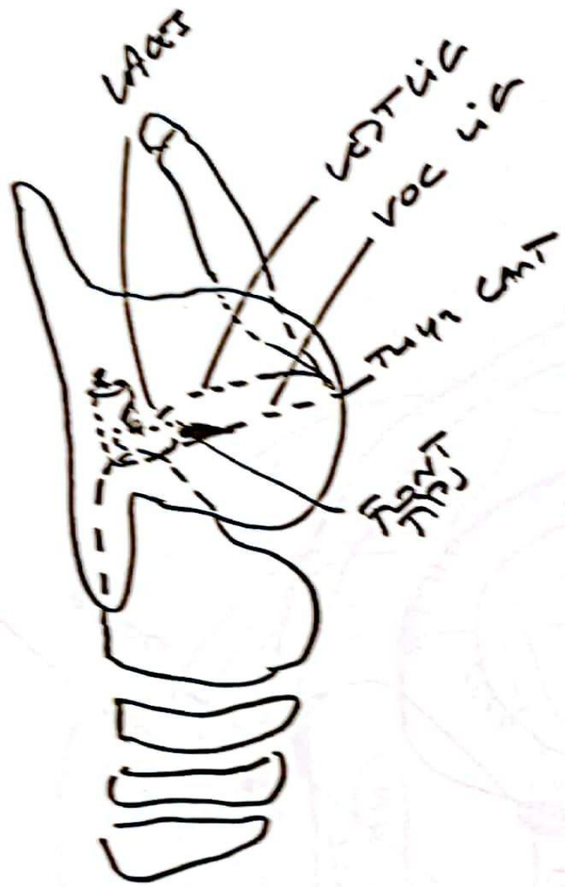

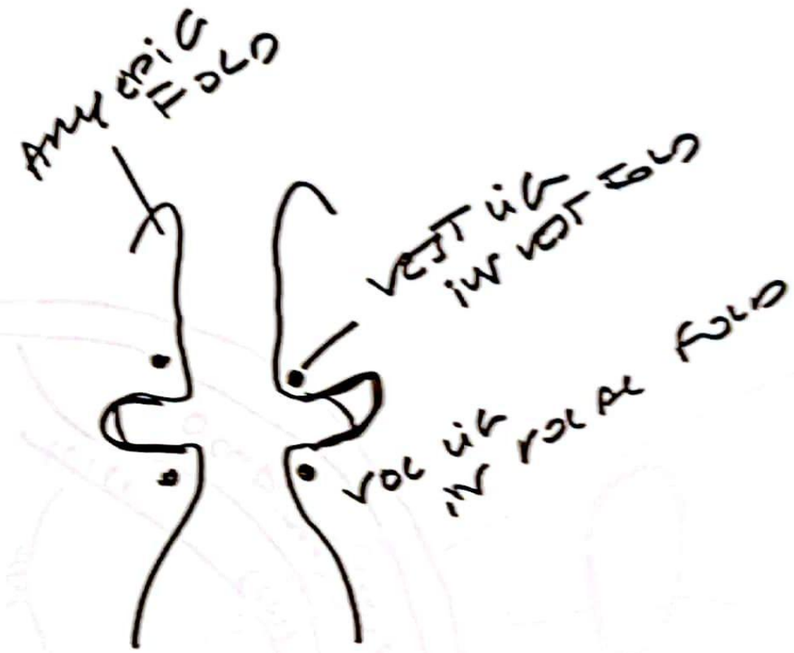

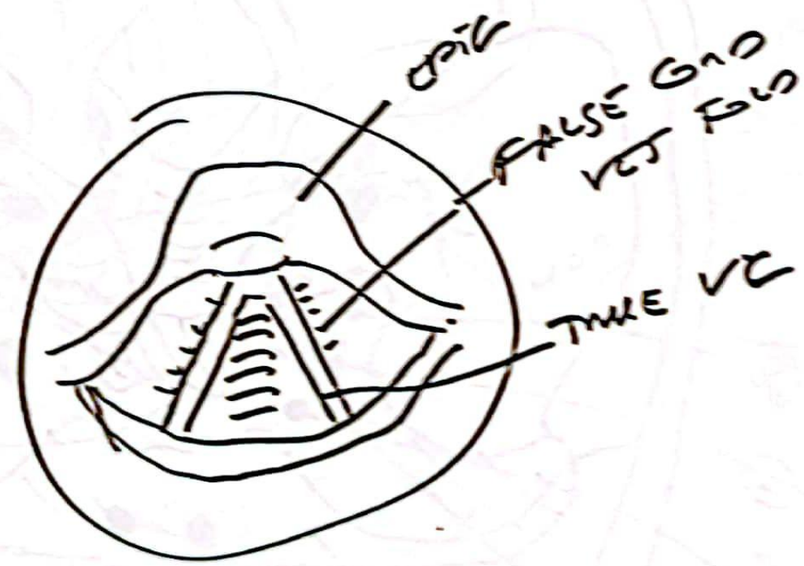

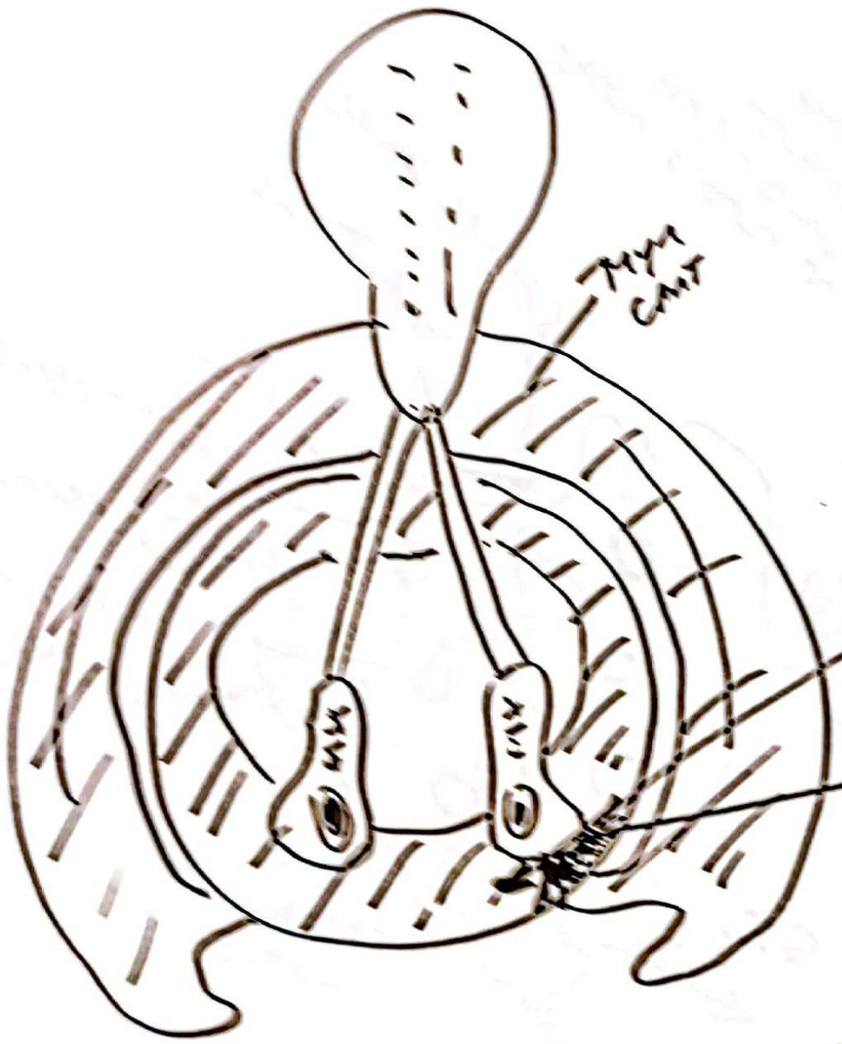

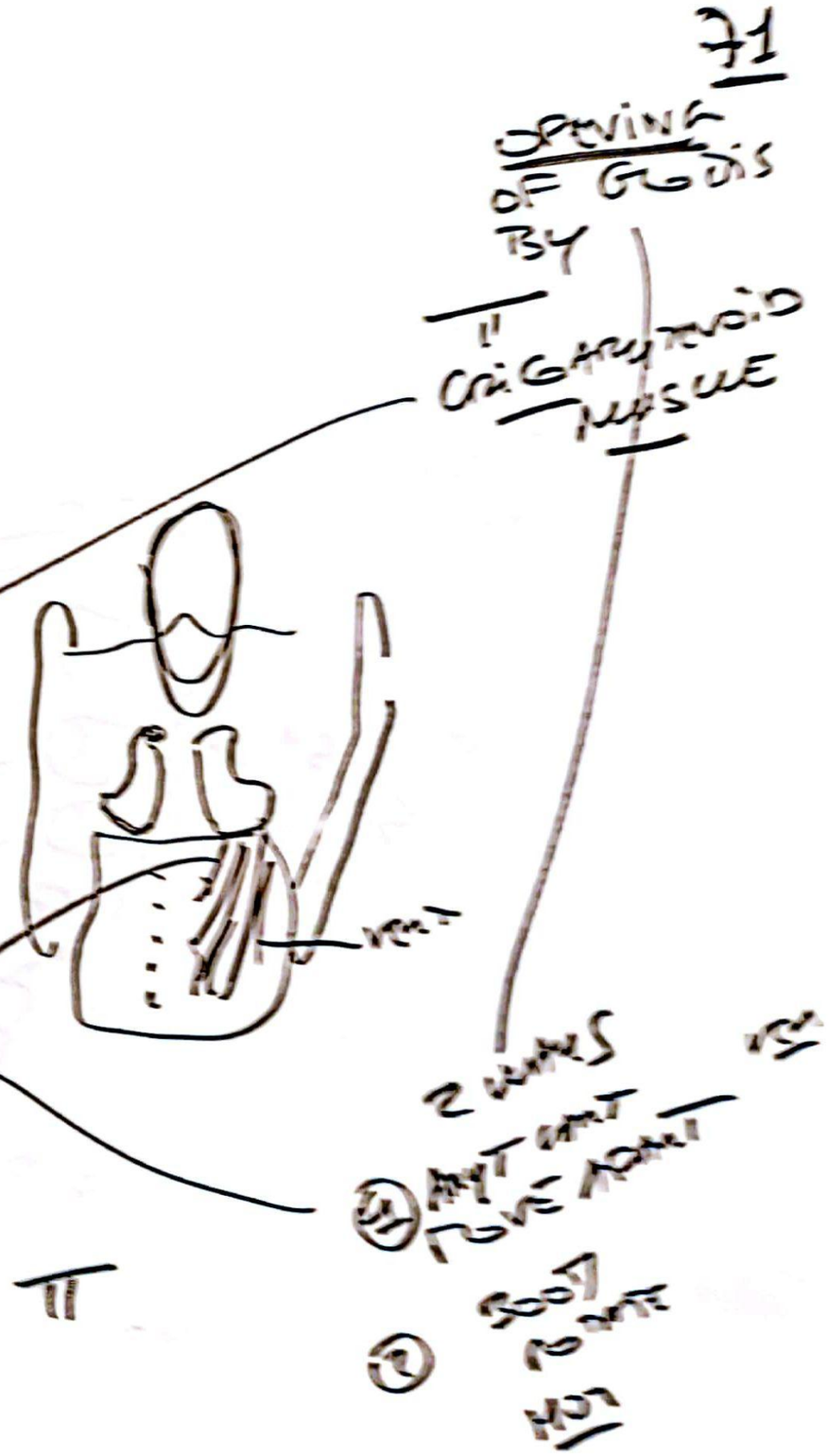

I

BEST IMP SKEL M IN BODY ONLY FOR THAT OPEN GLOTTIS

II

72

Closing Glottis

partly
↓ cricoarytenoid
rotation
↓
↑ tip
cricoid

CLOSE GLOTTIS
BY ROTATING & [illegible] BODY

↓ [illegible] THYR & ARYT
& ALTER TENSION [illegible] VC

CONT
TENSION
VOC
[illegible]

MOVE
THYR
ANTERIORLY
ON [illegible]
JOINT

CRICOTHYR
↑ [illegible] THYR & ARYT
[illegible] ↑ TENSION VC

BR
VOCALIS
&
THYROARYT
MM
TO VC

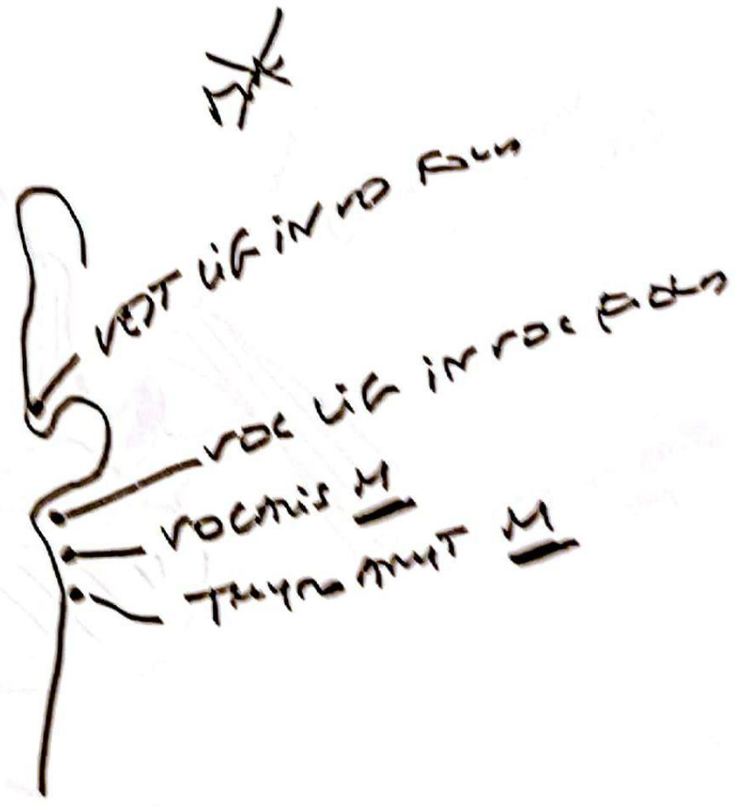

CLOSING ENTRANCE TO LARYNX

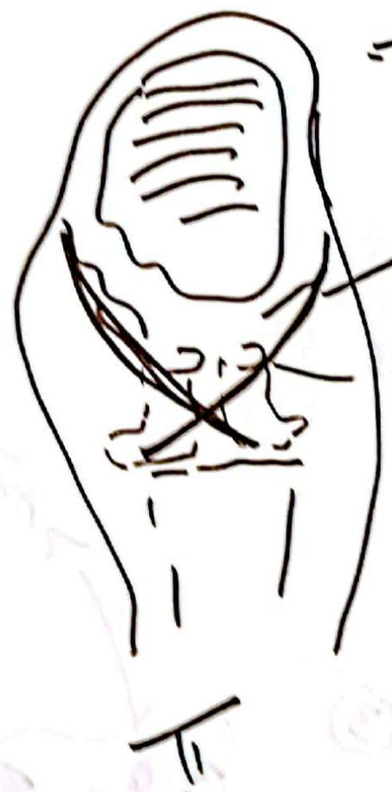

"PUSH" → PREVENTING FOOD → MATERIAL GOING VC

ARYEPIGLOTTIC M

OBLIQUE ARYTENOID M

INTRINSIC TONGUE

M SWALLOWING
- TONGUE
- PALATE
- HYOID
- PHARYNG

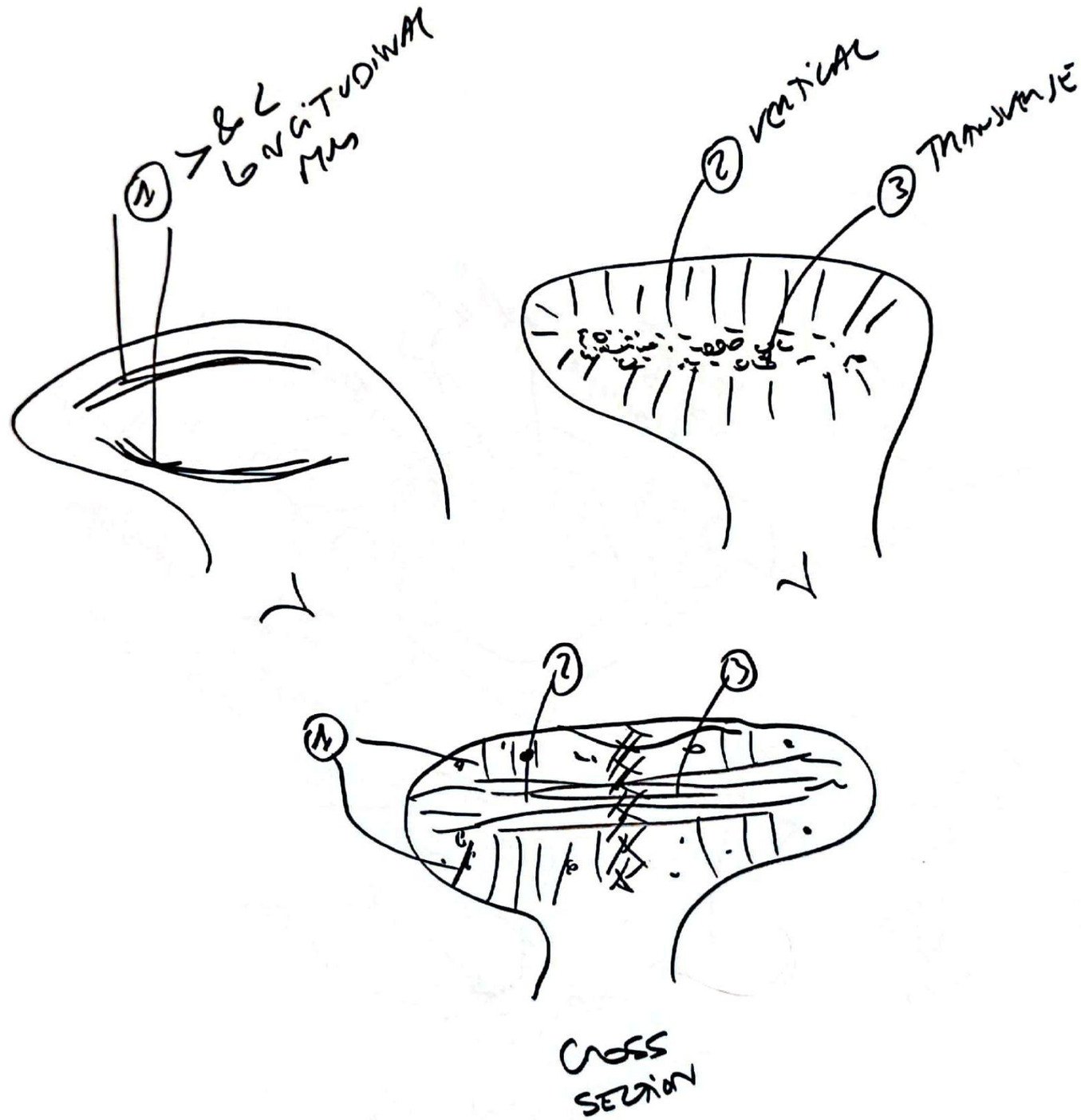

EXTRINSIC

BACKWARDS FOR — DOWN UP

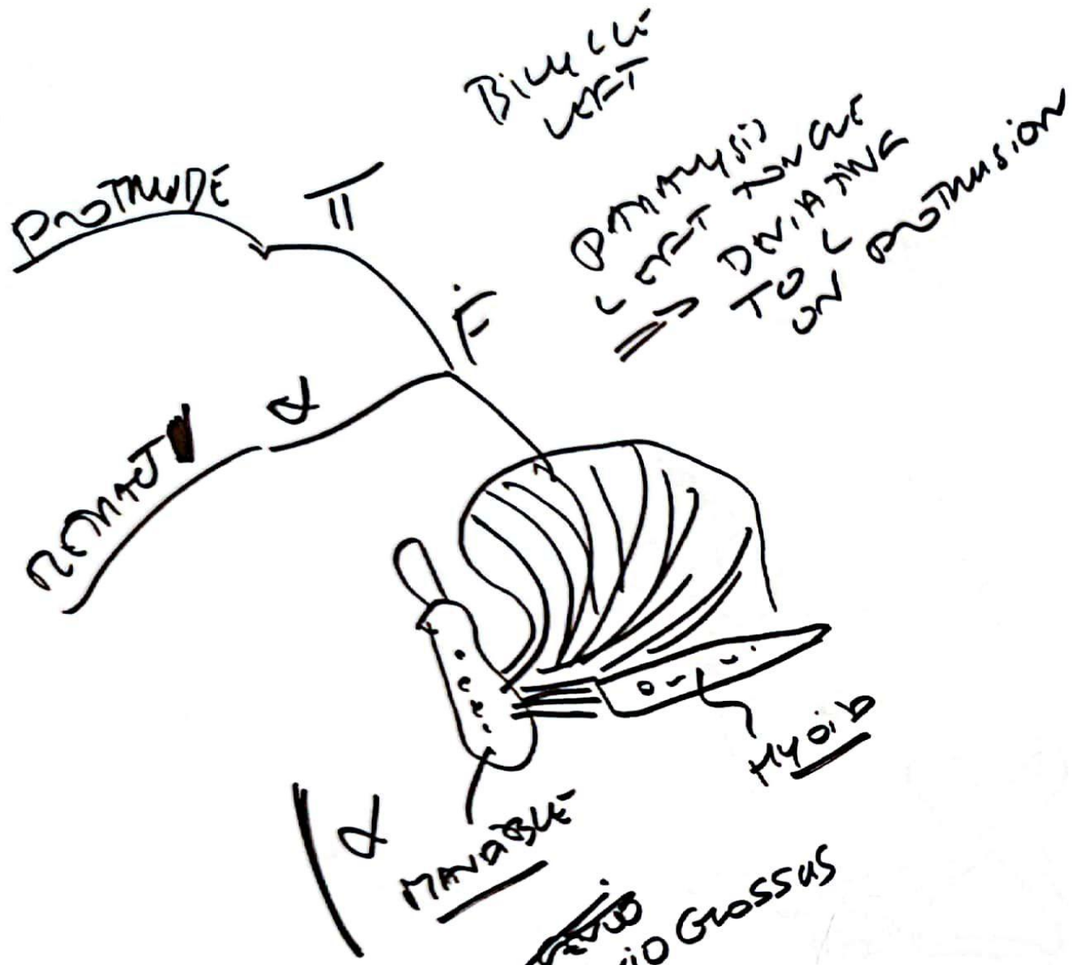

① GENIO GLOSSUS

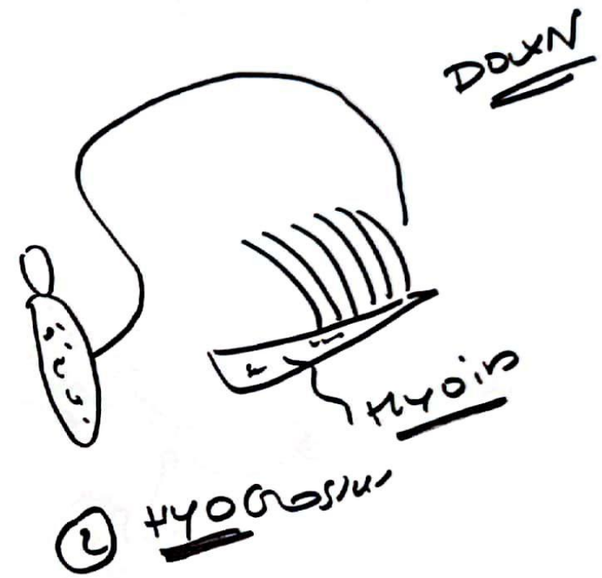

② HYOGLOSSUS



③ STYLO GLOSSUS

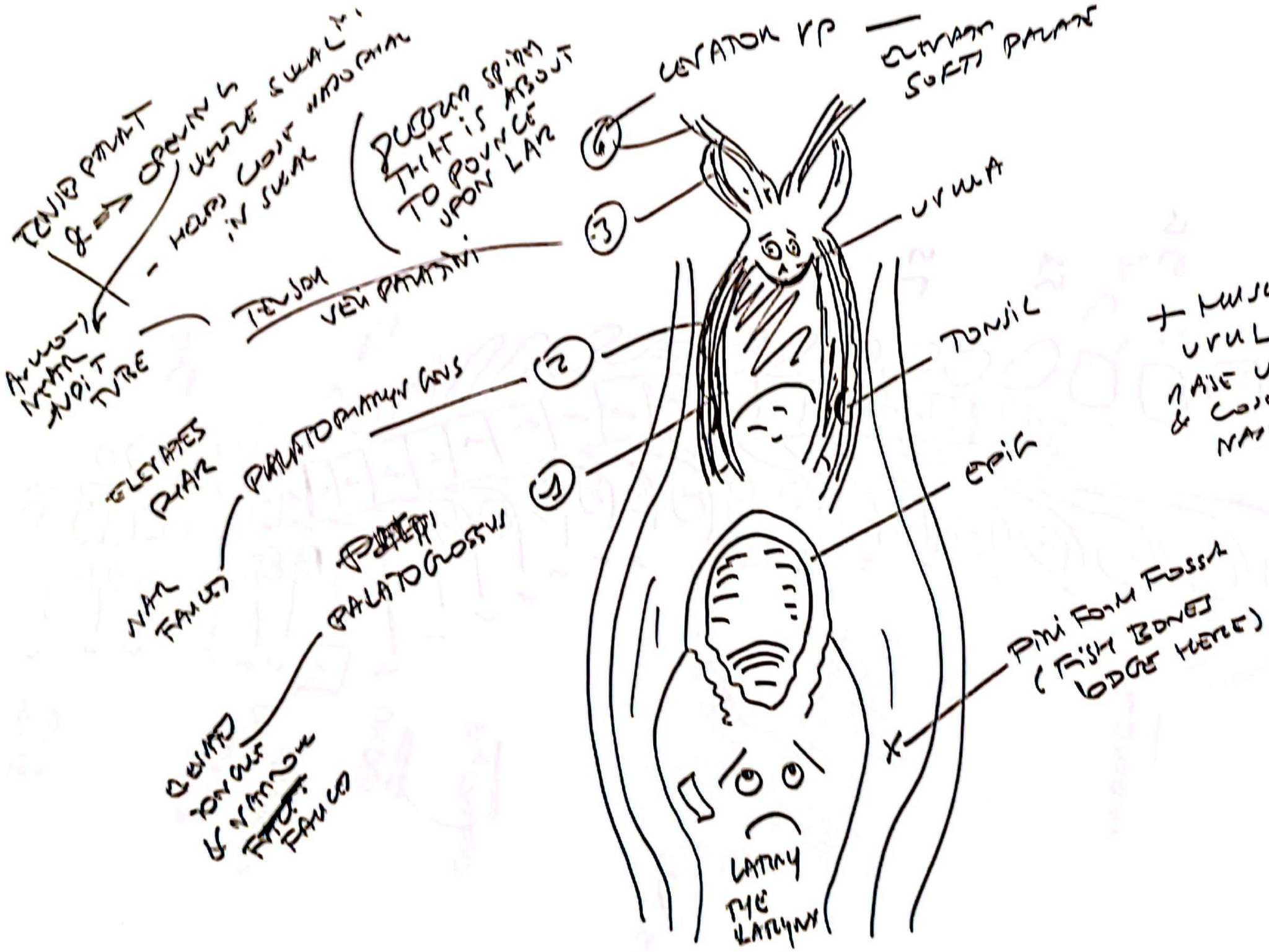

& PALATO
M SOFTPAL
AS SEEN
FROM PHAR

+ MUSCULUS
UVULAE
MAKE UVULA
& COSI
NASOPHA
LARYNX

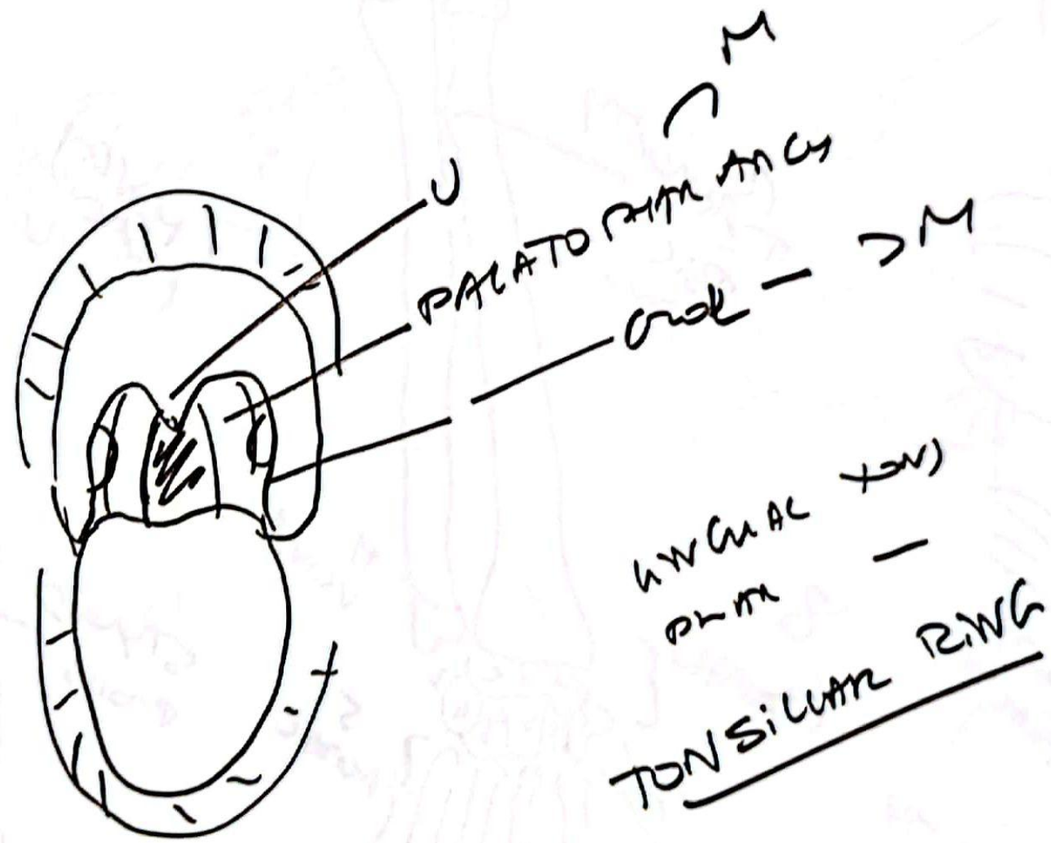
U
PALATOPHARYNGEUS
M
CRUR
M
LINGUAL TONS
PLAN
TONSILLAR RING

PHARYNX

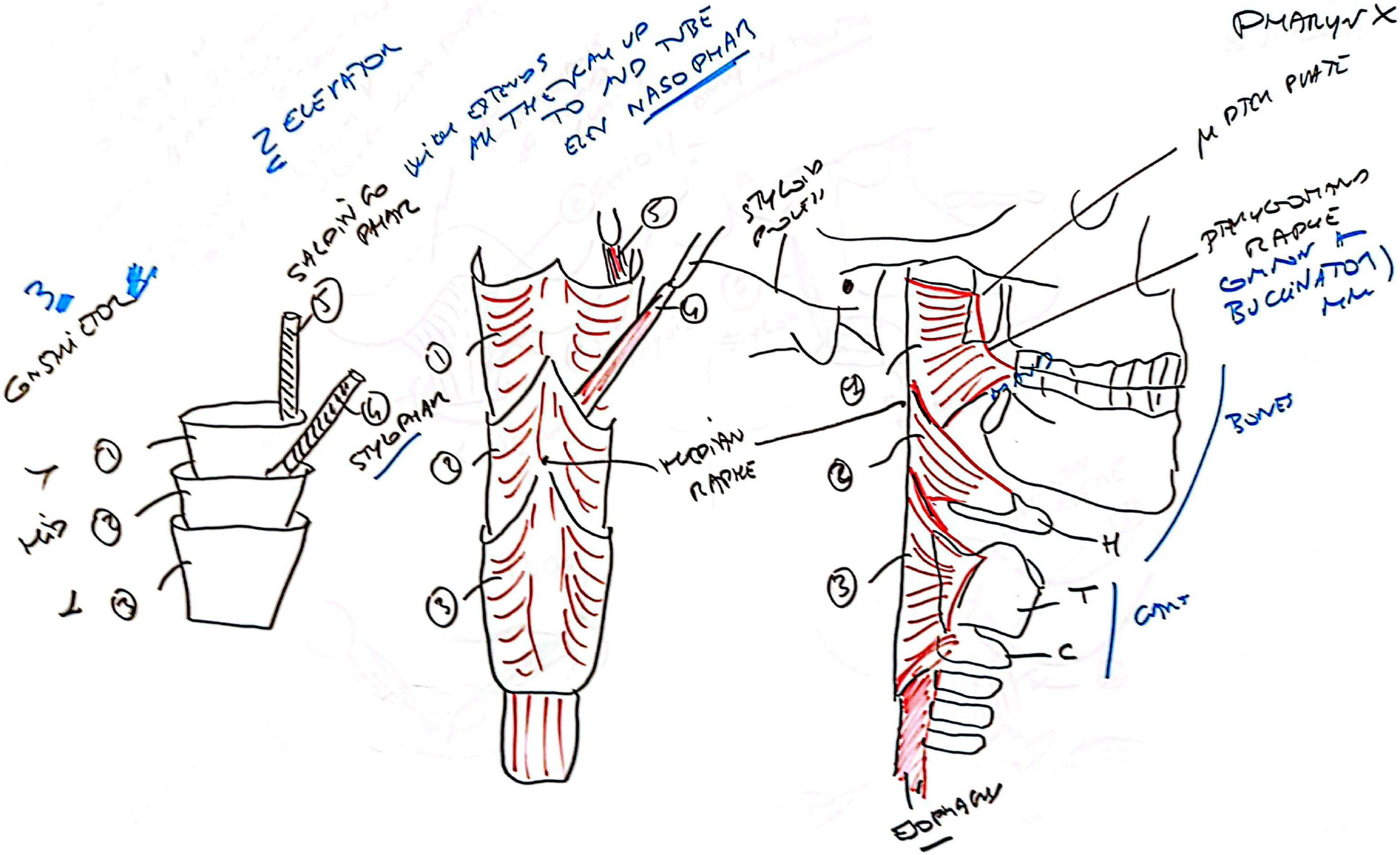
2 ELEVATOR
SALPINGO PHAR
MUSCLE EXTENDS FROM THE CLAM UP TO AND TUBE ELEV NASOPHAR
3 CONSTRICTOR
STYLOPHAR
STYLOID PROCESS
MEDIAN RAPHE
PTERYGOMANDIBULAR RAPHE (MAND + BUCCINATOR)
MEDIAL PLATE
BONES
H
T
C
CONST
ESOPHAGUS
1
2
3
4
5

HYOID

- THE ABOVE → RAISE H WHICH THEN PUSHES LARYNX GENIOID TUNGUE OF FLOOR MOUTH

- BELOW THEM TO LOWER H ALONG WITH PHAR

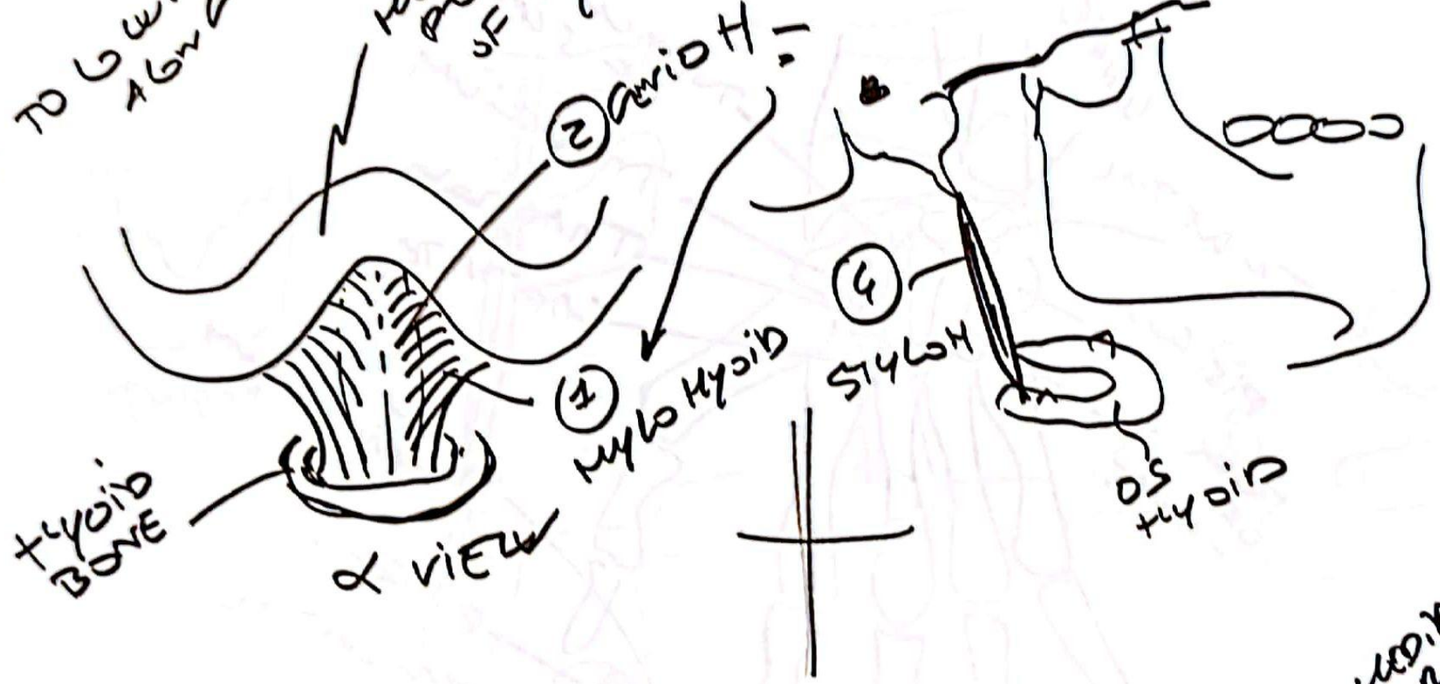

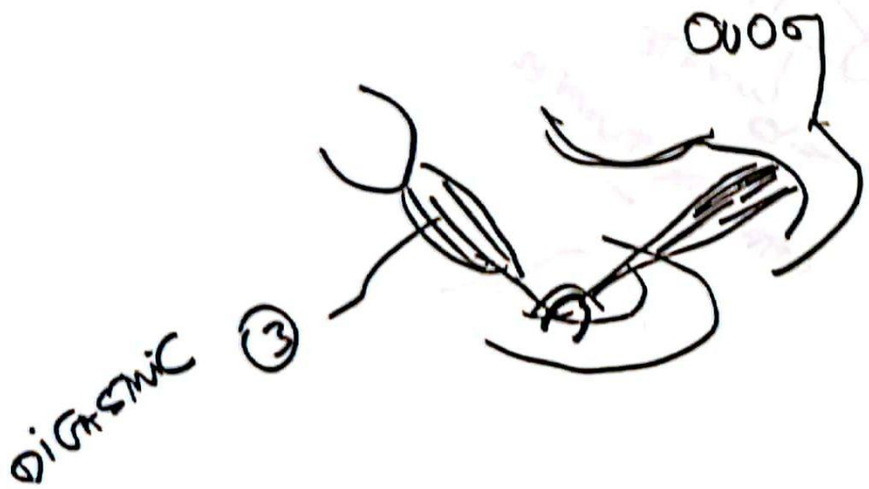

INFRAH

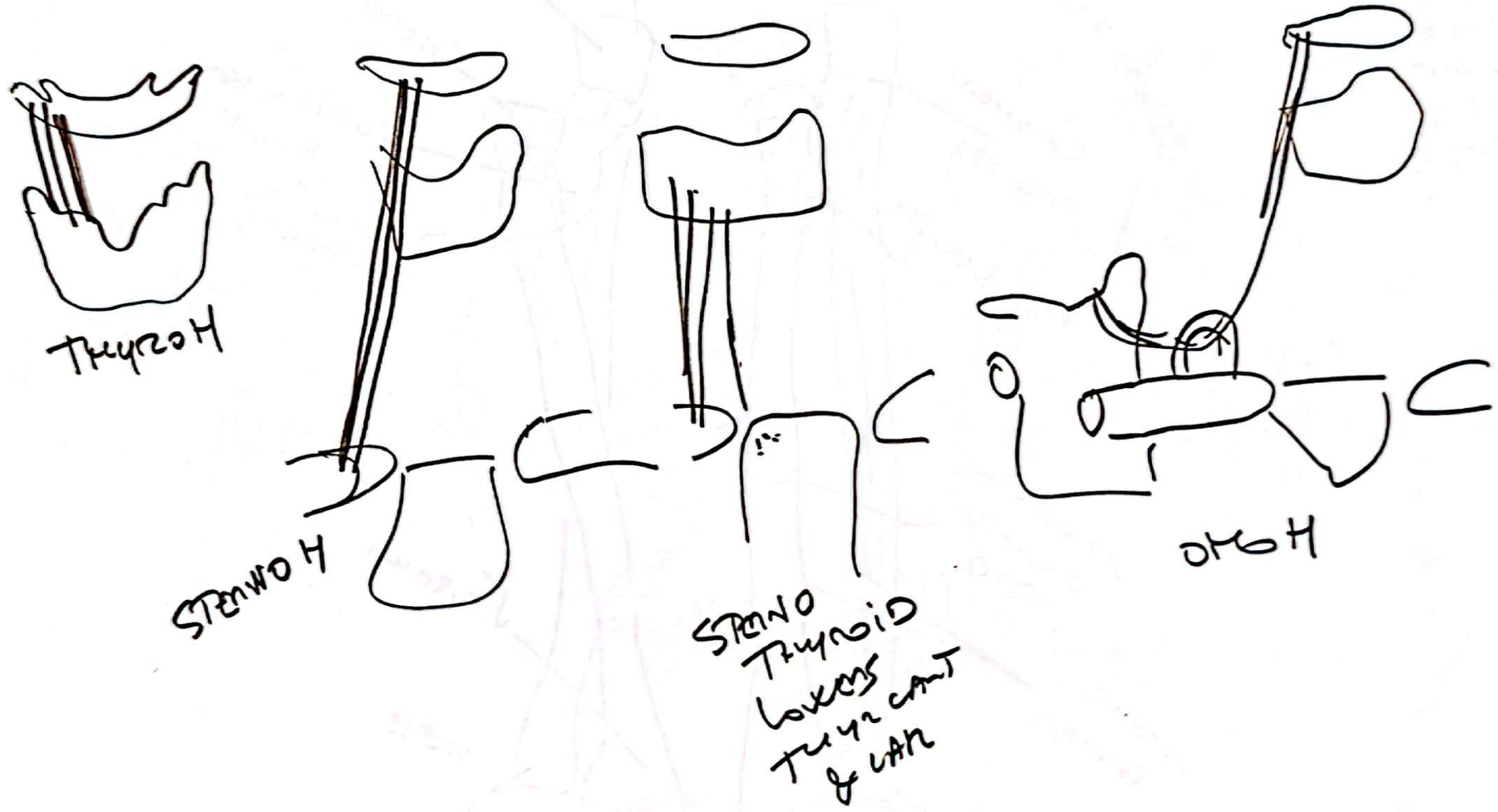

MECHANICS OF SWALLOWING





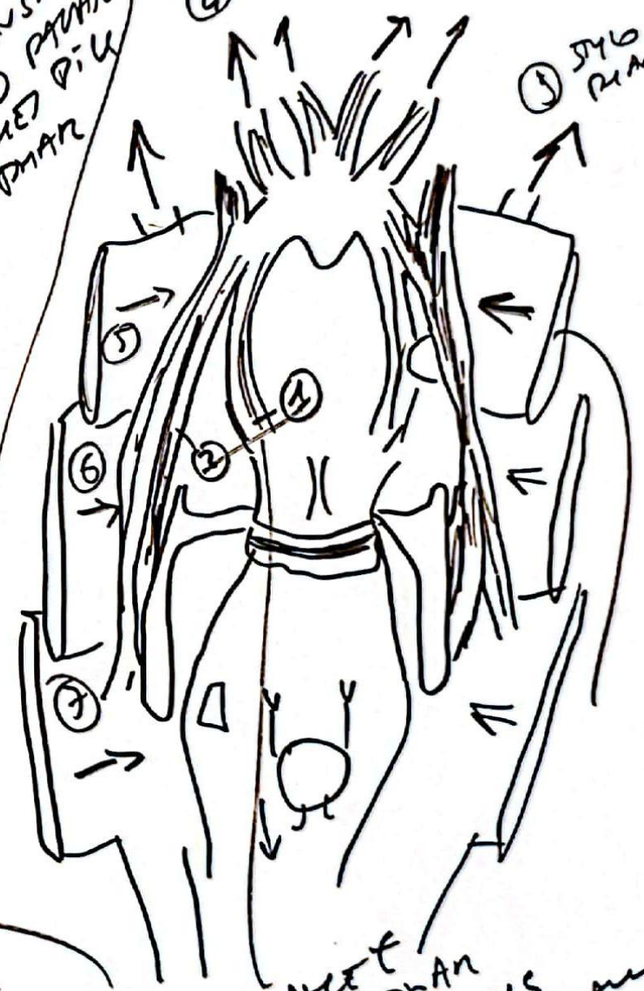

ANOTHER REASON LAR ELEVATES HYOID BONE ELEVATED IN ACT OF PUSHING TONGUE

LAR FUNCTION SPHINCTER EPIG & ARYTEPIGLOTTIC

PHASE 1

VOLUNTARY

INVOLUNTARY